

Childhood Acute Generalized Exanthematous Pustulosis Induced by Oral Ketoconazole

Ljubka Miteva¹, Miroslava Kadurina², Robert A. Schwartz³

¹Department of Dermatology and Venereology, Medical University Sofia; ²Department of Dermatology, Military Medical Academy, Sofia, Bulgaria; ³Dermatology and Pathology, New Jersey medical School, Newark, USA

Corresponding author:

Ljubka Miteva, MD, PhD
Department of Dermatology and Venereology
Medical University
1431 Sofia
Bulgaria
mitev@medfac.acad.bg;
roschwar@cal.berkeley.edu

Received: May 24, 2010.

Accepted: October 27, 2010

SUMMARY Acute generalized exanthematous pustulosis is a rare disorder characterized by an acute onset of generalized, nonfollicular, pustular eruption associated with fever. It is usually drug-induced and is uncommon in children. We report a 12-year-old girl with acute generalized exanthematous pustulosis induced by oral ketoconazole. To our knowledge, in spite of its relatively frequent use, acute generalized exanthematous pustulosis due to ketoconazole has not been previously reported.

KEY WORDS: acute generalized exanthematous pustulosis, ketoconazole, antifungal agents, drug eruption, adverse drug reactions

INTRODUCTION

The term acute generalized exanthematous pustulosis (AGEP) was first introduced by Beylot *et al.* in 1980 (1) to describe a pustular eruption characterized by an acute onset after an infection and/or drug ingestion in subjects with no history of psoriasis, evolution towards spontaneous healing after a single attack, and existence of a marked dermal vasculitis in addition to nonfollicular subcorneal sterile pustules (2,3). We report the occurrence of AGEP as the result of ketoconazole use. To our knowledge, this is the first reported case of ketoconazole-induced AGEP.

CASE REPORT

A 12-year-old girl with a one-year medical history of dermatomyositis was evaluated for the sudden onset of high fever and a widespread ery-

thematous rash of 5-days duration. Soon multiple, small pustules covered her trunk and extremities. The child had been on methylprednisolone therapy for one year from the onset of dermatomyositis with initial dose of 40 mg daily. Methylprednisolone had been gradually tapered and a maintenance dose of 4 mg daily had been established for 15 days prior to the current presentation and was continued during and after AGEP episode. One day before the onset of fever and rash, only ketoconazole 200 mg/day was prescribed as prophylactic therapy for oral candidiasis.

On physical examination, fever was detected (38.8 °C). Numerous erythematous and edematous patches with superficial, nonfollicular pustules were evident over the trunk and extremities (Fig. 1). Mucous membranes and her nails were

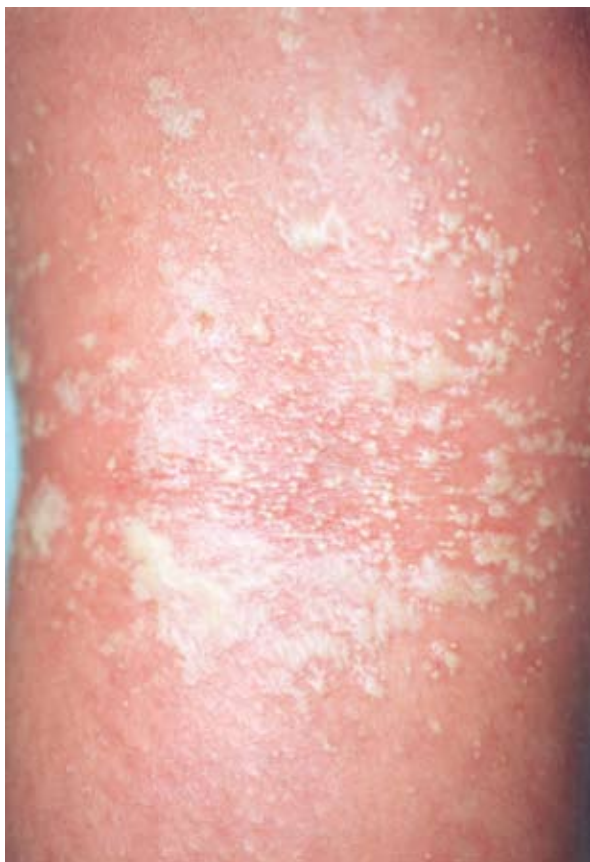

Figure 1. Close-up view of numerous superficial, non-follicular pustules arising on a widespread erythematous base.

spared. Results of laboratory evaluation revealed white blood cell count of $21 \times 10^9/L$ (NR $4.5-9 \times 10^9/L$), with neutrophil count $12.2 \times 10^9/L$ (NR $2-6 \times 10^9/L$) and erythrocyte sedimentation rate (ESR) of 28 mm/h. Liver function tests, urea, creatinine, electrolytes, and serum calcium level were within the normal limits. Viral serology, C-reactive protein, antistreptolysin O titers and bacteriologic studies of pustules were negative.

Histological examination of the skin revealed a large subcorneal pustule and moderate acanthosis. The papillary dermis was edematous with a mixed perivascular inflammatory cell infiltrate of lymphocytes, neutrophils, and a few eosinophils. In some areas, leukocytoclastic vasculitis was observed. The endothelial cells appeared swollen; the blood vessels had decreased lumens (Fig. 2).

The treatment with ketoconazole was stopped. However, methylprednisolone 4 mg daily was continued as to maintain dermatomyositis during and after AGEV episode. Symptomatic treatment with

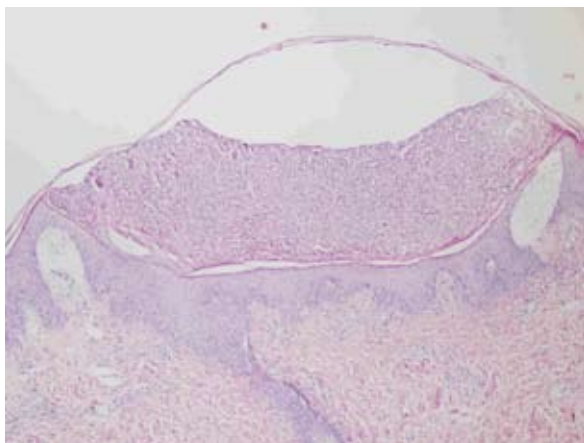


Figure 2. Subcorneal pustule, moderate acanthosis and edematous papillary dermis. HE x 40

topical 0.1% hydrocortisone-17-butyrate cream and levocetirizine 5 mg daily was initiated.

DISCUSSION

Acute generalized exanthematous pustulosis is a rare, rapidly evolving dermatosis characterized by numerous small, sterile nonfollicular pustules arising on a widespread edematous erythema, accompanied by high fever (temperature $>38^\circ C$), and neutrophilia of $>7 \times 10^9/L$. More than 50% of patients have other cutaneous signs, including purpura, vesiculobullae, target-like lesions, and mucous membrane involvement (2). In extensive cases, a positive Nikolsky sign has been observed (2,3). Characteristic laboratory findings include an elevated total blood cell count, which is usually predominantly neutrophilic ($7 \times 10^9/L$). Eosinophilia may also be present. Hypocalcemia is less frequent, mainly related to hypoalbuminemia and renal failure (2). The main histopathologic findings in AGEV are spongiform superficial pustules. Papillary dermal edema, polymorphous perivascular infiltrates with eosinophils, leukocytoclastic vasculitis, and necrotic keratinocytes are variably present (2). Pustular eruption of necrotizing vasculitis, Sneddon-Wilkinson disease, staphylococcal scalded skin syndrome, and toxic epidermal necrolysis can be distinguished more easily on the clinicopathologic basis. The pathogenetic basis of AGEV remains to be clarified, although T cells seem to play a crucial role (3).

The most frequent triggers of AGEV are medication, specifically β -lactam antibiotics, macrolides, vancomycin, doxycycline, diltiazem, nifedip-

ine, quinidine, anti-HIV protease inhibitors, non-steroidal anti-inflammatory drugs, and corticosteroids (2-6). Other, less common causes of AGEP are enterovirus, adenovirus, Epstein-Barr virus, cytomegalovirus, hepatitis B virus, mycoplasma pneumoniae, and hypersensitivity to mercury (2,6). Oral corticosteroids have been implicated in AGEP (6). In our case, the possibility that methylprednisolone could be a mitigating or modifying factor should be excluded as the patient had been on systemic corticosteroid therapy for one year to maintain dermatomyositis under control.

AGEP is remarkable for its rapid evolution with spontaneous resolution of pustules in less than 15 days (2). It is also more common in women than men, and unusual in children (6), although it was recently described in 20 Chinese children, attributed mainly to antibiotics, sulfonamides, antipyretic analgesics and vaccines (7), and in a pregnant woman (8).

AGEP has been reported with the systemic antimycotics fluconazole (9), terbinafine (10,11), itraconazole (12,13) and nystatin (14). As far as we are aware, there have been no reports of its occurrence with the use of ketoconazole. Ketoconazole itself is a highly safe agent, although it is possible that, due to its widespread use, a hypersensitivity reaction, especially AGEP, may appear. Ketoconazole-induced allergic reactions are infrequent and usually consist of urticaria, rash and pruritus. In a small number of cases, ketoconazole triggered angioedema. Major allergic reactions, including anaphylaxis, have been reported (15).

In our case, the diagnosis of AGEP induced by ketoconazole was established based upon the history of recent ingestion, clinical presentation, clinical course, and laboratory and histologic findings. We consider the occurrence of dermatomyositis to be incidental, with AGEP as a drug reaction to oral ketoconazole. Patch testing may be used to diagnose drug-induced AGEP (16), but it has the potential to trigger the original generalized eruption (17,18). Therefore, patch test was not performed in our case. Recently, an *in vitro* γ -interferon release test has been used to diagnose AGEP, but its role remains investigational (5). Although the child described herein responded well to 0.1% hydrocortisone-17-butyrate cream and levocetirizine, in severe cases systemic steroids may be employed and the use of cyclosporine considered (19).

References

1. Beylot C, Bioulac P, Doutre MS. Pustuloses exanthematiques aigues generalises: a propos de 4 cas. *Ann Dermatol Venerol* 1980;107:37-48.
2. Roujeau JC, Bioulac P, Doutre MS. Acute generalized exanthematous pustulosis: analysis of 63 cases. *Arch Dermatol* 1991;127:1333-8.
3. Sidoroff A, Dunant A, Viboud C, Halevy S, Bavinck JN, Naldi L, *et al.* Risk factors for acute generalized exanthematous pustulosis (AGEP) – results of a multinational case-control study (EuroSCAR). *Br J Dermatol* 2007;157:989-96.
4. Yesudian PD, Penny M, Azudria RM, King M. Ibuprofen-induced acute generalized exanthematous pustulosis. *Int J Dermatol* 2004;43:208-10.
5. Halevy S, Cohen AD, Livini E. Acute generalized exanthematous pustulosis associated with polysensitivity to paracetamol and bromhexiene: the diagnostic role of *in vitro* interferon- γ release test. *Clin Exp Dermatol* 2000;25:652-4.
6. Meadows KP, Egan CA, Vanderhooff S. Acute generalized exanthematous pustulosis (AGEP), uncommon condition in children. Case report and review of literature. *Pediatr Dermatol* 2000;17:399-402.
7. Zhang JL, Chen X, Li J, Xie HF. Clinical analysis of childhood acute generalized exanthematous pustulosis. *Zhongguo Dang Dai Er Ke Za Zhi* 2008;10:497-9.
8. Reich A, Szepletowski JC, Baran E. Severe acute generalized exanthematous pustulosis in a pregnant woman. *Skinmed* 2006;5:197-9.
9. Alsadhar A, Taher M, Krol A. Acute generalized exanthematous pustulosis induced by oral fluconazole. *J Cut Med Surg* 2002;6:122-4.
10. Rodalski C, Hurlimann A, Burg G, Wuethrich B, Kempf W. Drug reaction to terbinafine simulating an acute generalized exanthematous pustulosis. *Hautarzt* 2001;52:444-8.
11. Rubegni P, Mandato F, Sbrano P, Fimiani M. Terbinafine-induced acute generalized exanthematous pustulosis. *G Ital Dermatol Venerol* 2008;143:151-5.
12. Park YM, Kim JW, Kim CW. Acute generalized exanthematous pustulosis induced by itraconazole. *J Am Acad Dermatol* 1997;36:794-6.
13. Cançado GG, Fujiwara RT, Freitas PA, Correa-Oliveira R, Bethony JM. Acute generalized exanthematous pustulosis induced by itraconazole: an immunological approach. *Clin Exp Dermatol* 2009;34:e709-11.
14. Kuchler A, Hamm H, Weidenthaler-Barth B, Kampgen E, Blocker EB. Acute generalized

- exanthematous pustulosis following oral nystatin therapy: a report of three cases. *Br J Dermatol* 1977;137:808-11.
15. Cauwenbergh G. Safety aspects of ketoconazole, the most commonly used systemic antifungal. *Mycoses* 1989;32(Suppl 2):59-63.
16. Wittam LR, Wakelin SH, Barker JNWN. Generalized pustular psoriasis or drug-induced pustuloderma? The use of patch testing. *Clin Exp Dermatol* 2000;25:122-4.
17. Moreau A, Domp Martin A. Drug-induced acute generalized exanthematous pustulosis with positive patch tests. *Int J Dermatol* 1995;34:263-6.
18. Nishimura T, Yoshioka K, Katoh J. Pustular reaction induced by diltiazem HCL. *Skin Res* 1991;31(Suppl 10):308-9.
19. Di Lernia V, Grenzi L, Guareschi E, Ricci C. Rapid clearing of acute generalized exanthematous pustulosis after administration of cyclosporine. *Clin Exp Dermatol* 2009;34:e757-9.



INNOXA

*Stavite Vašu kožu u
„mliječno” stanje!*

Gospodjo!

Načinite ovaj pokus: namočite nešto vate mlijekom »INNOXA« a zatim brižljivo očistite Vaše lice. Bit ćete iznenađeni, jer će vata pobrati mnogo nečistoće. Budete li redovito izjutra i navečer izvršavali ovaj jednostavni i štedljivi postupak, moći ćete doskora ustanoviti:

1. da mlijeko »INNOXA« divno čuva kožu,
2. da čisti kožne pore do dna i to mnogo bolje nego sapun i da kožu ne nadražuje,
3. da omogućuje nesmetano disanje kože,
4. da zbog izvjesnih primjesa hrani racionalno kožu čineći je glatkom, jednoličnom, zdravom i stavljajući je zaista u »mliječno« stanje.

Zdrava koža je jedina tajna divnog teinta. Puder i šminka prikrivaju samo nepotpuno a često još više ispoljuju mane jedne umorne i osušene kože. Naprotiv, proizvodi »INNOXA« uvećavaju savršenost jedne glatke kože dajući teintu zaista divan sjaj.

**MLIJEKO
I N N O X A**
NIJE ŠMINKA

Krema i puder »INNOXA« upotpunjuju blagotvorni učinak mlijeka »INNOXA«

LABORATOIRE INNOXA
63, RUE DE PRONY, PARIS

GENERALNO ZASTUPSTVO:
HENRY H. NEUMANN, ZAGREB
BOŠKOVIČEVA 42

Innox – put your skin in 'milky' condition; year 1929.
(From the collection of Mr. Zlatko Puntijar)