

Expression of MAGE-A1, MAGE-A3/4 and NY-ESO-1 Cancer-Testis Antigens in Fetal Testis

Tvrtko Hudolin¹, Željko Kaštelan¹, Danijel Derežić¹, Nikolina Bašić-Jukić², Giulio Cesare Spagnoli³, Antonio Juretić⁴, Davor Ježek⁵

¹University Department of Urology, ²Dialysis Department, University Department of Medicine, Zagreb University Hospital Center, Zagreb, Croatia; ³Research Department, University Department of Surgery, Basel University Hospital, Basel, Switzerland; ⁴University Department of Oncology, Zagreb University Hospital Center, Zagreb, Croatia; ⁵Department of Histology and Embryology, School of Medicine, University of Zagreb, Zagreb, Croatia

Corresponding author:

Tvrtko Hudolin, MD, PhD
University Department of Urology
Zagreb University Hospital Center
Kišpatičeva 12
HR-10000 Zagreb
Croatia
thudolin@hotmail.com

Received: November 5, 2008

Accepted: May 5, 2009

SUMMARY Immunohistochemical expression of MAGE-A1, MAGE-A3/4 and NY-ESO-1/LAGE-1 cancer testis antigens (CTA) was assessed in 24 fetal testes from 15th to 36th week of gestation. Three monoclonal antibodies were used for immunohistochemical staining: 77B recognizing MAGE-A1, 57B recognizing multiple MAGE-A CTA, and D8.38 recognizing NY-ESO-1/LAGE-1. Expression of MAGE-A1 was not observed in fetal testis samples, whereas multi-MAGE-A and NY-ESO-1/LAGE-1 specific reagents stained pro-spermatogonia in all samples with different expression levels during the period of fetal development observed. Significant expression of MAGE-A3/4 and almost continuous expression of NY-ESO-1 in fetal testes after 22nd week of gestation suggested their important role in the development of sex cords and pro-spermatogonia in particular.

KEY WORDS: NY-ESO-1, MAGE-A, fetal testes, development, cancer antigens

INTRODUCTION

Cancer testis antigens (CTA) are proteins expressed in a limited number of healthy tissues and in a large variety of tumors of unrelated histologic origin (1). In normal tissue, their expression has been detected in adult testis germ cells and placenta (2). Their biological function remains unknown, although indications for their involvement in the regulation of gene expression have been re-

ported (3). Notably, they are able to induce humoral and cellular immune responses and therefore a number of them have been under evaluation as vaccines in the active specific tumor immunotherapy (4,5).

The generation of specific monoclonal antibodies (mAb) has permitted identification of CTA at the protein level in a number of tissue samples by

a relatively simple, inexpensive and fast method. In this study, we investigated the expression of CTA in fetal testis tissue, with the aim to improve the knowledge of MAGEs and NY-ESO-1 protein expression in developing testes.

MATERIALS AND METHODS

Tissue samples

Twenty four fetal testes from 15th to 36th week of gestation were investigated. All samples were obtained during routine pedopathologic section after spontaneous abortions at University Department of Gynecology and Obstetrics, Zagreb University Hospital Center. Developmental age of the fetuses was determined by data on the last period and from autopsy data, e.g., crown-rump length, crown-heel length, femur and humerus length.

Histology

The testis tissue samples were fixed in Bouin's fluid, dehydrated and embedded in paraffin. Paraffin blocks were cut into sections for hematoxylin-eosin (H+E) and immunohistochemical staining.

Immunohistochemistry

Tissue sections of 3-5 μm thickness were cut from paraffin embedded tissue blocks and placed on object slides (Menzel-Glaser, Germany). Slides with tissue sections were incubated for 20 minutes in a thermostat at 60 °C. Sections were then deparaffinized and incubated for 3x5 minutes in 10 mmol/L citrate buffer (pH 6.0) in a microwave oven at 800 W power. Subsequently, tissue slides were washed with PBS buffer (pH 7.2) and the endogenous peroxidase activity was blocked by a 5-min treatment with H₂O₂ (Dako-No.S2023). Slides were then washed with PBS buffer and incubated for 90 minutes with 77B, 57B, or D8.38 undiluted supernatant at room temperature.

After wash in PBS buffer, the secondary biotinylated antibody (Dako-No. K0690) was added for 30-min incubation. Slides were then washed with PBS buffer and treated with streptavidin-horseradish peroxidase (Dako-No. K0690) for 30 minutes. Tissue sections were washed once more in PBS buffer and then chromogen (Dako-No. K3468) was added for 5 minutes. Slides were washed in distilled water, stained with hemalaun (Dako-No. S2020) for 1 minute, washed with water, dehydrated with alcohol (96%), cleared with xylene, and mechanically covered.

Melanoma expressing CTA and adult testis tissues were used as positive control throughout the

study, whereas stroma and unstained cells served as negative control. Immunohistochemistry staining results were semiquantitatively expressed as follows: 1) negative response (-): no staining in germ cells; 2) weak positive response (+): up to 10% of germ cells positive; 3) moderate positive response (++) : 11%-50% of germ cells positive; and 4) strong positive response (+++) : over 50% of germ cells positive.

The study was approved by the Ethics Committee of the Zagreb University Hospital Center and Ethics Committee of the School of Medicine, University of Zagreb.

RESULTS

The fetal testes under investigation consisted of two major parts: sex cords and interstitial compartment, i.e. stroma. Sex cords measured 40-50 μm and were limited by several layers of peritubular cells and lined with pro-spermatogonia and fetal Sertoli cells. Pro-spermatogonia were recognized by their abundant and pale-stained cytoplasm. Their nucleus was large, ovoid or round, with abundant euchromatin and clumps of heterochromatin, predominantly associated with nuclear envelope. Frequently, one or more prominent nucleoli could be noted within the nuclei of the cells.

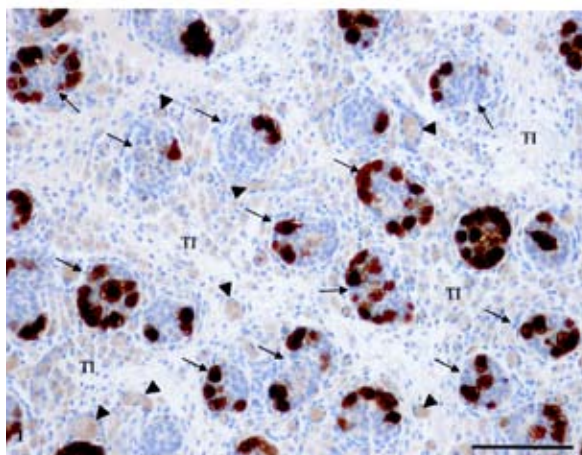


Figure 1. Human fetal testis in 18th week of gestation. Sex cords (arrows) are surrounded by layers of peritubular cells and lined with pro-spermatogonia and Sertoli cells. Some pro-spermatogonia (recognized by their size and abundant cytoplasm) highly express MAGE-A3/4. Sertoli cells show no positivity. The testis interstitium (TI) is composed of loose connective tissue with blood vessels (arrowheads). Leydig cells of the interstitium are negative for MAGE-A3/4. (DAB and hematoxylin staining, X200, scale bar = 100 μm)

Sertoli cells were distinguished by their smaller size (when compared to pro-spermatogonia), scanty cytoplasm, and round or ovoid nucleus. Within the interstitium of the gonad, fetal Leydig cells appeared in 2 forms. One cell type was oval, with centrally or eccentrically positioned nucleus and sometimes well-visible nucleolus, whereas another cell type was elongated with round or oval nucleus situated mainly in the middle of the cell. Other loosely arranged connective tissue cells including small blood vessels contributed to the interstitial compartment of the human fetal testis. In general, sex cords and associated blood vessels in the interstitium grew progressively from 15th to 36th week of gestation, achieving rather tortuous structures.

The expression of MAGE-A1 CTA as detected by 77B mAb was always negative in our samples, whereas multi MAGE-A specific, 57B and NY-ESO-1/LAGE-1 specific D8.38 mAbs stained pro-spermatogonia throughout the gestational period under investigation (Figs. 1 and 2). Both antibodies stained the cytoplasm of pro-spermatogonia, whereas no positive signal was found in Sertoli or peritubular cells of sex cords. It should be pointed out that not all pro-spermatogonia within the individual sex cords were positive at various gestational weeks, but only a fraction of them (Figs. 1 and 2). In addition, no positive cells were found in the interstitium of the gonad. Leydig cells as well as other interstitial cells including blood vessels were negative.

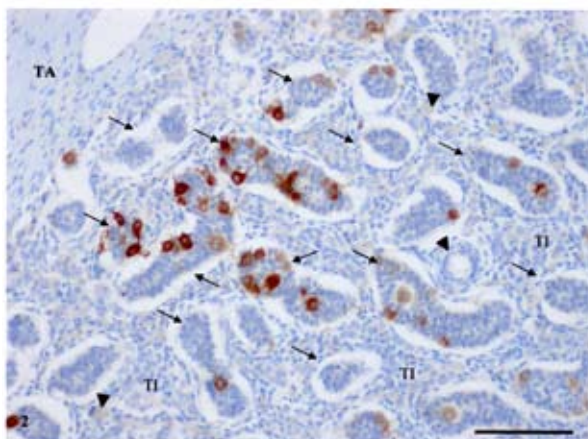


Figure 2. Part of human fetal testis in 25th week of development; expression of NY-ESO-1/LAGE-1. Some sex cords (arrows) contain immunopositive pro-spermatogonia. The testis interstitium (TI) demonstrates no positive cells. Blood vessels (arrowheads). Tunica albuginea (TA). (DAB and hematoxylin staining, X200, scale bar = 100µm)

The MAGE-A3/4 positivity was uneven during fetal development. It was present starting at 16th week, the earliest time point evaluated, and it slightly increased until 26th week. Thereafter, MAGE-A expression decreased, albeit never below the ++ level of positivity with a nadir at 33rd week. Then it roused again towards the end of fetal development. In contrast to MAGE-A, NY-ESO-1/LAGE-1 expression was initially detected with higher intensity and reached its maximum at 24th week. This level remained constant throughout fetal development (Fig. 3).

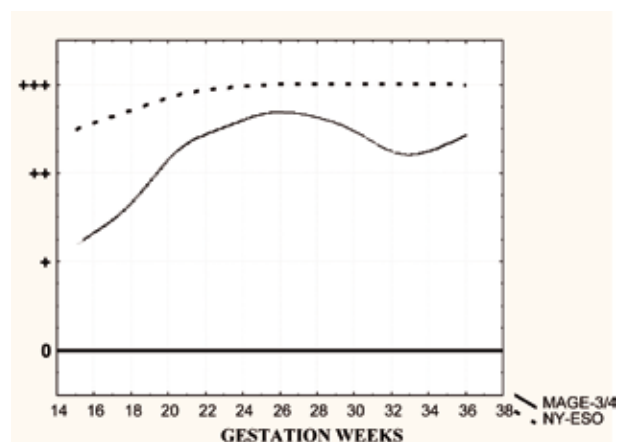


Figure 3. Distribution of MAGE-A and NY-ESO-1/LAGE-1 expression in fetal testes during gestation.

DISCUSSION

It has been shown that human fetal germ cells are heterogeneous regarding their morphology and production of different proteins. It has also been suggested that CTA are involved in the development and differentiation of fetal germ cells. The aim of the study was to improve our knowledge of MAGEs and NY-ESO-1 protein expression in developing testes.

We detected CTA expression only in pro-spermatogonia, as previously observed (6). MAGE-A1 expression was negative in all our samples. Gjerstorff *et al.* observed a bimodal pattern of expression with high MAGE-A1 expression in the 9th week of development, subsequently decreasing until 16th week (7). Then it started to be strongly expressed until 21st week, slightly dropping thereafter. The discrepancy with our results could be explained by the use of a different antibody (MA 454), which in our previous work with tumor samples displayed a stronger positivity as compared to 77B (8). Pauls *et al.* using the same mAb 57B as in

our study found only a few germ cells to express MAGE-A at week 12/13. The expression was then continuously increasing during further development, reaching 50% of germ cells at week 24 and more than 90% in the testis of the neonate (9). Our results are consistent with the high expression of MAGE-A in 26th week, slightly decreasing until 33rd week and then rising again towards maximum levels. These data are also consistent with a bimodal timing of MAGE-A CTA expression, see above.

Satie *et al.* found no NY-ESO-1 staining in immature gonad (before 16th week of gestation), with an increased number of positive cells in 18th week and maximum in 40-week-old fetus (10).

We showed the expression of NY-ESO-1/LAGE-1 to reach maximum level in 20th week, then maintaining it until the end of development. The constantly high level of NY-ESO-1 expression underlines its putatively important function during the second half of fetal development of pro-spermatogonia. On the other hand, no staining was found in fetal Sertoli and Leydig cells, or in the cells of connective tissue, as previously described (10).

Our immunohistochemical study showed missing expression of MAGE-A1, a bimodal expression of MAGE-A, and an almost constantly strong expression of NY-ESO-1/LAGE-1 CTA after 20th week of fetal testis development, suggesting that these proteins might play an important role in the pro-spermatogonia development.

Detection of CTA expression in fetal gonads as well as in gonads after birth on the one hand, and in different tumors in humans on the other hand, shows that these proteins could be responsible for some common characteristics of gonad cells and cancer cells. There is a possibility that cancer is re-expressing CTA in order to achieve some of the characteristics that can help it grow and advance. The re-expression of CTA in cells may be related to immortalization, invasion, lack of adhesion and migratory behavior of the cells as well as to demethylation and downregulation of MHC. Due to a significant number of proteins in CTA family, it is not easy to investigate their exact function in developing and adult testes. However, prolonged and strong expression of NY-ESO-1 from the beginning of second trimester till the end of pregnancy indicates that this protein has a general function in developing germ cells. Its function is probably not associated with a specific developmental stage in germ cell differentiation, as it may be the case with MAGE-A which showed bimodal distribution (11).

Our immunohistochemistry data show that both MAGE-A3/4 and NY-ESO-1/LAGE-1 are expressed in some pro-spermatogonia, while at the same time a large number of these cells are negative. The reason for this could lie in different phases of maturation. Although looking much alike, some of these cells could be either in 'silent' mode (expression of MAGE-A3/4 and NY-ESO-1/LAGE-1 genes is switched off) or strongly expressing the afore-mentioned antigens, as described in the results of the present study.

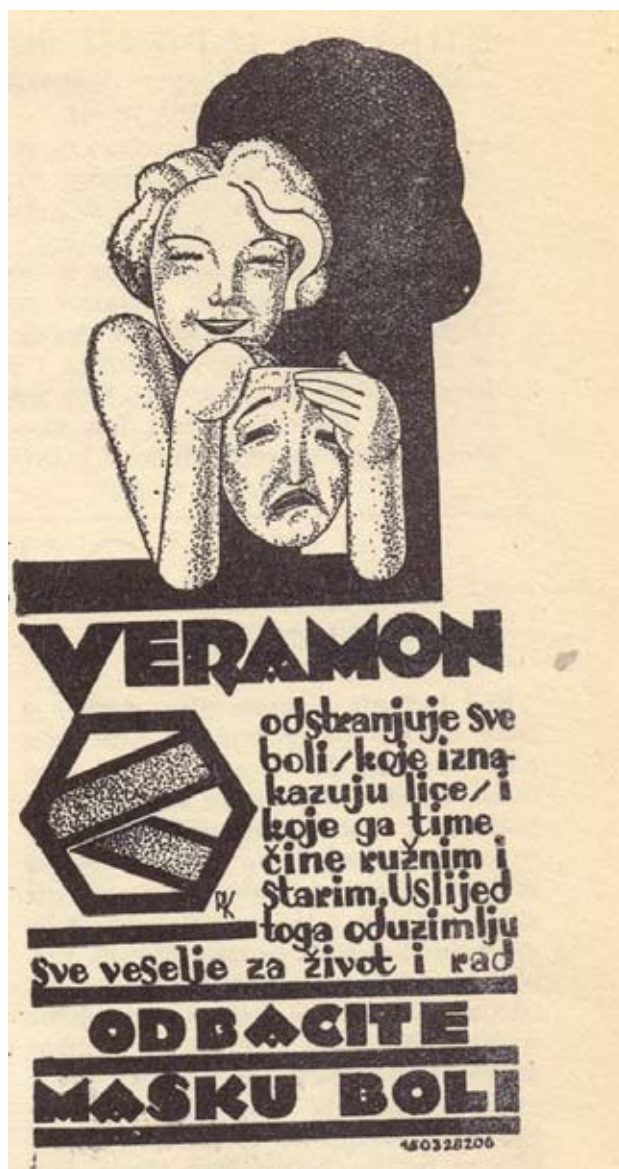CONCLUSION

Thus, pro-spermatogonia (although morphologically a homogeneous cell type within fetal sex cords) can be postulated to form an inhomogeneous population of cells regarding their maturation phase and gene expression.

References

1. Zendman AJ, Ruiters DJ, Van Muijen GN. Cancer/testis-associated genes: identification, expression profile, and putative function. *J Cell Physiol* 2003;194:272-88.
2. Jungbluth AA, Silva WA Jr, Iversen K, Frosina D, Zaidi B, Coplan K, *et al.* Expression of cancer-testis (CT) antigens in placenta. *Cancer Immun* 2007;24:7-15.
3. Laduron S, Deplus R, Zhou S, Kholmanskikh O, Godelaine D, De Smet C, *et al.* MAGE-A1 interacts with adaptor SKIP and the deacetylase HDAC1 to repress transcription. *Nucleic Acid Res* 2004;32:4340-50.
4. Thurner B, Haendle I, Roder C, Dieckmann D, Keikavoussi P, Jonuleit H, *et al.* Vaccination with MAGE-3A1 peptide-pulsed mature, monocyte-derived dendritic cells expands specific cytotoxic T cells and induces regression of some metastases in advanced stage IV melanoma. *J Exp Med* 1999;190:1669-78.
5. Nestle FO, Aljagic S, Gilliet M, Sun Y, Grabbe S, Dummer R, *et al.* Vaccination of melanoma patients with peptide- or tumor lysate-pulsed dendritic cells. *Nat Med* 1998;4:328-32.
6. Aubry F, Satie AP, Rioux-Leclercq N, Rajpert-De Meyts E, Spagnoli GC, Chomez P, *et al.* MAGE-A4, a germ cell specific marker, is expressed differentially in testicular tumors. *Cancer* 2001; 92:2778-2785.
7. Gjerstorff MF, Kock K, Nielsen O, Ditzel HJ. MAGE-A1, GAGE and NY-ESO-1 cancer/tes-

- tis antigen expression during human gonadal development. *Hum Reprod* 2007;22:953-60.
8. Hudolin T, Juretic A, Spagnoli GC, Pasini J, Bandic D, Heberer M, Kosicek M, *et al.* Immunohistochemical expression of tumor antigens MAGE-A1, MAGE-A3/4, and NY-ESO-1 in cancerous and benign prostatic tissue. *Prostate* 2006;66:13-8.
 9. Pauls K, Schorle H, Jeske W, Brehm R, Steger K, Wernert N, *et al.* Spatial expression of germ cell markers during maturation of human fetal male gonads: an immunohistochemical study. *Hum Reprod* 2006;21:397-404.
 10. Satie AP, Rajpert-De Meyts E, Spagnoli GC, Henno S, Olivo L, *et al.* The cancer-testis gene, NY-ESO-1, is expressed in normal fetal and adult testes and in spermatocytic seminomas and testicular carcinoma *in situ*. *Lab Invest* 2002;82:775-80.
 11. Jungbluth AA, Chen YT, Stockert E, Busam KJ, Kolb D, Iversen K, *et al.* Immunohistochemical analysis of NY-ESO-1 antigen expression in normal and malignant human tissues. *Int J Cancer* 2001;92:856-60.



Veramon - against pain; year 1929.
(from the collection of Mr. Zlatko Puntijar)