

TP53, Bcl-2 and Growth Hormone Receptor Expression in Cutaneous Squamous Cell Carcinoma

Andrija Stanimirović, Hrvoje Čupić, Berislav Bošnjak¹, Davor Tomas, Božo Krušlin, Mladen Belicza

Ljudevit Jurak University Department of Pathology, Sestre milosrdnice University Hospital; ¹Pliva Research Institute Ltd., Zagreb, Croatia

Corresponding author:

Professor Mladen Belicza, MD, PhD
Ljudevit Jurak University Department of Pathology
Sestre milosrdnice University Hospital
Vinogradska 29
HR-10000 Zagreb
Croatia
mbelicza@kbsm.hr; juraks@kbsm.hr

Received: February 20, 2005

Accepted: August 20, 2005

SUMMARY The incidence and prevalence of premalignant and malignant skin lesions including squamous cell carcinoma (SCC) of the skin are increasing worldwide. The aim of the study was to determine TP53, Bcl-2 and growth hormone receptor (GHR) expression in SCC and to investigate relative importance of these proto-oncogenes in its biological behavior. Expression of TP53, Bcl-2 and GHR was determined by immunohistochemistry in 27 SCC specimens and adjacent perilesional skin. The relative proportion of immunoreactive cells was counted with semiquantitative method. TP53 positivity was detected in 24 (89%), Bcl-2 in 18 (67%) and GHR in 25 (93%) of 27 SCC specimens investigated. In comparison with perilesional skin, TP53 and GHR positivity was significantly increased, and Bcl-2 positivity significantly decreased in SCC. Increased TP53 expression in SCC lesions implies that *Tp53* mutation is an early and crucial event in its development. Increased GHR expression suggests a role of growth hormone in the development of SCC.

KEY WORDS Bcl-2; growth hormone receptor; immunohistochemistry; squamous cell carcinoma; TP53

INTRODUCTION

Squamous cell carcinoma of the skin (SCC) is the second most common nonmelanoma skin cancer, frequently observed in the sun-exposed skin areas of the middle-aged and elderly population (1). SCC is induced by several forms of environmental damage, especially sun ultraviolet (UV) light. SCC can also arise from actinic keratosis (AK) (2). Furthermore, as AK shares great clinical and pathological similarity with SCC, novel investigations consider AK as an initial stage in the development of SCC (1,3,4).

Both AK and SCC arise from the expansion of keratinocyte clones with acquired mutations

induced by UV light (4). Detailed molecular mechanism of SCC development and progression has not yet been completely elucidated. Recent literature connects AK and SCC development and progression with increased cell proliferation rather than protection from apoptosis (5,6).

TP53 and Bcl-2 were recognized as pivotal participants in the regulatory mechanism of Bax-mediated apoptosis (6,7). Although there are relatively many reports on TP53 and Bcl-2 immunoreactivity in SCC, the immunopositivity detected markedly varies: from 15% to 92% for TP53 (5,6,8-14) and from 0% to 100% for Bcl-2 (5,6,15-18). Also,

expression of TP53 and Bcl-2 in SCC was only rarely investigated simultaneously (5,6).

Growth hormone receptor (GHR) is a novel proto-oncogene, which was recently detected on cells of various skin lesions (19,20). This finding implicated a role of growth hormone in the development and progression of skin lesions. GHR expression in SCC was investigated by one author only (20). GHR immunopositivity of tumor cells was detected in all seven SCC specimens investigated but it was always weaker than in normal keratinocytes (20).

Two earlier investigations done in our laboratory determined TP53, Bcl-2 and GHR immunopositivity in two most common AK types: hypertrophic (HAK) and atrophic (AAK) (21,22). Current investigation determined immunohistochemically TP53, Bcl-2 and GHR expression in SCC in order to evaluate their role in SCC development and progression.

PATIENTS AND METHODS

We investigated TP53, Bcl-2 and GHR expression in 27 specimens of SCC and adjacent perilesional skin (PS) taken from regularly sun-exposed skin in patients of both sexes older than 60 years of age. Clinical data were obtained from the files of the Ljudevit Jurak University Department of Pathology, Sestre milosrdnice University Hospital, Zagreb, Croatia. Immunohistochemical determination of TP53 and Bcl-2 proteins was performed following the Microwave Streptavidin ImmunoPeroxidase (MSIP) protocol on a DAKO TechMate™ Horizon automated immunostainer, as described previously (7). The presence of GHR was demonstrated by the streptavidin-biotin horseradish peroxidase complex (Strept ABC-HRP) technique, as described before (20,21). Expression of immunohistochemical staining was represented as

percentage of immunoreactive cells per 1000 cells analyzed. The following semiquantitative evaluation and scoring system were used: (-) for no immunoreactive tumor cells; weakly positive (+) for up to 10%; moderately positive (++) for 10% to 25%; and strongly positive (+++) for more than 25% of immunoreactive tumor cells. To estimate the relative importance of the study oncoproteins in SCC, positivity in SCC was compared with the level of positivity in perilesional skin. Statistical analysis was performed by use of χ^2 -test for trend (GraphPad InStat, version 3.05, GraphPad Software, USA). The level of significance was set at $p < 0.05$ in all cases.

RESULTS

Expression of nuclear TP53 and cytoplasmic Bcl-2 and GHR proteins in perilesional skin was uniform: all cases examined stained weakly positive (+) for each marker. Immunopositive keratinocytes were mainly localized in the basal epidermal layer (Figure 1A, 1C and 1E).

The majority of SCC specimens (59%) had moderate to strong (++/+++) TP53 expression (Table 1). In positive specimens most of the atypical epidermal keratinocytes stained positive, while tumor cells in the proximity of keratin pearls remained negative (Figure 1B). The majority (63%) of SCC showed weak (+) Bcl-2 expression in sporadically distributed patches throughout the tumor (Figure 1D). However, Bcl-2 protein was not expressed in one third (9/27) of study SCC specimens (Table 1). Eighteen (67%) SCC specimens showed strong (+++) GHR positivity (Table 1). Immunoreactive keratinocytes were diffusely spread over positive SCC lesions. Well-differentiated tumor cells in the proximity of keratin pearls showed more intense immunopositivity than undifferentiated tumor cells (Figure 1F).

Table 1. Expression of TP53, Bcl-2 and growth hormone receptor (GHR) in squamous cell carcinoma of the skin (N=27)

Immuno-histochemical expression	TP53		Bcl-2		GHR	
	n	%	n	%	n	%
-	3	11	9	33	2	7
+	8	30	17	63	2	7
++	11	41	1	4	5	19
+++	5	18	0	0	18	67
Total positive	24	89	18	67	25	93

-, no positive cells; +, less than 10% of positive cells; ++, 10%-25% of positive cells; +++, more than 25% of positive cells

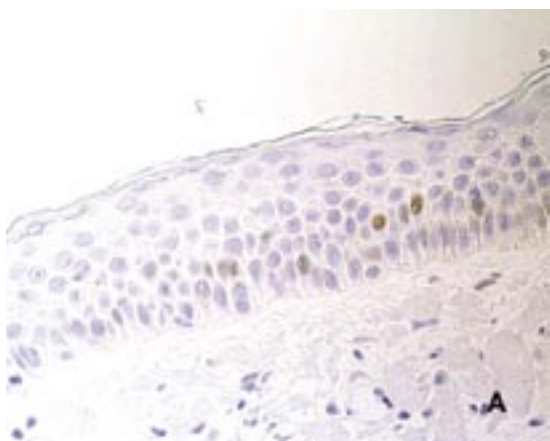


Figure 1A

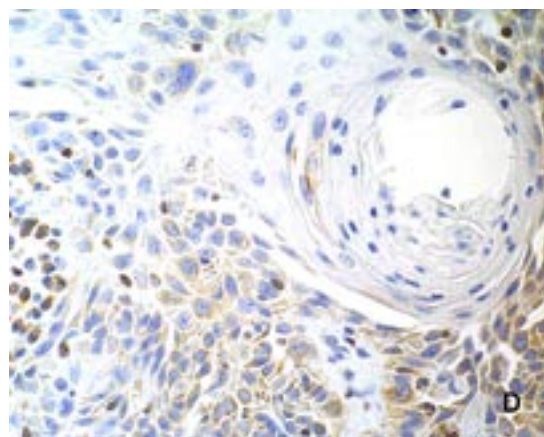


Figure 1D

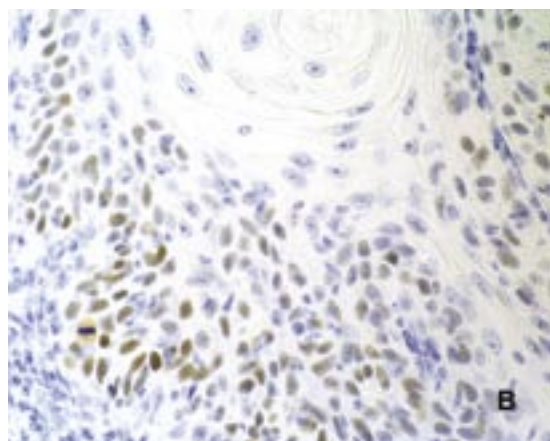


Figure 1B

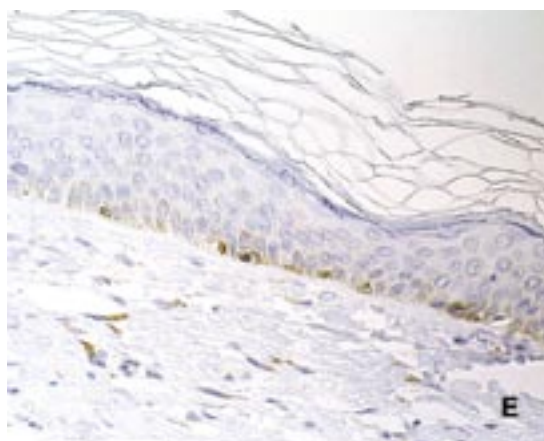


Figure 1E

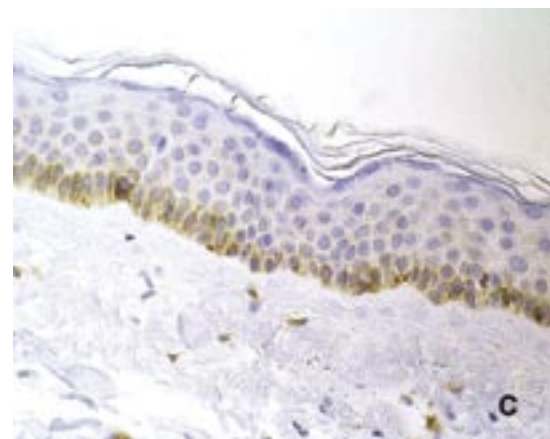


Figure 1C

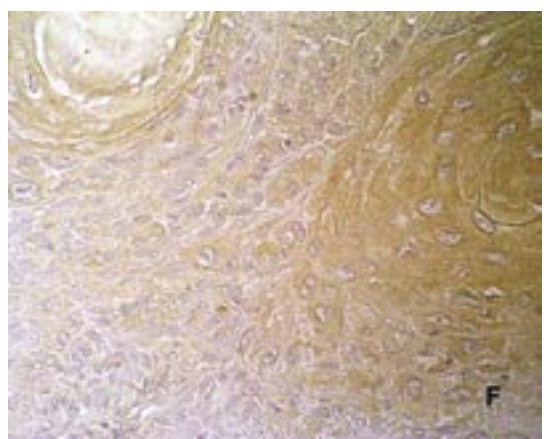


Figure 1F

Figure 1. Representative immunohistochemical staining of perilesional skin (PS) (A) and squamous cell carcinoma (SCC) (B) for TP53 protein (MSIP, x400); PS (C) and SCC (D) for Bcl-2 protein (MSIP, x400); and PS (E) and SCC (F) for growth hormone receptor (GHR) (Strept ABC-HRP, x400).

A significantly increased TP53 and GHR and decreased Bcl-2 positivity was observed in SCC compared with perilesional skin (χ^2 -test, $p < 0.05$).

DISCUSSION

Our study revealed TP53, Bcl-2 and GHR immunoreactivity of the perilesional skin layers and adnexal structures to show a similar pattern as previously reported (5,6,8-22). Recent investiga-

tions of TP53 and Bcl-2 expression in AK as an SCC precursor and SCC have associated their biological behavior with increased cell proliferation rather than protection from apoptosis (5,6).

Twenty-four of 27 (89%) SCC specimens investigated were immunopositive for TP53 protein, which is among the highest reported percentage of SCC lesions expressing TP53 (5,6,8-14). Only Nelson *et al.* (9) detected a higher percentage of TP53 expression: 12 of 13 (92%) SCC investigated. Most studies observed TP53 immunoreactivity in approximately half of SCC samples (10,11,13,14), which is similar to the proportion of SCC specimens showing stronger TP53 immunopositivity than perilesional skin (++) detected in our study, i.e. 59% (16/27).

Antiapoptotic protein Bcl-2 was weakly (+) positive in 67% of SCC specimens investigated, similar to the report by Tucci *et al.* (5). Most of earlier studies failed to detect Bcl-2 immunopositivity in SCC samples investigated (16-18). This difference could be explained by several reasons. Although a small number of specimens and various immunohistochemistry techniques should be mentioned (5,6,15-18), we consider uniform sampling of material (according to tumor grade, lesion location, patient sex and age) most important.

Results of decreased Bcl-2 expression and TP53 overexpression in SCC might indicate a relatively low importance of protection from apoptosis in SCC development and progression. This finding is supported by the work of Rossiter *et al.* (23), who found Bcl-2 overexpression to have a suppressive role in the development and progression of SCC. However, TP53 overexpression might provide explanation for decreased Bcl-2 expression: it indicates *Tp53* mutation, and mutated form of TP53 cannot initiate *bax* transcription (TP53 regulates transcriptionally the quantity of pro-apoptotic protein Bax (24)). Anti-apoptotic protein Bcl-2 interacts with Bax and in this way blocks apoptosis induced by Bax (25). Thus, even decreased Bcl-2 expression can protect cell with mutated *Tp53* from apoptosis. This hypothesis needs to be confirmed by further investigations.

On the other hand, cell proliferation is connected with increased responsiveness to growth factors such as growth hormone. Our finding of GHR immunoreactivity in the majority of SCC specimens investigated (93%), similar to a previous report (20), supports the opinion that GHR is an ubiquitous receptor in proliferative cutaneous lesions (19,20).

Furthermore, our two previous studies detected moderate to strong (++) GHR expression in 8 of 36 (24%) HAK and 8 of 25 (32%) AAK specimens (21,22). As the current study found moderate to strong GHR expression in 23 of 27 (86%) SCC specimens, this might suggest that those AK with increased GHR expression have a higher proliferative potential and may be progressing to SCC. These findings implicate the role of growth hormone and cell proliferation in the development of different kinds of cutaneous precancerous lesions (AK) and neoplasms (SCC).

In conclusion, our results generally agree with the hypothesis that increased cell proliferation has an important role in the biological behavior of SCC. However, the role of protection from apoptosis, especially through detecting Bax immunopositivity, should be further evaluated.

List of abbreviations

AK – actinic keratosis
BSA – bovine serum albumin
DAB – diaminobenzidine
GH – growth hormone
GHR – growth hormone receptor
HAK – hypertrophic type of actinic keratosis
MSIP – microwave streptavidin immunoperoxidase
PBS – phosphate buffered saline
PS – perilesional skin
SCC – squamous cell carcinoma
Strept ABC-HRP – streptavidin-biotin horseradish peroxidase complex

ACKNOWLEDGMENT

The authors would like to thank Mr. Tomislav Beus for his precious technical assistance.

References

1. Salasche SJ. Epidemiology of actinic keratosis and squamous cell carcinoma. *J Am Acad Dermatol* 2000;42:S4-7.
2. Mittelbronn MA, Mullins DL, Ramos-Caro FA, Flowers FP. Frequency of pre-existing actinic keratoses in cutaneous squamous cell carcinoma. *Int J Dermatol* 1998;37:677-81.
3. Lober BA, Lober CW. Actinic keratosis is squamous cell carcinoma. *South Med J* 2000;93:650-5.
4. Cockerell CJ. Histopathology of incipient intraepidermal squamous cell carcinoma ("actinic keratosis"). *J Am Acad Dermatol* 2000;42:S11-7.

5. Tucci MG, Offidani A, Lucarini G, Simonelli L, Amati S, Cellini A, *et al.* Advances in the understanding of malignant transformation of keratinocytes: an immunohistochemical study. *J Eur Acad Dermatol Venereol* 1998;10:118-24.
6. Wikonkal NM, Berg RJ, van Haselen CW, Horkay I, Remenyik E, Begany A, *et al.* Bcl-2 vs p53 protein expression and apoptotic rate in human nonmelanoma skin cancers. *Arch Dermatol* 1997;133:599-602.
7. Ziegler A, Leffell DJ, Kunala S, Sharma HW, Gailani M, Simon JA, *et al.* Sunburn and p53 in the onset of skin cancer. *Nature* 1994;372:773-6.
8. Gusterson BA, Anbazhagan R, Warren W, Midgely C, Lane DP, O'Hare M, *et al.* Expression of p53 in premalignant and malignant squamous epithelium. *Oncogene* 1991;6:1785-9.
9. Nelson MA, Einspahr JG, Alberts DS, Balfour CA, Wymer JA, Welch KL, *et al.* Analysis of the p53 gene in human precancerous actinic keratosis lesions and squamous cell cancers. *Cancer Lett* 1994;85:23-9.
10. Nagano T, Ueda M, Ichihashi M. Expression of p53 protein is an early event in ultraviolet light-induced cutaneous squamous cell carcinogenesis. *Arch Dermatol* 1993;129:1157-61.
11. Onodera H, Nakamura S-I, Sugai T. Cell proliferation and p53 protein expression in cutaneous epithelial neoplasms. *Am J Dermatopathol* 1996;18:580-8.
12. Bito T, Ueda M, Ahmed NU, Nagano T, Ichihashi M. Cyclin D and retinoblastoma gene product expression in actinic keratosis and cutaneous squamous cell carcinoma in relation to p53 expression. *J Cutan Pathol* 1995;22:427-34.
13. McGregor JM, Yu CCW, Dublin EA, Levison DA, MacDonald DM. Aberrant expression of p53 tumour-suppressor protein in non-melanoma skin cancer. *Br J Dermatol* 1992;127:463-9.
14. Stephenson TJ, Royds J, Silcoks PB, Bleehen SS. Mutant p53 oncogene expression in keratoacanthoma and squamous cell carcinoma. *Br J Dermatol* 1992;127:566-70.
15. Nakagawa K, Yamamura K, Maeda S, Ichihashi M. Bcl-2 expression in epidermal keratinocytic diseases. *Cancer* 1994;74:1720-4.
16. Wrone-Smith T, Bergstrom J, Quevedo ME, Reddy V, Gutierrez-Steil C, Nickoloff BJ. Differential expression of cell survival and cell cycle regulatory proteins in cutaneous squamoproliferative lesions. *J Dermatol Sci* 1999;19:53-67.
17. Delehedde M, Cho SH, Sarkiss M, Brisbay S, Davies M, El-Naggar AK, *et al.* Altered expression of bcl-2 family member proteins in nonmelanoma skin cancer. *Cancer* 1999;85:1514-22.
18. Morales-Ducret CR, van de Rijn M, LeBrun DP, Smoller BR. Bcl-2 expression in primary malignancies of the skin. *Arch Dermatol* 1995;131:909-12.
19. Lincoln DT, Sinowatz F, Temmim-Baker L, Baker HI, Kölle S, Waters MJ. Growth hormone receptor expression in the nucleus and cytoplasm of normal and neoplastic cells. *Histochem Cell Biol* 1998;109:141-59.
20. Ginarte M, García-Cabarello T, Fernández-Redondo V, Beiras A, Toribio J. Expression of growth hormone receptor in benign and malignant cutaneous proliferative entities. *J Cutan Pathol* 2000;27:276-82.
21. Stanimirović A, Čupić H, Bošnjak B, Krušlin B, Belicza M. Expression of p53, bcl-2 and growth hormone receptor in actinic keratosis, hypertrophic type. *Arch Dermatol Res* 2003;295:102-8.
22. Stanimirović A, Čupić H, Bošnjak B, Tomas D, Baličević D, Krušlin B, *et al.* Expression of p53, bcl-2 and growth hormone receptor in atrophic type of actinic keratosis. *J Dermatol Sci* 2004;34:49-53.
23. Rossiter H, Beissert S, Mayer C, Schon MP, Wienrich BG, Tschachler E, *et al.* Targeted expression of bcl-2 to murine basal epidermal keratinocytes results in paradoxical retardation of ultraviolet- and chemical-induced tumorigenesis. *Cancer Res* 2001;61:3619-29.
24. Miyashita T, Reed JC. Tumor suppressor p53 is a direct transcriptional activator of the human bax gene. *Cell* 1995;80:293-9.
25. Chao DT, Korsmeyer SJ. BCL-2 family: regulators of cell death. *Annu Rev Immunol* 1998;16:395-419.