

Physiologic Alterations of Oral Mucosa due to Aging: A Review

Maria Cristina Ribeiro de Castro, Marcia Ramos-e-Silva

Postgraduate Course in Dermatology, Section of Dermatology, University Hospital (HUCFF/UFRJ) and School of Medicine, Federal University of Rio de Janeiro, Rio de Janeiro, Brazil

Corresponding author:

Maria Cristina Ribeiro de Castro, MD, MS
Section of Dermatology
University Hospital and School of Medicine
Federal University of Rio de Janeiro
Rua Sorocaba, 464/205
22271-110 Rio de Janeiro
Brazil
ramos.e.silva@dermato.med.br

Received: January 10, 2005.

Accepted: March 10, 2005.

SUMMARY The Brazilian population, despite Brazil being considered a “country of young people”, is undergoing an aging process entailed by a decline in the fertility and mortality rates. In the year 2000, seniors accounted for about 5.85% of the Brazilian, and population projections for 2025 estimate that the group will reach 14% by that time. Oral mucosa has a function of providing a barrier and promoting immune and inflammatory responses, thus protecting the body. During the aging process, those functions deteriorate, allowing the action of predisposing agents. There is thus the need of better knowledge of the conditions of oral health in the Brazilian population, allowing for adoption of preventive measures. Oral cavity examination should be routinely performed in the elderly on a yearly basis, as a preventive measure which would reduce the morbidity and mortality in this population.

KEY WORDS elderly, mouth, oral mucosa, oral health, geriatric stomatology

INTRODUCTION

In 100 B.C. in ancient Rome, the average lifespan was only 23 years, in 1750 in Sweden adults reached an average of 35 years, in 1900 Americans lived up to 47 years, in the 1970s in England the average life expectancy was 74 years, whereas at the end of the century in Europe it was estimated to 85 years. The growing longevity of the population is a consequence of progress in science and medicine technology that have improved the quality of life and favored this development over centuries (1).

Brazil, considered before a “country of young people”, undergoes a rapid and progressive aging process of its population, caused by a decline in the mortality and fertility rates (2-6). In the south

and southeast of Brazil, life expectancy is already ranging between 68 and 72 years (1). In 1980, approximately 6.3% of the Brazilian population were aged 60 or above 60 years (3). According to a survey conducted by the Brazilian Geography and Statistics Institute (IBGE), the Brazilian population is rapidly expanding: in 1980 it totalled 119,002,706. According to the 2000 census, Brazil counted 169,799,170 people, and of these, in absolute figures, 9,935,100, i.e. 5.85% of the total population, were aged 65 or above (Fig. 1) (6).

Projections by the Latin Demography Center estimate that this group will grow to 14% by 2025 (3). The expectation is that already in 2005, Brazil will have the sixth largest contingent of old people in the world (4).

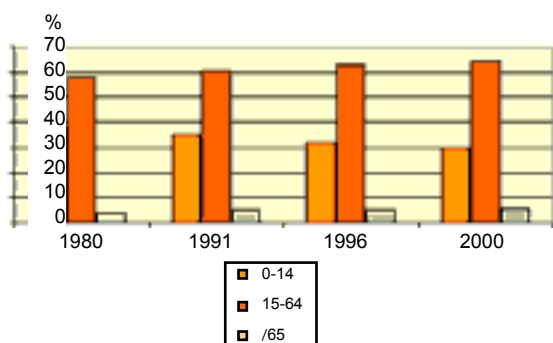


Figure 1. Population distribution according to groups, 1980-2000 (source: IBGE).

The more advanced a population's age, the greater the prevalence of lesions in oral mucosa. According to some authors, there is a 47% rise between different age groups (7,8). Oral mucosa is able to hinder the entrance of noxious and infectious material, to respond to damages to its integrity, and to promote an adequate immune and inflammatory response, in this way protecting the body (9). The elderly present a clinically normal oral mucosa, and aging is nothing more than a progressive cell degeneration (1) resulting mainly in retarded cell division, with a reduction of the cell growth capacity, thereby leading to a reduced tissue repair (10). Consequently the mucosa becomes more exposed (1,3,10,11), and besides aging, other general predisposing factors are added, such as inadequate food, use of alcohol, coffee and tobacco, medications, toxic substances, dental prosthetics, chronic diseases, nutritional privation, etc., that substantially aggravate alterations in the oral cavity (1).

CHARACTERISTICS OF ORAL CAVITY AGING

Oral mucosa

In the elderly, the mucosa of the oral cavity presents a shiny and waxy aspect, due to its epithelium being thinner, atrophic, with keratinization and reduced elasticity, and therefore more friable (10,12). The reduction of cardiac and respiratory functions, in addition to other alterations in the body, impair the overall metabolism, resulting in a reduced blood supply to the tissues, compromising even more cell regeneration and delaying the healing process. The reduced blood influx also leads to cell atrophy, reducing their hydrous content, and in this way the tissues gradually lose elasticity and undergo fatty infiltration (10). Then, oral mucosa becomes more susceptible to external stimuli, and consequently the number of small ulcers from repetitive trauma increases, often

imperceptibly, caused by too hot or excessively seasoned food, poorly adapted dental prosthetics, and iatrogenic consequences (10,12). Prosthetic devices can also cause development of keratosis, seen with relative frequency, resulting from low intensity irritation, or still surfacing in certain areas of ulcers surrounded by a keratotic area, and in others by slight intensification of tissue keratinization (10).

Gingiva

There is gingival retraction, mainly in the area around dental roots, due to apical migration of the cells caused by alterations proper of the aging process. This increases the incidence of periodontal diseases. This withdrawal varies individually, being dependent on genetic, external, local and systemic factors (10,12).

Tongue

It presents several changes. It loses its muscular tonus, without reducing in size. However, should the elderly lose his/her teeth, the tongue will expand, filling out the space formerly occupied by the teeth. The elderly may have a reduction in taste perception by up to 80%, mainly associated with sweet, salty, bitter and acid substances (13). The papillae are reduced, both in number and in size. At age 20, there are around 252 taste corpuscles in a papilla. After age 75, this number drops normally to 88 corpuscles, leading to partial loss of taste function, in addition to other changes of appetite in the elderly (12,13). There is also hypertrophy of the foliated papillae located bilaterally in the back third of the tongue borders, entailed by hypertrophy of the lymphoid tissue that makes up these anatomic structures (13).

Extremely common in seniors is the onset of varicosities on the tongue, which are dilations of the diameter and increase in the number of vessels of the venous system. Their appearance is due to the loss of support by the tissues, secondary to degeneration of elastic fibers. They are characterized clinically by small dots and/or reddish-purple areas, distributed mainly in the ventral area of the tongue in about 40%-50% of the seniors, and can also extend to the sides of the tongue, floor of the mouth, and other locations (12-14).

The tongue as a whole presents a smoother appearance with atrophy of the filiform and fungiform papillae, associated or not to a complaint of local discomfort. The differential diagnosis is important and varies from simple atrophy from the aging process to some disease or use of associated medication, e.g., diabetes, anemia or hypovitaminosis (13).

Lips

They become very dry, wrinkled and sometimes present fissures in the external mouth corners. These symptoms can be more or less pronounced, depending on the individual's exposure to environmental agents such as solar radiation, temperature extremes, etc. (12).

Saliva

It becomes thicker and more viscous, due to the relative increase of mucin in its content, and its pH becomes more neutral or even alkaline, thus additionally facilitating the colonization by undesirable microorganisms (11,12). Saliva has the function to lubricate and protect the mucous membrane, prepare food for mastication and deglutition, facilitate the swallowing process, preserve mouth flora, and aid in the production of speech.

Besides lubricating the soft tissues of the oral cavity, and if not averting, at least minimizing gingivitis and other alterations derived from ongoing and chronic friction, saliva contains important enzymes and substances that prevent oropharyngeal infections, especially by Gram-negative bacteria (15-17). In the elderly, all these functions become impaired to some extent.

In contrast to previous beliefs, studies show that the volume of saliva produced by the elderly is not significantly altered, from which we conclude that the major factor responsible for "dry mouth" are medications rather than aging (18).

Immune system

There is a compromising role of this system, as a greater incidence of local infections is recorded in the oral cavity (10,11). This is due to different factors, e.g., a decrease in the salivary levels of IgG, IgA and IgM antibodies; decrease in the total number of T cells due to the loss of interleukin 2 (IL-2) effectiveness; decrease in B cell response to activated T cell stimulus; reduction of the macrophage capacity to produce intercellular signaling substances, etc. (11).

Fordyce's granules

There is a quantitative increase of these structures that actually are sebaceous glands found in the buccal cavity. They are characterized clinically by several yellowish papules, placed in general in the jugal area bilaterally and in the vermilion of the lip(13).

ASSOCIATIONS WITH ORAL CAVITY AGING

Osteoporosis

If severe, osteoporosis can lead to total reabsorption of alveolar processes and even of part of the jaw and maxillary bone (10). The loss of teeth leads to a decrease in the tonus of facial musculature, which in turn causes variable degrees of temporomandibular articulation subluxation. This makes the elderly adopt positions that hinder closing of the mouth, or they produce signs of arthritis (10-12). All these alterations cause facial deformity affecting speech, deglutition and mastication, thus compromising the whole digestive process (10).

Nutritional deficiency

It is important to emphasize that the initial clinical picture of a nutritional deficiency can be very similar to that of aging. The elderly present several physiologic manifestations consistent with the age which, on dermatologic examination, resemble nutritional disturbances: fragile, brittle and onychodystrophic nails, xerosis, loss of skin turgor and elasticity, atrophy of mucous membranes, thinning of the hair and senile alopecia (including the pubic and axillary forms) (19).

A comprehensive study to establish indicators of nutritional deficiency, which also included individuals aged ≥ 60 , was performed in the United States in 1971-1972 (20). The main oral clinical manifestations due to vitamin deficiency are listed in Table 1 (19).

Table 1. Clinical manifestations in oral cavity caused by vitamin deficiency

Deficiency or lack of	Oral clinical manifestation
Niacin (vitamin B ₃)	Papillary filiform atrophy, angular stomatitis, cheilosis, tongue fissures and oral erosions
Vitamin C	Edematous and friable gum
Hydroxocobalamin (vitamin B ₁₂)	Hyperchromic macules on oral mucosa and increased tongue volume
Biotin (vitamin H)	Periorificial dermatitis
Riboflavin (vitamin B ₂)	Angular stomatitis, cheilosis, glossitis magenta
Pyridoxine (vitamin B ₆)	Glossitis, oral erosions, angular stomatitis and cheilosis
Zinc	Angular stomatitis, glossitis and periorificial dermatitis

A vicious circle is then created: alterations caused by malnutrition are worsened by the diseases and characteristics of aging itself, which in turn brings difficulties on eating (lack of teeth, use of prostheses, lack of autonomy) and appropriate absorption of nutrients (diseases of the gastrointestinal tract).

Medications

In addition to the alterations described above, some medications frequently used by seniors such as aspirin, digoxin, diuretics, non-hormonal anti-inflammatory drugs, H₂ antihistamines and antibiotics like tetracyclines, cephalosporins and trimethoprim, can interfere with the absorption and metabolism of nutrients (19), whereas others like digoxin and captopril reduce appetite, thus additionally worsening the nutritional state (21).

The elderly have a high prevalence of chronic and degenerative diseases, forcing them to an ongoing use of several drugs (17). The total number of lesions in oral mucosa are directly related to the number of medications taken on a daily basis (3,8). In recent years there has been a considerable increase in the amount of prescriptions. A study conducted in 1994 by Smith and Burtner (22) reports a 36% increase in the number of prescriptions per capita in the U.S. from 1970 till 1990. According to Pyle and Tolbert (23), four out of five geriatric patients take one or more medications *per day* on an average, with patients aged >65 accounting for one third of all prescriptions in the U.S. It is expected that in 2030, this proportion will reach 40%. This phenomenon is explained firstly by the increase in life expectancy, and secondly because a part of these seniors need daily and frequent medication to keep alive and healthy, due to the high prevalence of chronic pathologies such as cardiovascular diseases, diabetes, arthritis, etc. (17, 22-24).

Therapeutic management of senior population in nursing homes usually includes continuous administration of a great number of medications, since most suffer from chronic diseases and require higher care (15). This multi-medication results in a greater number of side effects and problems associated with the fact that an elderly patient has a reduced hepatic and renal mass, with consequential impairment of the pharmacokinetics and metabolite pharmacodynamics (3,17). Furthermore, there is a reduction of body fluids by about 17% and a decrease of muscular mass that is increasingly replaced by fat in some 35% of the elderly. In this way, liposoluble substances tend to

concentrate in adipose tissue and, consequently, present a lingering action that does not occur with hydrosoluble substances, which concentrate in the blood and have an increased activity (3). All these alterations in the absorption, distribution, biotransformation and excretion of medications increase the risk of drug interactions, toxicity and inefficacy, leading to increment of one or more drugs and other secondary problems (17).

Xerostomia is the most common side effect of the use of such large amounts of medicines. More than 400 drugs of different categories result in some degree of hyposalivation (16,17,25,26). Other frequent side effects are dysgeusia (loss or alteration of taste), stomatitis, which can vary from lichenoid eruption to drugs to erythema multiforme, glossitis, coated tongue, sialorrhea, gingivitis, ulcers, gingival hyperplasia, increased rate of associated infections such as candidiasis, and stomatitis (17,22,25).

CONCLUSION

Due to the great expansion of this age group with such peculiar characteristics, it is essential that the dermatologist knows the specific physiologic transformations of aging in the oral cavity. In this way, he/she will be able to notice and differentiate them, to make correct diagnosis and take the necessary preventive measures to avoid, or at least minimize, the alterations entailed by aging. The dermatologist should always be alert to the number of medications used by the elderly, a group which generally use a great number of drugs, sometimes for more than 20 years, leading to the highest incidence of iatrogenic effects and pharmacodermias.

References

1. Kina S, Conrado CA, Brenner AJ, Kurihara E. O ensino da estomatogeriatria no Brasil: A experiência de Maringá. Rev Odontol Univ São Paulo 1996;10:69-73.
2. Marino R. Oral health of the elderly: reality, myth, and perspective. Bull Pan Am Health Organ 1994;28:202-10.
3. Frare SM, Limas PA, Albarello FJ, Pedot G, Régio RA. Terceira idade: quais os problemas bucais existentes? Rev Assoc Paul Cir Dent 1997;51:573-6.
4. Saliba CA, Saliba NA, Marcelino G, Moimaz SA. Saúde bucal dos idosos: uma realidade ig-

- norada. Rev Assoc Paul Cir Dent 1999;53:279-82.
5. Colussi CF, Freitas SF. Aspectos epidemiológicos da saúde bucal do idoso no Brasil. Cad Saude Publica 2002;18:1313-20.
 6. Brasil em síntese. http://www.1.ibge.gov.br/brasil_em_sintese/default.htm 10/7/2004.
 7. Scott J, Cheah SB. The prevalence of oral mucosal lesions in the elderly in a surgical biopsy population: a retrospective analysis of 4042 cases. Gerodontology 1989;8:73-8.
 8. Nevalainen MJ, Narhi TO, Ainamo A. Oral mucosal lesions and oral hygiene habits in the home-living elderly. J Oral Rehabil 1997;24:332-7.
 9. Ettinger RL. The unique oral health needs of an aging population. Dent Clin North Am 1997;41:633-49.
 10. Pucca Junior GA. Saúde bucal do idoso: aspectos sociais e preventivos. In: Netto, MP. Gerontologia: a velhice e o envelhecimento em visão globalizada. São Paulo: Atheneu;1996. p.297-310.
 11. Berg R, Morgenstern NE. Physiologic changes in the elderly. Dent Clin North Am 1997;41:651-68.
 12. Kaplan H. The oral cavity in geriatrics. Geriatrics 1971;26:96-102.
 13. Figueiredo MA, Cherubini K, Yurgel LS, Lorandi CS. Alterações fisiológicas freqüentemente presentes na cavidade bucal do paciente idoso. Odontol Mod 1993;20:33-4.
 14. Seoane Leston JM, Aguado Santos A, Varela-Centelles PI, Vazquez Garcia J, Romero MA, Pias Villamor L. Oral mucosa: variations from normalcy, Part II. Cutis 2002;69:131-4.
 15. Handelman SL, Baric JM, Espeland MA, Berglund KL. Prevalence of drugs causing hyposalivation in an institutionalized geriatric population. Oral Surg Oral Med Oral Pathol 1986;62:26-31.
 16. Pyle MA, Terezhalmay GT. Oral disease in the geriatric patient: the physician's role. Cleve Clin J Med 1995;62:218-26.
 17. Paunovich ED, Sadowsky JM, Carter P. The most frequently prescribed medications in the elderly and their impact on dental treatment. Dent Clin North Am 1997;41:699-726.
 18. Erickson L. Oral health promotion and prevention for older adults. Dent Clin North Am 1997;41:727-50.
 19. Gaspar NK, Campbell G, Pinto JM, Trindade P, Meireles VM, Addor FA, et al. Manifestações cutâneas em deficiências nutricionais. An Bras Dermatol 1996;71(2 Suppl 2):43-7.
 20. Lowenstein FW. Preliminary clinical and anthropometric findings from the first Health and Nutrition Examination Survey, USA, 1971-1972. Am J Clin Nutr 1976;29:918-27.
 21. Saunders MJ. Nutrition and oral health in the elderly. Dent Clin North Am 1997;41:681-98.
 22. Smith RG, Burtner AP. Oral side-effects of the most frequently prescribed drugs. Spec Care Dentist 1994;14:96-102.
 23. Pyle M, Tolbert S. Pharmacologic considerations in geriatric dentistry. Dent Clin North Am 1994;38:755-67.
 24. Pyle M, Faddoul F, Terezhalmay G. Clinical implications of drugs taken by our patients. Dent Clin North Am 1993;37:73-90.
 25. Matthews TG. Medication side effects of dental interest. J Prosthet Dent 1990;64:219-26.
 26. Fox PC. Management of dry mouth. Dent Clin North Am 1997;41:863-75.