

Primary Anetoderma Associated with Antiphospholipid Antibodies and Micromorphologic Vascular Lesions: Case Report and Literature Review

Jaka Radoš, Ivan Dobrić, Daniela Ledić Drvar, Davorin Lončarić

University Department of Dermatology and Venereology, Zagreb University Hospital Center, Zagreb, Croatia

Corresponding author:

Jaka Radoš, MD, MS
University Department of Dermatology and
Venereology
Zagreb University Hospital Center
Šalata 4
HR-10000 Zagreb
Croatia
radosm@mef.hr

SUMMARY A 40-year-old male patient with primary anetoderma is presented in whom antiphospholipid antibodies were detected while not fulfilling diagnostic criteria for antiphospholipid syndrome. The possible pathogenic role of antiphospholipid antibodies in the disease development is postulated.

KEY WORDS anetoderma, antiphospholipid antibodies, antiphospholipid syndrome

Received: February 10, 2005.

Accepted: March 10, 2005.

INTRODUCTION

The term anetoderma has been derived from the Greek words *anetos* meaning slack and *derma* meaning skin. The term was introduced in 1891 by Jadassohn to describe a rare elastolytic disorder characterized by limited areas of slack skin associated with dermis reduction, determined by palpation, while the loss of elastic tissue is demonstrated by histopathology (1). There are two forms of anetoderma, idiopathic and secondary type. Idiopathic or primary anetoderma occurs in clinically intact skin and is not preceded by any specific dermatosis (2,3). Secondary anetoderma develops at sites previously affected by well defined dis-

eases of inflammatory (4-7) or tumorous genesis (8-11). Now the clinical classification of primary anetoderma into inflammatory (Jadassohn-Pellizzari) and noninflammatory (Schweninger-Buzzi) is exclusively of historical relevance because the two types of the disease may coexist in the same patient. Histologically, the two types of the disease are almost identical. Furthermore, inflammatory infiltration is present in both types of the disease, and clinical presence or absence of inflammation at the disease onset has no prognostic value (1,12). Rare familial cases of the disease (13,14) and its occurrence in premature infants (15,16) have also been described.

The cause of primary anetoderma has not yet been clearly identified, however, the role of immune mechanisms in the occurrence of elastolysis and primary anetoderma has been increasingly implicated.

The aim of this report is to point to the possible etiopathogenetic role of antiphospholipid antibodies in the development of anetoderma.

CASE REPORT

Our patient was a 40-year-old man, a Romany, with 9-year history of asymptomatic atrophic skin lesions gradually increasing in number. The diagnosis of anetoderma had been made by biopsy 4 years before, however, the patient received no therapy. There was no family history of similar skin lesions. The patient had no serious diseases in his personal medical history, except for chickenpox and infectious jaundice in childhood. There were no data on thrombotic events. During hospitalization, the patient complained of vertigo and hyperhidrosis. Physical examination was unremarkable.

Nine oval or round, slack, outpouching, elevated foci with positive herniation phenomenon, finely wrinkled surface, up to 6 cm in diameter were observed on the skin of the trunk and upper arms (Fig. 1, Figs. 2 a and b). Eight foci were flesh-colored, while only one focus was erythematous and mildly elevated (Fig. 3). Other skin and mucosal areas showed no alterations.

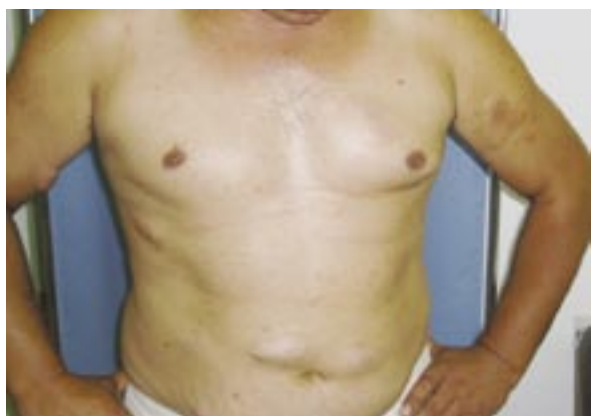

Figure 1. Atrophic foci on the skin of the trunk and upper arms.

Erythrocyte sedimentation rate (ESR), red, white and differential blood counts (RBC, WBC and DBC); routine biochemistry tests; electrophoresis and immunoelectrophoresis; ANF, ADNA; anti Ro, anti La; total complement, complement C3 and C4 fractions; PTT, APTT; fibrinogen; hepatitis markers; anti HIV1 and anti HIV2; VDRL, TPHA, PPD test, ACE; T3, T4, TSH; ECG; EEG; cervical spine

Figure 2a.

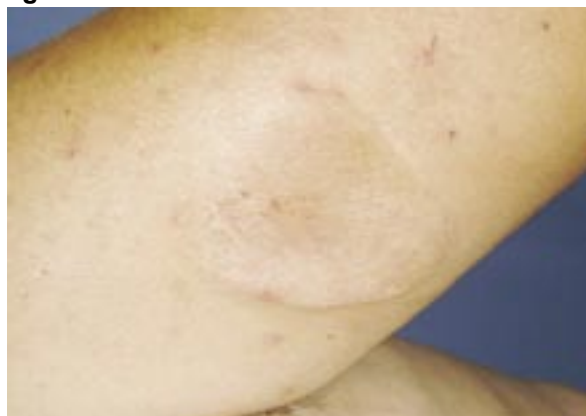
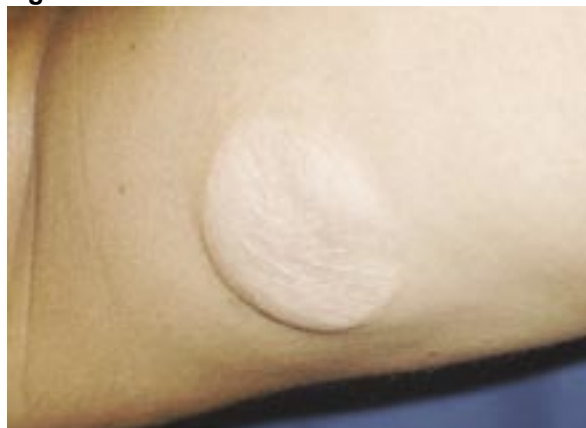
Figure 2b.



Figures 2 a and b. Flesh colored, outpouching, atrophic foci (a), with finely wrinkled surface (b).

x-ray, heart and lung x-ray; abdominal ultrasonography; Doppler ultrasonography of lower extremity circulation; ophthalmologic and neurologic examinations; and direct immunofluorescence in the affected skin were negative or within the normal limits.

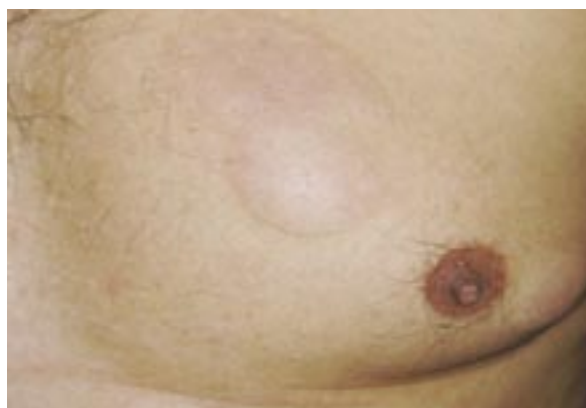

Figure 3. Erythematous and slightly elevated focus on the left side of the chest that appeared recently.

The following findings were borderline positive or pathologic: titer of IgG antibodies to *Borrelia burgdorferi* (indirect immunofluorescence) and level of circulating immunocomplexes. Thrombocytopenia was present (Plt: 103, 113, n 158-424). Flow cytometry indicated mild to moderate serum reactivity with healthy donor platelets, indicating unbound platelet reactive antibodies (that may have corresponded to antiphospholipid antibodies); no bound antiplatelet IgG antibodies were detected. Positive anticardiolipin antibodies (aCL) and lupus anticoagulant (LAC) were found on two occasions 7 weeks apart; aCL antibodies were determined by ELISA: aCL-IgM 41, 45 MPL U/ml (high positive value >30) and aCL-IgG 23, 30 GPL U/ml (moderate positive value 20-40). LAC was determined by use of coagulation tests, diluted Russel's viper venom time (dRVVT), activated partial thromboplastin time (aPTT) and kaolin clotting time (KCT).

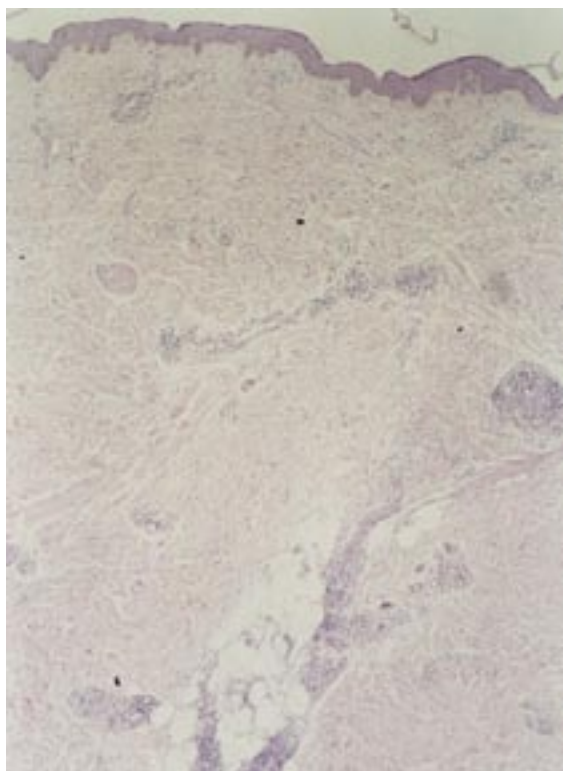


Figure 4. Scanty, perivascular lymphocytic infiltrate in the dermis (H&E, original magnification x25).

Histopathologic examination of the atrophic focus (upon excision biopsy performed by a plastic surgeon) revealed scanty perivascular lymphocytic infiltrate (Fig. 4) and almost complete intradermal loss or fragmentation of elastic fiber (Fig. 5). On serial section of a paraffin block containing



Figure 5. Almost complete intradermal loss, or fragmentation of elastic fiber (Orcein, original magnification x25).

a skin specimen obtained by initial biopsy 4 years before, inflammatory infiltrates located in vascular walls and perivascularly, along with endothelial lesion and vein discontinuation along cutaneous-subcutaneous border were observed (Figs. 6 a and b). There were no intraluminal microthrombi.

Based on the clinical picture, laboratory findings and skin histopathology, the diagnosis of primary anetoderma with coexisting thrombocytopenia and antiphospholipid antibodies was made. The patient had no other classification criteria for antiphospholipid syndrome.

The patient was administered azithromycin for 5 days as follows: day 1, 2x1 500 mg capsule, then 1x1 500 mg capsule/day for the next 4 days. Antiaggregation therapy with acetylsalicylic acid (Andol®) at a dose of 100 mg/day was introduced as a thrombotic event prophylaxis.

On control examination two new, round foci, 2 cm in diameter, were observed on the trunk. The patient was recommended continuous monitoring and control internal-medicine examinations for positive antiphospholipid antibodies and potential development of thrombosis.

Figure 6a.

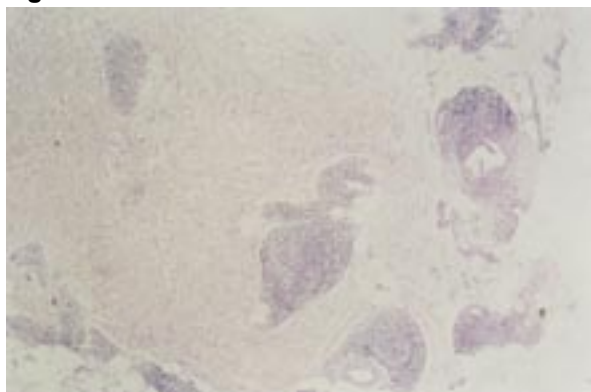
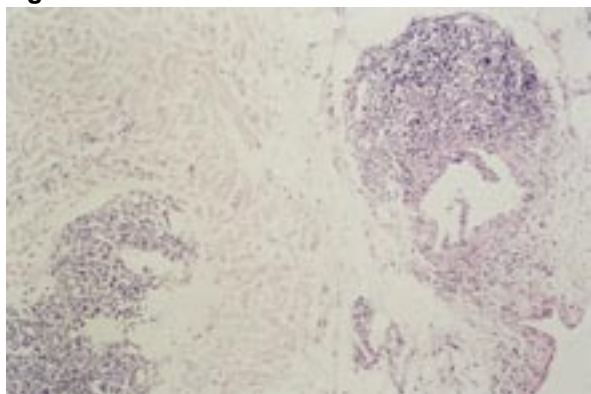


Figure 6b.



Figures 6a and b. Inflammatory lymphocyte infiltrates in vascular walls and perivascularly (H&E, original magnification x25) (a), and endothelial lesion of a vein with endothelial discontinuation (H&E, original magnification x50)

DISCUSSION

To date, several hundred patients with anetoderma have been described in the world (1). The pathogenesis of the disease remains unknown. Almost identical pathogenetic mechanisms have been postulated for primary and secondary anetoderma, both forms being predominated by the loss of dermal elastin that may be due to its increased destruction or decreased synthesis (1). A congenital elastin defect has been postulated in familial cases of the disorder (13). Many theories, especially those on secondary anetoderma following inflammation, try to explain the mechanism of anetoderma development by an increased destruction of elastic fiber, i.e. by an enhanced release of elastases and cytokines such as IL-6 from inflammatory cells; increased procollagenase A and B synthesis; or elastic fiber phagocytosis by macrophages (4-7). It should be noted that an impaired balance between metalloproteinases and their tissue inhibitors has been demonstrated in affected skin samples (17). Skin hypoxia may act as a trig-

ger for this balance impairment (18). Ischemic process has also been implicated as a possible cause of anetoderma in premature infants at the sites of skin contact with leads for ECG or EEG (15).

As clinical or laboratory signs of autoimmunity are quite commonly observed in patients with anetoderma, the association between anetoderma and immune mechanisms has been investigated with increased frequency, especially since 1990. So, patients with anetoderma have been observed to frequently show positive direct immunofluorescence in the affected skin in the form of linear or granular immunoglobulin and/or complement deposits along the dermoepidermal junction, and occasionally also perivascularly (19).

Anetoderma has also been described in association with various autoimmune disorders, e.g., discoid lupus erythematosus, systemic lupus erythematosus, alopecia areata, vitiligo, Hashimoto's thyroiditis, Graves' disease, Addison's disease, and systemic sclerosis (19). Yet, systemic lupus erythematosus, discoid lupus erythematosus and lupus profundus are autoimmune disorders that have been most commonly associated with anetoderma.

Anetoderma association with various antibodies has also been reported (20). The antibodies most commonly associated with anetoderma are positive ANF, false positive classic serologic reaction to syphilis or *Borrelia burgdorferi*, and antiphospholipid antibodies. Some antibodies are rarely detected, such as antibodies to proliferating cell nuclear antigen (anti-PCNA) (21), whereas others such as anticardiolipin IgA antibodies have not yet been routinely introduced in practice. The association of positive antiphospholipid antibodies and anetoderma has been investigated. To date more than 20 primary anetoderma patients have been described in whom antiphospholipid antibodies (LAC and/or aCL) and/or antibody to β_2 -glycoprotein I ($\alpha\beta_2$ -GpI) were demonstrated as an isolated laboratory finding, or as part of the antiphospholipid syndrome, or in relation to some other clinical and/or laboratory signs of autoimmunity (21-24). Anetoderma was also recorded during the course of HIV infection (25). Lindstrom *et al.* found a correlation between elevated aCL titer and occurrence of anetoderma, usually secondary, in HIV positive patients (26).

For the matter of convenience, here is an overview of the antiphospholipid syndrome features. Antiphospholipid syndrome is an acquired multi-system coagulation disorder that may occur as a primary or secondary type. Primary antiphospho-

lipid syndrome is more common and is diagnosed in patients with antiphospholipid antibodies and thrombosis, without associated comorbidity. Secondary antiphospholipid syndrome is associated with a broad array of diseases including systemic lupus erythematosus and other autoimmune diseases. The diagnosis of antiphospholipid syndrome is based on the presence of any of the following major criteria: arterial thrombosis, venous thrombosis, habitual abortion, and thrombocytopenia (as an accessory sign), along with the presence of LAC and aCL. Cutaneous manifestations include livedo reticularis, necrotizing vasculitis, livedoid vasculitis, thrombophlebitis, erythematous maculae and purpura (27), and very rarely described anetoderma (28).

In these patients, laboratory workup should include all biochemistry tests available for detection of antiphospholipid antibodies (LAC, all aCL isotypes, a β_2 -Gpl). Anticardiolipin IgA antibodies, anti β_2 -Gpl antibodies, and antibodies to phosphatidyl serine, prothrombin, annexin V, protein C and protein S have not yet been included among recognized criteria for verification of the disease (27). In some patient subgroups only positive lupus anticoagulant with negative anticardiolipin antibodies or negative anti β_2 -Gpl antibodies can be demonstrated, whereas others may show only positive anticardiolipin antibodies with negative lupus anticoagulant. Also, there are patients with positive LAC and aCL findings. Therefore, when antiphospholipid syndrome is considered on differential diagnosis, it does not appear acceptable to determine only one type of antibodies (27). The exact mechanism of thrombophilic state induction by antiphospholipid antibodies remains to be clarified (27,29). The antibodies may react with platelets, whereafter they release their cellular constituents to form a clot. Also, the antibodies may bind to the endothelial cell surface, thus rendering the otherwise nonreactive endothelial cell surface reactive to circulating blood constituents to form a clot. In normal conditions, hexagonal phospholipids of endothelial cells are bound via β_2 -Gpl prothrombin, a phospholipid binding protein, thus rendering endothelial cells nonreactive. However, in antiphospholipid syndrome, the normal phospholipid binding protein (β_2 -Gpl prothrombin) cannot bind to endothelial cell because the site has been occupied by the phospholipid antibody or its plasma level has been reduced (27).

As for the role of antiphospholipid syndrome in the pathophysiology of anetoderma, some authors have postulated that dermal vessel microthrom-

boses lead to focal ischemia, followed by dermal elastic fiber destruction (23). This hypothesis has been supported by the finding of microthrombi described in skin biopsy specimens of patients with primary anetoderma associated with antiphospholipid antibodies (30).

As differentiated from other cutaneous manifestations of antiphospholipid syndrome, primary anetoderma need not necessarily develop as a sequel of microthrombosis, because the finding of microthrombi is quite infrequently recorded in serial sections of skin biopsy specimens. Also, the time of the occurrence of microthrombus cannot be definitely determined, i.e. whether it has occurred in-between the onset of lesion and biopsy. The exact duration of lesions may occasionally be difficult to assess because some patients fail to observe skin alterations and it is the clinician who warns them of the lesions. Neither can the possible existence of skin alterations for months or even years be excluded, when the lesions are too old to demonstrate the presence of microthrombi. Yet, the existence of ischemic process has recently been emphasized (18). Alternatively, apart from microthrombosis and ischemia, antiphospholipid antibodies may also react with elastic fiber *via* an immune process. The existence has been postulated of an epitope common to elastic fiber and membrane phospholipids to serve as a binding site for autoantibodies, with resultant immune reaction upon binding (23).

There is no efficient treatment for anetoderma. While attempts have been made with topical/intralesional corticosteroid therapy, penicillin G, salicylates, phenytoin, dapsone and vitamin E, none of these therapies has proved efficient (2).

CONCLUSION

Based on the reports on patients in whom anetoderma preceded the occurrence of thrombotic event even by 20 years, we believe that all patients with anetoderma should undergo thorough testing for prothrombotic abnormalities, especially antiphospholipid antibodies, using all tests available. There is no consensus on thrombosis prophylaxis in patients with a high titer of antiphospholipid antibodies but without thrombotic events in their history (27,31). Many authors do not support the prophylactic use of antiaggregation therapy (27). Even if we are inclined to believe that the prophylaxis of deep venous thrombosis and pulmonary embolism with regular doses of acetylsalicylic acid (aspirin 325) is inefficient (27,32), regular control


checkups are needed, along with warning the patient that such an event may occur.

A finding of vasculitis with single vein endothelial damage detected in histologic slide may be considered as evidence for the pathogenetic role of antiphospholipid antibodies in inducing dermal microinfarcts and ischemia, which would in turn lead to elastic fiber destruction. Like other authors (22), we believe that anetoderma should be included in the group of skin disorders in antiphospholipid syndrome.

References

1. Maari C, Powell J. Atrophies of connective tissue. In: Bologna JL, Jorizzo JL, Rapini RP, editors. *Dermatology*. Edinburgh, London: Mosby; 2003. p.1540-2.
2. Benest L, Kwark E, Goldwasser J, Dantzig P, Weinberg JM, Davis I. Primary anetoderma. *Cutis* 2000;65:188-90.
3. Ponnighaus JM, Jaeger G, Baum HP. Anetodermie Schweninger-Buzzi auf dunkler Haut. *Hautarzt* 2001;52:950-1.
4. Özkan S, Fetil E, İzler F, Pabucçuoğlu U, Yalçın N, Güneş AT. Anetoderma secondary to generalized granuloma annulare. *J Am Acad Dermatol* 2000;44:335-8.
5. Crone AM, James MP. Acquired linear anetoderma following angular cheilitis. *Br J Dermatol* 1998;138:923-4.
6. Schepis C, Siragusa M. Secondary anetoderma in people with Down's syndrome. *Acta Derm Venereol (Stockh)* 1999;79:245-51.
7. Shalders K, Ilchysyn A, Walzman M. Secondary anetoderma following molluscum contagiosum infection. *Acta Derm Venereol* 2003;83:461-2.
8. Bauer J, Leitz G, Palmedo G, Hügel H. Anetoderma: another facet of Lyme disease? *J Am Acad Dermatol* 2003;48:S86-88.
9. Carr RD. Urticaria pigmentosa associated with anetoderma. *Acta Derm Venereol (Stockh)* 1971;51:120-2.
10. Ang P, Tay YK. Anetoderma in a patient with juvenile xanthogranuloma. *Br J Dermatol* 1999;140:541-2.
11. Fujioka M, Gozo N, Osamu M, Tsuneyuki Y, Takehisa Y. Secondary anetoderma overlying pilomatrixomas. *Dermatology* 2003;207:316-8.
12. Venencie PY, Winkelmann RK. Histopathologic findings in anetoderma. *Arch Dermatol* 1984;120:1040-4.
13. Gerritsen MJ, de Rooij MJ, Sybrandy-Fleuren BA, van de Kerkhof PCM. Familial anetoderma. *Dermatology* 1999;198:321-2.
14. Peterman A, Scheel M, Sams M Jr., Pandya AG. Hereditary anetoderma. *J Am Acad Dermatol* 1996;35:999-1000.
15. Prizant TL, Lucky AW, Frieden IJ, Burton PS, Suarez SM. Spontaneous atrophic patches in extremely premature infants. *Arch Dermatol* 1996;132:671-4.
16. Zellman GL, Levy ML. Congenital anetoderma in twins. *J Am Acad Dermatol* 1997;36:483-5.
17. Ghomrasseni S, Dridi M, Gogly B, Bonnefoix M, Vabres P, Venencie PY, *et al.* Anetoderma: an altered balance between metalloproteinases and tissue inhibitors of metalloproteinases. *Am J Dermatopathol* 2002;24:118-29.
18. Sparsa A, Piette JC, Wechsler B, Amoura Z, Francès C. Anetoderma and its prothrombotic abnormalities. *J Am Acad Dermatol* 2003;49:1008-12.
19. Hodak E, Shamai-Lubovitz O, David M, Hazaz B, Katzenelson-Weissman V, Lahav M, *et al.* Immunologic abnormalities associated with primary anetoderma. *Arch Dermatol* 1992;128:799-803.
20. Hodak E, Shamai-Lubovitz O, David M, Hazaz B, Lahav M, Sandbank M. Primary anetoderma associated with a wide spectrum of autoimmune abnormalities. *J Am Acad Dermatol* 1991;25:415-8.
21. Álvarez-Cuesta CC, Raya-Aguado C, Fernández-Rippe ML, Sánchez TS, Pérez-Oliva N. Anetoderma in a systemic lupus erythematosus patient with anti-PCNA and antiphospholipid antibodies. *Dermatology* 2001;203:348-50.
22. Hodak E, Feuerman H, Molad Y, Monselise Y, David M. Primary anetoderma: a cutaneous sign of antiphospholipid antibodies. *Lupus* 2003;12:564-8.
23. Bilen N, Bayramgürler D, Şikar A, Erçin C, Yılmaz A. Anetoderma associated with antiphospholipid syndrome and systemic lupus erythematosus. *Lupus* 2003;12:714-6.
24. Disdier P, Harlé JR, Andrac L, Verrot D, Bolla G, San Marco M, *et al.* Primary anetoderma associated with the antiphospholipid

- syndrome. *J Am Acad Dermatol* 1994;30:133-4.
25. Ruiz-Rodriguez R, Longaker M, Berger TG. Anetoderma and human immunodeficiency virus infection. *Arch Dermatol* 1992;128:661-2.
26. Lindstrom J, Smith KJ, Skelton HG, Redfield R, Alving BM, Wagner KF, *et al.* Increased anticardiolipin antibodies associated with the development of anetoderma in HIV-1 disease. *Int J Dermatol* 1995;34:408-15.
27. Gezer S. Antiphospholipid syndrome. *Dis Mon* 2003;49:691-742.
28. Gibson GE, Su DW, Pittelkov MR. Antiphospholipid syndrome and the skin. *J Am Acad Dermatol* 1997;36:970-82.
29. Iverson GM, Victoria EJ, Cockerill KA, Linnik MD. Advances in understanding what we measure when detecting anticardiolipin auto-antibodies. *Clin Chim Acta* 2004;343:37-44.
30. Stephansson EA, Niemi KM, Jouhikainen T, Vaarala O, Palosuo T. Lupus anticoagulant and the skin: a long term follow up study of SLE patients with special reference to histopathological findings. *Acta Derm Venereol (Stockh)* 1991;71:416-22.
31. Roubey RA. New approaches to prevention of thrombosis in the antiphospholipid syndrome: hopes, trials and tribulations. *Arthritis Rheum* 2003;48:3004-8.
32. Ginsburg KS, Liang MH, Newcomer L, Goldhaber SZ, Schur PH, Hennekens CH *et al.* Anticardiolipin antibodies and the risk for ischemic stroke and venous thrombosis. *Ann Intern Med* 1992;117:997-1002.



Vlažno, hladno!

Sad NIVEA

I to radi sigurnosti natarite čvrsto lice i ruke svako veče sa Nivea-Creme. To je dovoljno! Koža će Vam postati otporna i nježna. Vjetar i nevrijeme nemogu Vam više nahuditi. Vi ćete zadobiti opet mladenačko-zdrav, svjež izgled, koji mi svi toliko volimo.

Nivea cream for humid and cold weather!
From the Nivea collection of Zlatko Puntijar