

Pemphigus Vulgaris Triggered by Glibenclamide and Cilazapril

Ilan Goldberg¹, Aushrat Sasson¹, Andrea Gat², Avigdor Srebrnik¹, Sarah Brenner¹

Departments of ¹Dermatology and ²Pathology, Tel Aviv Sourasky Medical Center, Sackler Faculty of Medicine, Tel Aviv University, Tel Aviv, Israel

Corresponding author:

Professor Sarah Brenner, MD
Department of Dermatology
Tel Aviv Sourasky Medical Center
6 Weizmann Street
Tel Aviv 64239
Israel
derma@tasmc.health.gov.il

Received: April 13, 2005.

Accepted: May 5, 2005.

SUMMARY A case of pemphigus triggered by glibenclamide and cilazapril is described. The suspicion of drug induction was confirmed in a laboratory study in which a pemphigus-like effect was induced by glibenclamide in cultured human skin explants. Withdrawal of the drugs and their replacement by hydrochlorothiazide and metformin resulted in subsidence of the lesions and no appearance of new lesions. The laboratory study carried out to verify the suspicion of drug induced pemphigus and to confirm the diagnosis proved useful in the differential diagnosis in this case.

KEY WORDS cilazapril, drug-induced pemphigus, glibenclamide, pemphigus vulgaris

INTRODUCTION

Pemphigus is an autoimmune disease, the onset and progression of which depend on an interaction between genetic predisposition and exogenous factors such as drugs and diet (1-3). There are a number of reports in the literature of pemphigus developing after treatment with glibenclamide and cilazapril (4-6). We describe a case of pemphigus vulgaris that appeared to have been induced by these two drugs. Evidence was obtained in a laboratory study in which a pemphigus-like effect was induced by glibenclamide in cultured human skin explants.

CASE REPORT

A 75-year-old Jewish man was admitted to the hospital for erosions over the back, right ear, chest, scalp and buccal mucosa persisting for six weeks. He had a history of diabetes mellitus

and hypertension, for which he was treated with glibenclamide and cilazapril, an angiotensin-converting enzyme (ACE) inhibitor. Histologic and immunofluorescence studies on a biopsy specimen confirmed the diagnosis of pemphigus vulgaris. There was no family history of the disease. Systemic treatment with prednisone, 100 mg per day, resulted in only mild regression of the eruption. Suspecting the eruption was drug-induced, we conducted a laboratory investigation in which a biopsy specimen from intact skin of the patient was cultured with glibenclamide at concentrations of 0.25, 1 and 5 mM. Human breast skin from a healthy woman undergoing mastopexy was also cultured with these same concentrations of glibenclamide. As control, we cultured intact skin of the patient and a specimen from the healthy woman in a drug-free medium.

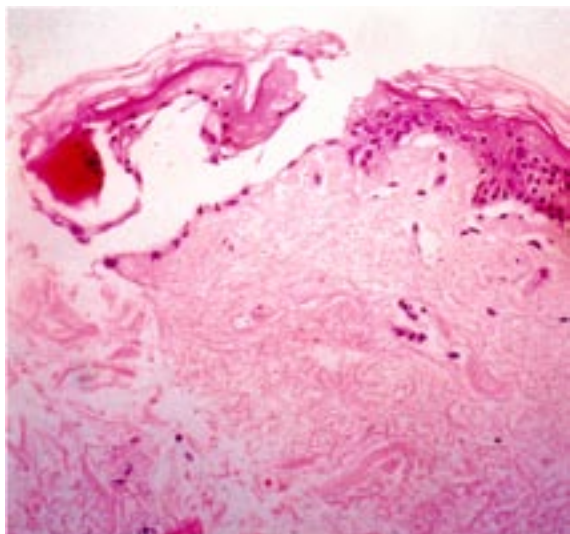


Figure 1. *In vitro* acantholysis in the skin of a healthy woman. The specimen was cultured with glibenclamide at a concentration of 0.25 mM

Suprabasal acantholysis was detected in all specimens cultured with the drug (Fig. 1), both from the pemphigus patient and the control subject, regardless of concentration. No structural changes were detected in the intact skin of the patient or in the specimen from the healthy woman that were cultured in a drug-free medium.

Based on these results and literature reports implicating this drug and cilazapril in pemphigus induction (4-6), we changed the patient's medications to hydrochlorothiazide and metformin. The lesions subsided and no new lesions appeared.

DISCUSSION

Drugs that induce pemphigus are divided into three groups according to their chemical structure: 1) thiol drugs (containing a sulfhydryl (SH-) group); 2) phenol drugs; and 3) nonthiol nonphenol drugs. Glibenclamide and cilazapril are nonthiol nonphenol drugs. Paterson *et al.* (4) report on a case of glibenclamide-induced pemphigus, in which the lesions subsided after discontinuation of the drug. Two cases have been reported with cilazapril (5,6), with subsidence of the lesions following withdrawal of the drug. Thiol drugs and phenol drugs are able to induce acantholytic changes in tissue cultures (7-9). The suggested mechanisms for acantholysis related to thiol drugs include (7): direct biochemical impairment to cell adhesion by thiol-cysteine bonds; inhibition of enzymes that aggregate keratinocytes; activation of enzymes like proteases and plasminogen activator that

disaggregate keratinocytes; and an immune reaction consisting of the formation of neoantigen and the consequent production of autoantibodies that cross-react with the native molecule and provoke pemphigus.

The possible mechanisms for phenol-induced pemphigus include the induction of IL-1 α and TNF- α release by keratinocytes. These cytokines have been demonstrated to play a role in the regulation and synthesis of complement and proteases like plasminogen activator, which has been implicated in the pathogenesis of acantholysis in pemphigus vulgaris (10,11).

The literature contains several reports of ACE inhibitors associated with pemphigus (12,13). Enalapril was found to be a powerful acantholytic drug *in vitro* (14), and glibenclamide was found in our study to be an acantholytic drug. More research is needed to understand the exact mechanism of the acantholysis induced by glibenclamide. It is interesting to note that glibenclamide is not exactly a thiol drug but it is one of the sulphonylureas and has sulfur (S-) in its molecule (Fig. 2), so the possible pathogenic mechanism is an inhibitory effect on the epidermal enzymes involved in cell-to-cell adhesion.

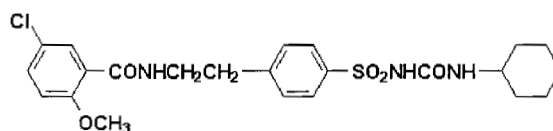


Figure 2. Chemical structure of glibenclamide.

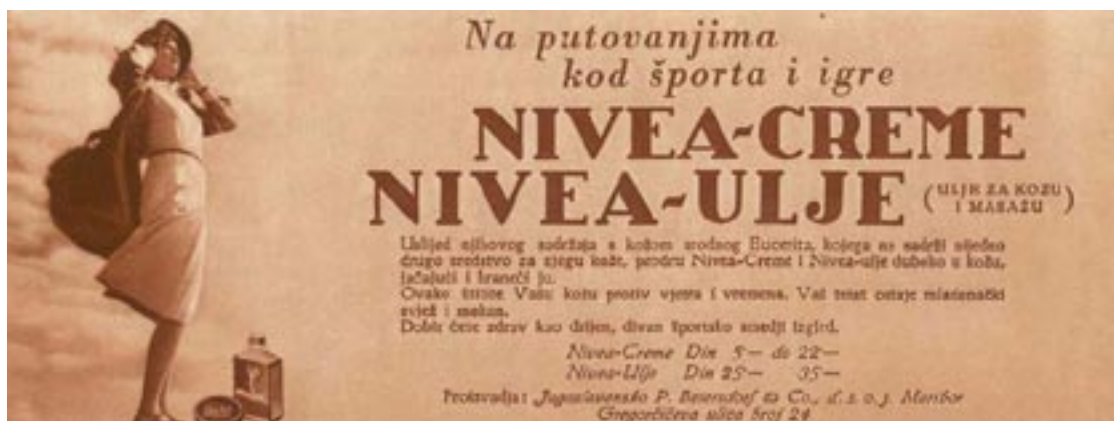CONCLUSION

Our case highlights the usefulness of the described laboratory investigation in the differential diagnosis and confirmation of drug induction of pemphigus.

References

1. Brenner S, Bialy-Golan A, Ruocco V. Drug-induced pemphigus. *Clin Dermatol* 1998;16:393-7.
2. Brenner S, Wolf R. Possible nutritional factors in induced pemphigus. *Dermatology* 1994;189:337-9.
3. Ruocco E, Aurilia A, Ruocco V. Precautions and suggestions for pemphigus patients. *Dermatology* 2001;203:201-7.

- Paterson AJ, Lamey PJ, Lewis MA, Nolan A, Rademaker M. Pemphigus vulgaris precipitated by glibenclamide therapy. *J Oral Pathol Med* 1993;22:92-5.
- Buzon E, Perez-Bernal AM, de la Pena F, Rios JJ, Camacho F. Pemphigus foliaceus associated with cilazapril. *Acta Derm Venereol* 1998;78:227.
- Orion E, Gazit E, Brenner S. Pemphigus vulgaris possibly triggered by cilazapril. *Acta Derm Venereol* 2000;80:220.
- Ruocco V, De Angelis E, Lombardi ML. Drug-induced pemphigus II. Pathomechanisms and experimental investigations. *Clin Dermatol* 1993;11:507-13.
- Brenner S, Ruocco V, Ruocco E, Russo A, Tur E, Luongo V, et al. In vitro tannin acantholysis. *Int J Dermatol* 2000;39:738-42.
- Brenner S, Srebrnik A, Goldberg I. Pemphigus can be induced by topical phenol as well as by drugs that contain phenols or thiols. *J Cosm Dermatol* 2003;2:161.
- Newby CS, Barr RM, Greaves MW, Mallet AI. Cytokine release and cytotoxicity in human keratinocytes and fibroblasts induced by phenols and sodium dodecyl sulfate. *J Invest Dermatol* 2000;115:292-8.
- Feliciani C, Toto P, Amerio P, Pour SM, Coscione G, Shivji G, et al. *In vitro* and *in vivo* expression of IL-1 alpha and TNF-alpha mRNA in pemphigus vulgaris: IL-1 alpha and TNF-alpha are involved in acantholysis. *J Invest Dermatol* 2000;114:71-7.
- Kaplan RP, Potter TS, Fox JN. Drug-induced pemphigus related to angiotensin-converting enzyme inhibitors. *J Am Acad Dermatol* 1992;26:364-6.
- Ong CS, Cook N, Lee S. Drug-related pemphigus and angiotensin converting enzyme inhibitors. *Australas J Dermatol* 2000;41:242-6.
- de Angelis E, Lombardi ML, Grassi M, Ruocco V. Enalapril: a powerful in vitro non-thiol acantholytic agent. *Int J Dermatol* 1992;31:722-4.



During travels, at sport and recreation, use Nivea cream and Nivea oil!
From the Nivea collection of Zlatko Puntijar