

PHACOEMULSIFICATION IN EYES WITH POSTERIOR POLAR CATARACT

Robert Stanić, Kajo Bućan, Karmen Stanić-Jurašin and Željko Kovačić

University Department of Ophthalmology, Split University Hospital Center, Split, Croatia

SUMMARY – The aim of the study was to evaluate the results of phacoemulsification in eyes with posterior polar cataract and to assess the risk factors for posterior capsular rupture during phaco surgery. This prospective study included 13 patients (14 eyes) undergoing phacoemulsification surgery with intraocular lens implantation. Intact posterior capsule was present in 10 (71.5%) eyes, posterior capsular rupture in 4 (28.5%) eyes, one of them with vitreal loss and requiring anterior vitrectomy. Of the eyes with intact posterior capsule, 5 (35%) had capsular plaque which was removed by gentle aspiration; in one case posterior capsulorrhexis was performed to remove the plaque; and postoperative capsule was clear in 4 (28.5%) eyes. In 3 eyes with capsular rupture, there was soft nucleus and capsular opacification greater than 3 mm in diameter, and the patients were under 40 years old. One capsular rupture occurred in dense cataract. The incidence of posterior capsular rupture in our study was 28.5%; other authors reported the incidence between 7.1% and 36%. Many different techniques have been described by other surgeons to avoid capsular rupture; however, in our opinion, posterior capsular rupture could not be avoided in some cases. In our study, the risk factors for capsular rupture in posterior polar cataract were soft nucleus with large capsular opacification and younger patient age. Our results of visual acuity after phacoemulsification in posterior polar cataracts are consistent with those reported by other authors: in 9 eyes, visual acuity was 0.8 or more (Snellen chart), and in 5 eyes there was no satisfactory improvement of visual acuity, probably due to amblyopia because the majority of the cataracts were unilateral. Accordingly, phacoemulsification in posterior polar cataracts, when done carefully, leads to good postoperative results and good visual improvement in most cases.

Key words: *Posterior polar cataract; Posterior capsular rupture; Phacoemulsification*

Introduction

Posterior polar cataract is a unique type of cataract characterized by a central dense block of white lens opacity on the posterior capsule¹. Posterior polar cataract presents a special challenge to the phaco surgeon because of its predisposition to posterior capsular dehiscence during surgery. The defect in the posterior capsule may cause rupture of the capsule during hy-

drodissection, nucleus removal, posterior capsule polishing, or the rupture may occur spontaneously^{1,2}.

The present study evaluated the results of phacoemulsification in the eyes with posterior polar cataract and assessed the risk factors for posterior capsular rupture during phaco surgery.

Patients and Methods

This prospective study included 13 patients (6 female and 7 male; 14 eyes) operated from February 2006 to December 2009. Twelve patients had unilateral cataract and one patient had bilateral cataract. The mean age of study patients was 45.5±13.3 (range

Correspondence to: *Robert Stanić, MD, MS*, University Department of Ophthalmology, Split University Hospital Center, Spinčićeva 1, HR-21000 Split, Croatia
E-mail: robertstanic@hotmail.com

Received February 15, 2011, accepted February 2, 2012

20–68) years. In 6 eyes, nucleus hardness was +2 (medium-hard) or more, and in 8 eyes it was 0 (soft) to +1 (semisoft), using nuclear hardness grading scale 0–4³. The surgery was performed under topical anesthesia. Clear corneal incision was made with a 2.75 mm knife (Alcon Laboratories, Inc., Forth Worth, TX, USA). Capsulorrhexis was performed with a 26 gauge needle under viscoelastic material, Celoftal® (Alcon Laboratories, Inc., Forth Worth, TX, USA; 2% hydroxypropyl-methylcellulose). Hydrodelineation was performed by injecting Balanced Salt Solution (BSS) into deeper layers of the lens in all cases, and hydrodissection was not performed. We also used Provisc® (Alcon Laboratories, Inc., Forth Worth, TX, USA) to maintain deep anterior chamber during phacoemulsification and to push back the vitreous face. In cases where the nucleus was +2 or more, we performed the phaco stop and chop technique⁴, with ultrasound power 50%–60%, vacuum 250 mm Hg, flow rate 20 mL/min and bottle height 90 cm. In cases with soft nucleus, we performed phaco aspiration, with vacuum 100–150 mm Hg, aspiration flow rate 15 mL/min and bottle height 70 cm. The residual cortex was aspirated by using a coaxial irrigation and aspiration probe. In one case, we performed posterior capsulorrhexis. Acrylic intraocular lenses (IOL; Acrysof MA60BM, Alcon, Forth Worth, TX, USA) were implanted in 13 eyes and in one eye polymethyl-methacrylate (PMMA) IOL was implanted in the ciliary sulcus.

Results

Intact posterior capsule was present in 10 (71.5%) eyes and posterior capsular rupture in 4 (28.5%) eyes, one of them with vitreal loss and requiring anterior vitrectomy. In 3 eyes that developed posterior capsular rupture, the nucleus was soft, posterior opacification was greater than 3 mm in diameter and the rupture occurred during aspiration. In one eye that developed posterior capsular rupture, the rupture occurred during removing nucleus fragments in dense cataract. Of the eyes with intact posterior capsule, five (35%) eyes had capsular plaque, which was removed with gentle aspiration; in one case we performed posterior capsulorrhexis to remove capsular opacification, and in 4 (28.5%) eyes the postoperative capsule was clear. In all cases, three-piece Acrysof MA60BM lens (Alcon,

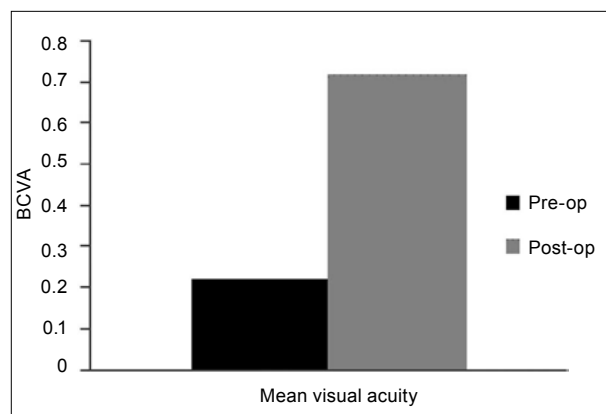


Fig. 1. Comparison of preoperative and postoperative visual acuity (BCVA = best corrected visual acuity).

Forth Worth, TX, USA) was implanted in the capsular bag, except for one case where PMMA lens was fixed in the ciliary sulcus because of a large capsular defect. In the eyes with small posterior capsular defect, IOL was implanted in the capsular bag.

The mean visual acuity improved significantly after surgery ($P < 0.001$, Wilcoxon matched pair test), (Fig. 1). In 9 eyes, the best corrected visual acuity was 0.8 or more (Snellen chart), while in 5 eyes visual acuity achieved 0.3 or less.

Discussion

The incidence of posterior capsular rupture in our study was 28.5%. Other authors report different results. So, Osher *et al.*¹ report on 26% incidence of posterior capsular rupture during surgery in eyes with posterior polar cataract, Vasavada and Singh² report 36%, Lee and Lee⁵ 11% and Hayashi *et al.*^{6,7} 7.1%. In our series, hydrodelineation was done in all cases, and we avoided hydrodissection. Hydrodissection and nucleus rotation are contraindicated in posterior polar cataract surgery because of the possible capsular rupture. Hydrodelineation without nucleus rotation is recommended to separate the nucleus from the epinucleus^{6,7}.

We performed the stop and chop technique in dense cataracts to remove the nucleus, and in very soft nucleus we performed phaco aspiration. In three cases, capsular rupture occurred at the time of epinucleus removal in soft cataracts, and in one eye it happened while we were emulsifying lens fragments in dense cataract. In soft cataracts, capsular rupture occurred

at the end of epinucleus removal and cortical removal was performed after IOL implantation. In our cases, 3 eyes with soft nucleus had capsular opacification greater than 3 mm in diameter, and this probably caused weakness of the capsule, which led to capsular rupture. Kumar *et al.* also report that the size of polar opacity has a significant risk of posterior capsular rupture⁸. Our patients with capsular rupture were younger than 40. Also, in soft cataracts, it is more difficult to maintain the depth of the anterior chamber because soft lens material does not support vitreous face, and so it makes the anterior chamber less stable. Vasavada and Raj⁹ performed inside-out delineation to protect posterior capsule during phacoemulsification.

Allen and Wood¹⁰ suggest performing viscodissection of the epinucleus by injecting viscoelastic Healon 5 (Pharmacia AB, Stockholm, Sweden) under the capsular edge to mobilize the rim of epinucleus. Vasavada and Singh² suggest the step by step chop in situ and lateral separation technique to emulsify the nucleus. Chee¹¹ devised a technique for hard posterior polar cataracts in which he cracked the nucleus in the periphery and then chopped into quadrants without rotation; then he engaged the core of the quadrant while cleaving along the lenticular lamellae, sparing the polar cataract. Despite all these different modified techniques described by other surgeons, in our opinion, posterior capsular rupture in posterior polar cataract could not be avoided in some cases, but capsular tearing and vitreous loss can be reduced using low settings of phacoemulsification¹², and maintain the depth of anterior chamber by injecting the ophthalmic viscosurgical device before removing the phaco- and I-A-probe from the eye. In our cases, there was no capsular rupture during aspiration and polishing the posterior capsule, probably due to the less fragility of the capsule and less adherent plaques. Other authors report avoiding polishing the posterior capsule because the traction produced by polishing may cause rupture of the capsule^{1,6}. Only in one case, capsular plaque was excessively adherent and we performed posterior capsulorrhexis¹³. Vasavada and Singh² performed Nd:YAG capsulotomy in these cases and posterior capsulorrhexis in cases where the rupture was confined to a small central area.

In our cases with capsular rupture, we implanted IOL in the bag because the rupture was small. Other

authors suggest capturing the optics through the anterior capsule in these cases¹³. Visual acuity was 0.8 or more (Snellen chart) in 9 eyes. The cause of the low acuity in 5 eyes probably was amblyopia because the majority of our cataracts were unilateral. Other authors report similar results of visual acuity after phacoemulsification in posterior polar cataracts^{7,14}.

Conclusion

In our study, the incidence of posterior capsular rupture was 28.5%. Posterior capsular rupture occurred more frequently in posterior polar cataracts with soft nucleus with large capsular opacification and in younger patients. Phacoemulsification in posterior polar cataracts, when done carefully, leads to good postoperative results and good visual acuity improvement in most cases.

References

- OSHER RH, YU BC, KOCH DD. Posterior polar cataracts: a predisposition to intraoperative posterior capsular rupture. *J Cataract Refract Surg* 1990;16:157-62.
- VASAVADA AR, SINGH R. Phacoemulsification with posterior polar cataract. *J Cataract Refract Surg* 1999;25:238-45.
- EMERY JM, LITTLE JH. Phacoemulsification and aspiration of cataracts: surgical techniques, complications and results. St. Louis: CV Mosby, 1979:45-8.
- KOCH PS, KATZEN LE. Stop and chop phacoemulsification. *J Cataract Refract Surg* 1994;20:566-70.
- LEE MW, LEE YC. Phacoemulsification of posterior polar cataracts – a surgical challenge. *Br J Ophthalmol* 2003;87:1426-7.
- HAYASHI K, HAYASHI H, NAKAO F, HAYASHI F. Outcomes of surgery for posterior polar cataract. *J Cataract Refract Surg* 2003;29:45-9.
- SIATIRI H, MOGHIMI S. Posterior polar cataract: minimizing risk of posterior capsular rupture. *Eye* 2006;20:814-6.
- UMAR S, RAM J, SUKHIJA J, SEVERIA S. Phacoemulsification in posterior polar cataract: does size of lens opacity affect surgical outcome? *Clin Exp Ophthalmol* 2010;38:857-61.
- VASAVADA AR, RAJ SM. Inside-out delineation. *J Cataract Refract Surg* 2004;30:1167-9.
- ALLEN D, WOOD C. Minimizing risk to the capsule during surgery for posterior polar cataract. *J Cataract Refract Surg* 2002;28:742-4.
- CHEE SP. Management of the hard posterior polar cataract. *J Cataract Refract Surg* 2007;33:1509-14.

12. OSHER RH. Slow motion phacoemulsification approach. *J Cataract Refract Surg* 1993;19:667.
13. GIMBEL HV, DeBROFF BM. Posterior capsulorrhexis with optic capture: maintaining a clear visual axis after pediatric cataract surgery. *J Cataract Refract Surg* 1994;20:658-64.
14. DAS S, KHANNA R, MOHIUDDIN SM, RAMAMURTHY B. Surgical and visual outcomes for posterior polar cataract. *Br J Ophthalmol* 2008;92:1476-8.

Sažetak

FAKOEMULZIFIKACIJA U OČIMA SA STRAŽNJOM POLARNOM KATARAKTOM

R. Stanić, K. Bućan, K. Stanić-Jurašin i Ž. Kovačić

Cilj istraživanja je bio evaluirati rezultate fakoemulzifikacije u očima sa stražnjom polarnom kataraktom i procijeniti rizične čimbenike za puknuće stražnje kapsule tijekom fakoemulzifikacijskog zahvata. Ovo prospektivno istraživanje uključivalo je 13 pacijenata (14 očiju) koji su podvrgnuti fakoemulzifikacijskom zahvatu s ugradnjom intraokularne leće. Kod 10 očiju (71,5%) imali smo intaktnu stražnju kapsulu, kod 4 oka (28,5%) razvilo se puknuće stražnje kapsule, od kojih smo u jednom slučaju imali gubitak staklovine, stoga je bilo potrebno uraditi prednju vitrektomiju. Kod pacijenata kod kojih je ostala intaktna stražnja kapsula, 5 pacijenata (35%) su imali kapsularni plak koji je odstranjen laganom aspiracijom, kod jednog pacijenta smo napravili stražnju kapsuloreksu da bismo odstranili plak, a kod 4 pacijenta (28,5%) postoperativna kapsula je bila čista. Kod 3 oka koja su imala meki nukleus došlo je do puknuća stražnje kapsule leće, te je kod tih očiju zamućenje stražnje kapsule bilo veće od 3 mm u promjeru. Pacijenti su bili mlađi od 40 godina. U jednom slučaju smo imali puknuće stražnje kapsule, koje se dogodilo kod tvrde katarakte. Incidencija puknuća stražnje kapsule u našem istraživanju je bila 28,5%, dok drugi autori govore o incidenciji između 7,1% i 36%. Drugi autori su opisali mnogo različitih tehnika za sprječavanje puknuća stražnje kapsule, međutim, prema našem istraživanju i kliničkom iskustvu, puknuće stražnje kapsule se u nekim slučajevima ne može izbjeći. U našem istraživanju čimbenici rizika za puknuće stražnje kapsule kod stražnje polarne katarakte bili su meki nukleus s velikim kapsularnim zamućenjem i mlađi pacijenti. Naši rezultati vidne oštine nakon fakoemulzifikacije kod stražnjih polarnih katarakti su slični onima drugih autora: kod 9 očiju vidna oština je bila 0,8 i više (Snelleova tablica), kod 5 očiju vidna oština se nije popravila na zadovoljavajući način, najvjerojatnije zbog postojeće ambliopije, jer je većina naših katarakti bila unilateralna. U zaključku možemo reći da fakoemulzifikacija kod stražnjih polarnih katarakti ima dobre postoperativne rezultate i vodi do poboljšanja vidne oštine u većini slučajeva.

Ključne riječi: *Stražnja polarna katarakta; Stražnja kapsularna ruptura; Fakoemulzifikacija*