

# ALL-INSIDE ARTHROSCOPIC SUTURING TECHNIQUE FOR MENISCAL RUPTURES

Nikica Daraboš<sup>1</sup>, Ivana Dovžak-Bajs<sup>1</sup>, Vide Bilić<sup>1</sup>, Anela Daraboš<sup>2</sup>, Iva Popović<sup>1</sup> and Tomislav Čengić<sup>1</sup>

<sup>1</sup>University Hospital of Traumatology, Sestre milosrdnice University Hospital Center, Zagreb; <sup>2</sup>Scientific Unit, Varaždin General Hospital, Varaždin, Croatia

**SUMMARY** – The most frequent indication for surgical treatment of the knee is lesion of the meniscus. The “all inside” arthroscopic technique with bioresorptive material for meniscus lesion is becoming the most popular treatment. This prospective study included 10 patients with posterior meniscal horn lesion operatively treated at Sports Traumatology Department. The “all inside” technique was performed by intra-articular application of bioresorptive pins-Darts sticks or Meniscus Viper and bioresorptive string. Patients were followed up for 2-6 months postoperatively and graded according to the IKDC 2000 scale. All surgical treatments showed satisfactory results. Young patients with acute longitudinal peripheral lesion-posterior horn lesions, in the red-red or red-white meniscal zone, 1-2 centimeters long are most appropriate for this type of treatment. In these patients, this technique proved to be superior and free from the risk of neurovascular damage. For better authentication of this conclusion, additional prospective randomized studies should be performed.

**Key words:** *Reconstruction; Meniscus; “All inside” technique, bioresorptive*

## Introduction

Meniscal lesion is the most frequent indication for surgical treatment of the knee. Rotation trauma is the usual cause of meniscal lesion in young patients and degenerative changes of meniscus in elderly patients<sup>1</sup>. The anatomy and vascularization of meniscus as well as the mechanism, classification and diagnosis of meniscal lesions are already described in the literature<sup>1-4</sup>.

The opinion of the importance of meniscus has changed with the development of knee surgery. Today, meniscal lesion refers to a lesion of the semicircular fibrocartilaginous segments that transfer forces between the bones in the tibiofemoral joint and keep pressure upon the cartilage below the allowable limit, while providing stabilization of the knee through their mobility<sup>1,2</sup>.

The interest in preserving the function of meniscus increased with the growing knowledge about the function of meniscus in the knee joint and implementation of arthroscopic technique in knee surgery<sup>2,3</sup>.

Currently, surgical treatment for meniscal lesion is as follows:

- partial or total resection,
- transplantation – tendon autograft, allograft,
- artificial meniscus – polyvinyl alcohol hydrogel,
- tissue engineering – tubular cartilage culture,
- repair
  - fibrin glue,
  - suturing with non resorptive material, and
- joining with resorptive darts.

Resection of meniscus leads to progression of radiological degenerative joint changes called Fairbanks signs, i.e. proliferation of peripheral osteophytes, alignment of condyle curves and narrowing of joint gap<sup>5</sup>.

Contrary, repair of meniscus preserves gait cycle and ensures normal distribution of synovial fluid,

Correspondence to: *Nikica Daraboš, MD, PhD*, University Hospital of Traumatology, Sestre milosrdnice University Hospital Center, Draškovićeva 19, HR-10000 Zagreb, Croatia  
E-mail: [darabos.dr@vz.t-com.hr](mailto:darabos.dr@vz.t-com.hr)

Received January 12, 2012, accepted April 3, 2012

lubrication of joint surfaces and proper nutrition of joint cartilage<sup>5</sup>. Surgical repair of meniscal lesion is arthroscopic treatment. There are more meniscal repair techniques usually divided into three types: (a) inside-out, (b) outside-in, and (c) all inside<sup>4-10</sup>. All these techniques have already been described in the literature<sup>4,6-10</sup>. In this study, postoperative results of meniscal repair treatment by the “all inside” technique were prospectively analyzed. The study included patients treated at our Traumatology Department.

## Patients and Methods

During a one-year period, four female patients aged 18-37 (median 30) and six male patients aged 25-45 (median 38) were treated for acute knee trauma at Sports Traumatology Department. As part of medical history, we kept track of Study Diary, which included general and demographic data, medical history, status of both knee joints, preoperative x-ray and magnetic resonance imaging (MRI) (4 patients), other diagnostic work-up of the injured knee, intraoperative findings and operation protocols, rehabilitation procedure, postoperative status and functional results of the operated knee, according to the International Knee Documentation Committee (IKDC) 2000 scale. All study patients had acute knee trauma with positive clinical signs for lesion of the medial, lateral or both menisci, variable amount of intra-articular effusion, and positive signs of Apley and Steinman tests. In four patients, clinical diagnosis was confirmed by MRI of the injured knee. Each patient was treated by standard arthroscopic surgery with the same instruments and by the same surgeon.

In all patients, meniscal lesion was longitudinal, located in the posterior horn region, always in the red-red or red-white zone of the meniscus. Lateral meniscus was damaged in seven patients and medial meniscus in three patients. The lesion volume was 1-2 centimeters long.

Concurrent lesion of the anterior horn of the opposite meniscus of the same knee was found in four patients, whereas rupture of the anterior cruciate ligament (ACL) as an additional lesion was detected in six patients. In these cases, the procedure of meniscus repair was combined with the treatment for other lesions of the knee.

The treatment combined two “all inside” techniques separately or together, depending on the volume of meniscal lesion. Both techniques included bioresorptive materials, i.e. suture with Meniscus Viper Fiber Wire material (Arthrex) or joining meniscus by bioresorptive darts (Arthrex) (Fig. 1). Bioresorptive material was completely resorbed in 6 months; however, it has been experimentally proven and published that meniscal load is possible even one month after reconstruction procedure.

Both reconstructive techniques started with intra-articular introduction of trocar through frontal, medial or lateral portal through which other instruments are introduced. It is followed by placing graduated crotchet, which gave us information on the type of rupture and on the site of material application, after which we placed a sharp rasp for treating lesion edges.

Meniscus Viper is a curved instrument, which makes the application easier. After rupture reposition, the Fiber Wire bioresorptive material was placed by a needle. Then a notch was made outside and placed on the extracondylar part of the ruptured meniscus, so it would not provoke pain symptoms. Additional notches were made to lock the suture.

When a combination of techniques was required or when the maximal length of the lesion was 1 cm, we used bioresorptive darts. Darts were positioned in the direction determined by the type of rupture or meniscal width.

Operative treatment was followed by physical therapy, at first stationary at the Department and then outpatiently or stationary in a rehabilitation center. For the first month of rehabilitation, passive and active knee joint motion was limited. Flexion 0

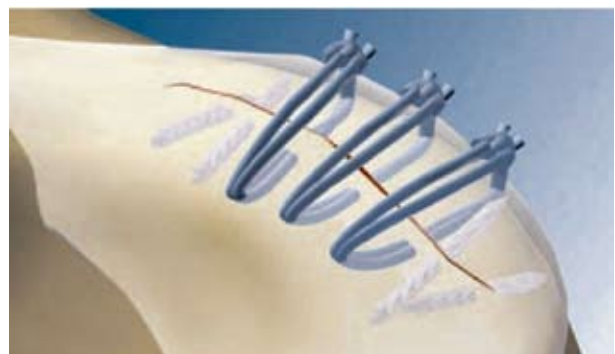


Fig. 1. Meniscus Viper Fiber Wire material (Arthrex).

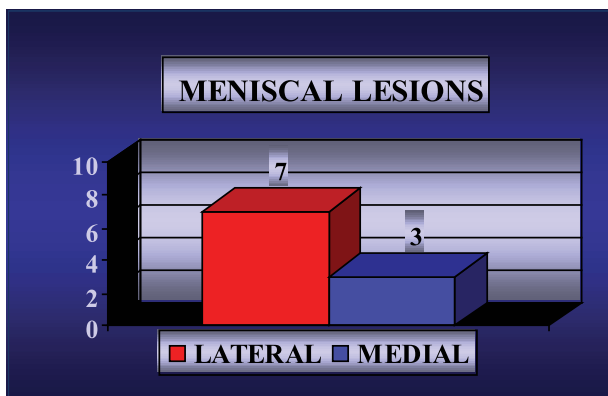


Fig. 2. Meniscal lesions.

and extension 90 degrees was allowed. Walking with limited flexion was allowed (30 degrees) supported by antebrachial crutches.

**Results**

This prospective study included ten patients with posterior meniscal horn lesion operatively treated at the Sports Traumatology Department during a one-year period. In all patients, meniscal lesion was longitudinal, located in the posterior horn region, always in the red-red or red-white meniscus zone. Lateral meniscus was injured in seven patients and medial meniscus in three patients. The lesions were 1-2 centimeters long (Fig. 2).

A lesion of the anterior horn of the opposite meniscus of the same knee was found in four patients and ACL rupture as an additional lesion in six patients. In these cases, the treatment of meniscus repair was combined with the treatment for other lesions of the



Fig. 3. Meniscal treatment.

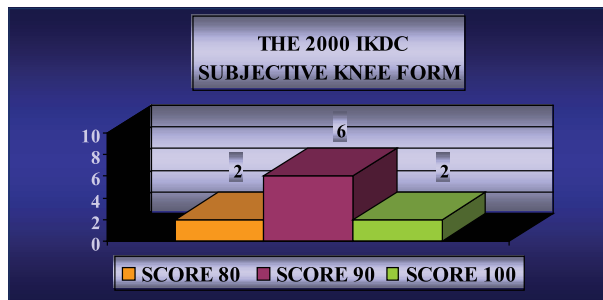


Fig. 4. The 2000 International Knee Documentation Committee (IKDC) subjective knee form.

knee. Surgery by the “all inside” technique connecting meniscus with bioresorptive Dart pins was performed in six patients, whereas in another four patients it was combined with the suture technique using the bioresorptive Fiber Wire material (Fig. 3).

Patients were followed up for 2-6 months postoperatively. All results were graded by use of interview and clinical status according to IKDC 2000 scale for the knee joint. According to the IKDC 2000 subjective scale (range 0-100), score 80 was recorded in two patients, score 90 in six patients and score 100 in two patients (Fig. 4). According to the IKDC 2000 clinical examination scale, eight patients were allocated in group A (without postoperative symptoms) and two patients in group B (with mild postoperative symptoms). In both cases, it was a complication in the form of patellar ligament enthesitis that was conservatively treated later (Fig. 5). Results of treatment according to IKDC 2000 scales were satisfactory in all patients, yielding 100% satisfactory results. Since there was no unsatisfactory result of treatment, the difference was significant.

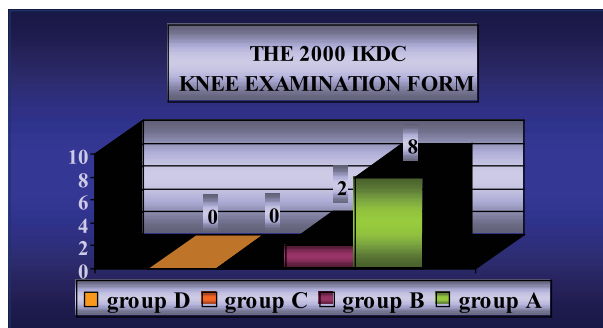


Fig. 5. The 2000 International Knee Documentation Committee (IKDC) knee examination form.

## Discussion

Using bioresorptive material for arthroscopic reconstruction of meniscal lesion has become very popular. At the same time, the “all inside” technique has been developed and excellent results have been achieved owing to the quality of the material<sup>6,9</sup>. The most significant advantage of the arthroscopic “all inside” technique is the possibility of application of bioresorptive material or pins through peripheral posterior horn lesion, without the risk of nerve or blood vessel damage<sup>4,6,9,10</sup>. At the same time, this technique introduces new arthroscopic instruments that give the surgeon the possibility of intra-articular pin placing and notch straining<sup>4,6</sup>.

Although our study showed very satisfactory treatment results, it should be emphasized that the technique must be used strictly individually. Young patients with acute longitudinal peripheral lesion-posterior horn lesions in the red-red or red-white meniscal zone, 1-2 centimeters long are most appropriate for this type of treatment. In these patients, this technique has proved superior and without the risk of neurovascular damage.

Additional prospective randomized studies should be performed to authenticate this conclusion.

## References

1. DUGAS RW, BRADLEY EDWARDS T. Meniscal injuries. Ortho.hyperguides.com, 2005.
2. SMILLIE JS. Injuries of the knee joint. 4<sup>th</sup> ed. Edinburgh: Churchill Livingstone, 1971.
3. ARNOCZKY SP, WARREN RF. Microvasculature of the human meniscus. Am J Sports Med 1982;10:90-5.
4. MILLER MD. Sports medicine. In: MILLER MD, editor. Review of orthopaedics. 3<sup>rd</sup> ed. Philadelphia, PA: WB Saunders, 2000.
5. FAIRBANK TJ. Knee joint changes after meniscectomy. J Bone Joint Surg Br 1948;30:664-70.
6. STONE KR. Current and future directions for meniscus repair and replacement. Clin Orthop Relat Res 1999;367:S273-S280.
7. BOHNSACK M, RUHMANN O. Arthroscopic meniscal repair with bioresorbable implants. Oper Orthop Traumatol 2006;18:425-52.
8. LOZANO J, MA CB, CANNON WD. All-inside meniscus repair: a systematic review. Clin Orthop Relat Res 2007;455:134-41.
9. TSAI AM, McALLISTER DR, CHOW S, YOUNG CR, HAME SL. Results of meniscal repair using a bioabsorbable screw. Arthroscopy 2004;20:586-90.
10. HANTES ME, KOTSOVOLOS ES, MASTROKALOS DS, AMMENWERTH J, PAESSLER HH. Arthroscopic meniscal repair with an absorbable screw: results and surgical technique. Knee Surg Sports Traumatol Arthrosc 2005;13:273-9.

## Sažetak

### ARTROSKOPSKA TEHNIKA “SVE UNUTAR ZGLOBA” ZA REKONSTRUKCIJU RUPTURIRANOG MENISKA

*N. Daraboš, I. Dovžak-Bajs, E. Elabjer, A. Daraboš, I. Popović i T. Čengić*

Ozljeda meniska je najčešća indikacija za kirurško liječenje koljena. Artroskopska tehnika “sve unutar zgloba” (“*all inside*”) za rekonstrukciju lezije meniska upotrebom bioresorpcijskih materijala sve je popularniji način liječenja ozljeda meniska. Prospektivno je analizirano iskustvo u operacijskom liječenju 10 bolesnika zbog ozljede stražnjeg roga meniska na Traumatološkom odjelu. Tehniku “sve unutar zgloba” proveli smo intraartikularnom aplikacijom bioresorpcijskih pino-va Darts sticks i/ili upotrebom Vipera meniska i bioresorpcijskog konca. Bolesnici su praćeni tijekom poslijeoperacijskog razdoblja od 2 do 6 mjeseci, a rezultati svih postupaka ocjenjivani prema ocjenskoj ljestvici IKDC 2000 za koljenski zglob su bili zadovoljavajući. Idealni kandidati za takav zahvat su mlađe osobe s akutnom, longitudinalnom, perifernom lezijom, tj. stražnji rog, u crveno-crvenoj ili crveno-bijeloj zoni meniska, dužine 1-2 cm. U takvih bolesnika, tehnika “sve unutar zgloba” u liječenju ozljede meniska pokazala se vrlo dobrom, jer omogućuje cjelokupan intraartikularni tretman bez rizika od neurovaskularnih ozljeda. Za procjenu vjerodostojnosti takvih zaključaka potrebne su veće prospektivne randomizirane studije.

Ključne riječi: *Rekonstrukcija; Menisk; Tehnika “sve unutar zgloba”; bioresorpcijska*