

UNRECOGNIZED FRACTURE OF THE POSTEROMEDIAL PROCESS OF THE TALUS – A CASE REPORT AND REVIEW OF LITERATURE

Srđan Rogošić¹, Ivan Bojanić¹, Igor Borić², Anton Tudor³, Dubravka Srdoč⁴ and Branko Šestan³

¹Department of Orthopedic Surgery, Zagreb University Hospital Center; ²Department of Radiology, Sestre milosrdnice University Hospital, Zagreb; ³Lovran Department of Orthopedics, School of Medicine, University of Rijeka, Rijeka; ⁴Department of Diagnostic and Interventional Radiology, Dubrava University Hospital, Zagreb, Croatia

SUMMARY – In this report, we present a rare case of an initially unrecognized fracture of the posteromedial process of the talus sustained in a seldom reported position of dorsiflexion and supination of the foot. Fractures of the posteromedial process of the talus are very rare and represent an important diagnostic problem. Difficult x-ray visualization makes these fractures often misdiagnosed as ankle sprains. Complications due to this kind of fractures can include serious consequences such as avascular osteonecrosis, tarsal tunnel syndrome, post-traumatic osteoarthritis, or chronic pain. Timely diagnosis represents an important factor in the development of these conditions. A heightened awareness in examining ankle traumas with specific patient history details is of great importance. The most common mechanism of injury includes dorsiflexion and pronation of the foot. However, in an increasing number of cases alternative mechanisms have been described, all including high-energy impacts. Our patient sustained a fracture of the posteromedial process of the talus in dorsiflexion and supination with high-energy impact due to a 3-m fall. The patient was treated with excision of the fragment six months after the injury, and 18 months after the surgery the patient returned to his normal daily activities with significantly less pain in the posteromedial part of the ankle.

Key words: *Fractures, bone – diagnosis; Fractures, bone – therapy; Talus – injuries; Case report*

Introduction

Talar fractures comprise 3%-5% of all foot and ankle fractures, most of them being fractures of the talar neck¹. By far the rarest foot and ankle fractures are those of the posterior process of the talus². Furthermore, the fractures of the medial tubercle are much rarer than those of the lateral tubercle of the posterior

process. Misdiagnosis is common due to inappropriate interpretation of conventional radiography and a low level of suspicion. As the most frequent diagnosis of ankle injuries is ankle sprain, many fractures of the ankle are often misdiagnosed as severe sprains². The first case of fracture of the posteromedial process of the talus was described by Cedell in 1974³. Already at that time, the significance of early recognition of such fractures was emphasized due to the possibility of further complications.

We present a case of fracture of the posteromedial process of the talus, which was initially unrecognized and misdiagnosed as ankle sprain.

Correspondence to: *Srđan Rogošić, MD*, Department of Orthopedic Surgery, Zagreb University Hospital Center, Šalata 7, HR-10000 Zagreb, Croatia

E-mail: srdan.rogosic@gmail.com

Received October 12, 2009, accepted August 11, 2010

Case Report

A 23-year-old male patient presented to emergency room of a trauma center with left foot injury after a fall from a 3-m high wall. To his recollection, the foot was in dorsiflexion and supination at the time of injury. On initial examination, there was significant swelling and severe tenderness of the ankle joint. Massive hematomas were present in both medial and lateral parts of the ankle spreading to the foot. At that time, no fractures were identified on standard anteroposterior or lateral x-ray images (Fig. 1). The patient was released from the hospital with a short leg, non-weight bearing cast, using two crutches due to the diagnosis of severe ankle sprain.

On follow-up examination after three weeks, the patient's immobilization was removed and he started physical therapy. Even though the edema and hematoma slowly subsided during the next two months, the patient still complained of a sharp continuous pain in

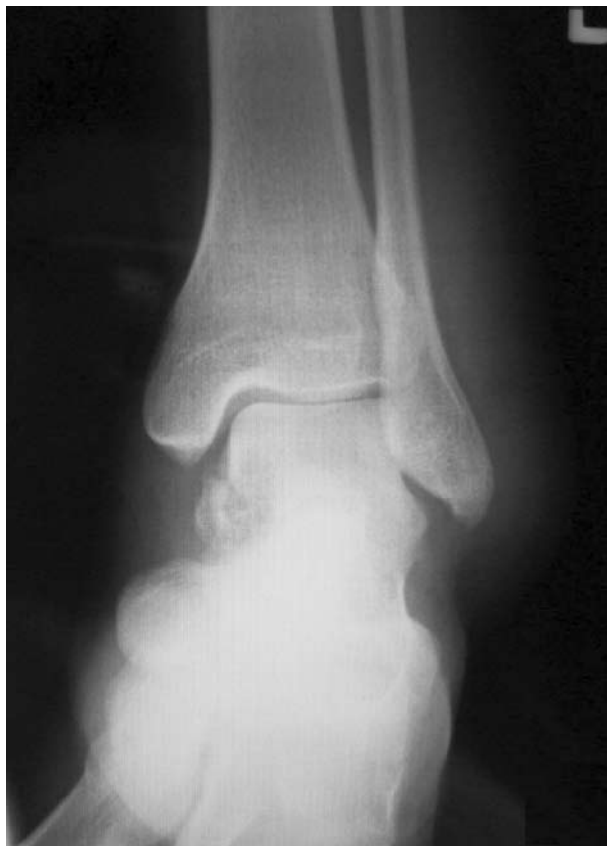

Fig. 1. Anteroposterior x-ray image showing ankle joint with inhomogeneous transparency in the area of medial talus.

the ankle, which would significantly increase after short periods of weight bearing or walking.

Due to these symptoms, the patient presented to Department of Orthopedic Surgery, Zagreb University Hospital Center, for second opinion. Physical examination revealed a normal range of motion in both ankles. The anterior drawer test and talar tilt test did not indicate joint instability. No ankle joint effusion or swelling around the ankle was present at that time. However, during the passive forced hyperplantarflexion test, the patient complained of pain in the posterior part of the ankle joint. Also, a strong feeling of discomfort and mild pain were present in the projection of the flexor hallucis longus (FHL) tendon behind the medial malleolus during passive motion of the big toe. The patient was unable to fully flex or extend his big toe and a significant tremor was present when performing these actions.

Multislice computed tomography (MSCT) was indicated due to suspicion of a misdiagnosed fracture of the talus. It confirmed a non-union fracture of the posteromedial process of the talus. The size of the fragment was 2x1.5x1 cm with a 3.5-mm displacement (Fig. 2). The fracture cleft was located in the very middle of the FHL groove, between the medial and lateral tubercles of the posterior process. Non-union was most likely caused by embedment of two small bone fragments in the fracture cleft. Two smaller fragments in the subtalar joint and one fragment just beneath the tip of the fibula were also observed.

We decided to perform surgical excision of the posteromedial fragment using the posteromedial approach. During surgery, we established that a small portion of the fragment had healed in the posterior part, so we decided to remove only the loose part of the fragment keeping anatomical continuity of FHL tendon groove intact and placing the tendon back into its place (Fig. 3). The patient was put in a short leg, non-weight bearing cast for four weeks. Following removal of the cast, he was rehabilitated by six-week physical therapy.

At final follow-up visit, 18 months after the surgery, the patient's ankle and subtalar joint range of movement was back to normal with a significant relief of pain in the posteromedial part of the ankle and unrestrained big toe movement. The patient has returned to his normal daily activities, although he still

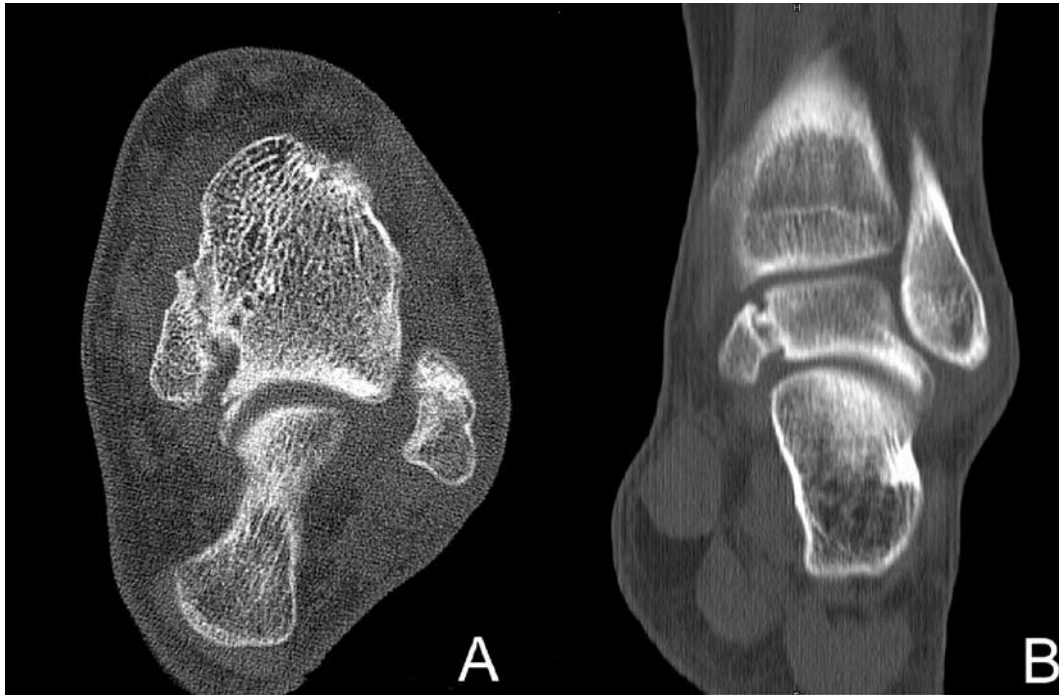


Fig. 2. Multislice computed tomography showing a non-union fracture of the posteromedial process of the talus in axial view (A) and coronal view with visible interposition of smaller fragments (B).

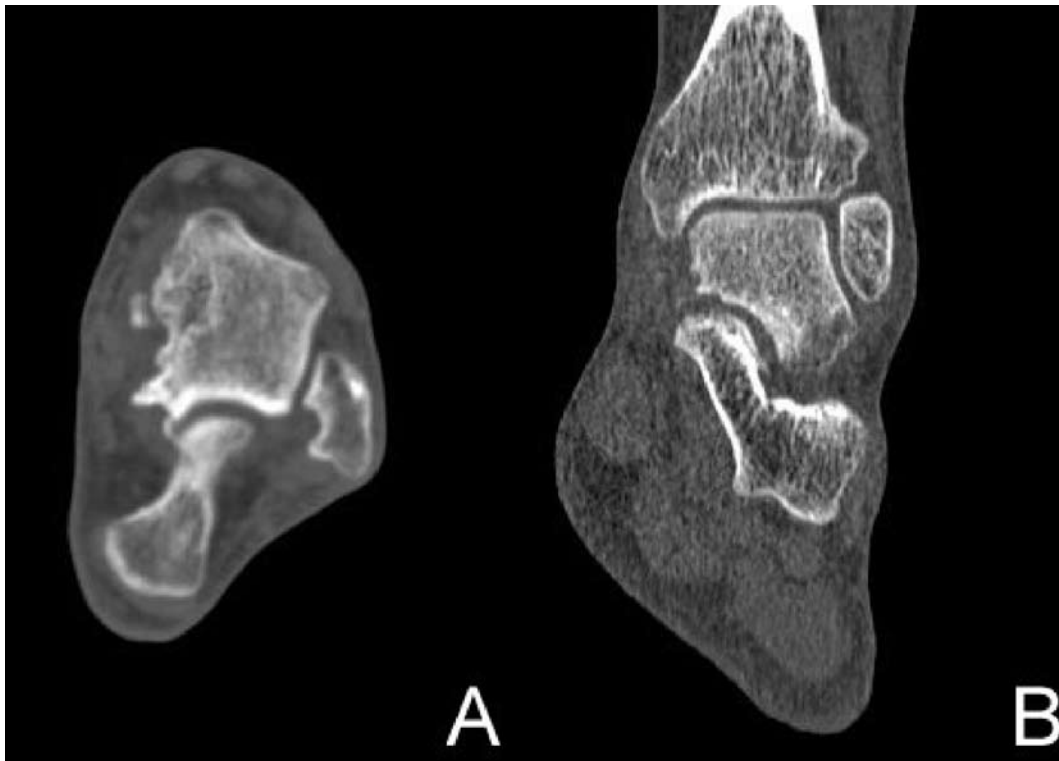


Fig. 3. Multislice computed tomography images showing the patient's ankle joint after excision of the posteromedial fragment in axial view (A) and coronal view (B).

complains of some pain in the anterolateral part of the ankle, especially after long walk.

Discussion

Ankle injuries are one of the most common causes of attending trauma centers. Among them, ankle sprains account for the highest number. Talar fractures represent only a small fraction of these injuries, but timely diagnosis of such an injury is of great importance due to early and late complications. Fractures most commonly occur in the neck of the bone and make up almost 50% of all talar fracture cases⁴. Due to the specific blood supply, such injuries can result in avascular osteonecrosis. Another serious complication of these injuries is the occurrence of tarsal tunnel syndrome⁵. However, development of posttraumatic osteoarthritis in the ankle or subtalar joint remains the most widely spread complication¹.

Since Cedell first described his four cases in 1974, 26 cases available to us through *Pub Med* service of the United States National Library of Medicine have been described in 17 reports^{1,3,5-19}. Most of those fractures were initially unrecognized.

Therefore, it is of great importance to screen for patients who should be referred for further diagnostic workup. We believe that the basis for such screening should be patient history with special reference to the mechanism of injury. Cedell's fracture was first described as an avulsion injury of the posterior talotibial ligament due to indirect force^{3,5-8}. This kind of trauma would occur with the foot in dorsiflexion and pronation^{3,5-7}. In 1998, Wolf and Heckman first described a fracture of the posteromedial process as the result of direct trauma⁹. Soon it was found that a high-energy impact, usually due to a fall or motor vehicle accident, could be a great predictor in direct, non-avulsion injuries^{1,6,7,10-15}. More reports have described alternative mechanisms of this injury. In those cases, we find that such an injury can occur when the foot is in plain dorsiflexion^{10,16,18}, plantarflexion¹², or supination^{7,11,13,17} (Table 1).

Our patient injured his ankle after a 3-m fall, with his foot dorsiflexed and supinated. Bone fragment was also significantly larger than in any case described as an avulsion injury. With this in mind, we presume that the high-energy impact in the described posi-

tion of dorsiflexion and supination of the foot caused impingement of the posteromedial part of the talus between the calcaneus (*sustentaculum tali*) and tibia (medial malleolus), resulting in such a fracture. So far, only four cases have indicated such a possibility in the genesis of Cedell's fracture^{7,11,13,17}. Furthermore, a small avulsion fragment underneath the tip of the fibula would indicate that such a mechanism really did occur in our case.

The ideal diagnostic tool for Cedell's fractures, which are poorly visible in standard x-ray images, is MSCT^{16,20}. But, if such an option is not available for any reason, satisfactory x-ray visualization might be obtained using two oblique views at 45° and 70° of external rotation. Such non-standard images have been demonstrated to be a quick and inexpensive method²¹.

The real challenge, after recognizing Cedell's fracture, is choosing appropriate treatment. There are four ways of treating Cedell's fracture and they include excision of the fragment^{3,5,9,12,19}, open reduction with internal fixation^{1,6,7,10,11,13-15}, conservative treatment involving only immobilization^{12,16-19}, and endoscopic treatment²². Factors which we sought for as relevant to make proper decision for our patient were fragment size and displacement, articular involvement, time delay and FHL interposition symptoms (Table 1).

In our case, there was a large fragment, which did not heal after six months. The bone fragment had small articular involvement, but was by 3.5 mm displaced with smaller fragments interposed. Displacement larger than 3 mm is considered significant and most often indicates the need of surgery^{1,23}. An additional factor in choosing treatment for our patient was time delay from the occurrence of the injury. All experiences available to us indicated a delay greater than 3 months should most likely be treated with surgical excision of the fragment^{3,5,12,19}. With all those factors summed up, it was evident that the fragment excision was the treatment of choice to obtain the best results with the fewest possible complications^{21,24}.

Unsatisfactory patient history and clinical detailing at the initial visit, together with an overseen inhomogeneous transparency in the medial part of the talus on x-ray images were the causes of misdiagnosis in our patient. Therefore, it is logical to stress that the patient history should be of utmost importance when

Table 1. Overview of papers on fractures of the posteromedial process of the talus sorted by years

First author and year of publication ^{Ref.no.}	No. of cases	Fracture displacement			Articular involvement			Mechanism of injury*	Time delay from injury to treatment			Treatment**
		Yes	No	n/a	Yes	No	n/a		<3 months	≥3 months	n/a	
Cedell 1974 ³	4			4			4	D/P		3	1	Ex, n/a‡
Banks 1994 ¹⁵	2	1		1	1	1		n/a	2			ORIF
Stefko 1994 ⁵	1			1			1	D/P		1		Ex
Kanbe 1995 ⁷	2	2			1		1	D/P, Sup	2			ORIF
Dougal 1997 ¹⁰	1	1					1	D	1			ORIF
Gutierrez 1998 ¹²	2	1		1	1		1	Pf	1	1		Ex, Im ^{##}
Wolf 1998 ⁹	1			1			1	n/a		1		Ex
Benmansour 1999 ⁶	1			1			1	D/P	1			ORIF
Cohen 2000 ¹¹	1	1					1	Sup	1			ORIF
Letonoff 2002 ¹	1	1			1			n/a	1			ORIF
Kim 1996 ¹⁸ , 2003 ¹⁹	5			5			5	D, n/a [†]	2	3		Ex, Im ^{###}
Hage 2005 ¹⁴	1	1			1			n/a	1			ORIF
Elmrini 2007 ¹³	1	1					1	Sup	1			ORIF
Van Tongel 2007 ⁸	1		1				1	n/a		1		No treatment
Yiannakopoulos 2007 ¹⁶	1		1				1	D	1			Im
O'Loughlin 2009 ¹⁷	1		1				1	Sup	1			Im

*D/P = dorsiflexion and pronation; D = dorsiflexion; Pf = plantar flexion; Sup = supination; n/a = data not available;

**ORIF = open reduction and internal fixation; Ex = excision; Im = immobilization; n/a = data not available;

†dorsiflexion in 1 patient, data not available in 4 patients;

‡3 patients treated with excision, data not available for one patient; ##1 patient treated with excision, 1 patient treated with immobilization only;

###3 patients treated with excision, 2 patients treated with immobilization only.

treating such injuries. Details about the mechanism of injury should take central place in this inquiry. Traumas including dorsiflexion with pronation, high-energy impacts with plantar or dorsal flexion and supination always indicate a higher probability of bone fractures.

Hence, we would like to emphasize that in all cases, including ours, physician's heightened awareness and adequate patient history details are crucial to making the right decision about further diagnostic workup and choosing the final treatment options.

References

1. LETONOFF EJ, NAJARIAN CB, SULEIMAN J. The posteromedial process fracture of the talus: a case report. *J Foot Ankle Surg* 2002;41:52-6.
2. JUDD DB, KIM DH. Foot fractures frequently misdiagnosed as ankle sprains. *Am Fam Physician* 2002;66:785-94.
3. CEDELL CA. Rupture of the posterior talotibial ligament with the avulsion of a bone fragment from the talus. *Acta Orthop Scand* 1974;45:454-61.
4. ELGAFY H, EBRAHEIM NA, TILE M, STEPHEN D, KASE J. Fractures of the talus: experience of two level 1 trauma centers. *Foot Ankle Int* 2000;21:1023-9.
5. STEFKO RM, LAUERMAN WC, HECKMAN JD. Tarsal tunnel syndrome caused by an unrecognized fracture of the posterior process of the talus (Cedell fracture). A case report. *J Bone Joint Surg Am* 1994;76:116-8.
6. BENMANSOUR MB, GOTTIN M, LECLERQ S, DINTIMILLE H, DIB C, CANTONNE Y. Fracture associée du tubercule postéro-médial et de l'apophyse latérale de l'astragale: un cas. *Appoint de la tomodesitométrie. Rev Chir Orthop Reparatrice Appar Mot* 1999;85:744-8.
7. KANBE K, KUBOTA H, HASEGAWA A, UDAGAWA E. Fracture of the posterior medial tubercle of the talus treated by internal fixation: a report of two cases. *Foot Ankle Int* 1995;16:164-6.
8. VAN TONGEL, MATRICALI GA. Fracture of the posterior medial tubercle of the talus: a case report and review of the literature. *Acta Orthop Belg* 2007;73:804-6.

9. WOLF RS, HECKMAN JD. Case report: fracture of the posterior medial tubercle of the talus secondary to direct trauma. *Foot Ankle Int* 1998;19:255-8.
10. DOUGALL TW, ASHCROFT GP. Flexor hallucis longus tendon interposition in a fracture of the medial tubercle of the posterior process of the talus. *Injury* 1997;28:551-2.
11. COHEN AP, CONROY JL, GIANNOUDIS PV, MATTHEWS SJ, SMITH M. Impingement fracture of the posteromedial process of the talus – a case report. *Acta Orthop Scand* 2000;71:642-4.
12. GUTIERRES M, CABRAL T, MIRANDA A, ALMEIDA L. Fractures of the posteromedial process of the talus. A report of two cases. *Int Orthop* 1998;22:394-6.
13. ELMRINIA, DAODIA, AGOUMIO, ELOUADGHIRI M, MAHFOUD M, BERRADA MS, ELBARDOUNI M, ELYAACOUBI M. Unusual associated postero-medial process of the talus fracture with medial malleolus and cuboid. *The Foot* 2007;17:42-4.
14. HAGE WK, OMONBUDE D, TEMPLETON PA. Postero-medial fracture of the talus in a skeletally immature adolescent treated by internal fixation. *Injury* 2005;36:1125-6.
15. BANKS AS, CALDARELLA D. Fractures of the posteromedial process of the talus. *J Am Podiatr Med Assoc* 1994;84:66-70.
16. YIANNAKOPOULOS CK, KANELLOPOULOS AD. Avulsion fracture of the medial tubercle of the posterior process of the talus. Three dimensional (3D) computed tomography features. *The Foot* 2007;17:38-41.
17. O'LOUGHLIN P, SOFKA CM, KENNEDY JG. Fracture of the medial tubercle of the posterior process of the talus: magnetic resonance imaging appearance with clinical follow-up. *HSS J* 2009 Apr 4. [Epub ahead of print]
18. KIM DH, HRUTKAY JM, SAMSON MM. Fracture of the medial tubercle of the posterior process of the talus: a case report and literature review. *Foot Ankle Int* 1996;17:186-8.
19. KIM DH, BERKOWITZ MJ, PRESSMAN DN. Avulsion fractures of the medial tubercle of the posterior process of the talus. *Foot Ankle Int* 2003;24:172-5.
20. EBRAHEIM NA, SKIE MC. Evaluation of process fractures of the talus using computed tomography. *J Orthop Trauma* 1994;8:332-7.
21. EBRAHEIM NA, PATIL V, FISCH NC, LIU X. Diagnosis of medial tubercle fractures of the talar posterior process using oblique views. *Injury* 2007;38:1313-7.
22. Van DIJK CN. Hindfoot endoscopy. *Foot Ankle Clin* 2006;11:391-414.
23. EBRAHEIM NA, SKIE MC, PODESZWA DA. Medial subtalar dislocation associated with fracture of the posterior process of the talus. A case report. *Clin Orthop Relat Res* 1994;303:226-30.
24. BERKOWITZ MJ, KIM DH. Process and tubercle fractures of the hindfoot. *J Am Acad Orthop Surg* 2005;13:492-502.

Sažetak

NEPREPOZNATI PRIJELOM POSTEROMEDIJALNOG NASTAVKA TALUSA: PRIKAZ SLUČAJA I PREGLED LITERATURE

S. Rogošić, I. Bojanić, I. Borić, A. Tudor, D. Srdoč i B. Šestan

U ovom prikazu opisujemo rijedak slučaj prvotno neprepoznatog prijeloma posteromedijalnog nastavka talusa zadobivenog u položaju dorzifleksije i inverzije stopala. Prijelomi posteromedijalnog nastavka talusa su iznimno rijedak i važan dijagnostički problem. Poradi otežane radiološke vizualizacije često se pogrešno dijagnosticiraju i to najčešće kao distorzija gležnja. Komplikacije ovakvih prijeloma mogu biti ozbiljne, a kao najčešće i najozbiljnije ističu se nastanak avaskularne nekroze kosti, sindrom tarzalnog tunela, poslijetraumatski osteoartritis ili kronična bol. Stoga je pravodobna dijagnoza od iznimne važnosti da bi se izbjegle moguće komplikacije. Potrebna je veća pozornost pri probiru ozljeda gležnja sa specifičnim anamnestičkim detaljima. Najčešći mehanizam nastanka ovakvog prijeloma je dorzifleksija i inverzija stopala. Međutim, u sve većem broju slučajeva opisuju se i drugačiji mehanizmi ozljede koji uključuju prijenos jake mehaničke sile. Naš bolesnik je zadobio prijelom posteromedijalnog nastavka talusa u rijetko opisanoj dorzifleksiji i inverziji, s prijenosom jake mehaničke sile, prilikom pada s 3 metra visine. Isprva je pogrešno liječen zbog distorzije talokruralnog zgloba, a poradi kontinuirane boli učinjena je ekscizija fragmenta šest mjeseci nakon ozljede. Osamnaest mjeseci nakon zahvata bolesnik se u potpunosti vratio svakodnevnim aktivnostima uza značajno manju bolnost u posteromedijalnom dijelu gležnja.

Ključne riječi: Prijelomi, kost – dijagnostika; Prijelomi, kost – terapija; Talus – ozljede; Prikaz slučaja