

# THE VASCULAR HYBRID ROOM – OPERATING ROOM OF THE FUTURE

Narcis Hudorović<sup>1</sup>, Sunčica Andreja Rogan<sup>2</sup>, Ivo Lovričević<sup>1</sup>, Mario Zovak<sup>3</sup> and Saša Schmidt<sup>4</sup>

<sup>1</sup>University Department of Vascular Surgery, <sup>2</sup>University Department of Oncology and Nuclear Medicine,

<sup>3</sup>University Department of Gastrointestinal Surgery, <sup>4</sup>University Department of Radiology, Sestre milosrdnice University Hospital, Zagreb, Croatia

**SUMMARY** – The last two decades have seen a paradigm shift in the treatment of vascular related diseases from once traditional open surgical repairs to the entire vascular tree being amenable to percutaneous interventions. Neither the classic operating room nor the conventional angiography suite is optimal for both open surgery and endovascular procedures. Important issues for the vascular hybrid operating room include quality of the imaging equipment, radiation burden, ease of use of the equipment, need for specially trained personnel, ergonomics, ability to perform both open and percutaneous procedures, sterile environments, as well as quality and efficiency of patient care. The most important feature of working in a dedicated hybrid vascular suite should be the ability to attain best treatment of vascular patients. Whether the interventional radiologist or the vascular surgeon uses the facilities is of less importance. Establishment of an endovascular operating room suite has the benefit of a sterile environment, and the possibility of performing hybrid procedures and conversions when necessary. Moreover, angiography immediately before treatment gives contemporary anatomical information, and after treatment provides quality control. Consequently, better quality and service can be provided to the individual patient. These changes in the treatment of vascular disease require that a new type of vascular specialist, named ‘vascular hybrid surgeon’, trained to perform both endovascular and open surgical procedures in this highly complex patient group.

**Key words:** *Operating rooms – organization and administration; Operating rooms – standards; Quality control; Vascular surgical procedures – adverse; Vascular surgical procedures – effects; Vascular surgical procedures – trends*

## Introduction

Patient and market forces continue to push for minimally invasive procedures over more traditional open surgical procedures with proven efficacy and long-term treatment benefit. The vascular surgeon of today has to adapt to this new technology driven trend<sup>1</sup>.

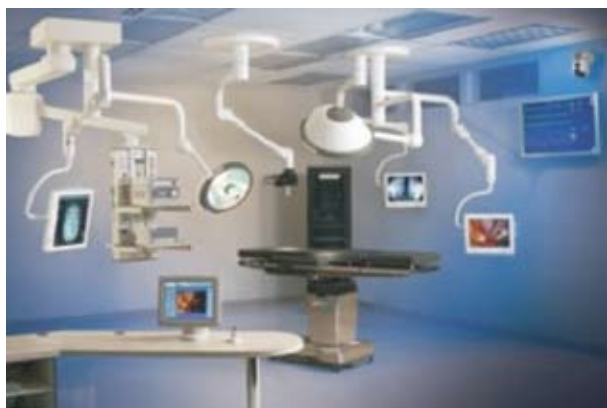These minimally invasive procedures or hybrid procedures have resulted in markedly decreased mor-

bidity and mortality of elderly patients who would otherwise be exposed to major operative morbidity and mortality. Currently, large areas of traditional vascular surgery as it stands are disappearing and have been substituted with less invasive percutaneous techniques. Areas of vascular surgery in which transcatheter techniques are firmly established and are rapidly being adapted to treat the whole spectrum of the vascular tree include treatment of peripheral artery disease (PAD), in which arterial revascularization is increasingly being replaced by percutaneous interventions and possibly by the emerging techniques of angiogenesis and related advances in molecular genetics. Abdominal aortic aneurysms (AAA) are disappearing from the surgical repertoire and are being treated with

Correspondence to: *Narcis Hudorović, MD, PhD*, University Department of Vascular Surgery, Sestre milosrdnice University Hospital, Vinogradska c. 29, HR-10000 Zagreb, Croatia  
E-mail: narcis.hudorovic@zg.htnet.hr

Received April 6, 2010, accepted in revised form July 29, 2010

endovascular procedures. Here, a true benefit is already being observed when applying this minimally invasive, percutaneous approach in aged, polymorbid patients. Percutaneous techniques are currently used to carotid endarterectomy (CEA) and reopening of intracerebral arteries by percutaneous transluminal angioplasty (PTA) or thrombolysis, carotid endarterectomy associated with PTA of the supra-aortic arteries, first rib resection associated with PTA, thrombolysis or vascular reconstruction, hybrid procedures for type B dissection, endoluminal repair of the aortic arch combined with revascularization of supra-aortic arteries, endoluminal repair of thoracoabdominal aneurysms combined with revascularization of the visceral arteries, endovascular treatment of thoracic aneurysms associated with open surgery of the infrarenal aorta for tandem lesions, open procedures to acquire aortic access for endoluminal grafting, hand-assisted techniques in laparoscopic infrarenal aortic reconstruction, robotic-assisted laparoscopic surgery of the infrarenal aorta, endovascular aortic reconstruction combined with elective open surgery, endovascular aortic reconstruction combined with laparoscopic surgery, long-term complications of endovascular aortic repair by means of laparoscopic techniques, embolization or revascularization of hypogastric arteries during endovascular aortic repair, proximal PTA



*Fig. 1. Hybrid solutions at the vascular hybrid room require the use of a C-arm and specialty imaging table, along with surgical support equipment to include surgical lights, booms, flat panel arms and displays, as well as advanced communications equipment to deliver surgical and radiological images when and where they are needed most. By courtesy of [www.siemens.com/healthcare-magazine](http://www.siemens.com/healthcare-magazine).*

associated with distal arterial surgical reconstruction, ring PTA techniques for femoropopliteal reconstruction, distal bypass combined with free vascular flap, fluoroscopy guided thrombectomy and other endovascular adjuncts for acute occlusion of lower limb arteries, venous thrombectomy combined with ilio caval stenting, and embolization combined with open surgery to treat complex congenital vascular malformations<sup>1-6</sup>.

Moreover, diseases of the thoracic aorta are currently being treated by transfemoral endovascular procedures, avoiding the inherent morbidity of aortic cross-clamping, aortic manipulation, and prolonged intensive care unit (ICU) stay with, in some cases, patients leaving the hospital on the next day.

The ability to provide such cutting edge technology borders on the availability of a new operative environment known as the vascular hybrid room (Fig. 1).

### **Operative Environment of Hybrid Vascular Operating Room**

A fully integrated vascular hybrid room combines surgical sterility<sup>7-9</sup> with flat-panel vascular imaging, a linked workstation, post processing, and storage facilities<sup>10-12</sup>. The size of the hybrid room should be of sufficient dimensions to allow for placement of anesthesiology facilities needed for full patient monitoring. Supportive equipment available in the room, such as machinery required for intravascular ultrasound, 3D transesophageal echocardiogram, rotational angiography as well as the ability for open conversion or hybrid intervention and endovascular supplies and devices must be able to fit in the hybrid room. Current vascular hybrid rooms are fitted with many interesting features to make certain procedures easier. An on-table duplex ultrasound makes puncturing easy and is a good guide during endovenous laser therapy. The possibility of storing several reference points to which the C-arm can be automatically relocated at any time during the procedure facilitates the management of even extremely complex procedures. Both endovascular and open surgical repair (OSR) gain from performance in this dual-capability working environment. For example, classic open bypass creation is immediately controlled on-table. When improvement of inflow or outflow becomes necessary after bypass surgery, balloon dilation with or without additional stent placement can be rapidly performed without dramati-

cally prolonging procedural time. The use of a vascular hybrid room, however, stretches beyond hybrid procedures and opens door to new diagnostic and treatment possibilities. Three-dimensional reconstructions generated by integrated CT or rotational angiography can make real-time visualization of vessel morphology in any direction and improve the visibility of vessel structures. Application of three-dimensional reconstruction during treatment of abdominal aneurysms, for instance, is a must to ensure optimal positioning of catheters, coils, balloons, and stents. Usage of integrated setting in a vascular hybrid room means saving time and personnel because more procedures can be completed in the same room by the existing staff without increasing the strain on the team and without relocating equipment or personnel from another department. The vascular hybrid room should become the one-stop shop where patients can be diagnosed and treated in one visit, for less downtime and faster recovery. Unique technology in the suite allows doctors across different specialties to work together on a case-by-case scenario, in the best interest of each patient. The most advanced imaging systems available provide quick and detailed information for shorter, more accurate treatment with substantially less x-ray exposure when compared to traditional devices. Complex cases are more easily treated, since the suite is designed to handle both minimally invasive percutaneous, hybrid operations and open surgical procedures<sup>13,14</sup>.

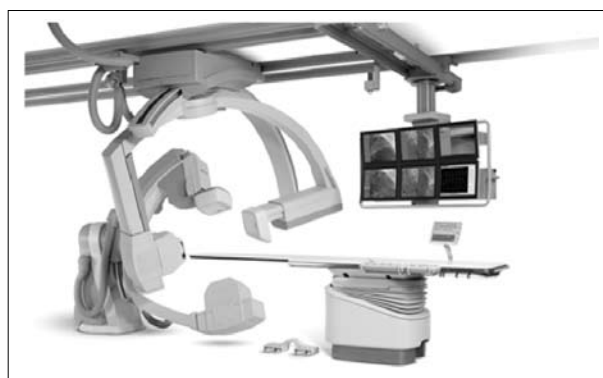
#### *Equipment and design of the hybrid vascular operating room*

The primary components of the vascular hybrid room are intraoperative angiography and fluoroscopy as well as carefully designed operating tables to accommodate and optimize the usefulness of radiographic equipment. The vascular hybrid room imaging system provides superior image quality, higher tube heat capacity and has measurement abilities capable of simple and complex procedures requiring high resolution. Price range is between US\$ 1.6-3.0 million depending on the brand, specifications, ability to provide rotational angiography, and the cost could even be higher with the addition of a biplanar system and with integration of various sophisticated imaging modalities like 3D echocardiography, intracardiac ultrasound, and wireless connections between basic

tools, intravascular ultrasound and electromagnetic navigation systems.

#### *Size and radiation of the hybrid vascular operating room*

The operating room should ideally be between 50-85 square meters, with a minimum clear area of 37-45 square meters. Floor to ceiling heights should be at minimum 3 meters to accommodate floor or ceiling mounted C-arms capable of rotational angiography for volume rendering 3D CT-like images achieved with advanced biplanar imaging systems (Fig. 2). In the existing operating rooms, the fixed ceiling-mounted C-arm requires some structural modifications to install the mounting plates and run electrical conduits under the floor to the components. Most states dictate that vascular hybrid room with a fixed imaging system must have lead-lined walls. Most standard vascular hybrid rooms have 0.5 mm lead covering, which is not sufficient for the radiation dose generated by a



*Fig. 2. Vascular hybrid room integrated in the operating room comprising a biplane digital subtraction angiography unit with multipurpose surgical capabilities. By courtesy of [www.siemens.com/healthcare-magazine](http://www.siemens.com/healthcare-magazine).*

fixed unit. Lead-lined walls in the range of 2-3 mm for fixed units may be needed and may vary from state to state. The expense of these constructions/modifications can vary up to US \$100,000, depending on the original condition of the room, local contracting costs, architect's fees, and companies that market fixed fluoroscopic units usually provide consulting services for such alterations.

As vascular hybrid surgical procedures become more complex, the relationship of the C-arm, table and patient's position becomes even more important.

The fluoroscopic unit should be able to move in horizontal plane from the groin along the course of the vessel with the ability to 'snap images on the move'. This parallel movement prevents the need for excessive contrast material and greatly expedites the procedure. When a catheter is placed in the brachial artery, the fluoroscopic unit must be capable of rapid movement over the catheter's path from the arm and through the thoracic aorta to the area of ultimate instrumentation. Obstructions from a table or a floor-mounted portable unit that hinder rapid panning over wide anatomic areas limit the potential success of the procedure<sup>2,4-6</sup>.

#### *Carbon fiber table*

In the hybrid vascular operating room, the surgeons and radiologists must optimize the usefulness of the radiographic equipment. For such a purpose, a non-metallic, carbon-fiber surgical table is available for interventional techniques<sup>15</sup>. For the hybrid vascular techniques, the surgical operating table should be preferably thin but highly stable and should provide complete clearance beneath a panning x-ray system. The best example is the Diethrich IC 2020 surgical imaging table, which is a thin carbon fiber table supported at only one end to provide complete clearance beneath for panning. The telescoping pedestal allows for vertical travel from 71 to 122 centimeters, 20° side-to-side roll and 20° Trendelenburg tilt (reverse and standard), which makes it ideal for a surgical operating room. Complete clearance is achieved beneath for unobstructed neck-to-toe imaging and rapid horizontal panning is achieved with multiple position, height, tilt and roll adjustments. The development of this table has enabled vascular surgeons enhanced opportunities to be involved in the ever-expanding and exciting field of endovascular surgery.

#### *Screens and monitors*

The surgeons, the assistant, the anesthesiologist and the nurse should all have views of all major imaging and monitoring sources. It is therefore suggested that display of all these sources should be available in all four quadrants of an integrated room. A total of 4-6 ceiling-mounted flat screens as imaging tools for the procedures are necessary. Extreme care should be taken to ensure that these ceiling-mounted flat screens do not collide with operating lights. Monitors for the

vital signs of the patient with provision for systemic arterial monitoring, central venous monitoring, and continuous electrocardiographic surveillance are an imperative. A large 101 centimeter flat panel should be available as well as cameras (wall/or in-light).

#### *Patient monitoring*

The hybrid suite must be equipped for accurate patient monitoring during the procedure. Observation of urine output is essential for cases involving renal arteries and higher abdominal or thoracic aortic segments. Intra-arterial monitoring that includes precise measurement of pressure differentials is also important during performance of these procedures. Space for storage for the special procedure-related equipment such as stents, wires, balloons, stent-grafts should be available.

#### *Imaging Systems at the Hybrid Vascular Operating Room*

The imaging quality is dominated by the quality of the fluoroscopy unit available. Available systems can be divided roughly into two categories: portable and fixed C-arm units. Fixed C-arm units could be floor mounted or ceiling mounted. There are a number of fixed fluoroscopic units available with various modifications, depending on the manufacturer (e.g., Philips, GE, OEC, Siemens, Toshiba) (Fig. 3). The image quality of fixed systems is usually superior to portable systems, which can be explained by the focal spot sizes of fixed systems being significantly smaller than those of portable units<sup>9,10</sup>. A smaller focal spot size means higher resolu-

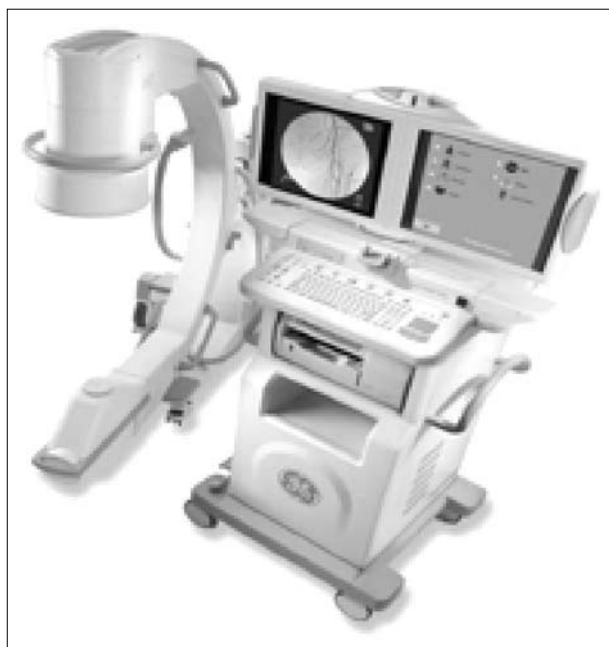

*Fig. 3. Floor mounted hybrid surgical system Artis zeego. Multi-axis system by Siemens. By courtesy of [www.siemens.com/healthcare-magazine](http://www.siemens.com/healthcare-magazine).*

tion through more line pairs *per* millimeter. Nevertheless, the latest portable C-arm systems are able to reach resolutions up to  $2.5 \times 10^3$  line pairs *per* mm, values that until recently could only be attained by fixed systems (Fig. 4). The monitor resolution of fixed systems differs from portable systems, the monitors of fixed systems usually having twice the lines of resolution as the monitors of portable systems. Portable systems have a smaller generator in order to keep the system 'practical', whilst fixed systems have a large remote generator, which provides more power with better tissue penetration and improved imaging quality. Currently, portable C-arm systems are able to provide sufficient quality for the majority of the standard procedures in vascular surgery. However, the more complex procedures are best performed with a fixed unit.

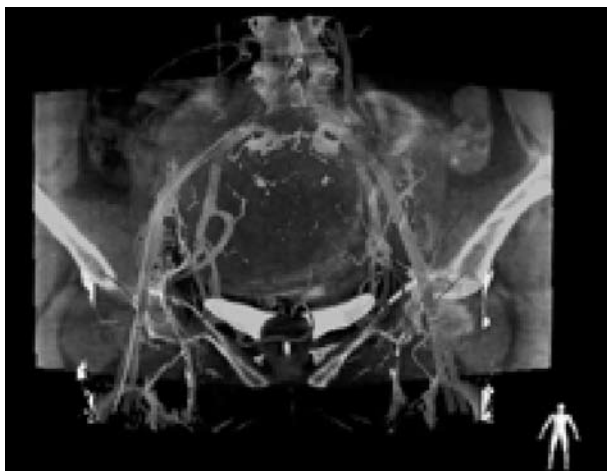
#### *Image acquisition and display*

Traditional fluoroscopy provides real-time, high-resolution, low-contrast images in two dimensions by use of an image intensifier. The development of a flat-panel detector to replace the image intensifier has enabled fluoroscopy to transition into three dimensions, producing a CT-like image. The contrast resolution of CT is  $\sim 1$  Hounsfield unit (HU), whereas the contrast resolution of a CT-like image is around 10 HU. CT



*Fig. 4. A General Electric OC 9900 mobile fluoroscopic unit. By courtesy of [www.nvidia.com](http://www.nvidia.com).*

fluoroscopy is not meant to replace diagnostic CT but to be used as a tool that will supplement interventional procedures. The ability to acquire data in three dimensions during an intervention has led to the fusion of three-dimensional datasets with two-dimensional images displayed on typical monitors. In CT rotational angiography, which the latest hybrid imaging systems have, the C-arm is used to rapidly rotate, obtaining serial images of the area in question in a radial fashion. The three-dimensional reconstruction can be recorded with subsequent real-time fluoroscopic images and projected to offer the clinician the ability to work in three dimensions. Data can be rendered volumetrically and overlaid on the fluoroscopic image, making the anatomy much more identifiable, a fused two-dimensional/three-dimensional dataset can be created, or the information can be placed side by side. Further requirements of the suite's imaging system are a processing unit, a workstation, and a central image storage unit. The potential of any C-arm equals the weakest link of each of these last three elements. While performing a procedure, smooth and fast graphic abilities are a must. Using large-size, superb-quality images from a C-arm implies that a powerful processing unit is needed. The higher the image quality, the more working memory the processing unit needs. Images from a C-arm are stored in DICOM format files, which can then be used for biometric post-processing, such as quantitative vessel analysis or three-dimensional reconstruction. The higher the quality of the images obtained from the C-arm, the larger the size of the files that have to be processed by the workstation. Advanced imaging using Dynamic 3D Roadmap has significant clinical advantages for applications such as real-time catheter navigation and monitoring coil delivery. The image is dynamic, meaning the 3D roadmap remains displayed even if the C-arm projection, source-to-image distance and field of view size are changed (Fig. 5). The 3D volume automatically follows the orientation of the C-arm in real-time, so that users can choose the optimal projection view. This dynamic overlay ensures excellent positioning for catheter navigation during challenging interventions (Fig. 6). The dynamic 3D image decreases the number of DSA acquisitions and fluoroscopy time for an examination. The user can also recall roadmap positions to reduce the need to re-mask. This reduces x-ray dose

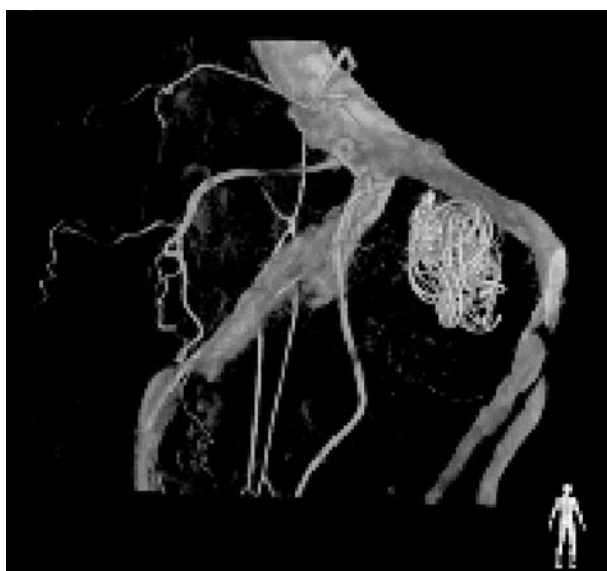

*Fig. 5. Dynamic 3D Roadmap provides live 3D guidance through tortuous vasculature. It creates an overlay of real-time 2D fluoroscopy images and 3D reconstruction of the vessel tree. By courtesy of [www.siemens.com/healthcare-magazine](http://www.siemens.com/healthcare-magazine).*

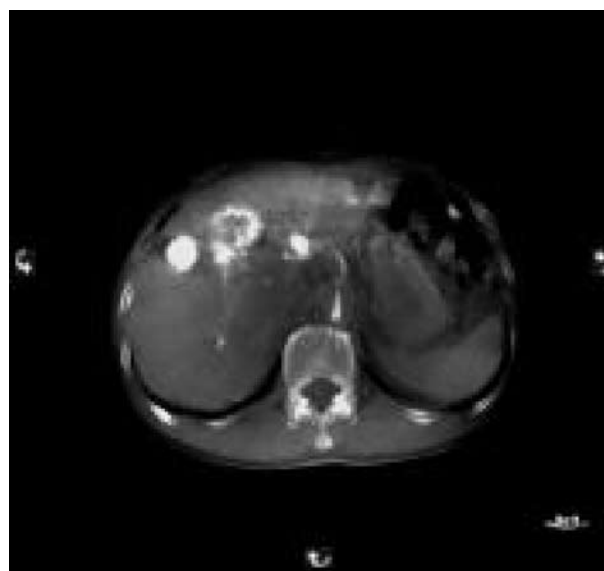
and contrast medium, which can reduce procedure costs. Dynamic 3D Roadmap provides live interventional catheter navigation (Fig. 7).

#### *Other imaging modalities*

Integration of other imaging modalities like intravascular ultrasound (IVUS) permits more data acquisition (Fig. 8)<sup>18</sup>.

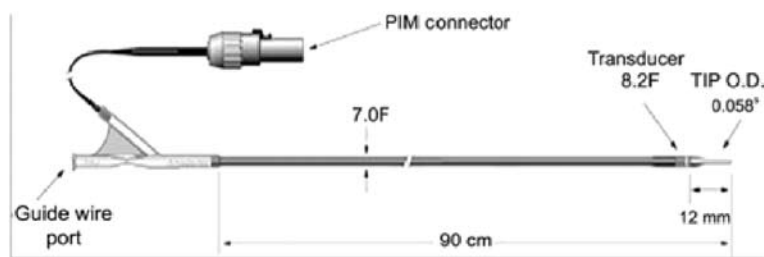


*Fig. 6. Flexible operational modes. Multiple modes provide maximum clinical flexibility. Technique can combine either high-resolution 3D-RA vascular images or previously-acquired 3D segmented MRA or CTA data with live fluoroscopy. Imported data are registered to the current patient position through a low X-ray dose 3D-RA scan, allowing 're-use' of contrast and X-ray doses. The system also supports improved visualization of soft tissues, and consolidated views of the current vascular anatomy with surrounding tissues. Moreover, 3D Roadmap adapts in real-time to changes in C-arm angulation and rotation, field of view and source-image distance. All modes of use can be controlled at the tableside through the XperModule and are fully dynamic to allow changes in gantry and table position, field of view and source-image distance. By courtesy of [www.siemens.com/healthcare-magazine](http://www.siemens.com/healthcare-magazine).*

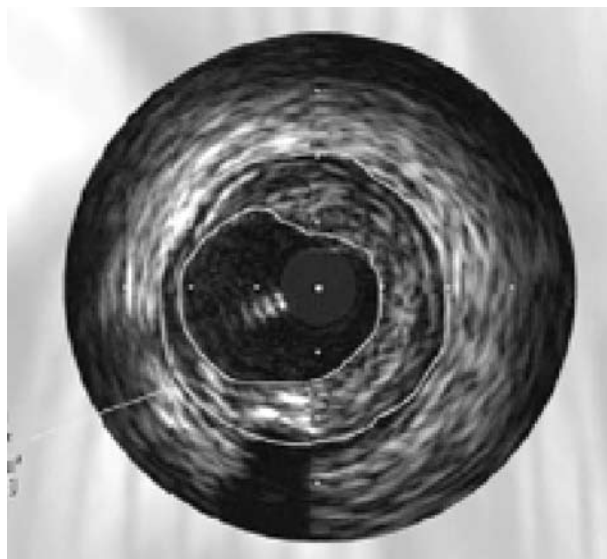


*Fig. 7. 3D visualization. The image data can be visualized as a regular CT image with 3D volume viewing in any orientation. Other 3D features include slice viewing in any orientation and at any slice thickness from 0.5 mm up. Cut-plane functionality provides information on anatomical structure, and a unique Reconstructive Zoom Technique is available for high-resolution applications. By courtesy of [www.siemens.com/healthcare-magazine](http://www.siemens.com/healthcare-magazine).*

The explosion of the endovascular revolution with particular application to the aorta has placed new demands on accurate preoperative and intraoperative imaging to obtain accurate aortic measurements for endovascular stent-grafting of the aorta<sup>16-18</sup>. Unlike traditional cardiac ultrasound that uses an exterior probe and is limited to imaging between the patient's



*Fig. 8. (a) Intravascular ultrasound 0.035 PV catheter system (IVUS). (PIM Connector = patient interface module connector; TIP O.D. = tip outer diameter of probe). By courtesy of [www.advancedultronics.com](http://www.advancedultronics.com);*



*Fig. 8. (b) Intravascular ultrasound used to calculate area and percentage of stenosis flow by dividing the lumen diameter by vessel diameter.*

ribs or a transesophageal probe, IVUS uses a miniature ultrasound transducer mounted on the tip of a catheter.

Standard IVUS catheters use a 9-French delivery sheath and a 0.035-inch guidewire, but smaller catheters do exist, such as the eagle eye gold catheter, which uses a 0.014-inch guidewire. The ultrasound transducer emits and receives signals at 12.5, 20, or 30 MHz, producing an axial image (or frame) similar to the cuts from computed tomography and magnetic resonance imaging. Sizes (in megahertz) increase results in a more detailed image (known as “near vision”) with a decrease in size (in megahertz) resulting in more penetration with a larger field of view.

Two-dimensional IVUS images are obtained by passing an ultrasound catheter over a guidewire into the area of investigation. The axial view is a 360° real-time image obtained by rotating the ultrasound beam rapidly around the axis of the catheter. The radius of

detection can be altered to suit the diameter of the vessel. In normal artery, ultrasound waves are reflected differently by various vessel wall components. The reflections from collagen and elastin are stronger than smooth-muscle cells, revealing muscular media as a hypoechoic circle, distinct from the reflective intima and adventitia.

The use of three-dimensional IVUS technology<sup>17,18</sup> is of particular importance in preventing suboptimal intraluminal device deployment that may not be appreciated on angiography, as well as selecting the size of the endovascular device to use. Intravascular ultrasound three-dimensional images are created by the computer using an edge-tracking formula (algorithm). Consecutive axial two-dimensional images are aligned and stacked longitudinally during a “pullback” of the ultrasound catheter through the vessel. Each picture element (pixel) of the two-dimensional image is assigned a digital position on the X and Y axis. By adding a Z axis, or a third dimension, each square pixel becomes a cubic picture element (voxel). When all the stacked frames are put together, the three-dimensional reconstruction is complete and can then be examined by the computer software to view the vessel from any angle, slice, or rotation. Three-dimensional reconstruction can assemble the stack of serial two-dimensional axial frames into both a “longitudinal” image and “volume” image. For acquisition of high-quality longitudinal and volume views, a smooth pullback of the catheter at a steady rate is required. This may be done manually or using a motorized device. In general, 1 mm/s with a 30 frames/s rate are recommended for shorter lesions. For longer areas of interrogation (>7 cm), the frame rate needs to be lowered to 10 frames/s because the computer can only handle 2,048 frames in one pullback.

In clinical practice there are three types of IVUS catheters that are currently in use for coronary and aortic interventions, the 0.035 PV 8.2-French (Vol-

cano Therapeutics, Rancho Cordova, CA) IVUS catheter system, the 0.014 Eagle Eye Gold (Volcano Therapeutics) IVUS catheter system, and the 0.018 PV (Volcano Therapeutics) IVUS catheter system<sup>19</sup>. The 0.035 PVIVUS catheter is an over the wire catheter based ultrasound with an 8.2-French crossing profile at the transducer and a 7.0-French shaft diameter. The minimum sheath internal diameter is 9-French. The working catheter length is 90 cm, and the imaging diameter is 60 mm, and it is an over the wire device. The 0.014 Eagle Eye Gold IVUS catheter system is a monorail based system with a 2.9-French crossing profile at the transducer and a 2.7-French shaft diameter. The minimum guide catheter internal diameter is 5-French. The working length is 150 cm and the imaging diameter 16 mm. The transducer, however, cannot be flushed, and the catheter is compatible with Volcano Trak Back II and R-100 Pullback devices (Volcano Therapeutics)<sup>13,16-18</sup>. The 0.018 PV IVUS catheter system is a monorail based system with a 3.5-French crossing profile at the transducer, an imaging diameter up to 24 mm, and working length of 135 cm. The minimum guiding catheter inner diameter is 6-French, and the transducer cannot be flushed<sup>18,19</sup>.

In addition to providing precise measurements, IVUS also provides important qualitative information on luminal morphology, including the presence of atherosclerotic plaque, calcification, fibrous lesions, and intraluminal thrombus. A strong correlation has been identified between arterial lumen diameter measurements performed on histologic specimens and IVUS.

## Perspectives

Planning of the hybrid room is truly an interdisciplinary task<sup>10,12</sup>. Clinicians and technicians of all cardiovascular disciplines should define their requirements and form a responsible planning team. Virtual visualization of the room, visits of established hybrid rooms, and information exchange with experienced users help tremendously during the planning process. In recent literature, a couple of case studies are published for planning hybrid operating room<sup>15,19-21</sup>. Moreover, the European Association of Cardio-Thoracic Surgery (EACTS) and the European Society of Cardiology (ESC), in collaboration with the European Association of Percutaneous Cardiovascular

Interventions (EAPCI) have issued regulations and training guidance for those seeking accreditation to become hybrid cardiovascular surgeon<sup>22</sup>.

In the near future, wireless devices will become reality and will overcome the limitations now present due to wire connection points. Within the vascular hybrid room with wireless connections, the operating table, C-arm, and other equipment could be rotated at full 360° (and beyond) at any location. Wireless technology would also save time in case that one piece of equipment needs to be repaired. A broken piece of equipment can be temporarily removed from the interventional suite and replaced by a spare. The vascular surgeon or interventionist would not lose valuable operation time. Integration of robotic and navigational techniques into clinical practice may lead to improved catheter accuracy, stability, and safety in comparison with conventional techniques, while minimizing radiation exposure. We hope that these would lead to improvement in overall clinical outcomes and further reduce the mortality and morbidity rates associated with managing vascular patients. It is hoped that, as these new fields develop and with increasing experience with these new hybrid methods, we may well be able to maximize the applicability of minimally invasive endovascular and hybrid technology to treat a larger cohort of patients with vascular disease.

## References

1. RATNER DW, PARK A. Advanced devices for the operating room of the future. *Surgical Innovation* 2003;10:85-9.
2. DEXTER F, LEDOLTER J, WACHTEL RE. Tactical decision making for selective expansion of operating room resources incorporating financial criteria and uncertainty in subspecialties' future workloads. *Anesth Analg* 2005;100:1425-32.
3. NAGY PG, KONEWKO R, WARNOCK M, BERNSTEIN W, SEAGULL J, XIAO Y, GEORGE I, PARK A. Novel, web-based, information-exploration approach for improving operating room logistics and system processes. *Surgical Innovation* 2008;15:7-16.
4. OLIVARES M, TERWIESCH C, CASSORLA L. Structural estimation of newsvendor model: an application to reserving operating room time. *Management Science* 2008;54:41-55.
5. MASURSKY D, DEXTER F, NUSSMEIER NA. Operating room nursing directors' influence on anesthesia group operating room productivity. *Anesth Analg* 2008;107:1989-96.
6. ZHOU W, LIN PH, BUSH RL, LUMSDEN AB. Endo-



- vascular training of vascular surgeons: have we made progress. *Semin Vasc Surg* 2006;19:122-6.
7. ELIASON JL, GUZMAN RJ, PASSMAN MA, NASLUND TC. Infected endovascular graft secondary to coil embolization of endoleak: a demonstration of the importance of operative sterility. *Ann Vasc Surg* 2002;16:562-5.
  8. DUCASSE E, CALISTI A, SPEZIALE F, RIZZO L, MISURACA M, FIORANI P. Aortoiliac stent graft infection: current problems and management. *Ann Vasc Surg* 2004;18:521-6.
  9. NICHOLS RL. The operating room. In: BENNETT JV, BRACHMAN PS, SANFORD JP, eds. *Hospital infections*, 3<sup>rd</sup> edition. Boston, MA: Little, Brown, 1992:461-7.
  10. EAGLETON MJ, SCHAFFER JL. The vascular surgery operating room. Development of an up to date vascular room that would meet the up to date demands of the vascular surgery patient and the team. *Endovasc Today* 2007;8:25-30.
  11. GOEL VR, AMBEKAR A, GREENBURG RK. Multimodality imaging and image-guided surgery. Advances in imaging provide physicians with the confidence to confront procedures previously thought impossible. *Endovasc Today* 2008;3:67-70.
  12. SIKKINK CJ, REIJNEN MM, ZEEBREGTS CJ. The creation of the optimal dedicated endovascular suite. *Eur J Vasc Endovasc Surg* 2008;35:198-204.
  13. FILLINGER MF, WEAVER JB. Imaging equipment and techniques for optimal intraoperative imaging during endovascular interventions. *Semin Vasc Surg* 1999;12:315-26.
  14. MANSOUR MA. Endovascular and minimally invasive vascular surgery. The new operating environment. *Surg Clin North Am* 1999;79:477-87.
  15. HODGSON KJ, MATTOS MA, SUMNER DS. Angiography in the operating room: equipment catheter skills and safety issues. In: Yao JST, Pearce WH, eds. *Techniques in vascular surgery*. Stamford, CT: Appleton & Lange, 1997:25-45.
  16. GARRETT HE, ABDULLAH AH, HODGKISS TD, BURGAR SR. Intravascular ultrasound aids in the performance of endovascular repair of abdominal aortic aneurysm. *J Vasc Surg* 2003;37:615-8.
  17. van ESSEN JA, van der LUGT A, GUSSENHOVEN EJ, LEERTOUWER TC, ZONDERVAN P, van SAMBEEK MR. Intravascular ultrasonography allows accurate assessment of abdominal aortic aneurysm: an in vitro validation study. *J Vasc Surg* 1998;27:347-53.
  18. DAVILA-ROMAN VG, PHILLIPS KJ, DAILY BB, DÁVILA RM, KOUCHOUKOS NT, BARZILAI B. Intraoperative transesophageal echocardiography and epiaortic ultrasound for assessment of atherosclerosis of the thoracic aorta. *J Am Coll Cardiol* 1996;28:942-7.
  19. KPODONU J, RAMAIAH VG, DIETHRICH EB. Intravascular ultrasound imaging as applied to the aorta: a new tool for the cardiovascular surgeon. *Ann Thorac Surg* 2008;86:1391-8.
  20. HIRSCH R. The hybrid cardiac catheterization laboratory for congenital heart disease: from conception to completion. *Catheter Cardiovasc Interv* 2008;71:418-28.
  21. PEETERS P, VERBIST J, DELOOSE K, BOSIERS M. The catheterization lab of the future. *Endovasc Today* 2008;3:94-6.
  22. VAHANIAN A, ALFIERI O, AL-ATTAR N, ANTUNES M, BAX J, CORMIER B, CRIBIER A, De JAEGERE P, FOURNIAL G, KAPPETEIN AP, KOVAC J, LUDGATE S, MAISANO F, MOAT N, MOHR F, NATAF P, PIERRARD L, POMAR JL, SCHOFER J, TORNOS P, TUZCU M, van HOUT B, Von SEGESSER LK, WALTHER T. Transcatheter valve implantation for patients with aortic stenosis: a position statement from the European Association of Cardio-Thoracic Surgery (EACTS) and the European Society of Cardiology (ESC), in collaboration with the European Association of Percutaneous Cardiovascular Interventions (EAPCI). *EuroIntervention* 2008 Aug;4(2):193-9.

## Sažetak

## VASKULARNA HIBRIDNA DVORANA – OPERACIJSKA DVORANA BUDUĆNOSTI

*N. Hudorović, S. A. Rogan, I. Lovričević, M. Zovak i S. Schmidt*

U posljednja dva desetljeća primjećuje se pomak u liječenju vaskularnih bolesti od tradicionalno otvorenih kirurških zahvata prema perkutanoj intervenciji cijelog vaskularnog stabla. Niti klasične operativne dvorane, a niti konvencionalne angio dvorane nisu optimalne za izvođenje otvorene operacije ili za endovaskularne zahvate. Glavne značajke vaskularne hibridne operativne dvorane obuhvaćaju kvalitetnu opremu za snimanje, radijacijski štiti, opremu za jednostavnu upotrebu, potrebu za dobro izučanim kadrom, ergonomičnost, mogućnost odvijanja otvorenih i perkutanih zahvata, sterilnu okolinu, kao i kvalitetu i učinkovitost bolesničke skrbi. Najznačajnija značajka rada u hibridnoj vaskularnoj operacijskoj dvorani trebala bi biti mogućnost pružanja najbolje operacije bolesniku s krvožilnom bolešću. Manje je važno tko će opremu upotrebljavati, intervencijski radiolog ili vaskularni kirurg. Uspostava jedne endovaskularne operativne dvorane ima prednost sterilne okoline, mogućnost izvođenja hibridnih zahvata, te ako je potrebno i konverzije. Također, angiografija učinjena neposredno prije operativnog zahvata pruža točnije anatomske informacije, a nakon zahvata pruža bolju kontrolu kvalitete. Posljedično, bolja kvaliteta i usluga može se ponuditi svakom pojedinačnom bolesniku. Takve promjene u liječenju bolesnika s bolešću krvnih žila zahtijevaju i novi profil vaskularnog kirurga nazvan "vaskularni hibridni kirurg" koji mora biti osposobljen u izvođenju endovaskularnih, ali i otvorenih operativnih zahvata kod iznimno složene skupine bolesnika.

*Ključne riječi: Operacijske dvorane – organizacija i administracija; Operacijske dvorane – standardi; Kontrola kvalitete; Vaskularni kirurški zahvati – štetni; Vaskularni kirurški zahvati – učinci; Vaskularni kirurški zahvati – trendovi*