

# HEADACHE AND APHASIA IN A YOUNG WOMAN WITH PROTEIN S DEFICIENCY AND NEPHROTIC SYNDROME

Željko Živanović<sup>1,2</sup>, Kristian Barlinn<sup>1</sup>, Clotilde Balucani<sup>1</sup>, Paola Palazzo<sup>1</sup> and Andrei V. Alexandrov<sup>1</sup>

<sup>1</sup>Comprehensive Stroke Center, University of Alabama Hospital, Birmingham, AL, United States; <sup>2</sup>University Department of Neurology, Clinical Center of Vojvodina, Novi Sad, Serbia

**SUMMARY** – We present sequential brain imaging findings in a young woman who while being evaluated for a newly discovered nephrotic syndrome developed headache followed by aphasia. The patient's symptoms were due to cerebral venous thrombosis in the setting of protein S deficiency and oral contraception.

**Key words:** *Intracranial thrombosis; Diagnostic imaging; Nephrotic syndrome; Protein S deficiency; Corticosteroids*

## Introduction

Cerebral venous thrombosis (CVT) is a rare subtype of stroke (0.5% of all strokes) that develops with hypercoagulability, blood stasis and endothelial damage<sup>1,2</sup>. Clinical presentation of CVT is variable and often mimics other neurological disorders. Progressive or sudden onset headache, seizures, and focal signs are suggestive of CVT<sup>3,4</sup>.

Noninvasive brain imaging techniques can help suspect CVT<sup>5</sup>. Computed tomography (CT) and magnetic resonance imaging (MRI) may visualize so-called venous infarcts, while contrast CT-venogram can confirm the location of intracranial thrombus. Magnetic resonance venography (MRV) could be prone to artifacts due to congenital hypoplasia. Thus, in some cases, catheter angiography may still be required to establish the diagnosis of CVT.

We report on a patient with CVT presenting with headache as the first symptom followed by aphasia three days later.

## Case Report

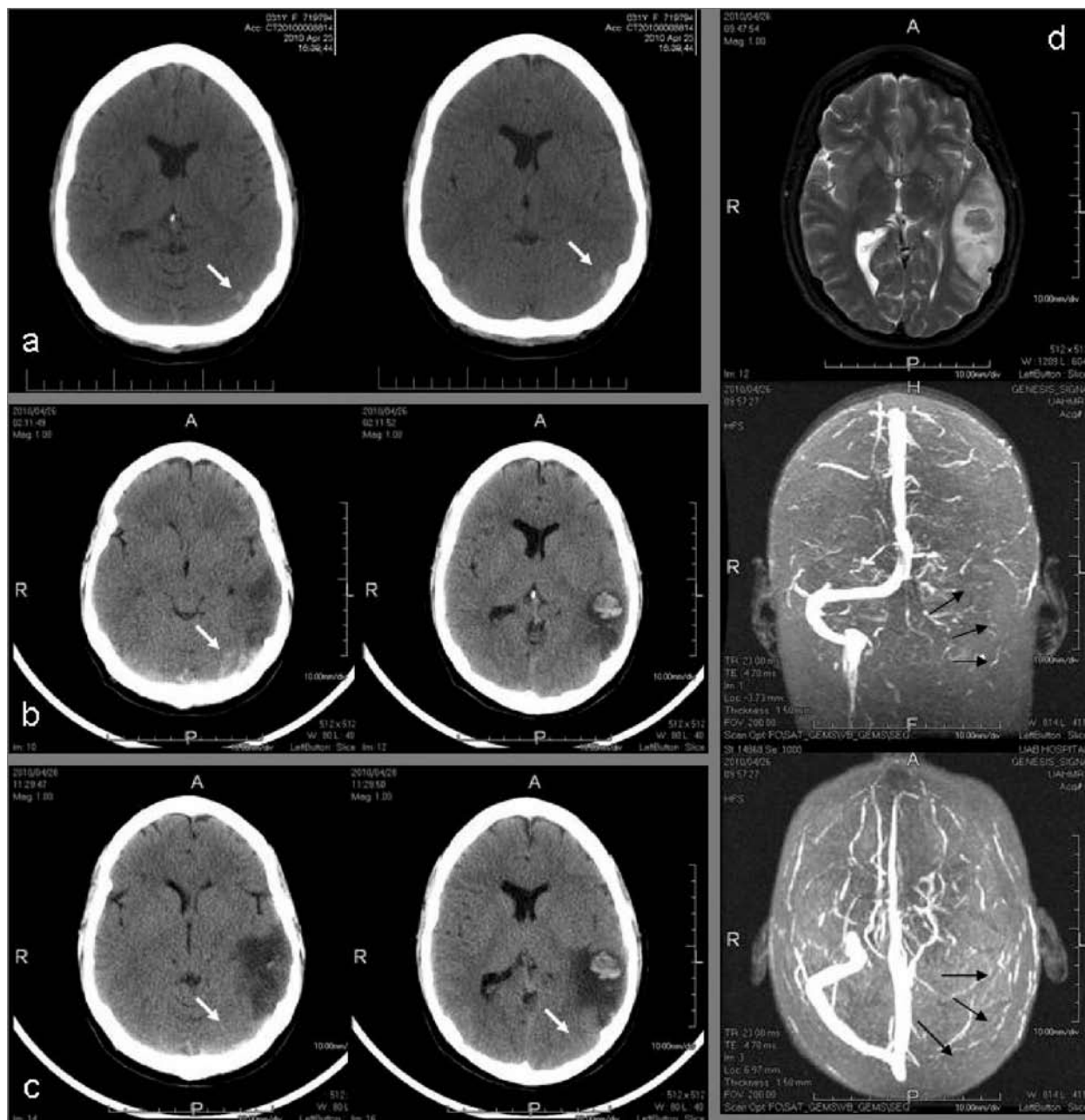
A 31-year-old Caucasian woman with a history of migraine, hypothyroidism, tobacco smoking and birth control pill use developed a sudden onset left-sided headache that lasted for three days. Then the patient's family noticed her having problems with speaking and brought her to the emergency room at an outside hospital. A non-contrast head CT scan was initially described as normal (Fig. 1a) and the patient was admitted. The patient's condition continued to worsen and she was transferred to our Center.

Repeat CT showed left parietotemporal hemorrhage with brain edema, a small hemorrhage along the left tentorial leaflet, and hyperdensity suggestive of a venous thrombus (Fig. 1b). MRI/MRV revealed extensive dural venous thrombosis, cortical vein thrombosis and left tentorial sinus thrombosis (Fig. 1d). Intravenous weight-based heparin was started.

Thyroid hormone tests showed low level of fT3 and high level of thyroid-stimulating hormone (TSH). Anti-thyroid peroxidase (anti-TPO) antibodies were negative. Routine laboratory workup for most common autoimmune diseases was negative. Thrombophilia panel test showed high level of factor VIII, high level of protein C and low level of protein S.

Correspondence to: Željko Živanović, MD, University Department of Neurology, Clinical Center of Vojvodina, Hajduk Veljkova 1, 21000 Novi Sad, Serbia  
E-mail: drzzivanovic@yahoo.com

Received November 12, 2010, accepted November 17, 2011



*Fig. 1. (a) Axial non-contrast head CT scan shows hyperdense left transverse sinus sign (white arrows), which represents a thrombus, initially misinterpreted as thickening of tentorium; (b) subsequent CT shows hematoma in the left temporoparietal cortex with surrounding hypoattenuation and a small hemorrhage along the left tentorial leaflet; thrombosis of the left transverse sinus is more visible (white arrow); (c) head CT on day 3 shows stable left temporal lobe hemorrhage with slightly worsening edema and decrease in hyperdensity of the left transverse sinus (white arrows); (d) T2/FLAIR shows hyper-intensity within the left temporoparietal region (hematoma). Intracranial time-of-flight venogram images demonstrate complete loss of flow-related signal within the left jugular vein and bulb, sigmoid, transverse sinuses, and left tentorial sinus thrombosis (black arrows).*

Basic metabolic panel and cell blood count were unremarkable. Estimated sedimentation rate was highly prolonged (93 mm/h). Hepatic function panel test documented low total proteins and albumin. Urinalysis showed significant proteinuria (>300). Because of constellation of proteinuria, hypoalbuminemia and hyperlipidemia, a nephrotic syndrome was considered and surgical biopsy of her right kidney was performed prior to this admission. Pathological findings were consistent with minimal change disease (lipoid nephrosis) and the nephrology service recommended to start prednisone 80 mg daily.

At this time, the patient had already been treated with heparin for three days and showed no significant speech improvement. A few hours after taking 80 mg prednisone orally, the patient started to name objects correctly and began to speak in simple sentences. The patient was discharged two days later with mild expressive aphasia on low molecular weight heparin-to-coumadin bridge.

## Discussion

Our case demonstrates an initially normal CT scan in terms of brain parenchyma visualization and hyperdense venous thrombus sign that was likely and erroneously attributed to tentorium appearance. Greater suspicion of CVT could have prompted faster transfer and treatment.

Our case also raises the possibility that a high dose steroid treatment given for a concurrent condition could have helped reduce brain edema and foster neurological recovery. Guidelines do not recommend routine use of steroids in general CVT population, since clinical studies did not confirm long term benefit and

pointed to a potential harm<sup>6</sup>. On the other hand, the role of steroids in stroke may be reduced to a relatively short window when vasogenic edema could exist, and this has not been studied properly neither in the setting of ischemic stroke nor CVT<sup>7</sup>.

Our patient had clear and multiple risk factors that predisposed to CVT. Physicians should be aware of CVT and facilitate multi-modal neuroimaging to detect this condition early.

## References

1. BOUSSER MG, FERO JM. Cerebral venous thrombosis: an update. *Lancet Neurol* 2007;6:162-70.
2. LIJFERING WM, BROUWER JL, VEEGER NJ, BANK I, COPPENS M, MIDDELDORP S, HAMULYÁK K, PRINS MH, BÜLLER HR, van der MEER J. Selective testing for thrombophilia in patients with first venous thrombosis: results from a retrospective family cohort study on absolute thrombotic risk for currently known thrombophilic defects in 2479 relatives. *Blood* 2009;113:5314-22.
3. BERGUI M, BRADAC GB. Clinical picture of patients with cerebral venous thrombosis and patterns of dural sinus involvement. *Cerebrovasc Dis* 2003;16:211-6.
4. WASAY M, KOJAN S, DAI AI, BOBUSTUC G, SHEIKH Z. Headache in cerebral venous thrombosis: incidence, pattern and location in 200 consecutive patients. *J Headache Pain* 2010;11:137-9.
5. RIZZO L, CRASTO SG, RUDÀ R, GALLO G, TOLA E, GARABELLO D, De LUCCHI R. Cerebral venous thrombosis: role of CT, MRI and MRA in the emergency setting. *Radiol Med* 2010;115:313-25.
6. EINHÄUPL K, STAM J, BOUSSER MG, de BRUIJN SF, FERRO JM, MARTINELLI I, MASUHR F. EFNS guideline on the treatment of cerebral venous and sinus thrombosis in adult patients. *Eur J Neurol* 2010;17:1229-35.
7. NORRIS JW. Steroids may have a role in stroke therapy. *Stroke* 2004;35:228-9.

## Sažetak

### GLAVOBOLJA I AFAZIJA U MLADE ŽENE S NEDOSTATKOM PROTEINA S I NEFROTSKIM SINDROMOM

Ž. Živanović, K. Barlinn, C. Balucani, P. Palazzo i A. V. Alexandrov

Predstavljamo sekvencijski nalaz slikovnog prikaza mozga mlade žene kod koje je tijekom kliničke evaluacije novotkrivenog nefrotskog sindroma došlo do pojave glavobolje praćene afazijom. Simptomi su bili uzrokovani cerebralnom venskom trombozom koja se razvila uslijed nedostatka proteina S i uporabe oralnih kontraceptiva.

Cljučne riječi: *Intrakranijska tromboza; Slikovna dijagnostika; Nefrotski sindrom; Protein S, nedostatak; Kortikosteroidi*

