

VETERINARSKI ARHIV 82 (3), 311-318, 2012

## Laparoscopic ovariohysterectomy in a bitch with endometrial hyperplasia - a case report

Tugomir Karadjole<sup>1\*</sup>, Nino Maćešić<sup>1</sup>, Goran Bačić<sup>1</sup>, Ana Beck<sup>2</sup>, Ivan Folnožić<sup>1</sup>,  
Nikica Prvanović<sup>1</sup>, Martina Karadjole<sup>1</sup>, and Stjepan Višnjić<sup>3</sup>

<sup>1</sup>*Clinic for Reproduction and Obstetrics, Faculty of Veterinary Medicine, University of Zagreb, Zagreb, Croatia*

<sup>2</sup>*Department for Veterinary Pathology, Faculty of Veterinary Medicine, University of Zagreb, Zagreb, Croatia*

<sup>3</sup>*Children's Hospital Zagreb, University Hospital Center „Sestre Milosrdnice“, Zagreb, Croatia*

---

**KARADJOLE, T., N. MAĆEŠIĆ, G. BAČIĆ, A. BECK, I. FOLNOŽIĆ, N. PRVANOVIĆ, M. KARADJOLE, S. VIŠNJIĆ: Laparoscopic ovariohysterectomy in a bitch with endometrial hyperplasia - a case report. Vet. arhiv 82, 311-318, 2012.**

### ABSTRACT

A crossbreed bitch, one year old, was brought to the Obstetrics and Reproduction Clinic at the Faculty of Veterinary Medicine, University of Zagreb for elective castration. From the history, the bitch had last been on heat three months before and did not mate. Clinical examination was performed before surgery, the health status and condition of the animal were good and at the owner's request no preoperative diagnostic methods were performed. Laparoscopic ovariohysterectomy of the enlarged uterus was performed under general inhaled anesthesia. The pathohistological finding was segmental endometrial hyperplasia of the uterus. According to this case report laparoscopic ovariohysterectomy is safe and effective in bitches with small to moderate enlargement of the uterus.

**Key words:** bitch, laparoscopy, endometrial hyperplasia

---

### Introduction

In veterinary medicine the first laparoscopic procedure was performed in 1985, sterilization of a bitch by ligation of the uterine horns (WILDT and LAVLER, 1985; LHERMETE and SOBEL, 2008). Veterinary laparoscopic surgery has largely been developed in equine medicine rather than in small animals (MINAMI et al., 1997). In horses laparoscopic surgery is applied for observation, biopsy of the abdominal organs,

---

\*Corresponding author:

Assist. Prof. Tugomir Karadjole, PhD, DVM, Clinic for Reproduction and Obstetrics, Faculty of Veterinary Medicine, University of Zagreb, Heinzelova 55, 10000 Zagreb, Croatia, Phone: +385 1 2390 167; Fax: +385 1 2441 390; E-mail: ktugomir@vef.hr

evaluation of colic cases, hernia repair, reproductive surgery, and urological and digestive surgery (FISCHER, 2002). In small animals the surgical procedures that can be performed using laparoscopy are: abdominal organs biopsy, gastropexy, feeding tube placement, ovariectomy and laparoscopic assisted ovariohysterectomy and cryptorchidectomy (LHERMETE and SOBEL, 2008). Due to minor tissue injury, laparoscopic surgery, as a minimal invasive procedure is thought to reduce the neuroendocrine, immunologic and metabolic response of the organism compared to laparotomic surgery (FREEMAN, 1999).

The present paper reports the accidental finding of an enlarged uterus (endometrial hyperplasia) in a bitch presented for castration, and successful laparoscopic ovariohysterectomy.

### **Materials and methods**

*Case history.* A 1-year-old mongrel bitch was presented at the Clinic of Obstetrics and Reproduction, the Faculty of Veterinary Medicine, University of Zagreb for elective castration. The owner of the bitch was an animal shelter (asylum). The last estrus was 3 months before, with no mating or previous litters. The body mass was 17 kg.

*Clinical finding.* Physical examination revealed a slightly elevated body temperature (39.1 °C). The pulse rate was 92/min, respiration rate 20/min, the mucous membrane was pink, CRT < 2 seconds. Further examinations (blood and laboratory testing) were not performed at the owner's request.

*Surgery.* Food was withheld for 16 hours and water for 4 hours prior to surgery. Premedication was achieved with methadone 0.5 mg/kg i/m (Heptanon® Pliva) and midazolam 0.2 mg/kg i/m (Dormicum®, F. Hoffmann-La Roche). A venous catheter was placed in the cephalic vein for the induction of anesthesia with continuous infusion of isotonic saline solution during the surgery. After 30 minutes anesthesia was induced with propofol 4 mg/kg i/v (Propofol 1%® Fresenius Kabi). The bitch was intubated and anesthesia was maintained with 2% isoflurane (Forane® Abbott Laboratories Ltd) in oxygen. Tidal volume was 12 mL/kg and mechanical ventilation with ventilator rate adjusted for ET<sub>CO<sub>2</sub></sub> (End Tidal CO<sub>2</sub>) between 25-35 mmHG (12 respiration/minute with I:E 1:2). Analgesia was achieved with fentanyl 0.003 mg/kg i/v (Fentanyl-Janssen® Janssen-Cilag). During anesthesia ECG, heart rate, respiratory rate, noninvasive blood pressure, SpO<sub>2</sub> (Oxygen Saturation), ET<sub>CO<sub>2</sub></sub>, body temperature was monitored. The bitch was restrained in dorsal recumbency and the surgical field was prepared in the standard manner for all abdominal operations.

A Veress needle was placed in a 1 cm skin incision next to the umbilicus and a pneumoperitoneum was established using the closed technique through carbon dioxide insufflations (Fig. 1). After the Veress needle was removed we placed a primary 10/12 mm trocar (Karl Storz Metall trocar) in the same incision and pneumoperitoneum was

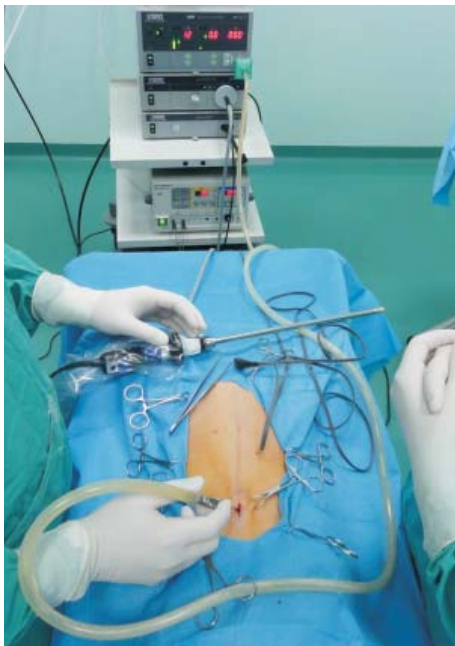

Fig. 1. Establishment of pneumoperitoneum with a Veress needle

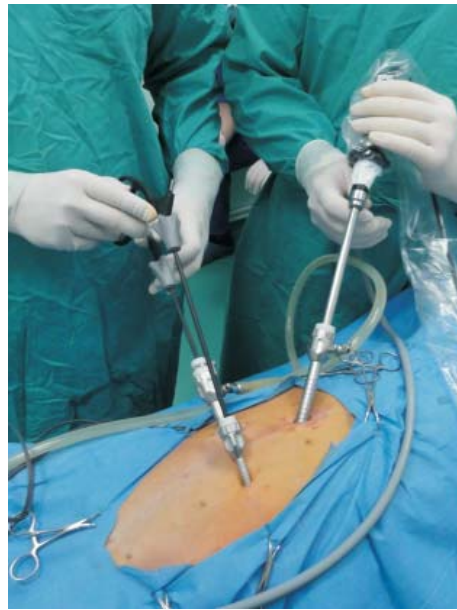

Fig. 2. Position of the trocars

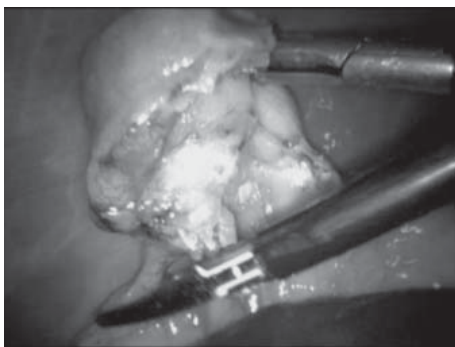


Fig. 3. Coagulation and transaction of the mesovarium with bipolar forceps

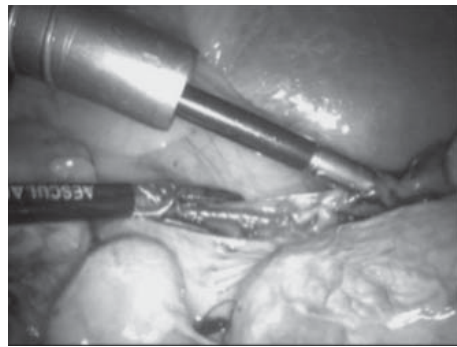


Fig. 4. Coagulation of the uterine arteries and veins

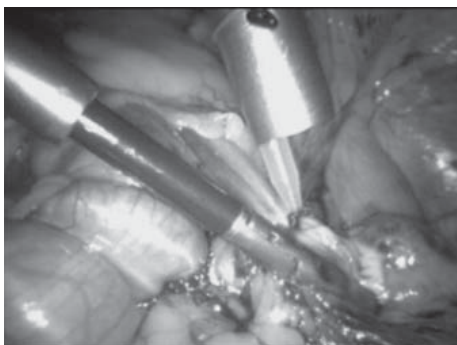


Fig. 5. Positioning and tightening of the Endoloop

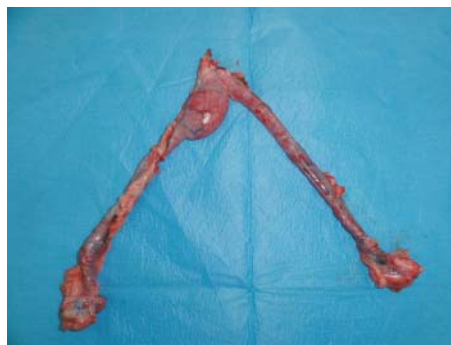

Fig. 6. Amputated enlargement of the uterus

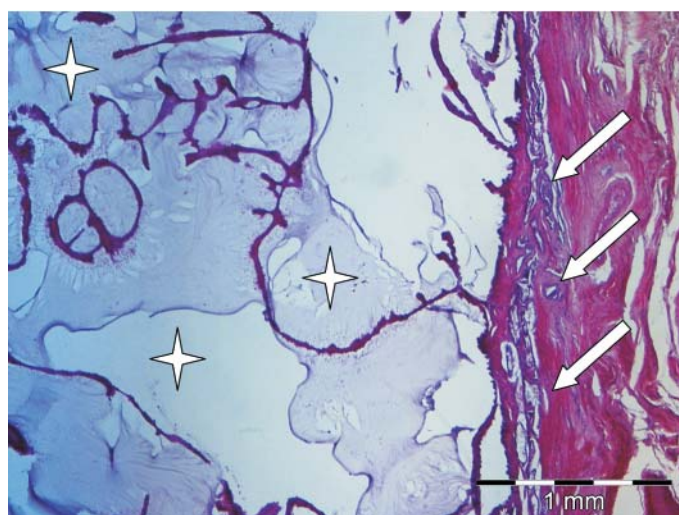


Fig. 7. Transversal segment of the uterine horn, H&E,  $\times 4$

The endometrium consists of numerous cystic structures filled with mucous and necrotic debris (asterisk). The cyst walls are lined with a single layer of secretory epithelial cells attached on thin fibrovascular bands. Glands in the deeper area of the endometrium have normal architecture (arrows).

maintained at 12 mmHg by an insufflation device (Karl Storz Electronic Endoflator). A 10 - mm laparoscope (Olympus Germany angle 0°) with a video camera (Karl Storz Telecam DX II) and light source (Karl Storz Xenon Nova) was inserted through the primary trocar. After abdominal exploration, an enlarged right uterine horn (5 cm in diameter, 5 -10 cm in length) was diagnosed.

After abdominal exploration through the primary trocar we placed two secondary 5 and 10/12 mm ports (Karl Storz Metall trocar). Secondary trocars were placed lateral to the mammary glands and halfway between the umbilicus and pubis (Fig. 2). The surgery was observed on a video monitor (Panasonic Viera LCD) placed opposite the operating table. Two grasping forceps (Aesculap Atraumatic Fixation Forceps Sovereign Quick-Snap) were passed through the lateral ports. First, the left ovary was elevated and the mesovarium with the suspensory ligament was coagulated with bipolar forceps (Aesculap Bipolar Ad Tec Combi) with an electro generator (Olympus UES-20) and transected (Fig. 3). The broad and round ligament was transected with bipolar forceps. The uterine arteries and uterine body were coagulated with bipolar forceps (Fig. 4). The same procedure was repeated on the right ovary and uterine horn. An Endoloop (Ethicon Endoloop Ligature Type - 0 PDS II) was introduced through a lateral port (Fig. 5). We passed grasping forceps through the suture loop and grasped one ovary and uterine horn through the loop. The second ovary with the uterine horn was treated in the same fashion. The loop was positioned cranial to the cervix and tightened firmly. The uterine body was transected with scissors (Aesculap Metzenbaum Scissors TC). The laparoscope was transferred from the umbilical port to 10 mm lateral port. Through the umbilical port grasping forceps were introduced and one ovary was fixed. Due to the uterus enlargement, the umbilical incision was extended (2 cm) and then the ovary, uterus and trocar were removed in a linear fashion. After the trocars had been removed, the muscles, subcutaneous tissue and skin were sutured in the standard fashion.

The animal was released home within a few hours after surgery and did not show any signs of pain or altered general condition after surgery. The uterus was submitted for pathohistology. Representative tissue samples collected during the ovariectomy procedure were fixed in 10% neutral buffered formalin. Paraffin sections 3 to 5 mm thick were cut, and stained with hematoxylin and eosin (H&E) for routine microscopic evaluation. Microscopic analyses showed that the expanded segment of the uterus was due to segmental endometrial hyperplasia consisting of localized proliferation of the endometrial glands forming a 3.5 cm long continuous band of protruding tissue. The superficial endometrial epithelium was severely necrotic (Fig. 6 and 7).

## Discussion

Reviewing the literature, we only found data about assisted laparoscopic ovariohysterectomy in bitches with pyometra, and no data about laparoscopic ovariohysterectomy in a bitch with pathological disorders of the uterus and ovaries. MINAMI et al. (1997) performed assisted laparoscopic ovariohysterectomy in two bitches with pyometra. They performed a mini laparotomic incision, prepared the ovaries in the abdomen and after that continued and finished surgery as per laparotomic (classic, open) ovariohysterectomy.

MINAMI et al. (1997) reported the advantages of assisted laparoscopic ovariohysterectomy in the treatment of pyometra compared to laparotomic surgery due to the smaller incision in the abdominal wall and better recovery. The authors emphasized that these two assisted laparoscopic ovariohysterectomies were the first performed in this way in veterinary medicine.

COLLARD and VIGUIER (2008) performed laparoscopic ovariohysterectomy in a 15 year old poodle bitch with “open” pyometra confirmed by ultrasonography. Intra-abdominally, they transected both suspensory ligaments cranially to caudally by coagulating the tissue and vessels with a monopolar scalpel. They performed a skin incision cranial to the pubis and the linea alba. The ovaries and uterine horns were drawn out through this opening. The uterine arteries and uterus were ligated and resected.

In our case surgery was performed by the laparoscopic method through three minimal (5-10 mm) incisions in the abdominal wall. We performed laparoscopic ligation and resection of the ovaries and uterine body completely in the abdominal cavity, which is different to MINAMI et al. (1997) and COLLARD and VIGUIER (2008).

The surgical procedure lasted 85 minutes in COLLARD and VIGUIER, 2008, and the mean time of the procedure is 120 minutes (DAVIDSON et al., 2004) compared to our case which lasted 55 minutes. Laparoscopy is more challenging for a surgeon but for the patient is undeniable better. Complications associated with laparoscopy are fewer than those encountered with laparotomy, and most of these complications are edema and inflammation around the area of port introduction, leakage or wound dehiscence (DEVITT et al., 2005; VAN GOETHEN et al., 2003).

MINAMI et al. (1997) reported some disadvantages of laparoscopic surgery. Surgical time is often prolonged and viscera could be injured by a trocar.

WILSON et al. (2004) reported that dogs must be anesthetized with propofol or ketamin for laparoscopic surgery, because these anesthetics cause no or little splenic enlargement, which limits the risk of spleen injury during port introduction. In our case the bitch was anesthetized with propofol.

The pathohistological finding of the removed uterus was segmental endometrial hyperplasia, which rarely occurs in a young bitch.

Cystic endometrial hyperplasia - pyometra complex is an acute or chronic post-oestral disease of intact adult bitches, leading to an inflammatory exudate in the uterus associated with variable clinical and pathological signs (DOW, 1957).

ROBERTS (1986), ANDERSEN and SIMPSON (1973) report that cystic endometrial hyperplasia is caused by repeated exposure of the endometrium to progesterone. The 2 month duration of diestrus predisposes this species to cystic endometrial hyperplasia.

DOW (1957, 1958, and 1959) described four stages of cystic endometrial hyperplasia - pyometra complex (CEH). Type I is uncomplicated CEH, where the endometrium has a cobblestone appearance with thickening and many cystic irregular elevations covering the endometrial surface. Histologically there is an increase in the number of glandular elements throughout the endometrium. Cysts are evenly distributed over the endometrial surface. Type II is CEH with diffuse infiltration of plasma cells. Histologically tissue destruction is not visible. Type III is CEH with overlying acute endometritis. Areas of endometrial ulceration and hemorrhage may be grossly visible, and intrauterine discharge varying in color from red-brown to yellow green may be present. Type IV is CEH with chronic endometritis. If the cervix is open, allowing drainage of intrauterine fluid, the endometrium is atrophied and myometrium is hypertrophied and fibrotic. If the cervix is closed, the uterine horns are distended with purulent fluid. Marked atrophy of the endometrium and myometrium are present.

### **Conclusion**

This case report describes the laparoscopic ovariohysterectomy of segmental endometrial hyperplasia in a bitch. This method is safe and effective in a bitch with small to moderate enlargement of the uterus.

### **References**

- ANDERSEN, A. C., M. E. SIMPSON (1973): The Ovary and Reproductive Cycle of the dog (beagle). Geron-X Edition. Los Altos. pp. 266-268.
- COLLARD, F., E. VIGUIER (2008): A pyometra managed by laparoscopic ovariohysterectomy in a dog. *Revue Med. Vet.* 12, 624-627.
- DAVIDSON, E. B., H. D. MOLL, M. E. PAYTON (2004): Comparison of laparoscopic ovariohysterectomy and ovariohysterectomy in dogs. *Vet. Surg.* 33, 62-69.
- DEVITT, C. M., R. E. COX, J. J. HAILEY (2005): Duration, complications, stress, and pain of open ovariohysterectomy versus a simple method of laparoscopic-assisted ovariohysterectomy in dogs. *J. Am. Vet. Med. Assoc.* 227, 921-927.
- DOW, C. (1957): The cystic hyperplasia - pyometra complex in the bitch. *Vet. Rec.* 69, 1409-1415.

- DOW, C. (1958): The cystic hyperplasia - pyometra complex in the bitch. *Vet. Rec.* 70, 1102-1108.
- DOW, C. (1959): The cystic hyperplasia - pyometra complex in the bitch. *J. Comp. Pathol.* 69, 237-250.
- FISHER, A. T. (2002): *Equine Diagnostic and Surgical Laparoscopy*. Saunders. Philadelphia, London, New York, St. Louis, Sydney, Toronto. pp. 3-5.
- FREEMAN, L. J. (1999): *Veterinary Endosurgery*. Mosby. St. Louis. IX - XVI.
- LHERMETTE, P., D. SOBEL (2008): Rigid endoscopy: Laparoscopy. In: *BSAVA Manual of Canine and Feline Endoscopy and Endosurgery*. (Lhermette, P., D. Sobel, Eds.). British Small Animal Veterinary Association. Gloucester. pp. 158-173.
- MINAMI, S., Y. OKAMOTO, H. EGUCHI, K. KATO (1997): Successful laparoscopy assisted ovariohysterectomy in two dogs with pyometra. *J. Vet. Med. Sci.* 59, 845-847.
- ROBERTS, S. J. (1986): Infertility and reproductive diseases in bitches and queens. In: *Veterinary Obstetrics and Genital Diseases* 3<sup>rd</sup> ed. (Roberts, S. J., Ed.). Woodstock, VT. pp 709-751.
- VAN GOETHEN, B. E., K. W. ROSENVELDT, J. KIRPENSTEIJN (2003): Monopolar versus bipolar electrocoagulation in canine laparoscopic ovariectomy: a nonrandomized, prospective, clinical trial. *Vet. Surg.* 32, 464-470.
- WILDT, D. E., D. F. LAVLER (1985): Laparoscopic sterilization of the bitch and queen by uterine horn occlusion. *Am. J. Vet. Res.* 46, 864-869.
- WILSON, D. V. A. T. EVANS, R. E. CARPENTER (2004): The effect of four anesthetic protocols on splenic size in dogs. *Vet. Anaesth. Analg.* 31, 102-108.

Received: 8 April 2011

Accepted: 4 November 2011

---

**KARADJOLE, T., N. MAČEŠIĆ, G. BAČIĆ, A. BECK, I. FOLNOŽIĆ, N. PRVANOVIĆ, M. KARADJOLE, S. VIŠNJIĆ: Laparoscopska ovariohisterektomija kuje sa segmentalnom hiperplazijom endometrija - prikaz slučaja. *Vet. arhiv* 82, 311-318, 2012.**

**SAŽETAK**

Kuja križane pasmine u dobi od godinu dana dovedena je na Kliniku za porodništvo i reprodukciju Veterinarskoga fakulteta u Zagrebu na elektivnu kastraciju. Kuja je vlasništvo azila za životinje. Iz anamneze se doznalo da je zadnji estrus bio prije 3 mjeseca te da se kuja nije parila. Kliničkim pregledom nisu ustanovljena nikakva odstupanja općeg stanja životinje, a na zahtjev vlasnika nisu učinjene nikakve prijeoperativne dijagnostičke metode. U općoj inhalacijskoj anesteziji učinjena je laparoscopska ovariohisterektomija ampulasto povećane maternice. Patohistološki dijagnosticirana je hiperplazija endometrija. Pregledom literature nismo našli podataka o laparoscopskoj ovariohisterektomiji kuje s patološki promijenjenom maternicom, osim tri slučaja laparoscopski asistirane ovariohisterektomije kuja s piometrom. Ovim slučajem prikazano je da je laparoscopska ovariohisterektomija sigurna operacija u kuja s blago do srednje patološki povećanom maternicom.

**Ključne riječi:** kuja, laparoscopska, hiperplazija endometrija

---