

Case Report

Adult-Type Rhabdomyoma of the Larynx: Clinicopathologic Study of an Uncommon Tumor in a Rare Location

Giancarlo Altissimi,¹ Massimo Ralli,² Giulio Sementilli,¹ Francesco Fiorentino,³ Andrea Ciofalo,¹ Antonio Greco,¹ Marco de Vincentiis,¹ Alessandro Corsi,³ and Giancarlo Cianfrone¹

¹Department of Sense Organs, Sapienza University of Rome, Rome, Italy

²Department of Oral and Maxillofacial Sciences, Sapienza University of Rome, Rome, Italy

³Department of Molecular Medicine, Sapienza University of Rome, Rome, Italy

Correspondence should be addressed to Massimo Ralli; massimo.ralli@uniroma1.it

Received 6 September 2017; Accepted 26 October 2017; Published 26 November 2017

Academic Editor: Marco Berlucchi

Copyright © 2017 Giancarlo Altissimi et al. This is an open access article distributed under the Creative Commons Attribution License, which permits unrestricted use, distribution, and reproduction in any medium, provided the original work is properly cited.

Rhabdomyoma is an uncommon benign mesenchymal tumor with skeletal muscle differentiation that may occur either in the heart or in extracardiac sites. Even though the head and neck region is the most common area of extracardiac rhabdomyoma, the larynx is rarely involved. We present the case of an 85-year-old woman who reported a 10-day history of breathing difficulties, dysphagia, and dysphonia. A computed tomography scan of the head and neck showed a contrast-enhanced, solid hypopharyngeal-laryngeal neoplasm with well-defined margins causing subtotal obliteration of the right pyriform sinus and a reduction in air lumen of the laryngeal vestibule. The patient underwent complete endoscopic removal of the lesion; histologic examination revealed an adult-type rhabdomyoma based on the histologic features and the immunoreactivity of the neoplastic cells for desmin, myoglobin, and muscle-specific actin but not for cytokeratin, S-100, CD68R, chromogranin-A, and synaptophysin. Since clinical and imaging features are not specific for rhabdomyoma, histologic examination and immunohistochemical analyses play a central role in the differential diagnosis of the adult-type rhabdomyoma from other laryngeal neoplasms. A correct diagnosis is mandatory to avoid inappropriate treatment.

1. Introduction

Rhabdomyoma (RM) is an uncommon benign mesenchymal tumor showing skeletal muscle differentiation that may occur in cardiac and extracardiac locations [1]. Cardiac RM is considered a hamartomatous lesion that usually occurs in children with phakomatosis, such as tuberous sclerosis. In contrast, extracardiac RM is usually sporadic and may present at all ages. Depending on the degree of differentiation and the site of development, extracardiac RM is classified into foetal-, adult- and genital-type [1–3]. The foetal-type RM exhibits immature skeletal muscle differentiation and typically occurs as a solitary lesion in children. The adult-type RM exhibits mature skeletal muscle differentiation, occurs in adulthood with a median age of 60 years,

and is usually, but not invariably, solitary. The genital-type RM shows an advanced degree of skeletal muscle differentiation and typically presents as a solitary lesion in the vagina, vulva, and cervix and, rarely, in the paratesticular region and epididymis of middle-aged patients. In terms of molecular genetics, both adult- and foetal-type RM have been associated with basal cell naevus syndrome and activation of the sonic hedgehog pathway [4, 5]. A t(15;17)(q24;p13) has been reported in one case of adult-type RM [6].

Even though the head and neck region is the most common area of extracardiac RM [1–3], this tumor is extremely rare in the larynx [7–38]. For this reason, we describe the clinicopathologic features of an adult-type RM of the larynx diagnosed in an 85-year-old woman and review the pertinent literature with the specific aim to assess the

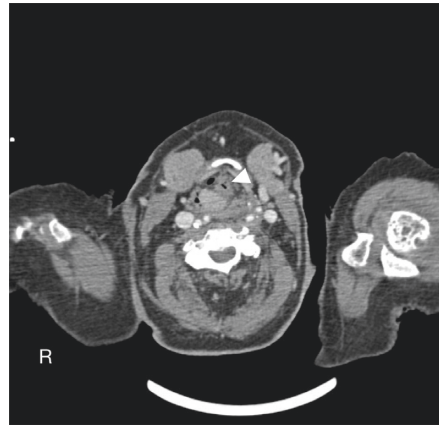


FIGURE 1: Contrast-enhanced computed tomography scan of the neck shows a large ($18 \times 22 \times 12$ mm) solid hypopharyngeal-laryngeal mass with well-defined margins, originating from the right pyriform sinus with partial contralateral extension (white arrow).

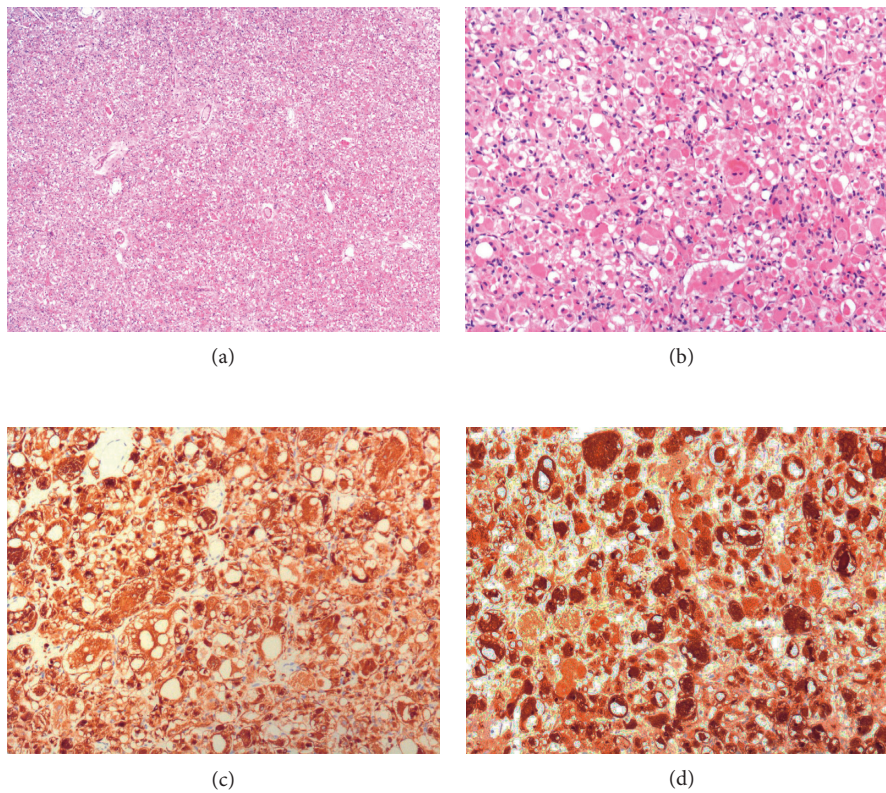


FIGURE 2: (a) Low- and (b) high-power magnification of tumor sections stained with haematoxylin and eosin. The neoplastic cells are diffusely positive for (c) desmin and (d) myoglobin.

diagnostic and therapeutic standards for this uncommon tumor that are invariably necessary to avoid erroneous diagnosis and inappropriate treatment.

2. Case Presentation

An 85-year-old woman was referred to our institution with a 10-day history of breathing difficulties, dysphagia for solids and liquids, and dysphonia. The patient was a former smoker (20 cigarettes/day for 45 years until the age of 60), while no alcohol intake was reported. The patient's medical history

was positive for chronic obstructive pulmonary disease, hypertension, anaemia, osteoporosis, goitre, and chronic renal failure.

General otolaryngological examination was normal. Endoscopy revealed a submucosal lesion in the right arytenoid, covered with normal mucosa, extending towards the right pyriform sinus. The right vocal cord was fixed while the left was hypomobile, thus reducing breathing space. There was no clinical evidence of cervical lymphadenopathy. A computed tomography (CT) scan of the head and neck showed a contrast-enhanced, solid hypopharyngeal-laryngeal

TABLE 1: Clinical comparative synopsis of our case with the other cases of adult-type RM of the larynx reported in the literature, including the present case.

Ref.	Age/gender Location	Chief complaint Duration of symptoms	Treatment
[7]	48/M R vocal fold	Hoarseness 3 months	Endoscopic excision
[8]	55/M L transglottic area	Hoarseness 3 years	Laryngofissure Local excision
[9]	52/F R false vocal fold	Hoarseness 3 years	Endoscopic excision
[11]	55/M R false vocal fold	NA	Endoscopic excision
[12]	64/F R ventricle	Hoarseness, foreign-body sensation 6 months	Endoscopic excision
[13]	39/M Vocal fold	Hoarseness 3 years	Endoscopic excision
[14]	76/F L true vocal fold	Hoarseness 2 months	Endoscopic excision
[15]	16/M R transglottic area	Acute airway obstruction Sudden onset	Tracheotomy Total laryngectomy
[17]	52/M L vocal fold	Hoarseness 6 months	Lateral pharyngotomy
[17]	66/M R vocal fold	Hoarseness 8 years	Excision
[18]	51/F Both arytenoid cartilages	Dyspnoea, dysphagia NA	External removal
[21]	51/M L ventricular fold	Hoarseness, snoring 1 year	Hemilaryngectomy
[22]	64/M L aryepiglottic fold	R asymptomatic submandibular mass	Cervical approach and L lateral pharyngotomy
[23]	69/F Vocal fold	Hoarseness 5 years	Endoscopic excision
[24]	39/M L-sided paraglottic space	Dysphagia and weight loss 5 months	Resection
[25]	66/M Arytenoid	Hoarseness and dysphagia 4 months	External removal
[26]	79/M R false vocal fold	Hoarseness 5 years	External removal
[27]	69/M Epiglottis (multifocal)	R asymptomatic submandibular mass	External removal
[28]	35/M Extrinsic laryngeal muscles	Cervical bulging NA	Resection
[29]	66/M R arytenoid	Dysphagia and hoarseness 3 years (sudden dyspnea)	Endoscopic excision
[30]	72/F L aryepiglottic fold (multifocal)	Globulus and hoarseness 1 year	Endoscopic excision
[31]	50/F R glossoepiglottic fold and vocal fold	NA	Exeresis with CO ₂ laser
[32]	76/M Arytenoid	Hoarsness, dysphagia and sleep-apnoea NA	Multiple endoscopic multiple debulking procedures
[33]	NA/NA Glottis	Dysphonia NA	Endoscopic excision
[34]	55/M L paraglottic space (multifocal)	Hoarseness and slight dysphagia 3 months	Endoscopic excision
[35]	35/M L supraglottic space	Hoarseness 1 year	Endoscopic excision

TABLE 1: Continued.

Ref.	Age/gender Location	Chief complaint Duration of symptoms	Treatment
[36]	67/F Supraglottis	Hoarseness and progressive dyspnea NA	Hemilaryngectomy
[37]	50/M R aryepiglottic fold	Change in voice 2 years	Total laryngectomy
[38]	75/M R vocal fold	Hoarsness 4 years	Endoscopic excision
Present case	85/F R arytenoid	Sudden breathing difficulties, dysphagia 10 days	Endoscopic excision

R: right, L: left, NA: not available.

neoplasm with well-defined margins, originating from the right pyriform sinus with partial contralateral extension. The mass measured 18 × 22 × 12 mm and extended caudally to the right arytenoid and the upper margin of the cricoid cartilage, causing subtotal obliteration of the right pyriform sinus and a reduction in air lumen of the laryngeal vestibule. Other laryngeal structures were preserved (Figure 1).

The patient underwent complete endoscopic removal of the lesion and temporary tracheostomy for respiratory distress; tracheostomy was closed 32 days later. Neither postoperative complications nor signs of recurrence during an 18-month follow-up were observed.

Histologic examination of the neoplasm revealed a well-circumscribed, not encapsulated, proliferation of large closely packed neoplastic round to polygonal cells in a scant stroma (Figures 2(a) and 2(b)). The cells showed a deeply eosinophilic focally vacuolated cytoplasm and round, predominantly central, nuclei, at times with prominent nucleolus. In some cells, multiple nuclei were found. Cells with a peripheral cytoplasmic clear zone traversed by thin cytoplasmic strands extending from the more central acidophilic cytoplasm to the periphery (so-called “spider” cells) were detected as well. Mitotic activity and necrosis were absent. Neoplastic cells were immunoreactive for desmin (Figure 2(c)), myoglobin (Figure 2(d)), and muscle-specific actin. Immunohistochemical staining for cytokeratin (CKAEAE3 and CKMNF116), S-100 protein, CD68R, chromogranin-A, and synaptophysin failed to stain the neoplastic cells. Based on the histologic and immunohistochemical features, a diagnosis of adult-type RM of the larynx was made.

3. Discussion

About 90% of extracardiac RMs occur in the head and neck region [1–3,17]. Even though usually solitary, multifocal lesions have been described as well [27, 34]. The pharynx and oral cavity are the most commonly involved sites, while the larynx is an extremely rare location. Only twenty-three well-documented cases of RM of the larynx were reported in a review of the literature published in 1995 by Johansen; of these, 12 were adult-type laryngeal RM, 3 were adult-type multifocal RM, 4 were foetal cellular RM, and 4 were foetal myxoid RM [21]. Since then, no more than twenty other cases of adult-type RM have been

published. A comprehensive list of adult-type laryngeal RMs reported in the literature is summarized in Table 1.

In the larynx, adult-type RM usually occurs as a solitary lesion in adulthood, is more frequent in men than in women, and more frequently involves the glottic and supraglottic regions [7–38]. In our case, the oldest patient in which an adult-type RM has been reported, the tumor involved primarily the arytenoid, an uncommon site of development for this neoplasm [18, 24, 28, 29, 31]. These tumors grow slowly as a submucosal painless swelling that progressively leads to hoarseness, foreign-body sensation, dysphagia, and dyspnea [3, 21]. Even though the duration of symptoms is usually long (typically years), airway obstruction and dyspnea may develop suddenly [15, 19]. In our case, the patient presented with a 10-day history of breathing difficulties, dysphagia for solids and liquids, and dysphonia. Imaging findings usually suggest a benign lesion because of submucosal location and absence of invasion of surrounding soft tissues. However, in particular on CT scan, adult-type RM may mimic malignant tumors because of indistinct borders blending into adjacent isodense muscles [24]. Thus, the absence of specific clinical and of unequivocal imaging features contributes to make any single case a diagnostic challenge. Preoperative differential diagnosis includes cysts, benign tumors (i.e., hemangioma, lipoma, neurofibroma, and granular cell tumor), and malignant neoplasms (i.e., squamous cell carcinoma and rhabdomyosarcoma).

Definitive diagnosis is possible only after histologic examination and immunohistochemical analysis. It is recommended to obtain the neoplastic tissue by excisional rather than incisional biopsy because in the latter the small amount of tumor tissue may contribute to misdiagnosis and inappropriate treatment [15, 37]. Independently of the site of the tumor, the histology of adult-type RM is quite distinctive [1]. As in our case, adult-type RM is composed by dense sheets of closely packed large, round cells with eosinophilic and granular cytoplasm, and centrally or peripherally located nuclei, in part with prominent nucleoli. Many cells are vacuolated because of intracellular glycogen that dissolves during processing. However, since these findings may resemble a variety of other lesions, in particular granular cell tumor, hibernoma, and paraganglioma, immunohistochemical staining is required for diagnosis. Neoplastic cells of adult-type RM—as reported

in this case—are immunoreactive for desmin, myoglobin, and muscle-specific actin (markers of differentiated skeletal muscle cells) and negative for cytokeratin, S-100, CD68R, and neuroendocrine markers (synaptophysin and chromogranin-A).

The treatment of adult-type RM is surgical and can be done either by endoscopic or external approach, but always preserving the adjacent structures such as the vocal folds and the swallowing apparatus. Complete surgical excision is curative. Adult-type RMs may recur [3, 13, 18], especially after incomplete excision; however, aggressive behavior and malignant transformation have never been described.

In conclusion, the adult-type RM of the larynx is a very rare benign tumor that must be distinguished from other submucosal laryngeal neoplasms. The present case fulfills the clinicopathologic criteria for the diagnosis of adult-type RM of the larynx. Since clinical and imaging features are not specific for adult-type RM, histology and immunohistochemistry are mandatory for a definitive diagnosis. Radical endoscopic excision is the recommended procedure to obtain tissue for histologic evaluation and for patient treatment.

Conflicts of Interest

The authors declare that they have no conflicts of interest.

References

- [1] J. R. Goldblum, S. W. Weiss, and A. L. Folpe, *Enzinger and Weiss's Soft Tissue Tumors. Chapter 19: Rhabdomyoma*, pp. 591–600, Elsevier Saunders, Philadelphia, PA, USA, 6th edition, 2013.
- [2] S. B. Kapadia, J. M. Meis, D. M. Frisman, G. L. Ellis, and D. K. Heffner, “Fetal rhabdomyoma of the head and neck: a clinicopathologic and immunophenotypic study of 24 cases,” *Human Pathology*, vol. 24, no. 7, pp. 754–765, 1993.
- [3] S. B. Kapadia, J. M. Meis, D. M. Frisman, G. L. Ellis, D. K. Heffner, and V. J. Hyams, “Adult rhabdomyoma of the head and neck: a clinicopathologic and immunophenotypic study,” *Human Pathology*, vol. 24, no. 6, pp. 608–617, 1993.
- [4] R. J. Gorlin, “Nevoid basal cell carcinoma syndrome,” *Dermatologic Clinics*, vol. 13, no. 1, pp. 113–125, 1995.
- [5] U. Tostar, C. J. Malm, J. M. Meis-Kindblom, L. G. Kindblom, R. Toftgård, and A. B. Undén, “Deregulation of the hedgehog signalling pathway: a possible role for the PTCH and SUFU genes in human rhabdomyoma and rhabdomyosarcoma development,” *Journal of Pathology*, vol. 208, no. 1, pp. 17–25, 2006.
- [6] Z. Gibas and M. Miettinen, “Recurrent parapharyngeal rhabdomyoma: evidence of neoplastic nature of the tumor from cytogenetic study,” *American Journal of Surgical Pathology*, vol. 16, no. 7, pp. 721–728, 1992.
- [7] A. R. W. Climie, E. A. Moscovic, and R. M. Kommel, “Rhabdomyoma of the larynx,” *Archives of Otolaryngology-Head and Neck Surgery*, vol. 77, no. 4, pp. 409–414, 1963.
- [8] H. A. Battifora, R. Eisenstein, and J. A. Schild, “Rhabdomyoma of larynx: ultrastructural study and comparison with granular cell tumors (myoblastomas),” *Cancer*, vol. 23, no. 1, pp. 183–190, 1969.
- [9] C. Bianchi and G. Muratti, “Rhabdomyoma (adult type) of the larynx,” *Beiträge Zur Pathologie*, vol. 156, no. 1, pp. 75–79, 1975.
- [10] A. Ferlito and P. Frugoni, “Rhabdomyoma purum of the larynx,” *Journal of Laryngology and Otology*, vol. 89, no. 11, pp. 1131–1141, 1975.
- [11] R. A. Bagby, J. T. Parker, and R. G. Iglesias, “Rhabdomyoma of the larynx: report of a case,” *Archives of Otolaryngology-Head and Neck Surgery*, vol. 102, no. 2, pp. 101–103, 1976.
- [12] F. Ebbesen, S. V. Petersen, R. Albrechtsen, P. Bretlau, and E. Thomsen, “Extracardial rhabdomyoma. 3 cases of rhabdomyoma in the head and neck regions,” *Ugeskrift for Laeger*, vol. 138, no. 2, pp. 96–98, 1976.
- [13] L. K. Winther, “Rhabdomyoma of the hypopharynx and larynx: report of two cases and review of the literature,” *Journal of Laryngology and Otology*, vol. 90, no. 11, pp. 1041–1051, 1976.
- [14] D. Boedts and J. Mestdagh, “Adult rhabdomyoma of the larynx,” *Archives of Oto-Rhino-Laryngology*, vol. 224, no. 3–4, pp. 221–229, 1979.
- [15] O. Kleinsasser and H. Glanz, “Myogenic tumours of the larynx,” *Archives of Oto-Rhino-Laryngology*, vol. 225, no. 2, pp. 107–119, 1979.
- [16] B. Modlin, “Rhabdomyoma of the larynx,” *Laryngoscope*, vol. 92, no. 5, pp. 580–582, 1982.
- [17] T. R. Helliwell, M. C. Sissons, P. J. Stoney, and M. T. Ashworth, “Immunocytochemistry and electron microscopy of head and neck rhabdomyoma,” *Journal of Clinical Pathology*, vol. 41, no. 10, pp. 1058–1063, 1988.
- [18] K. Hamper, J. Renninghoff, and H. Schafer, “Rhabdomyoma of the larynx recurring after 12 years: immunocytochemistry and differential diagnosis,” *Archives of Oto-Rhino-Laryngology*, vol. 246, no. 4, pp. 222–226, 1989.
- [19] D. N. Roberts, M. J. Corbett, D. Breen, D. A. Jonathan, and C. E. Smith, “Rhabdomyoma of the larynx: a rare cause of stridor,” *Journal of Laryngology and Otology*, vol. 108, no. 8, pp. 713–715, 1994.
- [20] V. Selme, M. D. Trincard, M. Wassef, and P. Papillon, “A rare cause of dysphonia: laryngeal rhabdomyoma,” *Annales de Pathologie*, vol. 14, no. 3, pp. 177–181, 1994.
- [21] E. C. Johansen and P. Illum, “Rhabdomyoma of the larynx: a review of the literature with a summary of previously described cases of rhabdomyoma of the larynx and a report of a new case,” *Journal of Laryngology and Otology*, vol. 109, no. 2, pp. 147–153, 1995.
- [22] P. Zbären, H. Lång, and M. Becker, “Rare benign neoplasms of the larynx: rhabdomyoma and lipoma,” *ORL: Journal for Oto-Rhino-Laryngology and its Related Specialties*, vol. 57, no. 6, pp. 351–355, 1995.
- [23] J. LaBagnara Jr., E. Hitchcock, and T. Spitzer, “Rhabdomyoma of the true vocal fold,” *Journal of Voice*, vol. 13, no. 2, pp. 289–293, 1999.
- [24] G. S. Liang, L. A. Loevner, and P. Kumar, “Laryngeal rhabdomyoma involving the paraglottic space,” *American Journal of Roentgenology*, vol. 174, no. 5, pp. 1285–1287, 2000.
- [25] J. M. Orrit, C. Romero, C. Mallofré, and J. Traserra, “Laryngeal rhabdomyoma: unusual case of dysphonia: review of the literature,” *Acta Otorrinolaringológica Española*, vol. 51, pp. 643–645, 2000.
- [26] A. K. Brys, O. Sakai, J. DeRosa, and S. M. Shapshay, “Rhabdomyoma of the larynx: case report and clinical and pathologic review,” *Ear, Nose, and Throat Journal*, vol. 84, no. 7, pp. 437–440, 2005.
- [27] B. D. Liess, R. P. Zitsch III, R. Lane, and J. T. Bickel, “Multifocal adult rhabdomyoma: a case report and literature review,” *American Journal of Otolaryngology*, vol. 26, no. 3, pp. 214–217, 2005.

- [28] G. G. Formigoni, F. S. G. Fortes, C. Wiikmann, L. U. Sennes, and P. C. Carneiro, "Adult extracardiac rhabdomyoma compromising the extrinsic laryngeal muscles," *International Archives of Otorhinolaryngology*, vol. 10, pp. 74–78, 2006.
- [29] K. Jensen and K. Swartz, "A rare case of rhabdomyoma of the larynx causing airway obstruction," *Ear, Nose, Throat Journal*, vol. 85, no. 2, pp. 116–118, 2006.
- [30] D. Koutsimpelas, A. Weber, B. M. Lippert, and W. J. Mann, "Multifocal adult rhabdomyoma of the head and neck: a case report and literature review," *Auris Nasus Larynx*, vol. 35, no. 2, pp. 313–317, 2008.
- [31] G. Viscasillas, J. Maiz, X. Lao, and J. J. Sanz, "Laryngeal rhabdomyoma. Transoral exeresis with CO₂ laser," *Acta Otorinolaringológica Española*, vol. 59, no. 10, pp. 512–513, 2008.
- [32] A. Farboud, R. Pratap, H. Helquist, and P. Montgomery, "An unusual cause of obstructive sleep apnoea," *Journal of Laryngology and Otology*, vol. 123, no. 11, p. e22, 2009.
- [33] A. D. Friedman, J. A. Burns, M. J. Lutch, and S. M. Zeitels, "Submucosal neoplasms of the laryngeal introitus," *Journal of Laryngology and Otology*, vol. 126, no. 7, pp. 706–713, 2012.
- [34] L. A. de Trey, S. Schmid, and G. F. Huber, "Multifocal adult rhabdomyoma of the head and neck manifestation in 7 locations and review of the literature," *Case Reports in Otolaryngology*, vol. 2013, Article ID 758416, 5 pages, 2013.
- [35] M. M. Pinto, J. de Carvalho E Castro, and R. G. Ramos, "Adult rhabdomyoma of the larynx," *International Archives of Otorhinolaryngology*, vol. 17, no. 4, pp. 415–418, 2013.
- [36] R. B. Cain, S. H. Gnagi, D. E. Jaroszewski, and D. G. Lott, "Adult laryngeal rhabdomyoma with extralaryngeal extension: surgical excision and reconstruction with aortic homograft," *Otolaryngology–Head and Neck Surgery*, vol. 50, pp. 501–502, 2014.
- [37] S. Vijendra Shenoy, A. Raghavendra Rao, V. Prasad, and S. Kuriakose, "Rhabdomyoma of larynx—a diagnostic dilemma," *Egyptian Society of Ear, Nose, Throat and Allied Sciences*, vol. 14, no. 3, pp. 217–220, 2013.
- [38] F. Carta, S. Sionis, C. Gerosa, and R. Puxeddu, "Endoscopic management of adult-type rhabdomyoma of the glottis: case report and review of the literature," *Brazilian Journal of Otorhinolaryngology*, vol. 82, no. 2, pp. 244–247, 2016.



Hindawi
Submit your manuscripts at
<https://www.hindawi.com>

