

Implant Prosthetic Rehabilitation of the Patients with Mandibular Resection Following Oral Malignoma Surgery

Marica Šimunović-Šoškić¹, Mirna Juretić², Zoran Kovač¹, Robert Cerović², Ivone Uhač¹, Robert Antonić¹ and Sonja Pezelj-Ribarić³

¹ University of Rijeka, School of Medicine, Clinic of Stomatological Prosthetics, Rijeka, Croatia

² University of Rijeka, School of Medicine, Clinic of Maxillofacial Surgery, Rijeka, Croatia

³ University of Rijeka, School of Medicine, Clinic of Oral Medicine and Parodontology, Rijeka, Croatia

ABSTRACT

Patient underwent mandibular resection due to surgical therapy of oropharyngeal malignoma. Facial asymmetry and cosmetic distortion are frequent consequences of such interventions, which may also include deviation and intrusion of the mandible, motor and sensory disorders, abnormal intermaxillary relations and malocclusion. Implant-supported prosthesis could be an optimal solution to prosthodontic treatment of such patients. However, there is a problem in determination of stable (interocclusal) intermaxillary relations. This article describes the choice of therapy and procedures undertaken in prosthetic rehabilitation of a patient who underwent mandibular resection and radiotherapy with supported prosthesis retained with four implants.

Key words: dental implants, overdenture, oral malignoma, occlusion

Introduction

Patient underwent mandibular resection due to oropharyngeal carcinoma at the Clinic of Maxillofacial Surgery, Rijeka University Hospital Center, where he also received the entire oncological treatment. Patient had facial asymmetry, esthetic distortion, mandible deviation towards the resected side with changes in mandibular movement, retrusion, motor and sensory deficiency of the lower lip, and limited opening of the mouth. As a consequence of radiotherapy the patient had reduced salivary function resulting in dry mouth (xerostomia)¹. Radiotherapy also caused atrophy of the oral mucosa and damage to small blood vessels favoring conditions from irritation to ulceration, possibly culminating in osteoradionecrosis¹. Osteoradionecrosis presents a number one problem after an invasive oncological therapy and complicates insertion of implants in irradiated edentulous jaw^{5,6}. Evidence shows that implant insertion into edentulous irradiated mandible does not compromise implant integrity and fails to reduce the implant survival rate^{7–10}. It is well known from the literature that the implant survival rate in cases of irradiated edentulous man-

dible is quite high, which has also been confirmed through histological analyses of osseointegration in irradiated mandible^{3,6,7,11–14}. It was recommended that implantation be performed minimum 9–12 months following the radiotherapy. This article presents step-by-step prosthetic rehabilitation of a patient who underwent malignoma surgery, mandibular resection and radiotherapy. Rehabilitation was initiated 12 months following the radiotherapy.

Case Report

Patient was 60 years of age, treated at the Clinic of Maxillofacial Surgery, Clinical Hospital Center Rijeka, for oropharyngeal carcinoma. Patient underwent a radical surgery for tumor excision, which included a mandibular »en block« surgery with segmental resection of a part of the mandible (right angulus and ramus). Patient experienced difficulties during feeding and chewing, with total edentulousness in both upper and lower jaws. Ex-

ternal examination and analysis revealed facial asymmetry caused by depression and collapse of the right angle of the mouth as a consequence of the resection, as well as the loss of motor and sensory innervation on the right-hand side of the lower lip. Mandible was retruded and

shifted towards the operated side, even when the mouth was closed.

Intraoral and radiological assessments were used to follow the condition of soft tissues, discontinuity of the alveolar ridge, and sensory loss on the right-hand side of the mandible. In addition, condition of the bone was evaluated, upon which it was concluded that there was a possibility for implant insertion.

Prosthetic rehabilitation was carried out with a total denture in the upper jaw, and implant-supported overdenture using four implants in the lower jaw. Implants were inserted in the tooth regions 43, 33, 35, 36, and implant dimensions were 11x3.5 (AstraTech, Sweden). Post-operative course was normal (orthopantomogram) (Figure 1). Three months after surgery, gingival flaps were opened (Figure 2) and sulcus formers were placed. After 15 days 45@ UNI ABUTMENTS were inserted. A perforated individual impression tray and transfers were used for functional impression in the lower jaw, and individual impression tray was also used for functional impression in the upper jaw. Intermaxillary relations were determined with great difficulty since the lower jaw was retruded and shifted (deviated) towards the operated side. Retention has been derived using a bar connectors placed in the denture and using CEKA placed at the both ends of the bar (Figures 3 and 4). Mandibular overdenture was cast in Cr-Co-Mo alloy together with respective components and the bar. During the course of fabrication, a try-in of the bar's metal construction was performed (Figure 5), as well as an esthetic try-in of tooth configuration with many esthetic corrections due to lower lip collapse towards the operated side and mandibular retrusion. Individual bar was fixated with screws, while the overdenture was fixated using the analogous attachments on the bar (Figures 6 and 7).

Patient was followed-up for the first seven days, one month and 6 months for the possible irritations, decubital lesions, and oral hygiene. Upper total denture instability presented a major problem, followed by lower denture saddle deviation on the operated side due to in-existent continuity of the mandible. One year after the completed

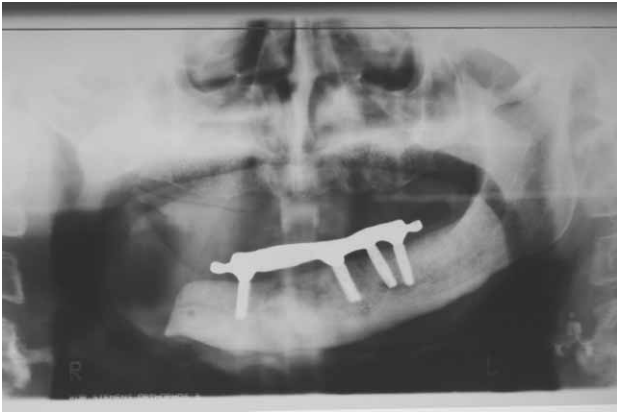

Fig. 1. The panoramic radiograph of implants and screwed bar.

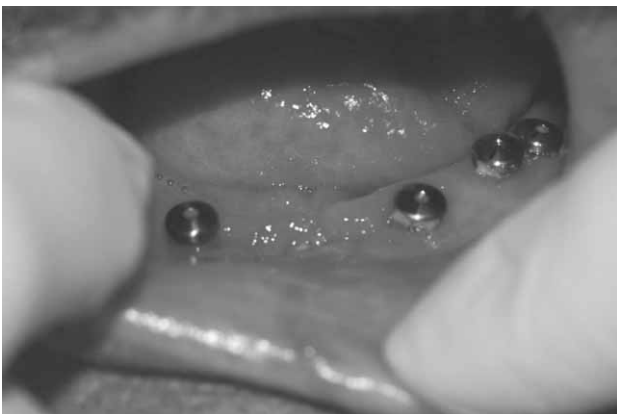

Fig. 2. Healing abutments after three weeks.

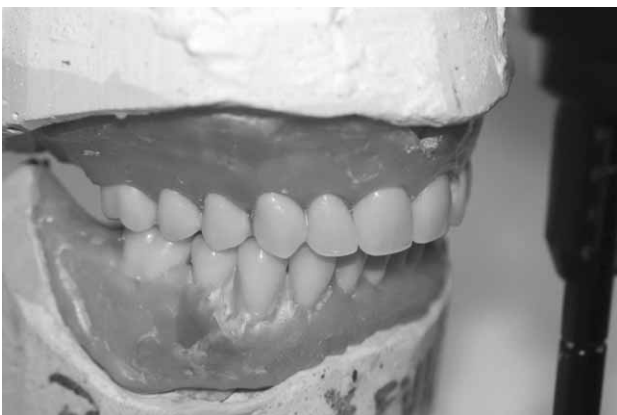

Fig. 3. Wax up in articulator.

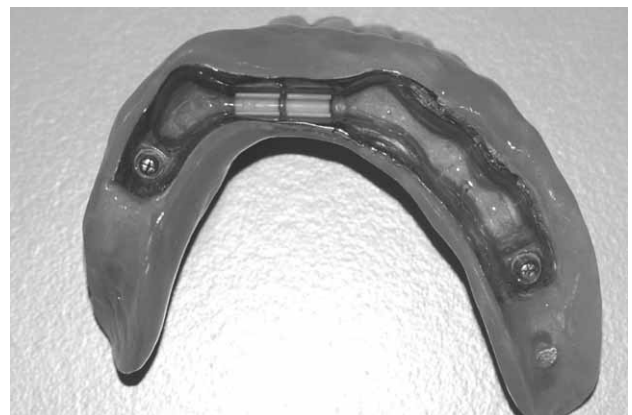

Fig. 4. Metal housing with retention parts.




Fig. 5. Try-in of the bar's metal construction.

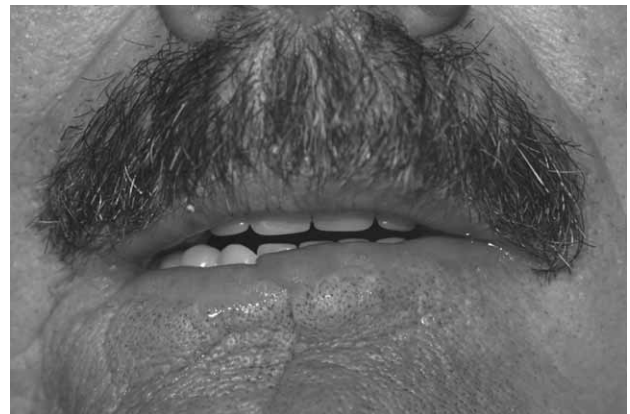

Fig. 6. Final prosthesis in mouth.

prosthetic rehabilitation the results were satisfactory, soft tissues were healthy with no signs of inflammation around the implants, and bone loss was absent.

Discussion

Surgical treatments of malignoma in the oral cavity (tongue, sublingual area, alveolar ridge, buccal vestibule, oropharynx) often result in undesirable anatomic situation (due to mandibular resection) for prosthetic rehabilitation¹. Edentulous patients who suffer from one of abovementioned malignomas undergo a partial mandibular resection and radiotherapy, and often suffer from difficulties in function such as speech, chewing, swallowing and esthetic. In the case presented, patient suffered from impaired myodynamics, and had difficulty controlling lower jaw and lower lip movements. In addition, one of the major problems was reduction of neutral zone, making prosthetic rehabilitation of such patient impossible using conventional models.

Available evidence from the literature shows that implant-retained overdentures may significantly reduce problems related to stability and retention of the denture, and decrease pressure on the underlying soft tissues⁶.

Obliteration of the small blood vessels in irradiated mandible causes secondary ischemia, leading to osteoradionecrosis. Bone vitality is damaged and bone is prone to invasion of microorganisms causing infection. As a consequence of aggressive treatment methods and osteoradionecrosis, implant placement poses a relative contraindication. In spite of this, implants placed into the irradiated area show a high survival rate, similar to survival rate of implants placed in healthy mandibular bone^{3,6,7}.

One of the studies reported removal of only 3 out of 169 implants placed into irradiated mandible⁸. Some authors believe that the period from radiotherapy to implant placement, in the absence of hyperbaric oxygen treatment, should be from 13 to 24 months³. Another study analyzed the fate of 221 Branemark and IMZ implants placed into irradiated mandible during a 10-year period, and only 18 (8.1%) implants failed to show osseo-

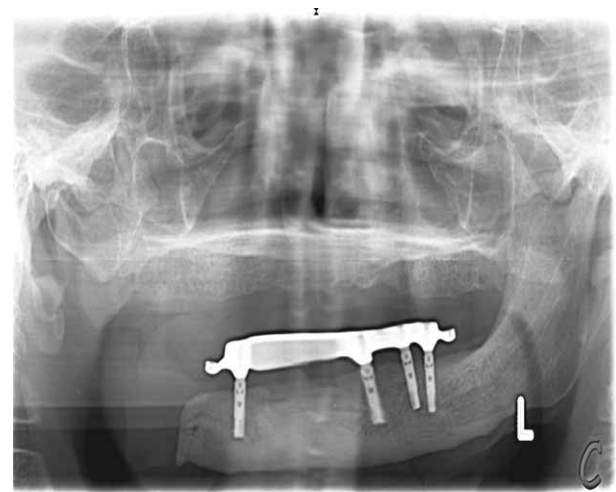


Fig. 7. Radiographic evaluation after 1 year.

integration^{2,11}. There are also authors who claim that, following the radiotherapy, a patient should undergo hyperbaric oxygen treatment in order to avoid future complications¹².

What is the best time for implantation procedure in relation to irradiation of the mandible remains an open question. While some authors believe that the bone healing period following irradiation is approximately 12 months, others report a continuous progressive loss of capillaries during the course of irradiation therapy¹³.

Marx and Granstrom reported that longer periods between irradiation and implantation increased the risk of implant failure. Later on, authors recommended implantation in a so called »window« sometime between 1 and 6 months following the radiotherapy^{14,15}.

On the basis of recent reports, risk of osteoradionecrosis shortly after the radiotherapy is neglectable. In this report, the patient had a long survival rate of mandibular implants. The major problem in this patient was retruded mandible, deviation towards the operated side,

small interocclusal space, and limited mouth opening, as well as the problem of both upper and lower denture function and placement. Upper teeth configuration presented another problem, due to a shift of the mandible and increased overbite and overjet, with missing posterior support.

Primarily due to a loss of sensitive sensation on the lower lip, it was of utmost importance to take into account the configuration of upper anterior teeth in order to avoid trauma to the lip during mastication and resting. There is loss of proprioceptive sense of occlusion with uncoordinated, less precise mandibular movement, and on the surgical side, the teeth in the mandible deflect away from their opposing maxillary teeth after initial contact on the non-surgical side. The unilateral unstable interocclusal relationship may compromise mastication. In patients with a loss of continuity in the mandible achieving and re-establishing of the completely successful chewing, load and functional rehabilitation are extremely difficult when using dentures. Since radiotherapy is known to reduce the salivary flow and obliterates small capillary vessels, the protective layer acting as a lubricant between the mucosa and inner mucosal surface disappears¹⁶. Oral mucosa becomes atrophic and fragile, and therefore prone to irritation and ulceration¹⁷. It is important to avoid additional trauma to the lower jaw through the use of mobile prostheses, as well as prevent further deterioration of mandibular bone. Therefore, implant-supported overdenture may be the best prosthetic solution.

Decreased motor and sensory functions of the tongue cause inability to control denture during movements.

Rehabilitation of the patients with conventional dentures is inefficient and problematic. Implant-supported

overdenture may improve both function and esthetics. Such denture solves majority of problems, reduces mechanical irritations to the tongue and soft tissues, and finally improves tongue space and mastication.

Conclusions

Following the mutilating procedures, unavoidable in treatment of oral malignomas, a loss of certain jaw segments leads to disruption of normal anatomic relations and makes rehabilitation using conventional prosthetic methods practically impossible. Such difficulties are intensified by the presence of xerostomia following the radiotherapy.

Edentulousness, bone loss, xerostomia, coupled with resection of oral soft tissues, complicate the patient's life, particularly its functional (chewing, feeding, speech), esthetic and psychosocial aspects. Therapy of these patients certainly requires satisfactory prosthetic rehabilitation, with the described procedure as the therapy of choice.

However, such therapy should be available to all similarly mutilated patients, provided the medical requirements are met, but unfortunately this kind of therapy is often a privilege of those with sufficient financial means. Otherwise, clinical experience supports such therapeutic approach in patients who undergo upper or lower jaw resective surgery due to treatment of oral malignomas. Therefore, the therapy described above may be recommended as the therapy of choice.

REFERENCES

1. SCHOEN PJ, REINTSEMA H, RAGHOEBAR GM, VISSINK JL, ROODENBURG N, Oral oncology, 40 (2004) 862. — 2. OELGHESSER D, LIRAN L, SHLOMO B, DEVORAH SA, J Prosthet Dent, 91 (2004) 310. — 3. OECHSLIN CK, ZIMMERMANN AP, GRATS KW, SAILER HF, Int J oral Maxillofac. Implants, 14 (1999) 113. — 4. KING M, CASARETT G, WEBER DA, J Nuc Med, 20 (1979) 1142. — 5. NISHIMURA RD, ROUMANS E, BEUMER J, MAY PK, SHIMIZU KT, J Prosthet Dent, 79 (1998) 641. — 6. ALI A, PATTON DW, SHARKAWI AM, DAVIES J, Int J Oral Maxillofac implants, 12 (1997) 523. — 7. NIIMI A, UEDA M, KELLEREE, WORMINGTON P, Int J Oral Maxillofac Implants, 13 (1998) 407. — 8. NIIMI A, FUJIMOTO T, NOSAKA Y, UEDA M, Int J Oral Maxillofac Implants, 12 (1997) 259. — 9. FRANZEN L, ROSENQUIST KI, GUSTAFSSON I, Int J Oral Maxillofac Implants, 10 (1995) 183. — 10.

BRONGIEZ V, NYSSSEN-BEHETS C, GREGOIRE V, REYCHLER N, LENGELE B, Clin Oral Implants Res, 13 (2002) 234. — 11. FUNK GF, ARCURI MR, FRODEL JL JR, Head Neck, 20 (1998) 38. — 12. NELSON K, HEBERER S, GLATZER C, J Prosthet Dent, 98 (2007) 405. — 13. SCHEPERS RH, SLAGHTER AP, KAANDERS JH, VAN DEN HOOGEN FJ, MERKX MA, Int J Oral Maxillofac Surg, 35 (2006) 803. — 14. SHAW RJ, SUTTON AF, CAWOOD J, HOWELL RA, LOWE D, BROWN JS, ROGERS SN, VAUGHAN ED, Head Neck, 27 (2005) 459. — 15. EPSTEIN JB, ROBERTSON M, EMERTON S, PHILLIPS N, STEVENSON-MOORE P, Head Neck, 23 (2001) 389. — 16. ALLEN PF, MCMILLAN AS, Clin Oral Implants Res, 14 (2003) 173. — 17. YERIT KC, POSCH M, SEEMANN M, HAINICH S, DORTBUDAK O, TURHANI D, OZYUVACI H, WATZINGER F, EWERS R, Clin Oral Implants Res, 17 (2006) 337.

M. Šimunović-Šoškić

University of Rijeka, School of Medicine, Department of Stomatological Prosthetics, Krešimirova 42, 51000 Rijeka, Croatia
e-mail: marिकासoskic@yahoo.com

IMPLANTOPROTETSKA REHABILITACIJA PACIJENTA S RESEKCIJOM MANDIBULE NAKON OPERACIJE ORALNOG MALIGNOMA

S A Ž E T A K

Pacijent je podvrgnut resekciji mandibule radi kirurškog tretmana malignoma orofaringsa. Kao posljedica, često se javlja asimetrija lica i kozmetska izobličenost uključujući devijaciju i retruziju mandibule, motorne i senzitivne poremećaje, abnormalne intermaksilarne odnose i okluziju. Implantatima poduprta proteza može biti optimalan način protetskog tretmana takvih pacijenata. Međutim postoji i problem u određivanju stabilnih (interokluzijskih) međučeljskih odnosa. Ovaj članak opisuje izbor terapije i postupke u protetskoj rehabilitaciji pacijenta koji je podvrgnut resekciji mandibule i radioterapiji sa poduprtom protezom retiniranoj sa četiri implantatima.