



The value of scrotal infrared digital thermography in detection of varicocele – initial results

TOMISLAV KULIŠ¹
DARKO KOLARIĆ²
KREŠIMIR KARLOVIĆ³
MATEJ KNEŽEVIĆ³
JOSIP SAMARDŽIĆ⁴
MILAN BITUNJAC⁵
SVETLANA ANTONINI⁶
ŽELJKO KAŠTELAN¹

¹ Department of Urology, University Hospital Centre Zagreb, Medical School, University of Zagreb, Zagreb, Croatia

² Ruder Bošković Institute, Centre for Informatics and Computing, Zagreb, Croatia

³ Department of Urology, General hospital »Dr. Josip Benčević«, Slavonski Brod, Croatia

⁴ Department of Surgery, General hospital »Dr. Josip Benčević«, Croatian urgent medicine and surgery association, Slavonski Brod, Croatia

⁵ Department of Neurology, General hospital »Dr. Josip Benčević«, Slavonski Brod, Croatia

⁶ Primary Health Care Zagreb – Center, Department of Radiology, Zagreb, Croatia

Correspondence:

Tomislav Kuliš
Department of Urology
University Hospital Center Zagreb
Kišpatićeva 12, 10000 Zagreb
E-mail: tkulis@kbc-zagreb.hr

Key words: Varicocele; Scrotal temperature; Thermography

Received July 15, 2011.

Abstract

Introduction: Varicocele is a dilatation of pampiniform venous plexus. It is associated with male infertility, as it is found in more than 40% of male partners in infertile couples. The main pathophysiological mechanism for impaired spermatogenesis is considered to be elevated scrotal temperature. Mainstay for diagnostic assessment of varicocele is physical examination and scrotal ultrasound/doppler. Thermography is a diagnostic method which measures temperature differences across the skin surface using a highly sensitive infrared camera. Currently there is no consensus regarding diagnostic parameters for thermography in diagnosis of varicocele. Aim of this study is to examine application of digital thermography in diagnosing varicocele.

Material and Methods: Study group consisted of 10 patients of mean age 18.2 ± 2.4 (range = 15.5 to 23.7). In all patients varicocele was detected incidentally on routine physical examination. All patients were evaluated by three methods. Infrared digital thermography was followed by physical examination and ultrasound/doppler. Infrared camera Thermo Tracer TH7102WL (NEC Sanei Instruments, Ltd., Japan) was used during all measurements. This infrared system has a geometric resolution of 76.800 pixels per picture (320×240) and the minimum detectable temperature resolution (difference) is 0.07°C at 30°C (Normal mode).

Results: Mean temperature at left pampiniform plexus was $34.65 \pm 0.66^\circ\text{C}$ (range = 34.1 to 36.3°C) and at right pampiniform plexus $32.53 \pm 0.78^\circ\text{C}$ (range = 31.5 to 33.5°C). Temperature at left testicle was $33.58 \pm 0.97^\circ\text{C}$ (range = 32.1 – 35°C) while at right testicle it was $32.19 \pm 0.81^\circ\text{C}$ (range = 31.2 to 33.5°C). Temperature at pampiniform plexus higher than 34°C presents main thermographic sign of varicocele, while temperature at testicle higher than 32°C is indicative of varicocele. Temperature difference between left and right pampiniform plexus was $2.12 \pm 1.08^\circ\text{C}$ (range = 0.9 to 4.7°C), and between testicles was $1.39 \pm 1.20^\circ\text{C}$ (range = 0.1 to 3.6°C). Thermography successfully confirmed varicocele diagnosis in all patients.

Conclusion: Digital infrared thermography presents feasible and low cost diagnostic method for varicocele. Further study on a larger number of patients and healthy participants is needed to evaluate sensitivity and specificity of this method and to establish consistent diagnostic parameters for thermographic assessment of varicocele.

INTRODUCTION

Varicocele is a dilatation of pampiniform venous plexus. The incidence of varicocele is about 15% in male population (1). It is associated with male infertility, as it is found in more than 40% of male partners in infertile couples (2). It presents common and treatable cause of male infertility.

Pampiniform plexus is commonly dilated due to the back flow of the venous blood within the spermatic veins (3). The etiology and pathophysiology of varicocele appears complex and multifactorial. Varicocele might cause decrease in testicular volume, impair sperm quality and Leydig cell function (4-7). Increased pressure in the spermatic veins, depleted oxygen, increased heat injury and presence of toxins in the spermatic veins have all been suggested to affect sperm quality in patients with varicocele (4-7).

Most varicoceles are left sided, possibly due to anatomical configuration with a more vertical inlet of the internal spermatic vein to the renal vein as opposed to a more oblique inlet on the right. However, recent studies have shown varicocele to be bilateral disease (8, 9): with usually, subclinical varicocele on the right side. Subclinical varicocele refers to the presence of retrograde blood flow that cannot be detected by careful palpation of the cord during Valsalva maneuver and requires radiographic imaging for diagnosis (10). Currently, the standard for diagnostic assessment of varicocele is physical examination and scrotal ultrasound/doppler (11). Nevertheless, scrotal thermography was demonstrated as a useful diagnostic method, especially in low grade varicocele (8, 11, 12). Recent development of digital infrared thermographic Focal plane array cameras offers the opportunity to revitalize this diagnostic method and further improve its accuracy.

The aim of this study is to examine the application of digital thermography in patients with already diagnosed varicocele.

PATIENTS AND METHODS

Study group consisted of 10 patients of mean age 18.2 ± 2.4 (range = 15.5–23.7) who are football players. In all patients varicocele was detected incidentally on routine physical examination before a football season. The hospital ethics committee approved the study, and all the patients signed informed consent before the examinations. All patients were evaluated by three methods. Infrared digital thermography was followed by physical examination and ultrasound/doppler. None of the patients reported previous episodes of cryptorchidism, hydrocele or testicular trauma. All data are reported as mean \pm standard deviation.

Scrotal infrared digital thermography

For all measurements we used infrared camera Thermo Tracer TH7102WL (NEC Sanei Instruments, Ltd., Japan). This infrared system has a geometric resolution

of 76.800 pixels per picture (320×240) and the minimum detectable temperature resolution (difference) is 0.07°C at 30°C (Normal mode). For experimental purposes we developed the Thermo WEB software for remote control and transferring data from infrared camera TH7102WL to a computer, which is designed to be used further as an open source thermoscan analyses software (13). This software supports thermal analysis and image presentation, in numerical or graphical forms, of temperature values of any part of surface inside the thermographic scan.

Before thermographic imaging patients spent 10 minutes in climatized room ($22\text{--}23^\circ\text{C}$) with undressed lower part of the body. Thermographic imaging was carried in climatized room as well ($22\text{--}23^\circ\text{C}$). Patients were standing with legs stretched and scrotum hanging freely. To avoid incorrect measurement, patients were holding tip of the penis with one hand to the abdominal wall. Position of camera was around 40cm from the scrotum. We have taken three images for each patient. First image at the start of the examination, second during Valsalva maneuver and third shortly after Valsalva maneuver. For later analysis all three images were used.

Physical and ultrasound/doppler examination

Patients were examined in upright position with and without Valsalva maneuver. Criteria for grading varicocele were the following: grade 1, varicocele palpable only during the Valsalva maneuver; grade 2, varicocele palpable in standing position; and grade 3, varicocele visible/evident without palpation.

For ultrasound 7.5MHz linear transducer was used. The diameter of largest pampiniform vein identified during the ultrasound examination was measured. Diameter larger than 2mm was indicative for varicocele and if larger than 3mm was considered unequivocal of varicocele.

RESULTS

At physical examination all patients had varicocele, three patients had varicocele grade I, six had grade II, and one had grade III. At ultrasound/doppler in all patients diameter of pampiniform veins were larger than 2mm, with positive reflux longer than 1 second during Valsalva maneuver. Mean temperature at left pampiniform plexus (T_{LP}) was $34.65 \pm 0.66^\circ\text{C}$ (range = 34.1 to 36.3°C) and at right pampiniform plexus (T_{RP}) $32.53 \pm 0.78^\circ\text{C}$ (range = 31.5 to 33.5°C). Temperature at left testicle (T_{LT}) was $33.58 \pm 0.97^\circ\text{C}$ (range = 32.1 to 35°C) while at right testicle (T_{RT}) it was $32.19 \pm 0.81^\circ\text{C}$ (range = 31.2 to 33.5°C) (Table 1).

Temperature difference (ΔT_{LP-RP}) between left and right pampiniform plexus was $2.12 \pm 1.08^\circ\text{C}$ (range = 0.9 to 4.7°C), and between testicles (ΔT_{LT-RT}) was $1.39 \pm 1.20^\circ\text{C}$ (range = 0.1 to 3.6°C). In all patients ΔT_{LP-RP} at pampiniform plexuses was $\geq 0.9^\circ\text{C}$. Thermography successfully confirmed varicocele diagnosis in all patients (Figure 1).

TABLE 1

Measured temperature (°C) at points of interest.

Temperature	LP	RP	LT	RT	DT_LPRP	DT_LTRT
Mean	34.65	32.53	33.58	32.19	2.12	1.39
Median	34.40	32.60	33.85	32.15	1.70	1.25
Standard Deviation	0.66	0.78	0.97	0.81	1.08	1.20
Minimum	34.1	31.5	32.1	31.2	0.9	0.1
Maximum	36.3	33.5	35.0	33.5	4.7	3.6
Confidence Level(95,0%)	0.47	0.56	0.70	0.58	0.77	0.86

n=10, Abbreviations: L, left; R, right; P, pampiniform plexus; T, testicle; Δ, temperature difference.

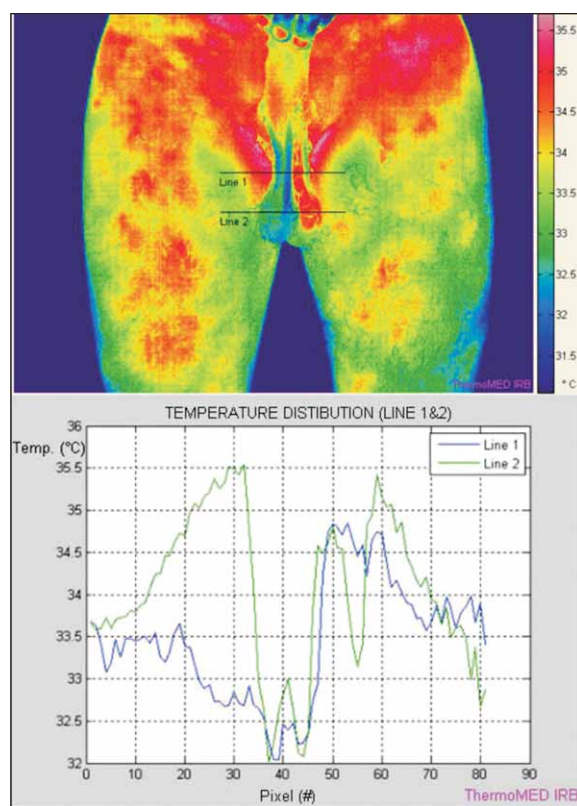


Figure 1. Scrotal infrared digital thermography of the patient with left sided varicocele. Graph shows temperature change between right and left side at the level of pampiniform plexuses and testicles.

DISCUSSION

Various diagnostic criteria for varicocele were suggested based on digital thermography imaging. However, standardized diagnostic criteria for varicocele with this method have not yet been established.

Ten patients with known left sided varicocele participated in this study. Thermography, with our protocol confirmed diagnosis of left sided varicocele in all patients. In our series, all patients had T_{LP} higher than $34^{\circ}C$ and T_{LT} higher than $32^{\circ}C$, while on the right side in all patients T_{RP} was $<34^{\circ}C$ and in 40% of patients T_{RT}

was $<32^{\circ}C$. Merla *et al.* stated that temperature of pampiniform plexus higher than $34^{\circ}C$ and/or testicle higher than $32^{\circ}C$ indicates toward varicocele (14).

Tucker suggested that Valsalva maneuver could aid in varicocele diagnosis and that in normal settings (i.e. lack of venous reflux) it causes temperature to drop for $0.5^{\circ}C$ (15). In our series we did not registered similar effect. Nogueira and Yamamoto stated that temperature difference between left and right pampiniform plexus (ΔT_{LP-RP}) higher than $0.8^{\circ}C$ and $0.3^{\circ}C$ respectively is a sign of unilateral varicocele (12, 16). Firstly, it is important to stress that this sign should be counted just in the case of unilateral varicocele. Secondly, in our series in all patients ΔT_{LP-RP} was $\geq 0.9^{\circ}C$, thus supporting this observation.

Infrared thermography allows imaging of the surface thermal distribution. Overlaying skin temperature depends on the complex relationships of heat exchange between skin tissue, inner tissue, local vasculature, and metabolic activity. Testicles hang freely in scrotal sacs and have $3-4^{\circ}C$ lower temperature than core body temperature (17). Important in maintenance of this lower temperature is heat clearance by pampiniform plexus. Therefore venous stasis in varicocele may cause elevated temperature of affected pampiniform plexus and/or testicle. Furthermore, recent study have demonstrated that impaired venous drainage leads to subsequent testicular hypoxia in the sperm production site (18). Effect of increased scrotal temperatures and hypoxia is impairment of male fertility. Current mainstay of varicocele diagnosis are physical examination and ultrasound/color doppler examination (11). Physical examination is subjective and furthermore it is insufficient in detecting small and subclinical varicocele (19). Potential disadvantages of ultrasound/doppler are that it chiefly depends on examiners experience and subjective impression and interpretation factors of the examiner. In addition, application of ultrasound in postoperative follow up is limited (20). On the other hand, thermography could provide an objective evaluation of subclinical varicocele (19, 21) and may prove useful in postoperative follow up- provided the criteria for diagnosis of varicocele prove reliable enough to reach a wider consensus. Potential disadvantage of scrotal thermography is inability to distinguish between vari-

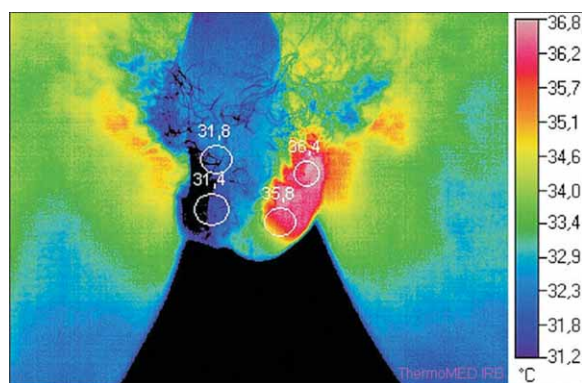


Figure 2. Scrotal infrared digital thermography of the patient with left sided varicocele grade III. Circles are placed at reference points with number indicating average temperature within the circle.

cocele and other scrotal pathology (i.e. testicular tumor, epididymitis).

Importance of detecting a subclinical varicocele lies in the fact that size of the varicocele does not influence fertility. In fact, even a subclinical varicocele can have damaging effect on sperm production (10). Bilateral varicocelectomy is reported to be useful in case of left clinical and right subclinical varicocele (22–25). Subsequent, enhancement in sperm production and fertility rate support this approach (22, 23). However, some authors oppose to the benefits of bilateral varicocelectomy (26).

Drawback of our study is lack of the control group which would enable to properly evaluate for the presence of right sided subclinical varicocele.

In our study, thermography successfully confirmed diagnosis of left sided varicocele (Figure 2). However, it should be noted that further studies are needed to establish reliable diagnostic criteria for scrotal thermography and to aid in diagnosing of right sided subclinical varicocele.

To conclude, digital infrared thermography presents feasible, low cost diagnostic method with possibly high sensitivity for varicocele. Further study on a larger number of patients and healthy participants is needed to evaluate sensitivity and specificity of this method and to establish consistent diagnostic parameters for thermographic assessment

Note: Presented at the 53rd International Symposium ELMAR-2011, 14-16 September 2011, Zadar, Croatia and in shorter form published in book of proceedings.

REFERENCES

1. ROMEO C, SANTORO G 2009 Varicocele and infertility: why a prevention? *J Endocrinol Invest* 32: 559–61
2. DUBIN L, AMELAR R D 1975 Varicocelectomy as therapy in male infertility: a study of 504 cases. *Fertil Steril* 26: 217–20
3. FICARRA V, CERRUTO M A, LIGUORI G, MAZZONI G, MINUCCI S, TRACIA A, GENTILE V 2006 Treatment of varicocele in subfertile men: The Cochrane Review—a contrary opinion. *Eur Urol* 49: 258–63
4. BENOFF S, GILBERT B R 2001 Varicocele and male infertility: part I. Preface. *Hum Reprod Update* 7: 47–54
5. JAROW J P 2001 Effects of varicocele on male fertility. *Hum Reprod Update* 7: 59–64
6. MARMAR J L 2001 The pathophysiology of varicoceles in the light of current molecular and genetic information. *Hum Reprod Update* 7: 461–72.
7. NAUGHTON C K, NANGIA A K, AGARWAL A 2001 Pathophysiology of varicoceles in male infertility. *Hum Reprod Update* 7: 473–81
8. GAT Y, BACHAR G N, ZUKERMAN Z, BELENKY A, GORNISH M 2004 Varicocele: a bilateral disease. *Fertil Steril* 81: 424–9
9. LEVINGER U, GORNISH M, GAT Y, BACHAR GN 2007 Is varicocele prevalence increasing with age? *Andrologia* 39: 77–80
10. DHABUWALA C B, HAMID S, MOGHISSI K S 1992 Clinical versus subclinical varicocele: improvement in fertility after varicocelectomy. *Fertil Steril* 57: 854–7
11. WATANABE Y 2002 Scrotal imaging. *Curr Opin Urol* 12: 149–53
12. YAMAMOTO M, HIBI H, HIRATA Y, MIYAKE K, ISHIGAKI T 1996 Effect of varicocelectomy on sperm parameters and pregnancy rate in patients with subclinical varicocele: a randomized prospective controlled study. *J Urol* 155: 1636–8
13. KOLARIC D, SKALA K, DUBRAVIC A 2006 ThermoWEB—remote control and measurement of temperature over the Web. *Period Biol* 108: 631–637
14. MERLA A, LEDDA A, DI DONATO L, ROMANI G L 2004 Assessment of the effects of varicocelectomy on the thermoregulatory control of the scrotum. *Fertil Steril* 81: 471–2
15. TUCKER A T 2000 Infrared thermographic assessment of the human scrotum. *Fertil Steril* 74: 802–3
16. NOGUEIRA F E, MEDEIROS F C, BARROSO L V, MIRANDA E P, DE CASTRO J D, MOTA FILHO F H 2009 Infrared digital telethermography: a new method for early detection of varicocele. *Fertil Steril* 92: 361–2
17. MIEUSSET R, BUJAN L 1995 Testicular heating and its possible contributions to male infertility: a review. *Int J Androl* 18: 169–84
18. GAT Y, ZUKERMAN Z, CHAKRABORTY J, GORNISH M 2005 Varicocele, hypoxia and male infertility. Fluid Mechanics analysis of the impaired testicular venous drainage system. *Hum Reprod* 20: 2614–9
19. GAT Y, BACHAR G N, ZUKERMAN Z, BELENKY A, GORNISH M 2004 Physical examination may miss the diagnosis of bilateral varicocele: a comparative study of 4 diagnostic modalities. *J Urol* 172: 1414–7
20. CVITANIC O A, CRONAN J J, SIGMAN M, LANDAU S T 1993 Varicoceles: postoperative prevalence—a prospective study with color Doppler US. *Radiology* 187: 711–4
21. COMHAIRE F, MONTEYNE R, KUNNEN M 1976 The value of scrotal thermography as compared with selective retrograde venography of the internal spermatic vein for the diagnosis of »subclinical» varicocele. *Fertil Steril* 27: 694–8
22. ELBENDARY M A, ELBADRY A M 2009 Right subclinical varicocele: how to manage in infertile patients with clinical left varicocele? *Fertil Steril* 92: 2050–3
23. LIBMAN J, JARVI K, LO K, ZINI A 2006 Beneficial effect of microsurgical varicocelectomy is superior for men with bilateral versus unilateral repair. *J Urol* 176: 2602–5; discussion 2605
24. PASQUALOTTO F F, LUCON A M, DE GOES P M, SOBREIRO B P, HALLAK J, PASQUALOTTO E B, ARAP S 2005 Is it worthwhile to operate on subclinical right varicocele in patients with grade II–III varicocele in the left testicle? *J Assist Reprod Genet* 22: 227–31
25. SCHERR D, GOLDSTEIN M 1999 Comparison of bilateral versus unilateral varicocelectomy in men with palpable bilateral varicoceles. *J Urol* 162: 85–8
26. ZHENG Y Q, GAO X, LI Z J, YU Y L, ZHANG Z G, LI W 2009 Efficacy of bilateral and left varicocelectomy in infertile men with left clinical and right subclinical varicoceles: a comparative study. *Urology* 73: 1236–40