

Otterbein University

Digital Commons @ Otterbein

Nursing Student Class Projects (Formerly MSN)

Student Research & Creative Work

Summer 7-27-2016

Cerebral Venous Thrombosis

Jennifer C. Lyons

Otterbein University, jennifer.lyons@otterbein.edu

Follow this and additional works at: https://digitalcommons.otterbein.edu/stu_msn



Part of the [Nursing Commons](#)

Recommended Citation

Lyons, Jennifer C., "Cerebral Venous Thrombosis" (2016). *Nursing Student Class Projects (Formerly MSN)*. 152.

https://digitalcommons.otterbein.edu/stu_msn/152

This Project is brought to you for free and open access by the Student Research & Creative Work at Digital Commons @ Otterbein. It has been accepted for inclusion in Nursing Student Class Projects (Formerly MSN) by an authorized administrator of Digital Commons @ Otterbein. For more information, please contact digitalcommons07@otterbein.edu.

Cerebral Venous Thrombosis

Jennifer C. Lyons BSN, RN, CCRN-E

Otterbein University, Westerville, Ohio

Introduction

Cerebral venous thrombosis (CVT) is a rare cause of stroke, primarily affecting young adults. CVT accounts for approximately 0.5% to 1% of all strokes (Saponsnik et al., 2011). Women are more susceptible than men, secondary to oral contraceptive use, pregnancy and puerperium (Sparaco, Feleppa & Bigal, 2015). CVT occurs due to extrinsic compression or a partially obstructing thrombus (Bansal, et al., 2016). The diagnosis and medical management is challenging due multiple genetic risk factors and various treatment approaches (Saponsnik et al., 2011).

Pathological Process

The two major pathophysiological mechanisms of CVT:

- 1. Extrinsic compression;** The thrombosis of cerebral veins of sinuses can cause an increase in venular and capillary pressure (Piazza, 2012).
 - As the local venous pressure increases, decreased cerebral perfusion results in ischemic injury and cytotoxic edema
 - Disruption of the blood-brain barrier leads to vasogenic edema
 - Venous and capillary rupture causes paraneural hemorrhage
- 2. Partially obstructing thrombus;** The obstruction of cerebral sinuses can cause insufficient cerebrospinal fluid absorption (Piazza, 2012).
 - Ordinarily, cerebrospinal fluid is absorbed through arachnoid granulations into the superior sagittal sinus

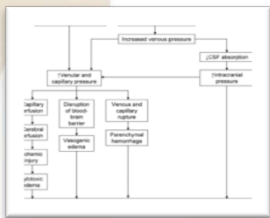

Figure 1. The pathophysiology of cerebral venous thrombosis (Piazza, 2012, p.1706).

- Thrombosis of the cerebral sinuses increases venous pressure, limits cerebrospinal fluid absorption, and causes increased intracranial pressure
- Intracranial pressure worsens venular and capillary hypertension and ultimately contributes to parenchymal hemorrhage and vasogenic and cytotoxic edema.

Risk Factors for Cerebral Venous Thrombosis

Table 1. The table below summarizes the risk factors for CVT as described by Piazza (2012, p. 1705).

Thrombophilia

Deficiencies in antithrombin, protein C, and protein S
Factor V Leiden mutation
Prothrombin gene mutation 20210
Antiphospholipid antibodies
Hyperhomocysteinemia

Women's health concerns

Pregnancy
Postpartum state
Hormonal contraceptive or replacement therapy

Infection

Localized infections such as otitis, mastoiditis, sinusitis
Meningitis
Systemic infectious disorders

Chronic inflammatory diseases

Vasculitides
Inflammatory bowel disease

Cancer

Hematologic disorders

Polycythemia
Essential thrombocytosis
Paroxysmal nocturnal hemoglobinuria

Trauma

Head trauma
Local injury to cerebral sinuses or veins
Jugular venous cannulation
Neurosurgical procedures
Lumbar puncture

Nephrotic syndrome

Signs and Symptoms

Unfortunately, the clinical presentation of CVT is not consistent, and regularly delays diagnosis. Four different syndromes have been identified including isolated intracranial hypertension, focal neurological abnormalities, seizures and encephalopathy. These signs and symptoms may occur in conjunction or independent of one another, subject to the location of the CVT (Piazza, 2012).

Intracranial hypertension caused by CVT most often presents as headache. Other clinical symptoms as a result of intracranial hypertension include papilledema and visual disturbances (Piazza, 2012).

According to Piazza (2012), just less than half, or 44% of patients with CVT, have focal neurological deficits. Motor weakness, including hemiparesis, is the most common sign. If a patient experiences CVT within the left transverse sinus, fluent aphasia can result.

Approximately 30-40% of patients who suffer CVT can present with focal or generalized seizures, including status epilepticus. As seizures are less common in other types of stroke, CVT should be weighed heavily. Seizures is most often recognized with thrombosis of the sagittal sinuses and cortical veins (Pizazza, 2012).

Encephalopathy presents most often from thrombosis of the straight sinus and its branches. Encephalopathy can also result from severe cases of cerebral venous thrombosis with widespread cerebral edema, large venous infarcts, or herniation caused by parenchymal hemorrhage. Elderly patients more often show signs of mental status changes rather than younger patients (Piazza, 2012)

Diagnosis

Hematologic studies including, chemistry panel, complete blood count and prothrombin time (PT), and activated partial thromboplastin time is encouraged in suspected CVT patients.

The three different imaging techniques that can be used to diagnose CVT include magnetic resonance imaging (MRI) with MR-venography, computerized tomography (CT)-venography and catheter angiography. MRI is the most commonly used imaging technique. Diagnosis of CVT requires the practitioner to visualize the thrombus within the vessel in combination with absent flow on MR-venography (Coutinho, 2015).

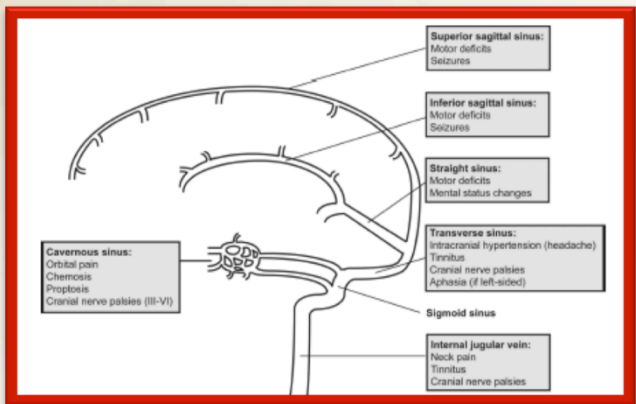


Figure 2 . Major clinical syndromes as defined by the location of the cerebral venous thrombus (Piazza, 2012, p.1706).

Treatment

Anticoagulation

Heparin is the "go-to" therapy for CVT and is recommended by the international guidelines. Due to the increased safety of low molecular heparin, it is preferred rather than unfractionated heparin, unless rapid reversal may be required (Bansal et al., 2016).

Endovascular treatment (ET)

There are two separate approaches for ET: intrasinus thrombolysis and mechanical thrombectomy. Thrombectomy has been more popular recently more than likely due to the fact it is suspected to have a lower risk of hemorrhagic complications (Bansal et al., 2016).

Decompressive surgery (DS)

A small percentage of patients develop a large venous hemorrhagic infarct causing brain displacement, transtentorial or subfalxine herniation. These patient present with decreased LOC and deteriorate rapidly. Immediate intervention is required for any chance of recovery (Bansal et al., 2015).

Bansal et al (2015) describes DS as when "part of the skull on the side of the lesion is temporarily removed to decrease the mass effect and reverse brain displacement" (p. 242).

Nursing Implications

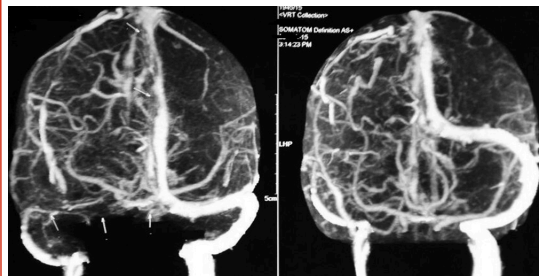
In conjunction with a neurologist, the nurse may assist in the management of CVT in the following ways (Jalili et al., 2013):

- Stabilize the patient
- Management of complications
- Assist in the removal of the thrombus in the vein
- Administer anticoagulation to prevent the clot from increasing in size
- Administer thrombolytics
- Administer antiepileptic drugs
- Treat the patient's underlying risk factors
- Participate in the long-term management of symptoms

Case Study

A 36-year-old female, MK, presented to the emergency department with altered mental status and right hemiplegia. Family reports she has a history of a severe headache. Her Glasgow Coma Scale on admission was E1M3V1. Her left pupil was dilated and not reactive to light. Computed Tomography (CT) of the head showed venous infarct in the leftfronto-temporo-parietal region with linear area of hemorrhage. CT venography reported thrombosis in the superior sagittal sinus, extending to adjacent cortical veins. She underwent emergent surgery, and a left fronto-temporo-parietal decompressive craniectomy was performed. Unfortunately the patient expired on post-op day 1 (Bansal et al., 2016).

Figure 3. Computed tomography venography showing superior sagittal sinus thrombosis (Bansal et al, 2016, p. 2).



Conclusion

Cerebral venous thrombosis is a very rare form of stroke, affecting mostly young women (Spanosnik et al., 2011). There are two major pathophysiological causes of stroke: extrinsic compression and partially obstructing thrombus as described by Piazza (2012). There are many risk factors for CVT, including thrombophilia, women's health concerns, infection, chronic inflammatory disease, cancer, hematologic disorders, trauma and nephrotic syndrome (Piazza (2012). More often than not, the diagnosis of CVT is delayed as the presentation is inconsistent. There are four major syndromes associated with CVT. Symptoms are dependent on which area of the brain is affected. A majority of patient report a severe headache (Piazza, 2012). Treatment includes, but is not limited to, anticoagulation, endovascular treatment and decompressive surgery (Bansal et al., 2015).

References

Bansal, H., Chaudhary, A., Mahajan, A., & Paul, B. (2016). Acute subdural hematoma secondary to cerebral venous sinus thrombosis: Case report and review of literature. *Asian Journal Of Neurosurgery*, 11(2), 177. doi: 10.4103/1793-5482.175632

Coutinho, J. M. (2015). Cerebral venous thrombosis. *Journal Of Thrombosis And Haemostasis: JTH*, 13 Suppl 1S238-S244. doi:10.1111/jth.12945

Jalili, M., Ghourchian, S., Shahidi, G., Rohani, M., Rezvani, M., & Zamani, B. (2013). A study of factors associated with cerebral venous thrombosis. *Neurological Sciences*, 34(3), 321-326. doi:10.1007/s10072-012-0997-x

Saponsnik, G., Barinagarrementeria, F., Brown, R. D., Bushnell, C. D., Cucchiara, B., Cushman, M., ... & Tsai, F. Y. (2011). Diagnosis and management of cerebral venous thrombosis: a statement for healthcare professionals from the American Heart Association/American Stroke Association. *Stroke*, 42(4), 1158-1192. doi: 10.1161/STR.0b013e31820a8364

Sparaco, M., Feleppa, M., & Bigal, M. E. (2015). Cerebral Venous Thrombosis and Headache - A Case-Series. *Headache: The Journal Of Head & Face Pain*, 55(6), 806-814 9p. doi: 10.1111/head.12599

Piazza, G. (2012). Cerebral venous thrombosis. *Circulation*, 125(13), 1704-1709. doi: 10.1161/CIRCULATIONAHA.111.067835

Additional References

DeFilippis, E. M., Barfield, E., Leifer, D., Steinfeld, A., Bosworth, B. P., Scherl, E. J., & Sockolow, R. (2015). Cerebral venous thrombosis in inflammatory bowel disease. *Journal Of Digestive Diseases*, 16(2), 104-108. doi: 10.1111/1751-2980.12212

Lu, A., Shen, P. Y., Dahlin, B. C., Nidecker, A. E., Nundkumar, A., & Lee, P. S. (2016). Cerebral venous thrombosis and infarct: Review of imaging manifestations. *Applied Radiology*, 45(3), 9-17 7p.

Thammishetti, V., Dharanipragada, S., Basu, D., Ananthakrishnan, R., & Surendiran, D. (2016). A prospective study of the clinical profile, outcome and evaluation of D-dimer in cerebral venous thrombosis. *Journal Of Clinical & Diagnostic Research*, 10(6), 7-10. doi:10.7860/JCDR/2016/19114.7926

Thorell, S. E., Parry-Jones, A. R., Punter, M., Hurford, R., & Thachil, J. (2015). Review: Cerebral venous thrombosis—A primer for the haematologist. *Blood Reviews*, 2945-50. doi:10.1016/j.blre.2014.09.006