

VETERINARSKI ARHIV 81 (6), 773-777, 2011

Ultrasonographic diagnosis of retinal detachment in a horse - case report

Deepak Patil^{1*}, Pinesh Parikh¹, Nisha Joy¹, Shivrajsinh Jhala¹,
Aarti Pitroda¹, and Madhvi Sheth²

¹Department of Surgery and Radiology, College of Veterinary Science and A.H., Agricultural University,
Anand, India

²Consultant Vitreoretinal Surgeon, Govind Eye Clinic, Baroda, India

PATIL, D., P. PARIKH, N. JOY, S. JHALA, A. PITRODA, M. SHETH:
Ultrasonographic diagnosis of retinal detachment in a horse - case report. Vet. arhiv
81, 773-777, 2011.

ABSTRACT

A horse presented with a history of vision loss not due to trauma, and clinically there was moderate corneal opacity. Real time B mode ultrasonography was performed using a linear transducer (7.5 to 18 MHz) and it revealed retinal detachment and migration of a *Setaria* sp. worm from the anterior chamber to the posterior chamber.

Key words: B-mode ultrasonography, retinal detachment, uveitis, cataract, eyeworm

Introduction

A B scan is the most common mode of ultrasonography used clinically in veterinary ophthalmology, as it provides a two dimensional real time image of the eye and orbit (SCOTTY et al., 2004). It is a quick, safe and practical method for examination of intraocular and retrobulbar structures in an alert horse. The most common clinical indications of ocular ultrasonography in the horse are evaluating for the presence of retinal detachment in the eyes after trauma, with uveitis, hyphema, cataracts, and severe corneal opacities (oedema, fibrosis) and as preoperative cataract surgery evaluation (WILKIE, 1991). This case report describes retinal detachment and migration of a *Setaria* worm from the anterior chamber to the posterior chamber in a horse.

*Corresponding author:

Dr. D. B. Patil, M.V.Sc., Ph.D. (Veterinary Surgery), Professor and Head, Department of Surgery and Radiology, College of Veterinary Science and A.H., Anand Agricultural University, Anand - 388 001, India, Phone: +91 98 2542 7650; E-mail: db1680@gmail.com

ISSN 0372-5480
Printed in Croatia

Materials and methods

A 6 year old female kathiawadi horse presented with vision loss in the left eye for the previous month. After obtaining a detailed history pertaining to visual disturbance, a systematic ophthalmic examination, including indirect ophthalmoscopy and ultrasonography, was conducted. Real time B mode ultrasonography was performed using a linear transducer (7.5 to 18 MHz) on the non-sedated animal, in a standing position. The globe was imaged in the horizontal, vertical and oblique planes through the visual axis, and observations were correlated with the anamnesis and clinical findings to arrive at a diagnosis.

Results

History ruled out a traumatic episode. Clinically there was blepharospasm, epiphora and moderate corneal opacity (nebula). Indirect ophthalmoscopy revealed fibrin flakes in the aqueous chamber and severe myosis, which prevented visualization of other intraocular structures. Thus ultrasonography was performed for further ocular examination.

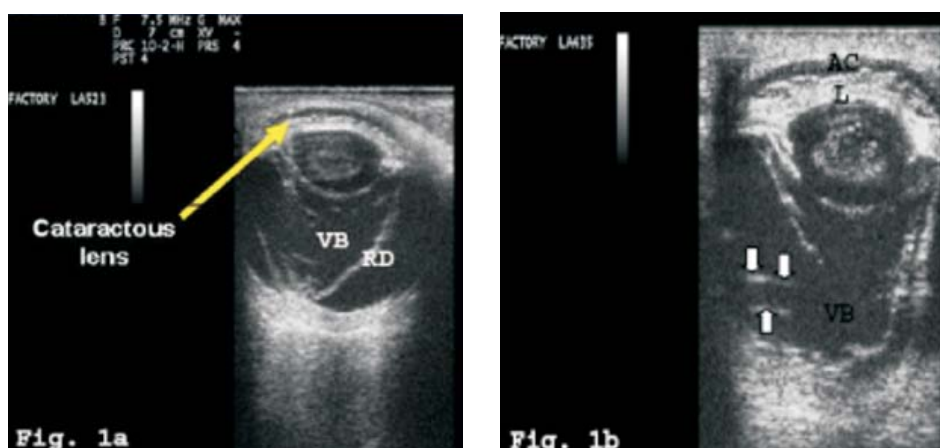


Fig. 1. USG image of left eye (7.5 and 10 MHz linear probe). Detached retina (RD) seen as hyperechoic membrane in the vitreous body (VB) (1a). Anterior chamber (AC) has become shallow and has lost normal anechoic appearance. Setarial worm (arrows) is seen as a hyperechoic structure within vitreous body (1b).

On ultrasonography, diffused hyperechoic foci was found in the aqueous chamber and the iris (usually seen as a hyperechoic membrane anterior to the lens) was found to be adhered to the anterior lens capsule, suggestive of fibrin accumulation in the anterior chamber and posterior synechia. The entire lens was echogenic indicating a complete

cataract. In the posterior segment retinal detachment was evident, where the detached retina appeared as a smooth, complete, hyperechoic membrane in the vitreous (Fig. 1). In the sagittal plane, the detached retina looked like an isosceles triangle open towards the anterior segment. On real time ultrasonography a hyperechoic structure was found to be moving within the vitreous. All observations in the contralateral eye were found to be normal except for cataract (Fig. 2).

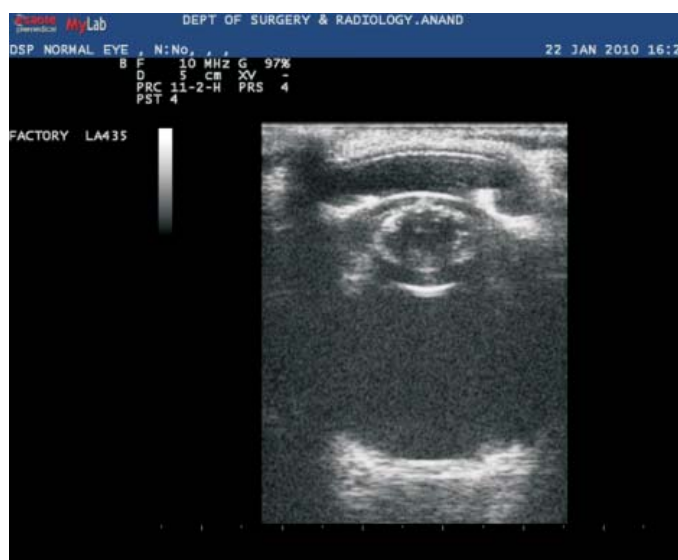

Fig. 2. Ultrasonogram of contralateral (right) eye showing cataract

Discussion

Ocular ultrasonography allows examination of the globe in conditions in which opacity of the transmitting media of the eye (cornea, aqueous humor, lens, and vitreous humor) or extreme eyelid swelling otherwise prevents a complete ophthalmic examination (GILGER, 2006). The transcorneal technique of scanning was adopted after using topical anaesthesia (proparacaine 0.5%, Alcaine, Alcon Laboratories) (WILLAMS and WILKIE, 1996). The transducer, when placed directly on the cornea, provides superior images of the posterior segment or orbit, when compared to those obtained through closed eyelids or with the use of an offset device. Sedation and/ or regional nerve blocks may be required, depending on the temperament and level of discomfort of the horse and globe stability (METTENLEITER, 1995).

Of the various frequencies used, 10 and 7.5 MHz gave images with good detail. A 10 MHz transducer is optimal for general use as it provides adequate depth of penetration and enhanced resolution to visualize the anterior and posterior chambers. Alternatively 7.5 MHz also produces good ophthalmic images and has better penetration for visualization of retrobulbar structures (MICHAU, 2005). However, near field reverberation artifacts obscure the anterior segment unless ample amount of sterile coupling gel are used.

Aberrant migration of *Setaria* sp. into the eye, resulting in severe intraocular inflammation has been reported (LEVINE, 1980). The motile structure in the vitreous was hypothesized to be setarial worm as we had previous incidence of locating *Setaria* sp. in the vitreal cavity and its surgical removal. The lashing movement of the worm may have augmented trauma and inflammation of the intraocular structures, leading to severe uveitis, cataracts and retinal detachment. This is evident from the clinical signs and ultrasonographic findings. As the retina was found to be detached the animal was not subjected to surgery for eye worm removal.

The retinal echo is indistinguishable from the underlying choroidal and scleral echo in a normal eye (WILLIAMS and WILKIE, 1996). The retina becomes apparent as a distinct echodensity with a separation of 0.5 to 1.0 mm (ROGER, 1986). Most often the retina remains attached at the optic disc posteriorly and at the ora serrata laterally, resulting in a classic funnel, sea gull wing or morning glory appearance on detachment on ultrasonogram (SPAULDING, 2008). Initially, retinal detachments will be seen to undulate in real time, but with chronicity, the retina will become fixed and less mobile (BYRNE and GREEN, 2002).

Thus, the present case depicts the ultrasonographic diagnosis of retinal detachment (RD) in a horse, probably induced by a migrated worm (*Setaria* sp.) from the anterior chamber into the posterior chamber.

References

- BYRNE, S. F., R. L. GREEN (2002): Ultrasound of the eye and orbit. 2nd edition. St Louis Mo. Mosby.
- GILGER, B. C. (2006): Ocular ultrasound - Technique and diagnosis. Proceedings of the North American Veterinary Conference, Small Animal Edition, Volume 2, Orlando, Florida. pp 873-874.
- LEVINE, N. D. (1980): Nematode Parasites of Domestic Animals and Man, Minneapolis, Burgess.
- METTENLEITER, E. M. (1995): Sonographic diagnosis (B mode technique) for the eyes in the horses. Methods and normal findings. Tierärztl. Prax. 23, 481-488.
- MICHAU, T. M. (2005): Equine ocular examination: basic and advanced diagnostic techniques. In: Equine Ophthalmology (Gilger, B. C., Ed.) Elsevier Saunders Press. Missouri. p. 46.

D. Patil et al.: Ultrasonographic diagnosis of retinal detachment in a horse

- ROGER, M. (1986): Evaluation of the extirpated equine eye using B-mode ultrasonography. *Vet. Radiol.* 27, 24-29.
- SCOTTY, N. C., T. J. CUTLER, D. E. BROOKS, E. FERREL (2004): Diagnostic ultrasonography of equine lens and posterior segment. *Vet. Ophthalmol.* 7, 127-139.
- SPAULDING, K. (2008): Eye and orbit. In: *Atlas of Small Animal Ultrasonography*. (Penninck, D., Marc-Andre d' Anjou, Eds.) Blackwell Publishing. USA. pp. 72-73.
- WILKIE, D. A. (1991): Ophthalmic procedures and surgery in standing horse. *Vet. Clinics North Am. Equine Pract.* 7, 535-547.
- WILLIAMS, J., A. WILKIE D (1996): Ultrasonography of the eye. *Comp. Contin Edu. Pract. Vet.* 18, 667-677.

Received: 28 November 2010

Accepted: 6 May 2011

PATIL, D., P. PARIKH, N. JOY, S. JHALA, A. PITRODA, M. SHETH: Ultrazvučna dijagnostika ablacije mrežnice u konja - prikaz slučaja. *Vet. arhiv* 81, 773-777, 2011.

SAŽETAK

Na pregled je bio doveden konj koji je prema anamnestičkim podacima izgubio vid zbog ozljede. Kliničkim pregledom ustanovljeno je umjereno zamućenje rožnice. Ultrazvučnom dijagnostikom B prikazom u stvarnom vremenu linearnom sondom (7,5 do 18 MHz) ustanovljena je ablacija mrežnice i migracija parazita *Setaria* sp. s prednje u stražnju očnu komoricu.

Ključne riječi: ultrazvuk, B prikaz u stvarnom vremenu, ablacija mrežnice, uveitis, siva mrena, *Setaria*
