

Epidermoid cyst in presacral space

Epidermoidna cista presakralnog područja

Martina Džoić^{1*}, Jana Fila², Mislav Čavka³, Mirjana Vukelić-Marković³, Boris Brkljačić³

¹Odjel radiologije Županijske bolnice Orašje, Orašje, Bosna i Hercegovina

²Odjel za dijagnostičku i intervencijsku radiologiju, Klinika za tumore, Zagreb

³Klinički zavod za dijagnostičku i intervencijsku radiologiju, KB Dubrava, Zagreb

Priljeno: 19. 5. 2011.

Prihvaćeno: 11. 8. 2011.

Adresa za dopisivanje:

*Martina Džoić, dr. med.

Odjel radiologije Županijske bolnice Orašje

III. ulica, 76 270 Orašje, BiH

e-mail: martina.dzoic@gmail.com

<http://hrcak.srce.hr/medicina>

Sažetak. Cilj: Cilj je ovoga rada prikazati epidermoidnu cistu presakralnog područja koja je rijedak tumor ovog područja, te ima osobitosti u prikazu slikovnim metodama. Prema našim saznanjima, često su opisivane slikovne karakteristike intrakranijalnih epidermoidnih cisti, ali su se u samo nekoliko prethodno objavljenih radova opisivale osobitosti epidermoidnih cisti presakralnog područja. **Prikaz slučaja:** Tridesetdvogodišnjoj ženi pri teškom porodu primijećen je velik tumor koji se sa stražnje strane utiskivao u porođajni kanal. Nakon oporavka javila se zbog daljnje obrade. Učinjen je pregled višeslojnom kompjutoriziranom tomografijom s intravenskom aplikacijom kontrastnog sredstva koji je pokazao cističnu leziju presakralnog područja lijevo s tankom rubnom imbibicijom kontrastnim sredstvom bez unutarnje opacifikacije lezije. Daljnjom obradom koja je uključivala magnetsku rezonanciju dokazane su morfološke karakteristike epidermoidne ciste s visokim sadržajem proteina (heterogeni signali na T1 i T2 sekvenci). Bolesnica je operirana, a patohistološkim nalazom potvrđena je epidermoidna cista s visokim sadržajem proteina. **Rasprava i zaključak:** Razvojne ciste presakralnog područja su rijetke, te se u literaturi ne nalazi mnogo podataka o radiomorfološkim karakteristikama cista toga područja. Epidermoidna cista ima određene morfološke karakteristike po kojima se može pretpostaviti dijagnoza.

Ključne riječi: cista, epidermoidna, MRI, MSCT, presakralno područje, radiologija

Abstract. Aim: The aim of this article was to present a case of epidermoid cyst, which is a rare tumor in this area and has some specific imaging features. To our knowledge, intracranial epidermoid cysts and its imaging features were often described, but only a few cases have been previously reported with imaging features of presacral epidermoid cysts. **Case report:** A 32-year-old woman presented with symptoms of difficult labor, and during the childbirth, a large tumor pressing from behind in to the birth canal was noticed. After recovery, multislice computerized tomography (MSCT) with intravenous contrast administration was performed. A cystic lesion in the presacral space on the left side with thin ring enhancement and no internal enhancement was demonstrated. Further magnetic resonance imaging (MRI) showed morphologic features of epidermoid cyst with high protein content (heterogeneous signal on T1W and T2W). Surgery was performed and pathohistological analysis confirmed the diagnosis of epidermoid cyst with high protein content. **Discussion and conclusion:** Developmental cysts in presacral space are rare and there is not much literature on radiomorphologic features of cysts in this area. Epidermoid cyst has certain morphologic features which can aid in setting the diagnosis.

Keywords: cyst, epidermoid, MRI, MSCT, presacral area, radiology

INTRODUCTION

The presacral space, often referred as a retrorectal space, is a potential space which lies anterior to the sacrum and coccyx and posterior to the rectum¹.

Developmental cysts of retrorectal region are rare in adults. About half of all developmental cysts are hamartoma/mucinous cysts (including so called tail-gut cysts); these are followed in frequency by dermoid/epidermoid cysts, teratomas and rectal duplication cysts. Neoplastic tumors and inflammation with cystic degeneration can also occur in the perirectal region. These include GIST, neurogenic tumors, anorectal carcinomas and perineal abscess. Histological, dermoid cysts are differentiated from epidermoid cysts by the presence of the cutaneous adnexal structures².

Epidermoid cyst of the presacral space is a rare benign congenital lesion of ectodermal origin. Histological it often has a thin wall lined by stratified squamous epithelium, surrounding a mixture of desquamated debris, cholesterol, keratin and water.

The epidermoid cyst develops from the remnants following the development and disappearance of the neurenteric canal, proctodeal membrane or postanal gut. It most often occurs in women, being rarely encountered in men³.

Symptoms are often related to local compression on the rectum, which causes constipation, rectal fullness, painful defecation, and lower abdominal pain, and to local compression on the lower urinary tract, which causes dysuria and urinary frequency⁴. The commonest symptom was pain over the sacrum. Patients also can be symptom less⁵. Usually such cysts appear as rectal masses or as causes of recurrent perianal abscess and sinus⁶.

CASE REPORT

A 32-year-old woman, without positive clinical history, presented with symptoms of difficult labor, and during the childbirth a large tumor pressing from behind into the birth canal was noticed. After recovery, multislice computed tomography (MSCT) with intravenous contrast administration

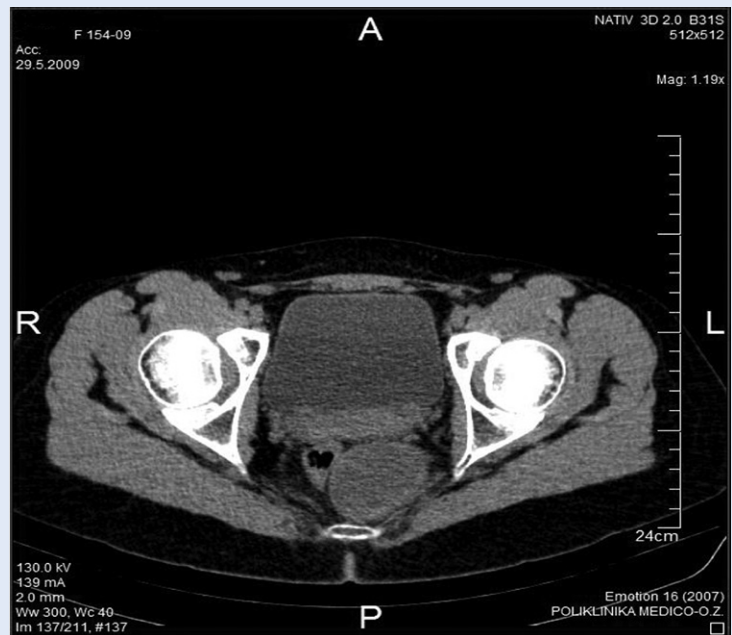


Figure 1: MSCT image: isodense cystic lesion in presacral space on the left.

Indication for magnetic resonance imaging (MRI) was set. MRI was performed using a 1.5 Tesla unit. T1-weighted (T1W), T1 fat saturation technique (T1 fat sat), T2-weighted (T2W) and gadolinium (Gd) – enhanced T1W images were undertaken. The tumor was noticed in presacral space on the left side and was sharply demarcated with mixed signal intensities on T1W images. On T1

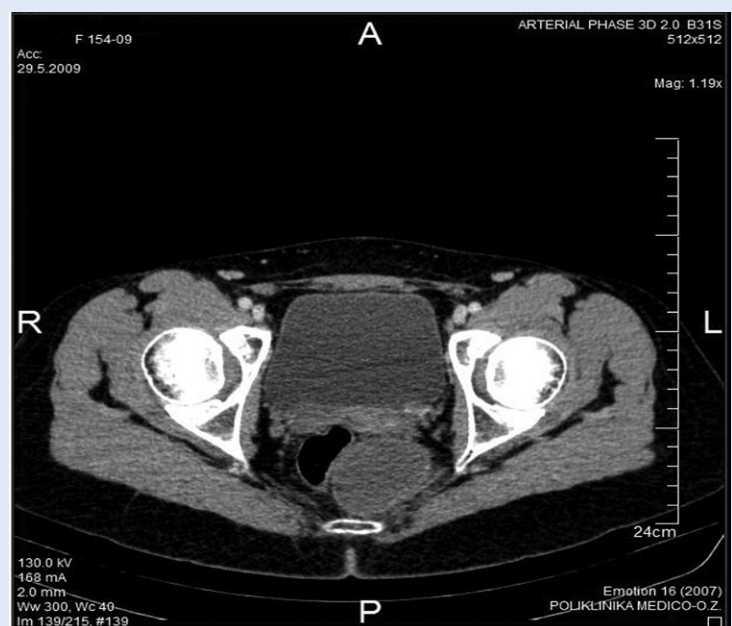


Figure 2: MSCT image: After iv. contrast administration, the MSCT showed only a thin ring enhancement and no internal enhancement of the lesion.

was performed. It showed an isodense cystic lesion in presacral space on the left side with thin ring enhancement and no internal enhancement (Figure 1 and 2).

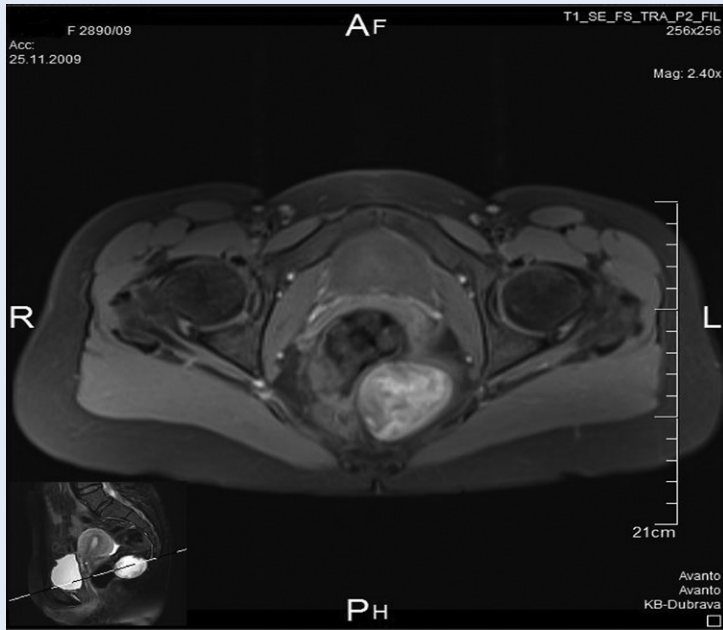


Figure 3: MRI T1 fat sat images: A sharply demarcated cystic lesion was found with heterogenous but mainly high signal intensity.

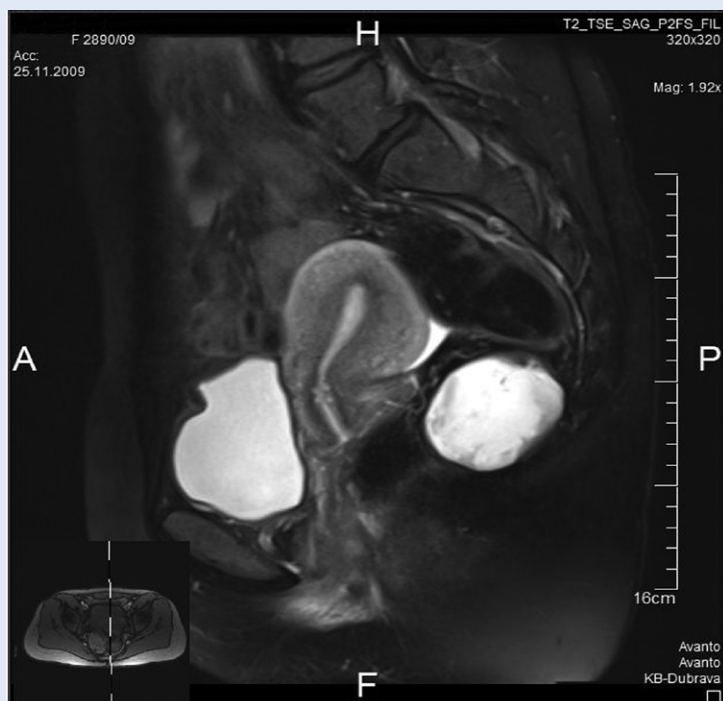


Figure 4: MRI T2W images: The tumor had heterogenous but mainly high signal intensity.

fat sat images the tumor was sharply demarcated cystic lesion with heterogenous, but mainly, high signal intensity (Figure 3). The tumor had heterogenous, but mainly, high signal intensity also on T2W images (Figure 4). On Gd enhanced T1W the lesion had only ring enhancement without enhancement inside the lesion (Figure 5).

Surgery was performed and pathology confirmed epidermoid cyst with high protein content.

DISCUSSION

The radiological findings from plain radiography and barium enema examination have been described¹⁰. Barium enema examination of such a cyst shows an extrinsic retrorectal mass, but differential diagnosis with other retrorectal tumors is not possible³.

Plain radiography uncommonly shows sacrococcygeal abnormalities such as a bone defect. A communication between the cyst and the anorectal lumen and widening of the retrorectal space on a lateral view of the pelvis may be demonstrated during a barium enema examination.

On ultrasonography a developmental cyst appears as a unilocular or multilocular retrorectal cystic lesion, sometimes with internal echoes due to mucoid material or inflammatory debris⁷.

On CT images, epidermoid cysts generally appear as thin walled cystic masses with fluid density and may contain calcification. They may appear hyperdense on precontrast CT scans, possibly due to a high protein content, prior bleeding, the abundance of polymorphonuclear leukocytes, saponification of the debris to calcium soaps, or deposition of iron-containing pigment³. If secondarily infected, the cyst may be thick walled with surrounding inflammatory changes. Uncommonly, the cyst may contain air due to an anorectal fistula⁷.

Although CT demonstration of a smooth margin and the absence of invasion of surrounding structures helps differentiate a benign mass from malignant tumors and concurrent infection, distinguishing between epidermoid cyst and other presacral cystic masses may be difficult³.

In intracranial epidermoid cysts, although MR signal intensity patterns can be variable, the most common MR findings have been reported as a

cyst with a thin wall, hypointensity on T1-weighted images, and hyperintensity on T2-weighted images. Epidermoid cysts have usually shown heterogeneous signal intensity on T1- and T2-weighted MR images. The MR characteristics of epidermoid cysts depend on the relative composition of cholesterol and keratin within the cyst. Their heterogeneous signal intensity, as seen on both T1- and T2-weighted MR images, is due to keratinous materials³.

CONCLUSION

The differential diagnosis of presacral cystic masses includes dermoid cyst, tailgut cyst, duplication cyst, anal gland cyst and anterior meningocele.

A dermoid cyst is lined with squamous epithelium with dermal appendage, while a tailgut cyst is a congenital lesion characterized by the presence of cysts lined with multiple, various types of epithelia such as columnar, squamous or transitional. A duplication cyst is lined with columnar or cuboidal epithelia and has a smooth muscle.

A dermoid cyst usually has fat in the cystic lesion, and can be diagnosed on CT or MRI.

Most reported MRI findings of other presacral cystic masses have a described homogeneous signal intensity on both T1- and T2-weighted images³. High signal intensity on T1-weighted images is likely secondary to mucoid (tailgut cysts) or fatty (dermoid cysts) content⁴ or it may have high signal intensity on T1-weighted images due to presence of high protein content, or hemorrhage in the cyst. Among the presacral cystic masses, epidermoid cyst, dermoid cyst, rectal duplication cyst and meningocele are usually unilocular⁷.

Although heterogeneous signal intensity can also be seen in cases of hemorrhage, calcification or high protein content within a cyst, subtle signal heterogeneity on both T1- and T2-weighted images is a characteristic findings of epidermoid cysts³.

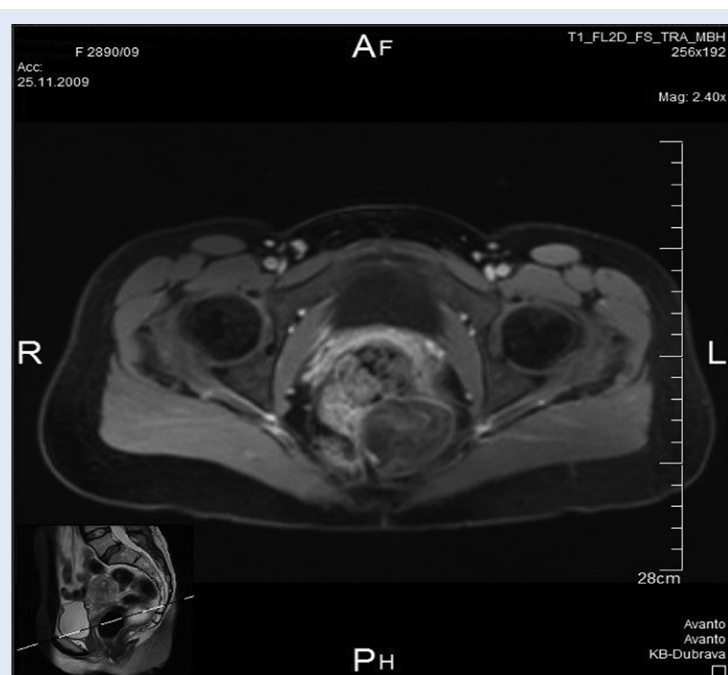


Figure 5: Gadolinium enhanced MRI T1W images: The lesion had only ring enhancement without enhancement inside the lesion.

Epidermoid cyst of the presacral space is a rare benign congenital lesion of ectodermal origin. Histologically it often has a thin wall lined by stratified squamous epithelium, surrounding a mixture of desquamated debris, cholesterol, keratin and water.

LITERATURE

1. Bennett EU, Johnson RJ. Presacral tumors and cysts in adults. *Diseases of the colon & rectum* 1975;18:581-96.
2. Sasaki A, Sugita S, Horimi K, Yasuda K, Inomata M, Kitano S. Retrorectal epidermoid cysts in an elderly woman: report of a case. *Surgery today* 2008;38:761-4.
3. Yang DM, Yoon MH, Kim HS, Kim HS, Chung S, Chung JW et al. CT and MR findings of presacral epidermoid cyst. *J Korean Radiol Soc* 1999;41:545-7.
4. Dahan H, Arrive L, Wendum D, Ducou le Pointe H, Djouhri H, Tubiana JM. Retrorectal developmental cysts in adults clinical and radiological – histopathologic review, differential diagnosis and treatment. *RadioGraphics* 2001;21:575-84.
5. McColl I. The Classification of Presacral Cysts and Tumors. *R Soc Med* 1963;56:797-8.
6. Ranson JHC, Harris MN. Retrorectal epidermoid cyst. *Diseases of the colon & rectum* 1968;12:26-9.
7. Yang BL, Gu YF, Shao WJ, Chen HJ, Sun GD, Jin HJ et al. Retrorectal tumors in adults: magnetic resonance imaging findings. *World J Gastroenterol* 2010;16:5822-9.