

Ana Kotarac Knežević¹, Spomenka Manojlović²

Marsupijalizacija keratocističnog odontogenog tumora mandibule: suvremena dilema

Marsupialisation of Keratocystic Odontogenic Tumour of the Mandible - Current Dilemma

¹ Zavod za oralnu kirurgiju Stomatološkog fakulteta Sveučilišta u Zagrebu
Department of Oral Surgery, School of Dental Medicine, University of Zagreb, Zagreb, Croatia

² Zavod za kliničku i eksperimentalnu patologiju Kliničke bolnice Dubrava, Zagreb
Department for Clinical and Experimental Pathology, University Hospital Dubrava, Zagreb, Croatia

Sažetak

Autori predstavljaju rezultate liječenja keratocističnog odontogenog tumora (KCOT-a) čeljusti kirurškim postupkom marsupijalizacije u kontekstu suvremenih dilema koje se o tom problemu mogu naći u literaturi. Na temeljno pitanje, može li marsupijalizacija biti konačan postupak u liječenju KCOT-a, još se ne može sa sigurnošću odgovoriti ni na osnovi podataka iz literature ni pozitivnih podataka predstavljenih u radu. Prikaz nešto promijenjenih rezultata liječenja uzorka iz ranije publiciranog rada i dvaju slučajeva nakon toga izvješća, autorima daju za pravo tvrditi da je marsupijalizacija metoda izbora, s vjerojatnošću da bude i konačan postupak u liječenju KCOT-a. Prema suvremenim podacima iz literature traži se i nadalje višegodišnje postoperativno praćenje pacijenata i primjena dodatnih sredstava liječenja kako bi se spriječili recidivi.

Zaprimljen: 31. siječnja 2011.

Prihvaćen: 29. lipnja 2011.

Adresa za dopisivanje

Ana Kotarac Knežević
Sveučilište u Zagrebu
Stomatološki fakultet
Zavod za oralnu kirurgiju
Gundulićeva 5, 10 000 Zagreb
Tel: + 385 1 4802 111
akotarac@sfzg.hr

Ključne riječi

Gorlin-Goltz sindrom; odontogena keratocista; donja čeljust; marsupijalizacija; kirurški postupak

Uvod

Keratocistični odontogeni tumor (KCOT) (1) patološka je promjena čeljusti odontogene etiologije, najčešće se svrstava među ciste, a tijekom godina imao je nekoliko različitih naziva, kao što su dermoidna cista, epidermoidna cista, cholesteatoma, primordijalna cista i odontogena keratocista.

Prema podacima u domaćoj literaturi, među cističnim promjenama čeljusti u vezi s donjim umnjakom bilo je oko 12 posto slučajeva (2), a nešto manje – 10,78 posto nađeno je među čeljusnim cistama (3), dok je pojavnost KCOT-a među odontogenim promjenama koje stvaraju cistične prozračnosti u čeljusti u zadnjem uzorku bila 19,72 posto (4). Postotci se u svjetskoj literaturi neznatno razlikuju, ovisno o tome jesu li se slučajevi KCOT-a tražili u uzorku svih cističnih promjena čeljusti (3,3% do 11,2%) (5), u uzorku odontogenih cista čeljusti (2,5% do 21,8%) (4,5) ili u uzorku cista u vezi s Gorlin-Goltzovim sindromom (65% do 75%) (6).

Koji su etiološki čimbenici i koja tkiva odgovorni za nastanak KCOT-a može se pretpostaviti na temelju raščlambe histološke građe. Je li to caklinski organ redovitoga ili pre-

Introduction

Keratocystic odontogenic tumour (KCOT) is a pathological lesion of the jaws of odontogenic aetiology, most frequently classified among cysts, and in the past referred to by various synonyms, such as: dermatoid cyst, epidermoid cyst, cholesteatoma, primordial cyst, odontogenic keratocyst (1).

According to data in Croatian literature, among the cystic lesions of the jaws approximately 12% of cases (2) are associated with the lower wisdom tooth, and a slightly lower percentage of 10.78% are found among jaw cysts (3), while the occurrence of KCOT among odontogenic lesions which create cystic translucency of the jaws, in the last sample of our study, amounted to 19.72% (4). In the world literature percentages differ only slightly, according to whether the cases of KCOT were taken from a sample of all cystic lesions of the jaws (3.3%-11.2%) (5), a sample of odontogenic cysts of the jaws (2.5%-21.8%) (4,5) or in a sample of cysts associated with Gorlin Goltz's Syndrome (65%-75%) (6). Which aetiological factors and which tissue were responsible for the occurrence of KCOT can be determined on the basis of an analysis of histological material. It is not particularly important

kobrojnoga zuba prije početka kalcifikacije ili su to epitelni ostatci zubne gređice ili bazalni slojevi epitela usne šupljine, nije osobito važno (7,8). No, njegova histološka i histokemijska građa s odgovarajućom potentnošću epitela odgovorne su za razvoj postoperativnih recidiva. Jesu li za to odgovorni i neki drugi čimbenici ili više njih, to su pitanja na koja se odgovori još istražuju.

Recidivi KCOT-a pojavljuju se u rasponu od 25 do 62,5 posto (8), a drugi navode raspon od 6 do 60 posto (9). U domaćoj literaturi u uzorku od 82 slučaja spominje se recidiv od 20,83 posto (3), a čimbenici koji su korelirali s nastankom recidiva bili su spol, veličina i lokalizacija ciste. Nisu nađeni elementi koji bi povezali kirurški postupak s nastankom recidiva. Usporedno istraživanje učestalosti recidiva KCOT-a i ameloblastoma (10) pokazalo je sličnu učestalost obiju tvorbi, a posebice onih u donjoj čeljusti; od 74 slučaja KCOT-a, 62 ili 83,78 posto bili su smješteni u donjoj čeljusti i operirani su raznim tehnikama; ukupno je bilo 16 recidiva (19,51%) od čega je 14 bilo u donjoj čeljusti ili 87,50 posto. Slični su podatci dobiveni i za ameloblastome s nešto većom učestalošću recidiva onih u donjoj čeljusti. Autori koji su smatrali da je kirurški postupak uzrok recidiva (11) bili su skloni izboru Broscheve metode u liječenju (KCOT-a), umjesto uobičajenih metoda ekskohleacije ili marsupijalizacije. Argumenti za to bili su uspješno riješeni pojedinačni slučajevi velikih primjera te tvorbe u uzlaznome kraku donje čeljusti. No, u većim serijama liječenima Broschevom tehnikom (12) također su nađeni recidivi, pa ta tvrdnja ima samo djelomično opravdanje.

Diferencijalnodijagnostički tvorbu treba razlikovati od ostalih odontogenih tumora, posebice od ameloblastoma i kalcificirajuće odontogene ciste koja može imati vrlo sličnu kliničku i radiološku sliku, ali malokad recidivira (13).

Ispitanici i postupak

Postupak se sastojao u raščlambi dosad objavljenih vlastitih rezultata i djelomičnoj korekciji zaključaka. Predstavljaju se novi primjeri KCOT-a liječeni uspješno metodom marsupijalizacije i iznose novi podaci iz literature u kojima se navodi znatan broj recidiva nakon takvog postupka. Temeljem procjene vlastitih slučajeva i podataka iz literature, nastojalo se objektivno vrednovati metodu.

Rezultati

Naš uzorak od devetero pacijenata koji su bili podvrgnuti marsupijalizaciji obuhvatio je osam slučajeva KCOT-a i jedan slučaj radikularne ciste simfize donje čeljusti (4). Tri tvorbe bile su promjera tri do šest centimetara, a šest je bilo promjera većeg od šest centimetara. Opturator su pacijenti nosili u poslijeoperativnom razdoblju dok se šupljina ne bi smanjila, što je trajalo od šest do osam mjeseci. No, nakon našeg posljednjeg izvješća (14) zabilježen je jedan recidiv nakon marsupijalizacije (KCOT-a). Bio je to slučaj koji je

whether it is an enamel organ of a normal or supernumerary tooth prior to the appearance of calcification, or the epithelial remains of the dental lamina or basal layers of the epithelium of the oral cavity (7-9). However, its histological and histochemical structure, with relevant potency of the epithelium, is responsible for the development of postoperative recurrence. Whether or not some other factors or several of them are also responsible are questions that still remain unanswered. Recurrences of KCOT range from 25% to 62.5% (9), while some reports range from 6% to 60% (10). In domestic literature, in a sample of 82 cases, recurrence was reported in 20.83% of cases (3), and the factors which correlated with recurrence were gender, size and localisation of the cyst. No elements were found which connected the surgical method with recurrence. Comparative research on the frequency of recurrence of KCOT and ameloblastoma (11) showed similar frequency of the recurrence of both tumours, particularly those located in the mandible; among 74 KCOT 62 or 83.78% were located in the mandible and operated by various techniques; there were 16 recurrences (19.51%) of which 14 were in the mandible, or 87.50%. Similar data were obtained for ameloblastomas, with slightly greater frequency of recurrence in the case of those located in the mandible. The authors, who considered that the surgical method was the reason for the recurrence (12), were inclined to choose Brosch's method in the treatment of KCOT instead of the usual method of excochleation or marsupialisation. Arguments for this were successfully resolved individual cases of large examples and tumours in the ramus of mandible. However, in a greater series treated by Brosch's technique (13), recurrences were also found and thus the foregoing claim has only partial justification.

The tumour should be differentiated from other odontogenic tumours by differential diagnostics, particularly from ameloblastomas and calcifying odontogenic cysts, which can have very similar clinical and radiographic appearance, but which seldom recur (14).

Material and Method

The method consisted of analysis of previously published personal results and partial correction of conclusions. New examples are shown of KCOT successfully treated by the method of marsupialisation. Also, new data from the literature are presented which report a significant number of recurrences following this method. Based on an assessment of our own cases and data from the literature an attempt is made to objectively evaluate the method.

Results

Our sample of 9 patients in whom marsupialisation was performed, comprised 8 cases of KCOT and one case of radicular cyst of the mandibular symphysis (4). Three tumours were 3-6 cm in diameter, and 6 greater than 6 cm. The obturator was worn in the postoperative period until the cavity reduced, which lasted 6-8 months. However, following our last report¹⁵ one case of recurrence after marsupialisation of KCOT was recorded. It was a case which had previously recurred on two occasions after excochleation. All other cas-

već nakon ekskohleacije dva puta recidivirao. Kod svih ostalih pacijenata liječenih marsupijalizacijom tvorba je nestala i kost se potpuno obnovila, a rezultati su praćeni pet godina nakon zahvata.

Nakon tog istraživanja operirano je kod nas još nekoliko pacijenata s KCOT-om postupkom marsupijalizacije, a rezultirali su nestankom tvorbe u čeljusti i obnovom koštanoga tkiva.

Osim marsupijalizacije u liječenju KCOT-a primjenjivan je i postupak punjenja koštanog defekta s granulatom beta trikalcijske fosfata – Bioresorba. Obnova kosti mogla se primijetiti već od četiri do šest mjeseci nakon zahvata (15,16).

Pacijentica u dobi od 58 godina bila je primljena na Kliniku za maksilofacijalnu i oralnu kirurgiju Kliničke bolnice Dubrava zbog radiološkog nalaza koštanoga prosvjetljenja u lijevom korpusu i angulusu donje čeljusti. Prije toga liječila se kod svojeg stomatologa zbog perimandibularne otekline, što je bio razlog za radiološku obradu. Koštano prosvjetljenje bilo je nepravilnih lobuliranih rubova s nekoliko trabekula i koštanih spikula koje su stršile prema unutrašnjosti prosvjetljenja. Distalno se u uzlaznome kraku nalazila sjena retiniranog umnjaka. U zubnom nizu nedostajali su prvi i drugi kutnjak (slika 1.). Prema rendgenološkom nalazu pretpostavilo se da je riječ o KCOT-u, što je potvrđeno patohistološkom analizom. Nalaz: stijenka keratocističnog odontogenog tumora građena je od veziva obloženog tankim slojem pravilnoga višeslojnog pločastog epitela s istaknutom parakeratozom na površini i palisadno poredanim bazalnim stanicama (slika 2.). Nakon pripreme zahvat je obavljen u općoj inhalacijskoj anesteziji. Ekstrahirani su donji lijevi sjekutići s ostičkim periapikalnim promjenama, učinjena je alveotomija umnjaka i marsupijalizacija tvorbe. Šupljina je tamponirana jodoformnom gazom koja je drugi postoperativni dan uklonjena i uzet je otisak za akrilatni opturator. Opturator je prilagođen otvoru u kosti i pacijentica je četvrti postoperativni dan otpuštena na kućnu njegu. Kontrolni nalaz nakon mjesec dana pokazao je da opturator zatvara otvor u kosti bez iritacije okolnoga mekog tkiva, a sluznica u dnu šupljine ima boju sluznice usne šupljine (slike 3. i 4.). Dva mjeseca nakon zahvata kontrolni rendgenološki nalaz pokazao je djelomičnu obnovu kosti, opturator je uklonjen i pacijentica je dobila upute za ispiranje i održavanje čistoće čeljusne šupljine. Kontrola nakon četiri mjeseca pokazala je znatnu obnovu koštanoga tkiva, a intraoralni nalaz manju udubinu na kosti na mjestu prijašnjega marsupijalizacijskog otvora (slika 5.).

Muškarac u dobi od 44 godine bio je primljen na obradu zbog prosvjetljenja u angulusu i uzlaznome kraku donje čeljusti koje je slučajno nađeno pri rutinskom snimanju čeljusti i zuba. Prije toga bilo je simptoma, s neznatnom deformacijom koja se palpira s desne strane donje čeljusti. Rubovi prosvjetljenja su prema uzlaznome kraku lobulirani s pregradama, a u donjem dijelu vidi se intenzivnije ovalno prosvjetljenje koje odgovara perforaciji lingvalne stijenke donje čeljusti. U dnu je vidljiva sjena retiniranog umnjaka (slike 6. i 7.).

U općoj inhalacijskoj anesteziji obavljena je marsupijalizacija i uklonjen retinirani zub. Šupljina je tamponirana jodoformnom trakom koja je uklonjena treći postoperativni

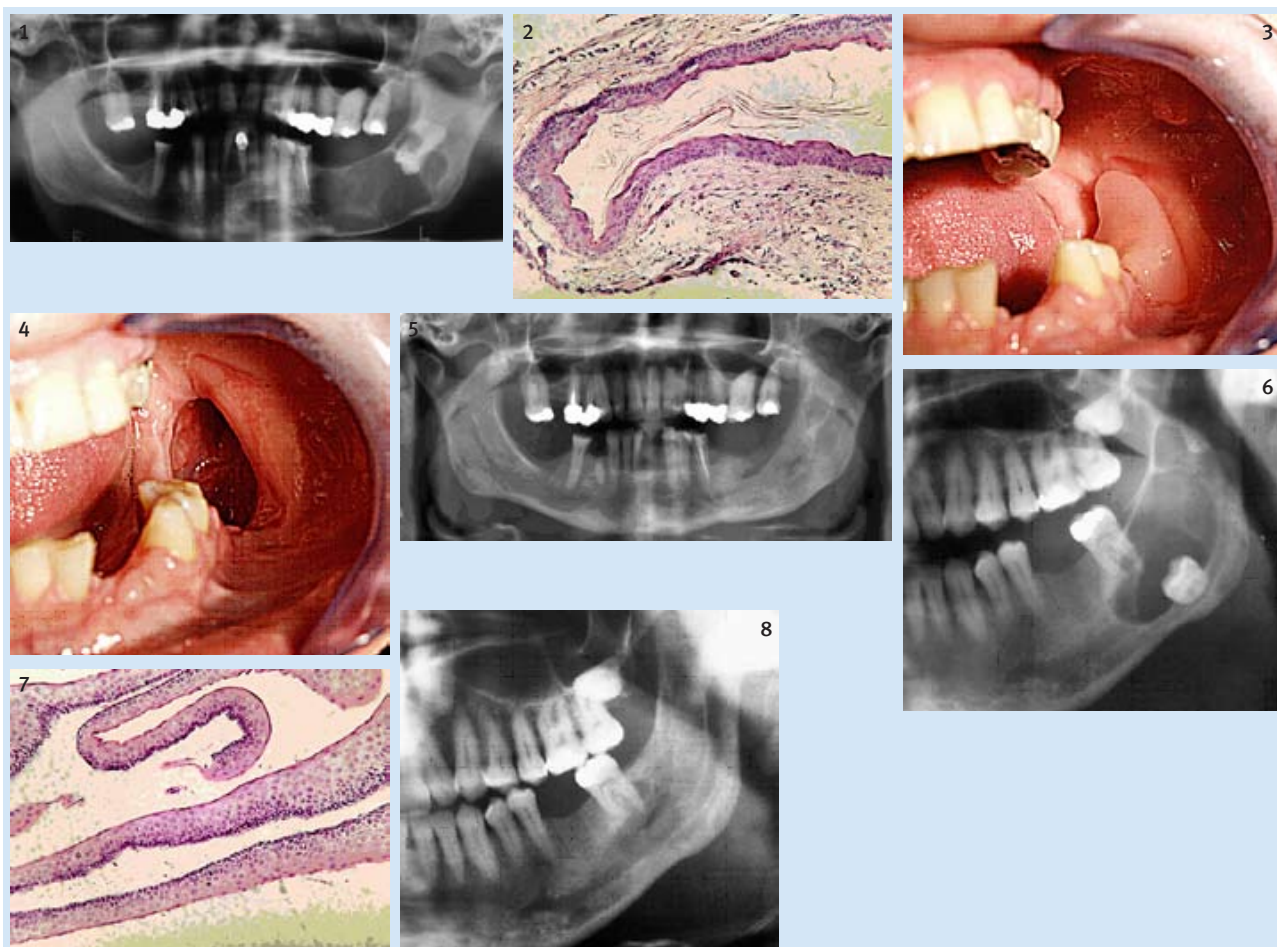
es treated by marsupialisation led to the disappearance of the tumour and complete restoration of the bone. The results were monitored for a period of 5 years after the surgery.

Following that investigation, several more examples of KCOT were treated surgically in the Clinic by the method of marsupialisation, which resulted in the disappearance of the tumour in the jaws and restoration of bone tissue.

Apart from marsupialisation in the treatment of KCOT, the method of filling the bone defect with granulate beta tricalcium phosphate - Bioresorb was applied. Restoration of the bone was already observed 4 to 6 months after the operation (16,17).

A female patient aged 58 years was admitted to the Clinic for Maxillofacial and Oral Surgery of the University Hospital Dubrava, because of a radiographic finding of bone translucency in the left corpus and angulus of the mandible. The patient had previously been treated by her dentist for a perimandibular swelling, which was the reason for the radiographic treatment. The bone translucency showed irregular lobular edges with several trabeculae and bony spicule which extended towards the inner part of the translucency. Distally, in the ramus of the mandible, was the shadow of an impacted wisdom tooth. The first and second molars were missing in the dental arch (Figure 1). On the basis of an X-ray, it was assumed that it was a case of KCOT, which was confirmed by histopathological analysis. The following findings were obtained: the wall of the keratocystic odontogenic tumour was constructed of fibrous tissue covered with a thin layer of regular multi-layered squamous epithelium with marked parakeratosis on the surface and palisad aligned basal cells (Figure 2). After preparation, the surgery was performed under general anaesthesia; extraction of the lower left incisor with ostitic periapical lesions, alveotomy of the wisdom tooth and marsupialisation of the tumour. The cavity was tamponed with Jodoform gauze which was removed on the second postoperative day and an impression taken for the acrylic obturator. The obturator was adjusted to the opening in the bone and the patient was discharged from hospital into home care on the fourth postoperative day. After one month a check-up showed that the obturator closed the opening in the bone with no irritation of the surrounding soft tissue, and the mucosa in the cavity base matched the colour of the mucosa of the oral cavity (Figures 3 and 4). Two months after the surgery, a check-up X-ray showed partial restoration of the bone. The obturator was removed and the patient was given instructions for rinsing and maintenance of hygiene of the cavity in the jaw. After four months, a check-up showed significant restoration of the bone tissue, and intraoral finding showed a reduced depth of the bone at the place of the former marsupialisation opening (Figure 5).

A male patient aged 44 years was admitted for treatment because of lucency in the angulus and ramus of mandible, which had been discovered by chance during a routine X-ray of the jaws and teeth. Previously without symptoms and with only slight deformation, which could be palpated on the right side of the mandible. The edges of the translucency towards the ramus of mandible were lobular with trabecules while in the lower part a more intensive oval translucency could be seen, indicating perforation of the lingual



Slika 1. Radiološki nalaz keratocističnog odontogenog tumora – KCOT-a s retiniranim umnjakom u uzlaznome kraku donje čeljusti
Figure 1 Radiographic finding of a keratocystic odontogenic tumour (KCOT) with an impacted third molar in the ramus of mandible.

Slika 2. Patohistološka slika keratocističnog odontogenog tumora (KCOT-a) prvog prikazanog slučaja (HE x 200)
Figure 2 Histopathological finding of the keratocystic odontogenic tumour (KCOT) of the first presented case (HE x 200)

Slika 3. Nakon marsupijalizacije i alveotomije umnjaka pacijent je nosio opturator dva mjeseca
Figure 3 After marsupialisation and alveolectomy of the wisdom tooth the obturator was worn for two months

Slika 4. Intraoralni nalaz bez opturatora mjesec dana nakon zahvata
Figure 4 The intraoral finding without the obturator one month after surgery

Slika 5. Rentgenološki nalaz šest mjeseci nakon marsupijalizacije

Figure 5 X-ray 6 months after marsupialisation

Slika 6. Radiološki nalaz keratocističnog odontogenog tumora (KCOT-a) u angulusu i izlaznome kraku donje čeljusti – u dnu se vidi sjena retiniranog umnjaka

Figure 6 Radiographic finding of a keratocystic odontogenic tumour (KCOT) in the angulus and ramus of mandible. An impacted third molar can be seen on the floor.

Slika 7. Patohistološki slika keratocističnog odontogenog tumora (KCOT-a) drugoga prikazanog slučaja (HE x 200)

Figure 7 Histopathological finding of the keratocystic odontogenic tumour (KCOT) of the second presented case (HE x 200)

Slika 8. Radiološki nalaz godinu dana nakon marsupijalizacije pokazuje potpunu obnovu kosti

Figure 8 Radiographic finding one year after marsupialisation shows completely restored bone

dan i izrađen je opturator. Kontrolni pregledi pokazali su postupno smanjenje koštanog defekta, a opturator se tijekom tih posjeta brušenjem prilagođavao veličini otvora. Nakon šest mjeseci je uklonjen i šupljina se nakon toga čisti ispiranjem. Godinu dana nakon zahvata intraoralni nalaz nije pokazao defekte na mjestu marsupijalizacije, a rentgenološki nalaz pokazao je obnovu koštanoga tkiva (slika 8.).

wall of the mandible. The shadow of an impacted wisdom tooth could be seen in the floor (Figures 6 and 7). Marsupialisation and extirpation of the impacted tooth was carried out under general inhalation anaesthesia. The cavity was tamponed with Jodoform gauze which was removed on the third postoperative day and an obturator was made. Check-up examinations showed a gradual reduction of the bone defect, and the obturator was adapted by grinding to the size of the opening during check-ups. The obturator was removed after six months and the cavity cleaned by rinsing. One year after the surgery, the intraoral finding did not show any defect at the place of marsupialisation, and the X-ray revealed restored bone tissue (Figure 8).

Rasprava i zaključak

Tvrđnja da se keratocistični odontogeni tumor može izliječiti marsupijalizacijom čini se realnom, nakon što je kod osam od devet liječenih pacijenata postignuto potpuno cijeljenje kosti i nije bilo recidiva u petogodišnjem postoperativnom razdoblju. Dobiveni rezultati u skladu su sa stajalištem Nakamure i suradnika (9) da se učestalost recidiva nakon marsupijalizacije smanjuje. No, naši prvi podatci (14) bili su u skladu i s tvrdnjom Pogrela i Jordana o mogućnosti da marsupijalizacija bude konačan postupak u liječenju KCOT-a (17). Jedan recidiv nakon pet godina potvrdio je naknadno mišljenje Pogrela kojim je on djelomice povukao svoja stajališta o marsupijalizaciji kao o konačnome postupku u liječenju KCOT-a (18).

Dva prikazana slučaja obrađena su nakon toga i rezultat se nakon jednogodišnjeg praćenja može smatrati zadovoljavajućim. U oba je slučaja kost potpuno obnovljena i nema vidljivih znakova recidiva. Primjer recidiva nakon petogodišnjeg praćenja iz našeg uzorka nalaže oprez u primjeni marsupijalizacije kao konačne metode liječenja KCOT-a, posebice u slučajevima kad su nakon konzervativno kirurških postupaka liječenja već zabilježeni recidivi. U tom smislu govore i suvremeni podatci iz literature o koristi marsupijalizacije u liječenju čeljusti. Sigurno je da se tim postupkom znatno smanjuje koštani defekt, nakon čega neki autori pristupaju enukleaciji tvorbe (19). Zahvat je još metoda izbora u slučaju recidiva tvorbe (20) nakon enukleacije. Podatci koje navode Zacha i suradnici (21) o 40 posto recidiva KCOT-a nakon marsupijalizacije u razdoblju od 58 mjeseci nakon zahvata i 20,7 posto nakon enukleacije u razdoblju od 46 mjeseci, nalažu obvezu višegodišnjih postoperativnih kontrola u svim slučajevima, a posebice nakon marsupijalizacije. Autori preporučuju dodatnu primjenu Carnoyeve otopine u liječenju. Temeljem naših dosadašnjih rezultata, koji se još uvijek mogu smatrati preliminarnima, marsupijalizaciju i nadalje smatramo metodom izbora u liječenju KCOT-a, uz obvezne redovite višegodišnje postoperativne kontrole.

Discussion and conclusion

After eight out of nine treated cases showed completely healed bone and were without recurrence during the five-year postoperative period, the claim that a keratocystic odontogenic tumour can be treated by marsupialisation appears to be realistic. The results obtained are in accordance with the opinion of Nakamura et al (10), that the frequency of recurrence of KCOT after marsupialisation is reduced. However, our first data (15) were in accordance with the claims of Pogrel and Jordan about the possibility that marsupialisation is the definitive method in the treatment of KCOT (18). The case of one recurrence after five years confirmed later Pogrel's claim, by which he partially retracted his opinion on marsupialisation as the definitive method in treatment of KCOT (19). The two cases presented were treated later and the result after a one-year monitoring period can be considered satisfactory. In both cases a complete restoration of bone occurred, with no visible signs of recurrence. The example of recurrence after a five-year monitoring period in our sample suggests caution in the application of marsupialisation as the definitive method of treatment of KCOT, particularly in cases in which recurrence had previously been registered after conservative surgical methods of treatment. This is corroborated by current data from the literature on the usefulness of marsupialisation in the treatment of KCOT of the jaws. Clearly, this method significantly reduces the bone defect, after which some authors carry out enucleation of the tumour (19). The method is still the method of choice in cases of tumour recurrence (20) after enucleation. Data reported by Zachs et al (21) on the occurrence of 40% recurrence of KCOT after marsupialisation, during a period of 58 months after the operation and 20.7% recurrence after enucleation during a period of 46 months indicate that several years of postoperative check-ups in all cases are obligatory, particularly after marsupialisation of KCOT. The authors recommend the additional application of Carnoy's solution in treatment. Based on our previous results, which can still be considered preliminary, we believe that marsupialisation is the method of choice in the treatment of KCOT, with several years of obligatory, regular postoperative check-ups.

Abstract

The authors present the results of treating mandibular keratocystic odontogenic tumour (KCOT) by the surgical method of marsupialisation in the context of current dilemma in the literature regarding this problem. The basic question of whether marsupialisation can be the definitive method in treatment of KCOT still cannot be answered with certainty, neither on the basis of data from the literature nor on the basis of positive data presented in the study. Presentation of slightly modified results of the treatment of a sample from an earlier published study, and two cases treated subsequently give the authors the prerogative to claim that marsupialisation of KCOT is the method of choice, which will probably be the definitive method of treatment. Current data from the literature still require several years of postoperative monitoring of patients and application of additional means of treatment in order to prevent relapse.

Received: January 31, 2011

Accepted: June 29, 2011

Address for correspondence

Ana Kotarac Knežević DMD
University of Zagreb
School of Dental Medicine
Department of Oral Surgery
Gundulićeva 5, HR-10 000 Zagreb,
Croatia
Tel: + 385 1 4802 111
kotarac@sfzg.hr

Key words

Gorlin-Goltz Syndrome; Odontogenic Keratocyst; Mandible; Marsupialisation; Surgical Treatment

Literature

1. Reichart PA, Philipsen HP. Odontogenic tumors and allied lesions. London: Quintessence Publishing; 2004.
2. Planinić D. Prevalence of odontogenic keratocysts (OKC) associated with impacted third molars [MS thesis]. Zagreb: School of Dental Medicine; 2007.
3. Sokler K. Recurrence of odontogenic keratocysts of the jaws with the respect to the surgical procedures for treatment and other factors [disertation]. Zagreb: School of Dental Medicine; 2006.
4. Kotarac Knežević A. Evaluation of marsupialisation in the treatment of odontogenic pathological jaw lesions [MS thesis]. Zagreb: School of Dental Medicine; 2008.
5. Daley TD, Wysocki GP, Pringle GA. Relative incidence of odontogenic tumors and oral and jaw cysts in a Canadian population. *Oral Surg Oral Med Oral Pathol*. 1994 Mar;77(3):276-80.
6. Barnes L. Surgical pathology of the head and neck. New York: Marcel Dekker; 2001.
7. Lucas RB. Pathology of tumours of the oral tissues. London: Churchill Livingstone; 1976.
8. Stoelinga PJ, Peters JH. A note on the origin of keratocysts of the jaws. *Int J Oral Surg*. 1973;2(2):37-44.
9. Nakamura N, Mitsuyasu T, Mitsuyasu Y, Taketomi T, Higuchi Y, Ohishi M. Marsupialization for odontogenic keratocysts: long-term follow-up analysis of the effects and changes in growth characteristics. *Oral Surg Oral Med Oral Pathol Oral Radiol Endod*. 2002 Nov;94(5):543-53.
10. Prica A. Comparison between the recurrence of odontogenic keratocyst and ameloblastomas [MS thesis]. Zagreb: School of Dental Medicine; 2009.
11. Ephros H, Lee HY. Treatment of a large odontogenic keratocyst using the Brosch procedure. *J Oral Maxillofac Surg*. 1991 Aug;49(8):871-4.
12. Farmand M, Makek M. Late results following the Brosch-procedure for treating large mandibular ramus cysts. *J Maxillofac Surg*. 1983 Oct;11(5):211-5.
13. Knežević G, Sokler K, Kobler P, Manojlović S. Calcifying odontogenic cyst--Gorlin's cyst--report of two cases. *Coll Antropol*. 2004 Jun;28(1):357-62.
14. Kotarac Knežević A, Knežević G, Perić B, Grgurević J. Marsupialization in the treatment of jaw cysts. *Acta Stomatol Croat*. 2010; 44(1):53-60.
15. Knežević G, Rinčić M, Knežević D. Radiological evaluation of the healing of bone defects filled with tricalcium phosphate (biore-sorb) after cystectomy of the mandible. *Acta Stomatol Croat*. 2007;41(1):66-73.
16. Rinčić M. The application of the pure ceramic of tricalcium phosphate --Biore-sorb- in treatment of large bone defects of jaws [MS thesis]. Zagreb: School of Dental Medicine; 2008.
17. Pogrel MA, Jordan RC. Marsupialization as a definitive treatment for the odontogenic keratocyst. *J Oral Maxillofac Surg*. 2004 Jun;62(6):651-5; discussion 655-6.
18. Pogrel MA. Decompression and marsupialization as definitive treatment for keratocysts--a partial retraction. *J Oral Maxillofac Surg*. 2007 Feb;65(2):362-3.
19. Zhao Y, Liu B, Han QB, Wang SP, Wang YN. Changes in bone density and cyst volume after marsupialization of mandibular odontogenic keratocysts (keratocystic odontogenic tumors). *J Oral Maxillofac Surg*. 2011 May;69(5):1361-6.
20. Hyun HK, Hong SD, Kim JW. Recurrent keratocystic odontogenic tumor in the mandible: a case report and literature review. *Oral Surg Oral Med Oral Pathol Oral Radiol Endod*. 2009 Aug;108(2):e7-10.
21. Zecha JA, Mendes RA, Lindeboom VB, van der Waal I. Recurrence rate of keratocystic odontogenic tumor after conservative surgical treatment without adjunctive therapies - A 35-year single institution experience. *Oral Oncol*. 2010 Oct;46(10):740-2.