

VETERINARSKI ARHIV 74 (6), 467-474, 2004

Severe Auzdyk infection in one-month-old camel calves (*Camelus dromedarius*)

Fadhel Housawi^{1*}, ElTayeb Abu-Elzein², Ahmed Gameel³, Mohamed Mustafa¹, Adel Al-Afaleq², Janice Gilray⁴, Abdulwahab Al-Hulaibi¹, and Peter Nettleton⁴

¹Department of Clinical Studies, College of Veterinary Medicine, King Faisal University, Saudi Arabia

²Department of Microbiology and Parasitology, College of Veterinary, Medicine, King Faisal University, Saudi Arabia

³Department of Pathology, College of Veterinary Medicine, King Faisal University, Saudi Arabia

⁴The Moredun Research Institute, Edinbrough, UK

HOUSAWI, F., E. ABU-ELZEIN, A. GAMEEL, M. MUSTAFA, A. AL-AFALEQ, J. GILRAY, A. AL-HULAIBI, P. NETTLETON: Severe Auzdyk infection in one-month-old camel calves (*Camelus dromedarius*). Vet. arhiv 74, 467-474, 2004.

ABSTRACT

On 11 March 2002 two approximately one-month-old, one-humped camel calves (*C. dromedarius*) were presented to the University Veterinary Teaching Hospital, King Faisal University, Al-Hasa, Saudi Arabia (SA), suffering from severe lesions on the lips and hard palates. Samples were collected and virological, pathological and serological investigations were carried out. The disease was confirmed to be Auzdyk. The situation was discussed in relation to the severity of the disease, a condition seen for the first time in this country, in these very young camels. The results confirmed that fairly young camel calves, 1-month old, can suffer a severe form of the disease.

Key words: one-month-old camel calves, Auzdyk, Saudi Arabia

Introduction

Contagious pustular dermatitis, orf, of sheep and goats is endemic in SA, (HOUSAWI et al., 1991, 1992, 1993; ABU ELZEIN and HOUSAWI 1997; GAMEEL et al., 1995). Several outbreaks are reported annually in sheep and goats in the country.

* Contact address:

Dr. Fadhel Housawi, college of Veterinary Medicine, King Faisal University, P.O.Box 1757, AL-Ahsa 31982, Saudi Arabia, E-mail: fhousawi@yahoo.com.uk

Camel-contagious ecthyma, Auzdyk, is not common in SA. The first record of the disease was detected in 1998 (ABU ELZEIN et al., 1998). Despite the endemic nature of sheep and goat orf in SA, camels were not observed to be cross-infected under field conditions, although they are usually in close proximity to sheep and goats.

The epidemiological picture of Auzdyk in SA is not clear. To the best of our knowledge there are no published data regarding this disease except that reported in 1998 (ABU ELZEIN et al., 1998).

This situation necessitates the reporting of any gathered information that may add to the understanding of its epidemiology in SA.

The present paper describes an outbreak of the disease in fairly young camel calves. The significance of the disease as a potential cause of camel calf mortality is discussed in relation to the epidemiology and future control of the disease in the Kingdom.

Materials and methods

History. In March 2002, two one-humped Arabian camel calves (*Camelus dromedarius*) aged approximately one month old were brought to the King Faisal Veterinary Teaching Hospital at Al-Hasa Oasis of Eastern Saudi Arabia. The calves were suffering from lesions on the lips and hard palates (Fig. 1).



Fig. 1. Camel parapox scab on the lips of an affected one-month old camel calf

On examination, rectal temperature was 39 °C. The calves were panting and showed restlessness and pain. They were weak and had not suckled since the appearance of the lesions three days before. The involved herd consisted of eighty camels of different age groups. Although the morbidity rate was 50%, the calves were the worst affected. No mortality was recorded. The herd was kept in the desert to graze freely but was also supplemented with concentrate feed.

At the time of the outbreak no signs of orf were observed in sheep or goats in the area.

Sampling. Biopsies from the lip lesions were collected in sterile containers for virological investigations. A portion of the lip lesion, was placed in 10% formol saline for histopathological examination.

Agar gel immunodiffusion (AGID). The AGID test, as described by SAWHNEY et al. (1973) was followed employing a known rabbit antiserum to an orf virus (MK-5) isolated from an outbreak in sheep in Saudi Arabia (HOUSAWI et al., 1991). The MK-5 orf virus was identified by the serum neutralization test (SNT) using a reference, sheep antiserum to the orf virus, which was procured from the Central Veterinary Laboratory, Weybridge, U.K.

The AGID test was designed in such a way that the antiserum was placed in the central well. The suspect material was placed in 3 alternate peripheral wells. To the remaining three wells a known sheep orf virus isolate was added. In control agar gel rosettes non-immune sheep serum was reacted against the tested viruses. Included as mock control antigens were normal camel skin and sheepskin, each at a concentration of 50% in phosphate buffered saline (PBS) pH 7.4. The reactants were left at room temperature under humid conditions and the results were read the following day.

Immunofluorescence (IF). Indirect IF as described by LEINDO and CASTRO (1981) was employed on thin sections from the lip lesions of the affected camel calves.

Virological investigations. A 10 percent suspension was made of the lip biopsy in PBS pH 7.4 to inoculate the CAM of chicken embryos, as described by MCCARTHY and DUMBELL (1961). Vero, primary lamb kidney cell culture and primary lamb's cell testicles were inoculated with a 10% suspension of the suspected lesions, as described by HOUSAWI et al. (1991).

Results

The histopathological section from the lip lesions showed epidermal hyperplasia with acanthosis and epitheliomatous hyperplasia. The dermis was densely cellular, exhibiting fibroplasia and infiltration mainly of macrophages and lymphocytes, which greatly obscured the dermo-epidermal junction (Figs 2 and 3).

In some sections there was advanced epidermal necrosis with neutrophil infiltrations, presence of bacterial colonies and hyperkeratosis. The dermis showed intense infiltration with neutrophils, indicating secondary bacterial infection (Figs 2, 3, 4 and 5).

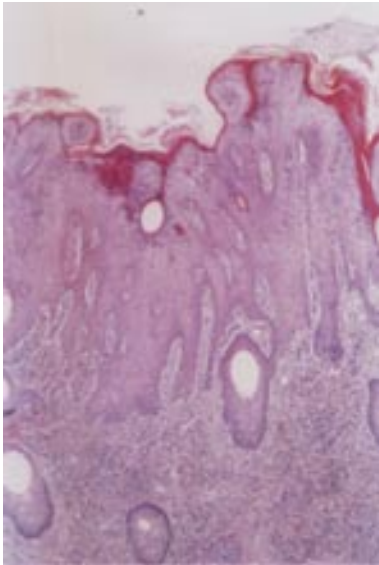


Fig. 2. Thickened epidermis with acanthosis, epitheliomatous hyperplasia and dermal infiltration by mainly mononuclear cells. H&E, $\times 100$

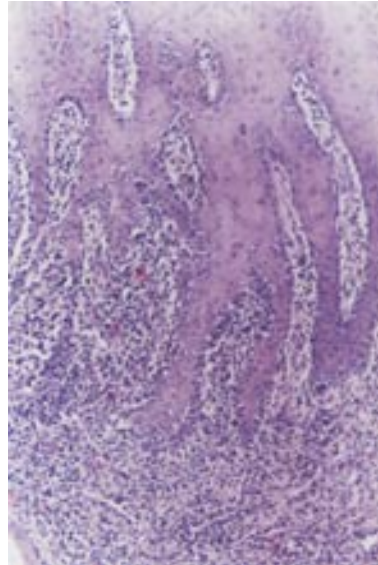


Fig. 3. Epitheliomatous hyperplasia and dermal infiltration by mainly lymphocytes and macrophages which partly obliterate the dermo-epidermal junction. H&E, $\times 200$

AGID test results revealed that a precipitation line was produced between the suspect material and the reference orf antiserum. This line completely merged with a line produced between the known sheep orf virus and the reference antiserum,

making a line of complete identity. The negative controls did not react in the test.

The inoculated cell culture showed no discernible cytopathic effect (CPE), in spite of two blind passages.

No pathological changes were observed in the inoculated CAMs of the inoculated chicken embryos and none of the inoculated embryos died until they were collected seven days post- inoculation.



Fig. 4. Advanced epidermal necrosis and hyperkeratosis with infiltration of neutrophils. H&E, $\times 100$

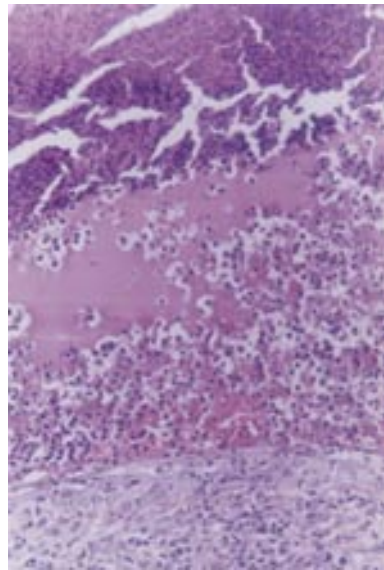


Fig. 5. Advanced epidermal necrosis with edema and neutrophil infiltration. H&E, $\times 400$

Specific fluorescence was seen intracytoplasmic in the sections, which were collected from the lips of the affected camel calves.

Discussion

The historic association between Bedouins and their hardy and well-adapted beast (the camel) with the harsh and arid conditions of the Arabian Peninsula has led them to pay special attention to the welfare of that animal.

The camel provides them with meat, milk and hides. As a pack animal it was their 'desert ship'. It conveyed them and their needs to distant places in the desert. No other beast or vehicle can reach such vicinities except the camel.

Right up to the present day camel calf meat has been one of the favourite sources of nourishment for the inhabitants of the Arabian Peninsula.

Accordingly, and because camel calf infections will have direct effects on camel productivity, and bearing in mind that the calving interval in the camel might be more than two years, any disease that seriously affects camel calves will be the focus of intense attention in SA.

The clinical-pathological, serological and virological results of the present study confirmed that the disease which involved the camel calves was camel contagious pustular dermatitis.

These findings represent an alarm bell regarding the emergence of a severe ailment in camel calves in SA. Internationally, Auzdyk is one of the scourges of camel calves (BUCHNEV et al., 1987; DASHT-SERREN et al., 1984; MOALLIN and ZESSIN 1988; KHALAFALLA et al., 1994, 1997, 1998; KHALAFALLA, 2000). For instance, it was found that 98% of the cases of camel orf occur in camel calves aged less than one year, with a mortality that reached 38% (KHALAFALLA, 2000).

The epidemiology of camel orf in various countries varied according to ecological conditions. In most cases, the annual young camel calf crop is exposed to infection when they start grazing prickly-plants. This was the case in Asia (BUCHNEV et al., 1987); and Africa (MOALLIN and ZESSIN 1988; ALI et al., 1991; KHALAFALLA et al., 1997; KHALAFALLA, 2000).

In SA ecological conditions are different. Most of the landscape is desert. There is no acacia coverage or any other thorny plants. Under such conditions, therefore, it is not expected that young camel calves would be exposed to prickly-plants as they are in other countries. However, they seem to be somehow infected at a very early age, as happened in the present outbreak.

In the present outbreak the camel calves involved were suckling (one month old) and did not graze. It would seem, therefore, that other mechanism(s) are involved in exposing them to infection. This necessitates clarification in future studies in SA.

The epidemiological situation of camel orf in camel calves in SA is unclear. During the last two decades no reports have been available on this subject. In

any event the present outbreak could be merely the tip of an iceberg. Therefore, it is felt that more elaborative studies in the future are required in order that this situation be clarified.

References

- ABU ELZEIN, E. M. E., F. M. T. HOUSAWI (1997): Severe long lasting contagious ecthyma infection in a kid. *J. Vet. Med. B* 44, 561-564.
- ABU ELZEIN, E. M. E., E. R. COLOYAN, A. A. GAMEEL, R. O. RAMADAN, A. I. AL-AFALEQ (1998): Camel contagious Ecthyma in Saudi Arabia. *J. Camel prac. Res.* 5, 225-228.
- ALI, O. A., S. A. M. KHEIR, H. ABU-DAMIR, M. E. S. BARRI (1991): Camel contagious ecthyma in the Sudan. A case report. *Rev. Elev. Med. Vet. Pays. Trop.* 44, 143-145.
- BUCHNEV, K. N., S. Z. TULEPBAEV, A. F. SANSYZBAEV (1987): Infectious diseases of camels in the USSR. *Rev. Sc. Tech. Off. Int. Epiz.* 6, 487-495.
- DASHT-SEREN, T. S., B. V. SOLVYEV, F. VAREIJKA (1984): Camel contagious ecthyma (pustular dermatitis). *Acta Virol.* 28, 122-127.
- GAMEEL, A. A., E. M. E. ABU ELZEIN, F. M. T. HOUSAWI, A. AGIB, A. O. IBRAHIM. (1995): Naturally occurring contagious ecthyma in lambs in Saudi Arabia. *Rev. Elev. Med. Vet. Pays Trop.* 48, 233-235.
- HOUSAWI, F. M. T., E. M. E. ABU ELZEIN, M. M. AMIN, I. AFALEQ (1991): Contagious pustular dermatitis infection in sheep and goats in Saudi Arabia. *Vet. Rec.* 128, 550-551.
- HOUSAWI, F. M. T., E. M. E. ABU ELZEIN, A. I. AL-AFALEQ, M. M. AMIN (1992): Serosurveillance for orf antibodies in sheep and goats in Saudi Arabia employing the ELISA technique. *J. Comp. Pathol.* 106, 153-158.
- HOUSAWI, F. M. T., E. M. E. ABU ELZEIN, A. A. GAMEEL, A. I. AL-AFALEQ (1993): A close comparative study on the response of sheep and goats to experimental orf infection. *J. Vet. Med. B* 40, 272-282.
- KHALAFALLA, A. I. (2000): Camel contagious ecthyma: Risks in young calves. *Rev. Elev. Med. Pays. Trop.* 53, 173-176.
- KHALAFALLA, A. I., H. AGAB, B. ABBAS (1994): An outbreak of contagious ecthyma in camels (*Camelus dromedaries*) in Eastern Sudan. *Trop. Anim. Hlth. Prod.* 26, 253-254.
- KHALAFALLA, A. I., M. E. H. MOHAMED (1997): Epizootiology of camel contagious ecthyma in Eastern Sudan. *Rev. Elev. Med. Vet. Pays. Trop.* 50, 99-103.
- KHALAFALLA, A. I., M. E. H. MOHAMED, B. H. ALI, S. A. M. KHEIR (1998): Isolation and identification of camel contagious ecthyma virus in Sudan. *Sud. J. Vet. Sci. Anim. Husb.* 37, 49-56.
- LEINDO, G., A. E. CASTRO (1981): Bluetongue in cattle: diagnosis and virus isolation. *Bovine Practitioner* 16, 7.

F. Housawi et al.: Severe Auszyk infection in one-month-old camel calves (*Camelus dromedarius*)

MCCARTHY, K., K. R. DUMBELL (1961): Chorioallantoic inoculation of eggs. *Virology* 14, 488-489.

MOALLIN, A. S. M., K. H. ZESSIN (1988): Outbreak of camel contagious ecthyma in Central Somalia. *Trop. Anim. Hlth. Prod.* 20, 185-186.

SAWHNEY, A. N., S. C. DUBEY, B. S. MALIK (1973): Diagnosis of contagious pustular dermatitis in sheep and goats by age-gel precipitation test. *Ind. Vet. J.* 50, 605-607.

Received: 25 September 2003

Accepted: 8 November 2004

HOUSAWI, F., E. ABU-ELZEIN, A. GAMEEL, M. MUSTAFA A. AL-AFALEQ, J. GILRAY, A. AL-HULAIBI, P. NETTLETON: Teška Auszyk infekcija u jednomjesečnih devinih mladunaca (*Camelus dromedarius*). *Vet. arhiv* 74, 467-474, 2004.

SAŽETAK

Na sveučilišnu veterinarsku kliniku King Faisal Sveučilišta u Saudijskog Arabiji (SA), dovedena su dva mladunca jednogrbi deva u dobi od približno mjesec dana s jako izraženim lezijama na usnama i tvrdom nepcu. Uzeti su uzorci kako bi se obavile virološka, patološka i serološka pretraga. Potvrđeno je da je riječ o Auszyk infekciji. Razmatrana je jačina bolesti i njena pojava u mladim deva po prvi put u ovoj zemlji. Rezultati potvrđuju da i sasvim mlade deve, stare mjesec dana, mogu oboljeti s jako izraženim znakovima bolesti.

Ključne riječi: jednomjesečne deve, Auszyk, Saudijska Arabija
