

Shrimati Bhikhiben Kanjibhai Shah Medical Institute and Research Centre, Piraria, India

FALLOPIAN TUBE ADENOCARCINOMA – A CASE REPORT ADENOKARCINOM JAJOVODA – PRIKAZ BOLESNICE

Uday J. Patel, Kishor P. Chauhan, Bakul R. Leuva

Case report

Key words: Fallopian tube adenocarcinoma, chemotherapy

SUMMARY. Mrs. UB aged 35 years came to us with complaints of oligomenorrhoea, lower abdominal pain, haematuria, retention of urine with CT scan report of December 2008 which was suggestive of left sided ovarian tumor. We investigated her with ultrasonography and CA-125 level and primary diagnosis of left sided ovarian tumor was made. On laparotomy it turned out to be primary fallopian tube carcinoma. Abdominal total hysterectomy with bilateral salpingo-oophorectomy with omental and node biopsy was done. On histopathological examination it turned out, as primary serous adenocarcinoma of fallopian tube grade $G_2PT_{1(C)}P_{N0}$. To patient were given two cycles of chemotherapy. Primary fallopian tube carcinomas are quite rare. In routine practice when we come across a case, it is usually diagnosed as an adnexal mass, more commonly as an ovarian tumor. The usual investigations cannot discriminate between the ovarian and the tubal mass. The fallopian tube cancer comes as a surprise on laparotomy. We have to be ready to deal with this condition even when it suddenly crops up.

Prokaz slučaja

Ključne riječi: adenokarcinom Fallopijeve tube, kemoterapija

SAŽETAK. Gospođa UB, životne dobi 35 godina, javila sa smetnjama oligomenoreje, bolima donjeg trbuha, hematurijom i retencijom mokraće. Posjedovala je CT nalaz iz prosinca 2008. godine koji je upućivao na lijevostrani ovarijski tumor. Istražili smo je ultrazvukom i razinom Ca 125 u krvi te je bila postavljena dijagnoza lijevostranog ovarijskog tumora. Učinjena je laparotomija te je nađen primarni karcinom lijevog jajovoda. Učinjena je totalna abdominalna histerektomija s obostranom salpingo-ooforektomijom s biopsijom omentuma i limfnih čvorova. Histopatološki je utvrđen primarni adenokarcinom jajovoda, stupnja $G_2PT_{1(C)}P_{N0}$. Bolesnici su aplicirana dva ciklusa kemoterapije. Primarni rak jajovoda je zaista rijedak. U rutinskoj praksi se dijagnosticira kao adneksalna tvorba, obično kao ovarijski tumor. Uobičajene pretrage ne mogu razlikovati ovarijsku od tubarne tvorbe. Rak tube Fallopii je iznenađenje prigodom laparotomije. Moramo biti spremni suočiti se s tim stanjem makar ono naglo iskrсне.

Introduction

Primary fallopian tube cancer is a rare gynaecological malignancy.¹ They account for 0.1–1.8% of all gynaecological cancers.² Overall incidence recorded in US study 2007 was 0.41 per 100,000 women.³ Secondary malignant lesions of the fallopian tube usually arise from the adjacent ovary or uterus, occasionally from the gastrointestinal tract and rarely the breast cancer or peritoneal carcinomatosis.⁴ An association is seen in those with BRCA-1 gene.⁵ When secondary, these are single and localized in less than 50% of cases. These cases should be managed aggressively at primary surgery in view of their poor outcome – reportedly worse than that of ovarian cancer, stage for stage.⁶ In England and Wales, 40 cases of primary fallopian tube cancer (PFTC) and 4,500 cases of epithelial ovarian cancer (EOC) are registered annually.⁷ Furthermore, data from an ovarian cancer screening study that followed up a cohort of 22,000 postmenopausal women revealed a higher than expected ratio of PFTC to EOC among these volunteers.⁸ It is also possible that the true incidence of PFTC has been underestimated⁷ because PFTC may have been mistakenly identified as ovarian tumors during initial surgery and/or during microscopic examination by a pathologist, as the histological appearance of these tumors are identical.^{9,10} A study from Finland reported that the incidence of PFTC is increasing, with an age-adjusted

incidence of 1.2 per million for 1953–1957 to 5.4 per million for 1993–1997.¹¹ About 1,200 cases of PFTC have been reported in the literature until now.^{12,13}

Case report

Mrs. UB, a 35 years old woman, was seen in gynecological OPD for oligomenorrhoea since last 6 months, pain in bilateral iliac fossa since seven days, haematuria since two days and retention of urine since one day. Patient was referred to us from Madhya Pradesh (Zabua district). She had irregular menses with frequency of 2–3 months. She was para 2 with normal home deliveries by dais (traditional birth attendant). Last delivery was 7 years ago. She had undergone laparoscopic tubal ligation 6 years before.

On examination, her vitals were stable. On per abdominal palpation, ascites was present and freely mobile mass of around 15×15 cms was felt in the left iliac fossa. On per speculum examination, minimal discharge from the vagina was present and mild degree of rectocele was present. On per vagina examination, cervix was downward forward, uterus was anteverted, normal size, in left adnexa a mass of 15×12 cms size was felt which was freely mobile and right adnexa were free. There was no tenderness with movement. All her routine investigations were normal. Transabdominal sono-

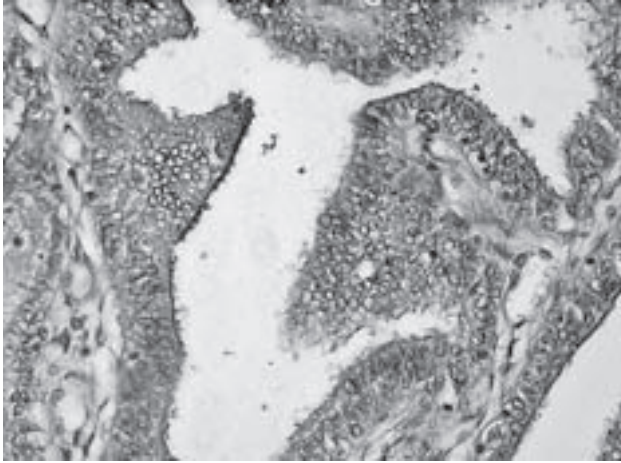


Figure 1. Hyperplastic mucosal epithelium with dysplastic changes of the left fallopian tube (H/E 450×).

Slika 1. Hiperplastični epitel sluznice s displastičnim stanicama lijevog jajovoda (H/E 450×).

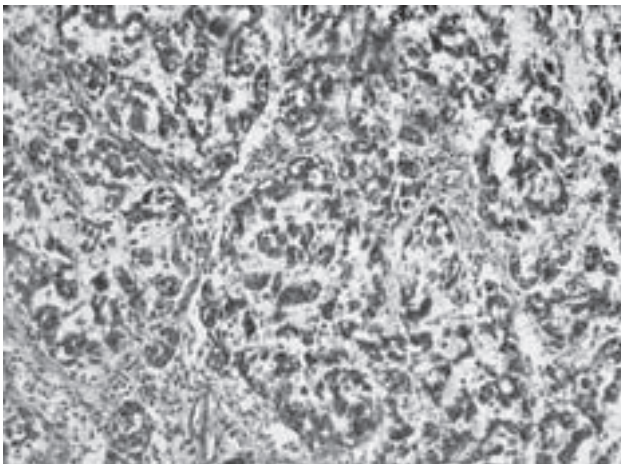


Figure 2. Tumor showing tubular architecture infiltrating stroma of the left fallopian tube (H/E 450×).

Slika 2. Tubularna građa stanica koje infiltriraju stromu lijeve tube (H/E 450×).

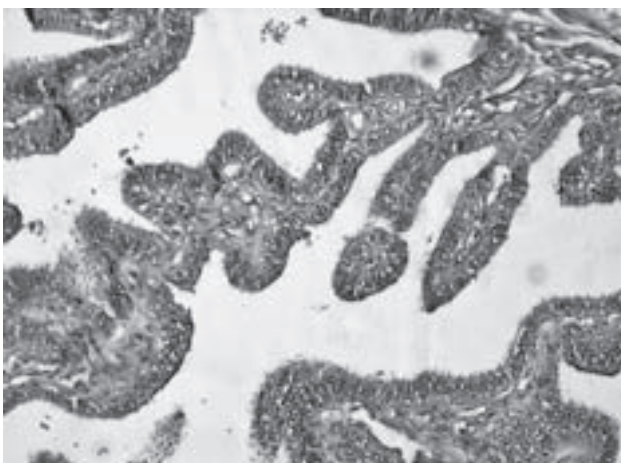


Figure 3. Right fallopian tube showing hyperplastic changes (H/E 450×).

Slika 3. Desni jajovod s hiperplastičnim stanicama (H/E 450×).

graphy demonstrated moderate ascites. Free fluid was seen in supra hepatic, sub hepatic and pelvic cavity and a mixed echogenic mass of 15×10×13.8 cm from left side adnexal region. Her CA 125 level was 218 IU. She had come to our hospital with CT abdomen report of Dec. 2008 from other hospital which was suggestive of heterogeneous mass of size 11.7×8.9×9 cms arising from left side ovarian mass. Considering all above examination points and investigations, diagnosis of malignant left sided ovarian tumor was kept and laparotomy was done.

On laparotomy, on opening abdomen hemorrhagic ascitic fluid came out, of which around one liter was suctioned out. On examination, right ovary, right fallopian tube and uterus were normal, left ovary was normal, but there was around 15×10×13.8 cms size mass arising from left fallopian tube. The total abdominal hysterectomy with bilateral salpingo-oophorectomy was done. On examination, omentum was normal; pre and para aortic lymph nodes were palpated and sent for histopathologic examination. Abdominal closure was done.

The pathohistological report was as follows: on gross examination uterus was measuring 7.5×4.5×3 cms. There was a mass on left at the fimbrial end of fallopian tube measuring 14×11×9 cms. On cut section solid areas, hemorrhages and small cystic areas were seen. On microscopic sections: endometrium and myometrium showed no abnormal pathology. Section from cervix showed changes of chronic cervicitis. Section from fimbrial end of left fallopian tube with mass show hyperplastic mucosal lining with severe degree dysplasia with histomorphology of serous adenocarcinoma invading through all layers of fallopian tube up to serosa. Cuboidal and low columnar tumor cells are arranged mainly around cleft like spaces forming tubular structures and at places solid sheets. The nuclei were large hyper chromatic with voluminous clear cytoplasm. Overall features were that of serous adenocarcinoma-moderately differentiated grade-II (Figures 1 and 2). The section from left fallopian tube near uterine end showed hyperplastic changes with severe degrees of dysplasia at places reaching up to carcinoma in situ. The section from left ovary showed no remarkable pathology. The section from omentum and lymphonode showed no remarkable pathology. The section from right fallopian tube (Figure 3) showed hyperplastic changes without dysplasia. The section from right ovary showed no remarkable pathology, as well. Final diagnosis: Serous adenocarcinoma of fimbrial end of left fallopian tube, moderately differentiated, grade-II FIGO staging Ic (tumor limited to one or both tubes with extension onto or through the serosa or with malignant cells in ascites or peritoneal washing). Histology grade of tumor was G₂PT_{1(C)}P_{N0}.

The patient's postoperative period was uneventful. Then patient was given two cycles of Carboplatin 450 mg as per AUC 5 with Paclitaxel 250 mg (175 mg/m²). The patient declined the third course of chemotherapy

due to her personal reasons. She and her husband were explained about the implications of omitting the third course.

Discussion

Patient was diagnosed with pelvic mass 6 months back by pelvic CT. Although she came late to us, with all above mentioned investigations, it was diagnosed as ovarian tumor and on laparotomy it turned out to be a fallopian tube adenocarcinoma. With all advanced investigations available we could not make out the diagnosis of fallopian tube carcinoma.

The fallopian tube carcinoma though a well known female genital cancer, in routine practice one does not encounter this malignancy frequently in comparison to other genital malignancies. In the case presented the tumor originated from the lateral end of the tube, hence clinically it was diagnosed as an ovarian tumor.

The investigations like ultrasonography and even CT scan failed to differentiate the tumor from ovary. The diagnosis of fallopian tube tumor was made only after opening the abdomen. The final diagnosis was made only after receiving the histopathology examination details which revealed moderately differentiated adenocarcinoma (G₂PT_{1(C)}P_{N0}) and the clinical stage was marked as Stage Ic.^{14–16}

The currently advocated management of the fallopian tube carcinoma is more or less like epithelial ovarian malignancy. The patient was treated with total hysterectomy with lymph node biopsy followed by chemotherapy. Postoperatively the patient recovered very well in terms of her primary symptoms. She did suffer from side effects of chemotherapy like mild nausea and vomiting (her complete blood count and renal function test were within normal limit). The Ca 125 levels fell from 218 to 88 within a 6 weeks time.

The literature reveals the participation of fallopian tube carcinoma as 0.31% to 1% of female genital malignancies. The current suggested management is to treat such malignancies as epithelial ovarian malignancy. The other managements suggested are intraperitoneal chemotherapy, second look surgery, radiotherapy, neo adjuvant chemotherapy, and immunotherapy or gene therapy. But the results of these managements are not promising. Intraperitoneal chemotherapy is not so popular because of toxicity. A number of unanswered fundamental questions regarding efficacy, of optimal agent, schedule, future trial designs, and the impact of alternative agents such as biologic therapies (vascular endothelial growth factor and epidermal growth factor targeting) have limited the general acceptance of this strategy in the clinical practice.¹⁸ Clinical investigation is ongoing. However, second look surgery is not advocated because of chances of negative second-look operation due to factors like 1) low tumor grade, 2) no residual disease after primary operation, 3) young age (younger than 55 years), and rapid regression to normal of

increased CA 125 values during chemotherapy.¹⁷ Radiation is not used, as there are no large-scale trial data available for this technique and because of the risk of complications and the lack of extensive data regarding its effectiveness; whole abdominal radiation has generally not been used in these cases. For immunotherapy and gene therapy no detail data are available.

Patient came to us about 7 months after the primary diagnosis of ovarian mass in December 2008. She was afraid of surgery and took some ayurvedic treatment from her local doctor. But as there was no improvement she came to us. If she would have come to us immediately after her CT scan then the size and grade of tumor would have been less.

References

1. Lialis A, Bakalianou K, Mpolsa E, et al. Fallopian tube malignancies. A retrospective clinical pathological study of 17 cases. *J Obstet Gynecol* 2008;28(7):93–5.
2. Benedet JL, Bender H, Jones H 3rd, Nagan HY and Pecorelli S. FIGO staging classifications and clinical practice guidelines in the management of gynaecological cancers. FIGO Committee on Gynecologic Oncology. *Int J Gynaecol Obstet* 2000;70:209–62.
3. Stewart SL, Wilke JM, FASTER SL. The incidence of primary fallopian tube cancer in the United States. *Gynecol Oncol* 2007;107(2):392–7.
4. Colgan TJ. Challenges in the early diagnosis and staging of Fallopian tube carcinomas associated with BRCA mutations. *Int J Gynecol Pathol* 2003;22:109–20.
5. Klein M, Rosen A, Lahousen M, Graf AH, Rainer A. The relevance of adjuvant treatment in primary carcinoma of fallopian tube stage 1 & 2: irradiation v/s chemotherapy. *Int J Radiol Oncol Biol Phys* 2000;48(5):1427–31.
6. Sedlis A. Carcinoma of the fallopian tube. *Surg Clin North Am* 1978;58:12–19.
7. Woolas RP, Smith JHF, Sarharnis P et al. Fallopian tube carcinoma: an under-recognized primary neoplasm. *Int J Gynecol Cancer* 1997;7:284–288.
8. Rosen AC, Klein M, Hafner E et al. Management and prognosis of primary fallopian tube carcinoma. Austrian Cooperative Study Group for Fallopian Tube Carcinoma. *Gynecol Obstet Invest* 1999;47:45–51.
9. Henderson SR, Harper RC, Salazar OM et al. Primary carcinoma of the fallopian tube: difficulties of diagnosis and treatment. *Gynecol Oncol* 1977;5:168–79.
10. Asmussen M, Kaern J, Kjoerstad K et al. Primary adenocarcinoma localized to the fallopian tubes: report on 33 cases. *Gynecol Oncol* 1988;30:183–6.
11. Riska A, Leminen A, Pukkala E. Sociodemographic determinants of incidence of primary fallopian tube carcinoma, Finland 1953–97. *Int J Cancer* 2003;104:643–5.
12. Woolas R, Jacobs I, Davies AP et al. What is the true incidence of primary fallopian tube carcinoma? *Int J Gynecol Cancer* 1994;4:384–8.
13. Wang PH, Yuan CC, Chao HT et al. Prognosis of primary fallopian tube adenocarcinoma: report of 25 patients. *Eur J Gynecol Oncol* 1998;19:571–4.

14. Boutselis JG, Thompson JN. Clinical aspects of primary carcinoma of the Fallopian tube: a clinical study of 14 cases. *Am J Obstet Gynecol* 1971;111:98–101.

15. Chalmers JA, Marshall AT. Carcinoma of the fallopian tube. *Br J Obstet Gynaecol* 1976;83:580–3.

16. Pfeiffer P, Mogensen H, Amtrup F et al. Primary carcinoma of the fallopian tube. A retrospective study of patients re-

ported to the Danish Cancer Registry in a five-year period. *Acta Oncol* 1989;28:7–11.

17. Takeshima N, Hasumi K. Treatment of fallopian tube cancer. Review of the literature. *Arch Gynecol Obstet* 2000;264:13–9.

18. Rose PG, Piver MS, Tsukada Y. Fallopian tube cancer. The Roswell Park experience. *Cancer* 1990;66:2661–7.

Paper received: Aug., 23rd 2010; *accepted:* Oct. 26th 2010.

Address for correspondence: Uday Patel, MD, assist. professor, S.B.K.S. Medical Institute & Research Centre, Piraria, TA Waghodia, District Vadokara, State Gujarat, India; e-mail: mitr-uday78@yahoo.com.