

# Giant Aneurysm of Basilar Artery

Lidija Šapina<sup>1</sup>, Gordana Lojen<sup>1</sup>, Željka Janjetović<sup>2</sup> and Željka Vuković-Arar<sup>2</sup>

<sup>1</sup> »Dr. Josip Benčević« General Hospital, Department of Neurology, Slavonski Brod, Croatia

<sup>2</sup> »Dr. Josip Benčević« General Hospital, Department of Ophthalmology, Slavonski Brod, Croatia

## ABSTRACT

*In the article we showed the patient, a woman with unruptured giant aneurysm of basilar artery, we showed the done examinations, and therapy dilemmas about what to do in the given case. We found in literature a number of examples which suggest operation treatment, but of embolisation too, some suggest conservative treatment.*

**Key words:** aneurysm, basilar artery, treatment, therapy dilemmas

## Introduction

Intracranial aneurysms are vascular abnormalities which ruptures presents subarachnoid bleeding. It happens in the age from 35–65 years, and mostly between 55 and 60 years, 60% of ruptured aneurysm are found in women.

Giant aneurysms are defined as those with diameter is 25 mm or bigger, 60% are in anterior, 40% are in posterior circulation with predilection in vertebrobasilar arteries. Aneurysms originate as effect of prolonged hemodynamic stress, with important role of relationships of anatomic locality, hemodynamics and degenerative factors. Physical exertions and emotional stress are precursors of rupture<sup>1</sup>.

Unhemorrhagic symptoms and the signs of unruptured aneurysms are manifested as »mass effect«, thrombosis, embolisation, epileptic attacks, irritation of meninges.

Diagnosis is stated through neuroradiological treatment: computed tomography (CT), multi slice-computed-tomography of brain (MSCT), multi-slice angiography (MSCT angiography), magnetic angiography (MRA), cerebral angiography-digital subtraction angiography (DSA).

Cerebral angiography is »gold standard« for diagnostic and aneurysm evaluation<sup>1</sup>. Most of aneurysms of brain arteries with the locality in anterior circulation is treated by titan »clips«, in posterior circulation with »coil« from platinum (Guglielmi), which is since 1995 acknowledged by FDA as sure and effective method of

treatment, made better by biological active material on the surface polyglycol/polylactat acid which covers platinum and decreases the risk from aneurysm recanalisation<sup>2-6</sup>.

## Case Report

The 63-years-old woman was accepted to the Department of Neurology because of fast lost of sight on both eyes, dull headache in occipital region, afterwards nausea and vomiting. She did not lose consciousness and denied head trauma. Anamnestic: she is hypertensive for many years, at acceptance a very high value of blood pressure. Neurologic state at acceptance: very slowly, asymmetry of the lower part of the face-skin deep left nasolabial furrow, during examination weakened sight on both eyes, sees only shadows, somatic hypertensive.

The following examinations performed:

- CT of the brain: Nativ and with application of contrast medium: on both sides occipital-encephalomalacia, and new ischaemic lesion right, suprasellar right round hyperdense lesion which was after application of the contrast medium specifically opacified and which initiated aneurysm.
- Pancerebral angiography: Giant aneurysm of basilar artery- on the right contour medium third part of basilar artery of wide neck. Dilated type of atherosclerosis.

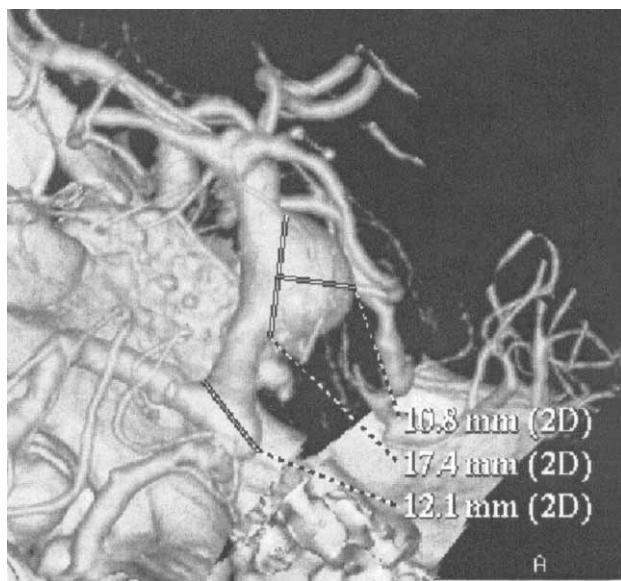


Fig. 1.

- MSCT angiography: in the area of medium part of basilar artery we see saccular aneurysm with the beginning on the right lateral wall with direction cranial in the length 25 mm, dolichoectasy of basilar artery as well as carotid arteries-ACI (Figure 1).
- We consulted: neurosurgeon who did not recommend operation for the reason of the Size and statement of aneurysm, and risk conditions, and neuroradiologist who tries to perform endovascular intervention. Tried embolisation was not successful, and for that reason conservative treatment was continued. During hospital treatment with antihypertensive and antiaggregation therapy, blood pressure was normal value, laboratory parameters were normal. After 4–5 weeks patient had a great headache of pulsatile character, with prompt disturbance of consciousness to deep coma. There was a doubt of rupture of existed aneurysm. CT of the brain showed great unruptured aneurysm of basilar artery and great recent ischaemic lesion of cerebellum and brain trunk and brain parenchyma parietooccipital left, in the area of thalamus, with compression of III and IV ventricle which caused by edema. She died after 24 hours. Autopsy was not done (family overload).

## Discussion

The clinical dilemma – what to do with the patient with unruptured giant aneurysm of basilar artery, with

added risk factors for cerebrovascular illness: arterial hypertension, atherosclerosis, adiposity, to decide whether endovascular or operative or conservative treatment? The examples from literature, as well as from clinical practice showed that the decision is individual, concerning risk factors and the greatness of aneurysm.

The risk of death is too high for non operated aneurysms for the reason of embolisation of intraneurysmatic situated thromb and followed ischaemia distal from aneurysm and possibility of rupture, and it is 14.5%–40%<sup>7</sup>. The data from literature show always the same dilemma: surgery (operation) or endovascular (coil placing) or conservative treatment<sup>1,7–9,16–20</sup>. The lowest risk for rupture has the aneurysm located in the anterior circulation if not greater from 10 mm in diameter. The greatest risk for rupture has aneurysm 10 mm in diameter or bigger located in posterior circulation. The risk can be made lower by very careful anticoagulation, antihypertensive therapy, avoiding of physical activities and by lowering of other risks, but epidemiological data are not very good and took about very high grade of individuality, further of death during next 5 years<sup>1,8</sup>.

In the decision of therapeutic treatment very important role has the configuration of aneurysm. If it is longish and narrow, it is better for coil, and otherwise not<sup>10,16–20</sup>. ISAT study has proved that therapeutic decision of ruptured intracranial aneurysm is same good endovascular and neurosurgical treatment, but concerning risks from new bleeding is more frequent of endovascular treatment<sup>11</sup>. Recovering of the patient with the damage of posterior circulation, whether if it is infarct of aneurysm, need very careful physical therapy with limited possibilities of recovery of neurological attacks: walk-balance, sight, sensory functions<sup>12–15</sup>.

Diagnosis will be given through non invasive and invasive diagnostic treatment, near interdisciplinary cooperation of neurologist and neurosurgeon with radiologist-neuroradiologist, anesthesiologist, as well as doctor known risk factors and possible decisions, to get the highest quality of life of such patients.

The patient from our description died for the reason of massive ischaemic cerebral infarct which developed as consequence of mobilisation of intraneurysmatic situated thromb distal from aneurysm 24 hours after starting of headache, and after that coma statement and not for the reason of rupture of aneurysm. Unfortunately, autopsy was not done (family overload).

## REFERENCES

1. AMINOFF MJ, DAROFF R, Encyclopedia of the neurological sciences, 1 (2003) 161. — 2. BENDESZUS M, BARTSCH AJ, SOLYMOSI L, Stroke, 38 (2007) 2855. — 3. BENDESZUS M, SOLYMOSI L, Am J Neuroradiol, 27 (2006) 2053. — 4. OGILVY CS, CARTER BS, Neurosurgery, 52, (2003) 82. — 5. OGILVY CS, HOH BL, SINGER RJ, PUTMAN CM,

Neurosurgery, 51 (2002) 14. — 6. PIEROT L, BONAFE A, BRACARD S, LECLERC X, Am J Neuroradiol, 27, (2006) 1693. — 7. MEYER-LINDENBERG A, MEWES J, BINIEK R, Der Nervenarzt, 68 (1997) 674. — 8. AMMERER HP, DOBNER T, IVE-SCHAPPELWEIN, LOYDDINUM, J Neurol Neurochir Psychiatr, 4 (2003) 14. — 9. NATIONAL INSTITUTE

- OF NEUROLOGICAL DISORDERS AND STROKE, Cerebral aneurysm fact sheet. NINDS. November 2009. NIH Publication No. 08-5505. — 10. JOHNSTON SC, GRESS DR, KAHN JG, Neurology, 52 (1999) 1806. — 11. MOLYNEUX A, KERR R, STRATTON I, SANDECOCK P, CLARKE M, SHRIMPSON J, HOLMAN R, Lancet, 360 (2002) 1267. — 12. BARKER FG 2nd, AMIN-HANJANI S, BUTLER WE, HOHN BL, RABINOV JD, JAMES D, PRYOR JC, OGILVY CS, CARTER BS, Neurosurgery, 54 (2004) 18. — 13. CLINCHOT DM, KAPLAN P, MURRAY DM, PEASE WS, Arch Phys Med Rehabil, 75 (1994) 1342. — 14. NG YS, STEIN J, SALLES SS, BLACK-SCHAFFER RM, Arch Phys Med Rehabil, 86 (2005) 2138. — 15. ZOROWITZ RD, Top Stroke Rehabil, 12 (2005) 50. — 16. ZHU YQ, LI MH, FANG C, TAN HQ, WANG W, ZHANG PL, CHENG YS, WANG JB, MA LT, J Endovasc Ther, 17(1) (2010) 55. — 17. TAN HQ, LI MH, LI YD, FANG C, WANG JB, WANG W, WANG J, ZHANG PL, ZHU YQ, Cerebrovasc Dis, 31(2) (2010) 154. — 18. WANG JB, LI MH, FANG C, WANG W, CHENG YS, ZHENG PL, DU ZY, WANG J, Neurosurgery, 62(5) (2008) 1176. — 19. WEHMAN JC, HANEL RA, LEVY EL, HOPKINS LN, Neurosurgery, 5 Suppl 3 (2006) S125. — 20. VAN ROOIJ WJ, SLUZEWSKI M, AJNR Am J Neuroradiol, 30(1) (2009) 12.

L. Šapina

»Dr. Josip Benčević« General Hospital, Department of Neurology, A. Štampara 42, 35000 Slavonski Brod, Croatia  
e-mail: lsapina@net.hr

## GIGANTSKA ANEURIZMA ARTERIJE BAZILARIS

### SAŽETAK

U članku smo prikazali bolesnicu sa nerupturiranom gigantskom aneurizmom arterije bazilaris, prikazali učinjene pretrage, te terapijske dileme što učiniti u konkretnom slučaju. U literaturi smo našli niz primjera koji govore u prilog operativnom liječenju, ali i embolizaciji, dok dio stručnjaka zagovara konzervativni tretman.