

Candan Efeoglu, Gülcan Coşkun

Zbrinjavanje pacijenta koji je progutao privremenu djelomičnu protezu: prikaz slučaja

Management Issues of a Patient who Ingested a Denture: a Case Report

Stomatološki fakultet Sveučilišta Ege, Bornova – Izmir, Turska
School of Dentistry University Ege, Bornova – Izmir, Turska

Sažetak

U ovom prikazu slučaja ističu se moguće opasnosti u zbrinjavanju pacijenata koji progutaju privremenu djelomičnu zubnu protezu. Tako je u hitnu pomoć primljen je 47-godišnji muškarac nakon što je slučajno progutao loše prilagođenu djelomičnu protezu. Najprije je pregledan laringoskopom uz topikalnu anesteziju, a zatim je snimljen rendgenogram. Nakon toga slijedila je hospitalizacija i ezofagoskopija u općoj anesteziji kako bi se uklonio predmet i on potpuno oporavio. Naime, nestabilne zubne proteze i one s lošom retencijom predstavljaju rizik za pacijenta jer ih može progutati ili aspirirati. Zato ih treba izbjegavati ili se njima koristiti privremeno tek nakon što smo osigurali dodatnu retenciju i stabilizaciju.

Zaprimljen: 10. prosinca 2010.

Prihvaćen: 29. ožujka 2011.

Adresa za dopisivanje

Dr. Candan Efeoglu
Ege University School of Dentistry
Department of Oral Surgery
Bornova-Izmir Turkey,
35100 Bornova
Tel: 00 90 232 3881108
cefeoglu@yahoo.com

Ključne riječi

gutanje; usisavanje udahom; zubne proteze, djelomične, mobilne; zubne proteze, zadržavanje; strana tijela

Uvod

Strana tijela poput novčića, ribljih kostiju, zalogaja hrane ili baterija najčešći su predmeti s kojima imaju problema kirurzi na otorinolaringologiji (1–4). Isto tako zabilježene su ingestija i aspiracija proteza, ispuna i stomatoloških instrumenata, poput endodontskih iglica (5–7).

Privremena djelomična zubna proteza razmjerno je mala i obično nadomješta jedan ili dva prednja zuba, pa je često nazivamo "žabica". Naime, umjetni se zubi pričvršćuju na nepčanu ploču koja oblikom podsjeća na žlicu. Ta proteza oslanja se uglavnom samo na adheziju za retenciju i stabilizaciju, nema kvačica i nije u doticaju s palatinalnim ploham lateralnih zuba. Zbog toga je nestabilnija od konvencionalnih proteza. Pacijent se mora naviknuti pridržavati je jezikom dok jede (8,9). Dakle, loša stabilnost glavni je nedostatak te proteze koja može prouzročiti i recesije desni, daljnje rasklimavanje te čak opstrukciju dišnih puteva. Prednosti su joj, pak, niski troškovi, jednostavna izrada, mogućnost prilagodbe, smanjen rizik od karijesa i jednostavniji parodontni problemi u usporedbi s ostalim alternativnim metodama (8,9).

Introduction

Foreign bodies such as coins, fish bones, food bolus and batteries are commonly found by the ear nose and throat (ENT) surgeons (1-4). Ingestion or aspiration of dentures, restorations and dental instruments such as files have also been previously reported (5-7).

A spoon denture is a small denture which is used to replace one or two anterior teeth. The teeth are then attached to a spoon-shaped palatal plate. It relies on adhesion alone to hold the plate in place as it is in contact with palatal surfaces of the posterior teeth but without clasps. Hence these dentures tend to be more mobile than conventional dentures. The patient also needs to acquire the skills of using their tongue to stabilise it while eating (8,9). The lack of stability is the main disadvantage which may lead to gum recession, further loosening and even obstruction of the airway (8,9). On the other hand, they have advantages such as low cost, simplicity of fabrication, modifying and a reduced risk of caries or periodontal problems compared to other alternative methods of restoration (8,9).

Prikaz slučaja

47-godišnji muškarac došao je u hitnu pomoć jer je progutao gornju protezu nakon jakog napadaja kašlja. Osjećao je nelagodu u predjelu prsne kosti te disfagiju kod gutanja krute hrane. U prsima nije osjećao bol. Dotadašnje bolesti nije naveo, a nije uzimao ni lijekove.

Tijekom pregleda pacijent nije pokazivao znakove respiratornih problema. Laringoskopskim pregledom orofarinksa, hipofarinksa i larinksa nisu bili uočeni znakovi patoloških promjena.

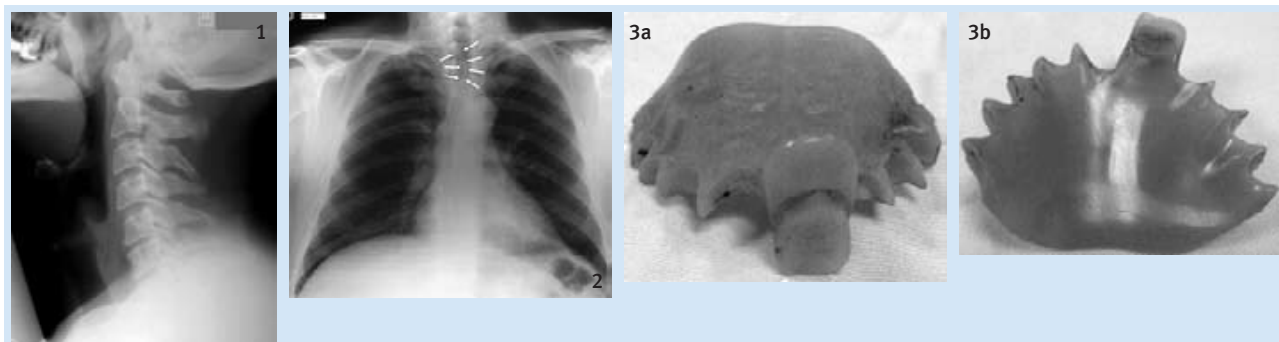
Lateralni rendgenogram (slika 1.) vrata nije pokazao patološke promjene, ali je zato rendgenska slika prsnog koša upozorila na strani predmet zaglavljen u jednjaku u razini drugog rebra, iza sternuma (slika 2.). Pacijent je primljen u bolnicu te mu je proteza izvađena metodom krute ezofagoskopije u općoj anesteziji (slika 3.). Oporavak je bio brz i bez komplikacija te je otpušten sljedeći dan.

Case report

A 47-year-old man arrived at the Accident and Emergency Department. His presenting complaint was that he swallowed his upper denture after a bout of severe coughing. He had discomfort at the level of sternal notch. He also complained of dysphagia to solids. He denied any chest pain. He did not have any significant past medical history and was not on any regular medication.

On examination the patient looked well with no signs of respiratory distress. The examination of the oropharynx, hypopharynx and the laryngeal inlet using the fibre optic laryngoscope did not reveal any pathology.

A lateral neck x-ray (Figure 1) did not reveal any pathologies but the chest x-ray revealed the FB at the level of the 2nd rib behind the sternum in the patient's oesophagus (Figure 2). The patient was admitted to hospital and the denture was removed using a rigid oesophagoscopy procedure under general anaesthesia (GA) (Figure 3). The patient's recovery was uneventful; the patient remained in hospital overnight and was discharged the following day.



Slika 1. Lateralni rendgenogram vrata

Figure 1 Lateral view of the neck

Slika 2. Proteza iza sternuma u jednjaku na razini trećeg rebra

Figure 2 Chest film revealed the missing denture behind the sternum in the oesophagus at the level of 3rd ribs.

Slika 3a i 3b. Izgled izvađene proteze za nadomještanje gornjega lijevog srednjeg inciziva

Figure 3a, 3b Views of the recovered spoon denture designed to restore the missing upper left central incisor.

Rasprava

Slučaj aspiracije ili gutanja stranog predmeta kao što je proteza zahtijeva hospitalizaciju sve dok se taj predmet ne ukloni ili dok samostalno ne prođe kroz gastrointestinalni trakt. Oralni laringoskopski pregled te topikalni anestetik sigurni su i jeftini načini detekcije stranih tijela ako su iznad krikofaringealnog ušća. Za sve druge slučajeve ingestije stranih predmeta ezofagoskopija je jedina kirurška metoda kojom se uklanjaju strana tijela iz jednjaka (3,4). Rendgenogram vrata i prsnog koša potreban je kako bi se vizualno odredilo gdje se nalazi strani predmet, no ponekad se ne vidi zbog toga što ne baca sjenu ili ga strukture vrata i prsnog koša čine nejasnim (10).

U ovom slučaju veličina proteze i razmjerno oštar incizalni rub umjetnih zuba predstavljali su velik rizik za pacijenta te je zato bila odabrana tehnika krute ezofagoskopije. Ako se strani predmet ostavi in situ, mogu nastati komplikacije kao što su retrofaringealni apsces, pneumotoraks, emfizem, ma-

Discussion

Aspiration or swallowed foreign body such as a denture requires hospitalisation until the FB is removed or passed through gastrointestinal system spontaneously. Oral examination followed by laryngoscopic examination under topical anaesthesia is a safe and cost-effective technique for detecting and removing foreign bodies at, above or just below the cricopharyngeal junction (3,4). For all other cases of FB ingestion oesophagoscopy is the only surgical option to retrieve oesophageal foreign bodies.¹⁰ The radiograph of neck and chest may be necessary to visualise foreign bodies but occasionally these images may be normal as the denture may not be radio-opaque enough or obscured by the soft tissue in the neck and chest (10).

In such a case, both the size of the denture and its relatively sharp incisal edge were considered as high risk to the patient and therefore retrieval with rigid oesophagoscopy was performed. If left in situ, foreign bodies may sometimes lead to potential fatal

diastinitis, perforacija jednjaka, retroesofagealni apsces, esofagealno-aortna fistula, apsces pluća, traheo-esofagealna fistula, potkožni emfizem, pneumomediastinitis i epiduralni emfizem (1,5,10–14).

Retencija “žabice” uglavnom ovisi o adheziji nepčane ploče i sline. To je rezultiralo odvajanjem proteze od ležišta zbog silovite inhalacije između pojedinačnih iskašljaja. Taj incident upozorava na problem sigurnosti pacijenata koji se služe protezama s lošom retencijom. Rizik od aspiracije ili gutanja teoretski postoji kod svih pacijenata s protezama. Nedvojbeno je da je opasnost veća ako proteza ima lošu retenciju. Slabo prilagođena ili potrgana proteza isto se tako može progutati tijekom jela ili u slučaju epileptičkog napada (1,5,6,14,15). Posebice su opasne unilateralne djelomične proteze. Zbog toga su osmišljene mnogobrojne tehnike i savjeti u vezi s komplikacijama kako bi pacijenti izbjegli navedene komplikacije (16–21).

Treba izbjegavati žličaste i unilateralne djelomične proteze zbog loše retencije i veličine. Sigurnije su one konvencionalne ili adhezivni mostovi te djelomične proteze na implantatima (22–24). Unatoč svemu, žličaste i unilateralne djelomične proteze dobre su ako se primjenjuju kao privremeno protetičko rješenje ili ako je potrebno stalno podlaganje proteza (25). Kada se planira takva privremena proteza, osobitu pozornost treba posvetiti retenciji i stabilizaciji.

Proteze se često izrađuju od radiolucenog akrilata. U slučaju pomaka ili frakture, te nakon toga aspiracije ili ingestije, vrlo ih je teško uočiti na rendgenogramu, što otežava dijagnozu i tretman (26,27). Izborom materijala za protezu koji baca sjenu na rendgenogramu mogla bi se smanjiti incidencija pogrešnih ili produženih dijagnoza nakon ingestije. Kako akrilati koji bacaju sjenu na rendgenogramu nisu dostupni u širokoj primjeni, bilo bi praktičnije odabrati radioopakne materijale za proizvodnju proteza kao što su čelične žice ili soli teških metala (barijev fluorid, barijev sulfat, barijev akrilat ili bizmutovo staklo) (8,22,27,28). Nažalost, dodavanjem tih spojeva stvara se tendencija za nastanak stresa u akrilatu te on slabi (22,23). Kao alternativna metoda nameće se korištenje polimera s monomerima jer sadržavaju teški atom u svojoj strukturi te bi tako polimerizirani akrilat imao radioopakna svojstva i lakše bi ga se detektiralo rendgenogramom (29,30). Godine 1981. američko Vijeće za stomatološke materijale, instrumente i opremu preporučilo je primjenu radioopaknih akrilata u stomatologiji nakon «post mortem» izvješća u kojem je kao uzrok smrti bilo navedeno gušenje zbog aspiracije proteze.

Vrlo je važno napraviti proteze koje će pravilno prijanjati. One oštećene, ili ako imaju lošu retenciju, treba ukloniti i nadomjestiti novima kako bi se spriječila slučajna ingestija ili aspiracija. To znači da pacijente s mobilnim protezama treba redovito kontrolirati kako bi se pravodobno uočili problemi (30,31).

complications like retropharyngeal abscess, pneumothorax, surgical emphysema, mediastinitis, oesophageal perforation, retroesophageal abscess, oesophagus-aortic fistula, lung abscess, tracheo-oesophageal fistula, subcutaneous emphysema, pneumomediastinum and epidural emphysema (1,5,10-14).

Retention of the spoon denture depended solely on the adhesion effect of the palatal plate and saliva. This resulted in dislodging of the denture during forceful oral inhalation between coughs as it happened in this case where the patient had a coughing fit. This incident raises questions regarding the safety of dentures with poor retention. Theoretically, the risk of aspiration or swallowing exists for all types of prosthetic appliances. Undoubtedly the risk is higher in the case of dentures with poor retention. An ill fitting or broken denture may also be accidentally swallowed during a meal or after an epileptic seizure (1,5,6,14,15). The hazards of unilateral removable partial dentures have long been recognized.² Numerous techniques and advice to the patients have been devised to avoid these complications (16-21).

The use of spoon dentures or unilateral removable partial dentures should best be avoided due to their small size and poor retention, and the latter certainly pose a higher risk because of their small size and sharp clasps (22,23,24). Some safer alternatives include conventional or adhesive bridges and implant supported fixed partial dentures (25). However, these dentures still play an important role when the denture is meant to be used short term or where alterations such as additions or relines would be necessary. When such a removable denture is planned, it should be designed in such a manner as to render it retentive and stable.

Dentures are frequently made of acrylic resin which is radiolucent. In case of displacement or fracture and subsequent loss by ingestion or inhalation, it may be extremely difficult to detect dentures on radiographs thus causing a delay in diagnosis and appropriate treatment (26,27). The use of the radioopaque material in the fabrication of dentures may reduce the incidence of missed or delayed diagnosis when such plates are ingested. Since commercial radio-opaque polymethylmetacrylate denture base material is not widely available, it may be more practical to introduce the radio-opaque materials such as stainless steel wire or heavy metal salts (barium fluoride, barium sulphate, bismuth glass, and barium acrylate) into the denture during fabrication (8, 22,27,28) Unfortunately, the incorporation of these materials into acrylic tends to increase stress concentrations thus weakening the material (22,23). Alternatively, the production of co-polymers with one of the comonomers containing a heavy atom could be a useful manufacturing strategy to enable radiographic detection of aspirated or ingested dentures (29,30). In 1981, the American Council on Dental Materials, Instruments and Equipment recommended the use of radio-opaque acrylic in dentistry, following a coroner's report regarding a death resulting from inhalation of a denture (30, 31).

It is imperative that dentures are made to fit properly. Damaged or poorly retentive dentures should be discarded and replaced in order to prevent accidental ingestion or aspiration. Therefore, the patients wearing removable dentures should be regularly examined to enable early detection of such problems.

Zaključak

Stomatolozi trebaju izbjegavati unilateralne djelomične proteze. Žličastim djelomičnim protezama treba se koristiti u rijetkim slučajevima i to samo privremeno. Pacijentima također treba preporučiti da izvade proteze dok spavaju.

Conclusion

Dentists should always avoid the delivery of unilateral removable dentures to their patients and spoon dentures should be reserved for rare cases to be used for short periods. In addition, patients should be strongly advised against wearing removable dentures during sleep.

Abstract

This case study aims to highlight the potential hazards and the management of a patient who ingested a spoon denture. Case report: A 47 years old man attended the Accident and Emergency Department after accidentally ingesting his poorly fitted denture. Initial management included examination with a laryngoscope under topical anaesthesia and the appropriate films to detect the foreign body (FB). Hospitalisation and rigid oesophagoscopy under general anaesthesia (GA) was required to remove it and recovery was uneventful. Poorly retentive and unstable dentures pose a risk of ingestion or aspiration for patients and therefore should be avoided or temporarily used provided that the necessary measures to improve retention and stability are taken.

Received: December 10, 2010

Accepted: March 29, 2011

Address for correspondence

Dr. Candan Efeoglu
Ege University School of Dentistry
Department of Oral Surgery
Bornova-Izmir Turkey,
35100 Bornova
Tel: 00 90 232 3881108
cefeoglu@yahoo.com

Key words

Ingestion, Respiratory Aspiration,
Denture, Partial, Removable; Dental
Prosthesis Retention; Foreign Bodies

References

- Nayak SR, Kirtane MV, Shah AK, Karnik PP. Foreign bodies in the cricopharyngeal region and oesophagus (a review of 226 cases). *J Postgrad Med.* 1984 Oct;30(4):214-8.
- Baraka A, Bikhazi G. Oesophageal foreign bodies. *Br Med J.* 1975 Mar 8;1(5957):561-3.
- Janik JE, Janik JS. Magill forceps extraction of upper esophageal coins. *J Pediatr Surg.* 2003 Feb;38(2):227-9.
- Kumar A, Singh S, Low C, Shahab R. A safe and cost-effective method of removal of obstructed pharyngeal foreign body in the accident and emergency department. *Eur Arch Otorhinolaryngol.* 2005 Mar;262(3):192-3.
- Rajesh PB, Goiti JJ. Late onset tracheo-oesophageal fistula following a swallowed dental plate. *Eur J Cardiothorac Surg.* 1993;7(12):661-2.
- Peters TE, Racey GL, Nahman BJ. Dental prosthesis as an unsuspected foreign body. *Ann Emerg Med.* 1984 Jan;13(1):60-2.
- Heggie AA, Walker JD. Traumatic pharyngeal displacement of a full maxillary denture: case report. *J Oral Maxillofac Surg.* 1989 Nov;47(11):1208-10.
- Tyson K, Yemm R, Scott B. General principles of partial dentures and how they work. In: Tyson K, Yemm R, Scott B, editors. *Understanding Partial Denture Design.* Oxford: Oxford University Press; 2006. p. 42-63.
- Barclay C. Prosthodontics. In: Heasman PA, editor. *Master dentistry. Restorative dentistry, pediatric dentistry and orthodontics.* Toronto: Churchill Livingstone; 2003. p. 147.
- Athanassiadi K, Gerazounis M, Metaxas E, Kalantzi N. Management of esophageal foreign bodies: a retrospective review of 400 cases. *Eur J Cardiothorac Surg.* 2002 Apr;21(4):653-6.
- Wilson RT, Dean PJ, Lewis M. Aortoesophageal fistula due to a foreign body. *Gastrointest Endosc.* 1987 Dec;33(6):448-50.
- Leow CK. Subclavian arterio-esophageal fistula secondary to fish bone impaction: report of a case. *Surg Today.* 1998;28(4):409-11.
- Hollander JE, Quick G. Aortoesophageal fistula: a comprehensive review of the literature. *Am J Med.* 1991 Sep;91(3):279-87.
- Dinleyici EC, Kocak K, Ilhan H, Ozkan R, Tutuncu R, Bor O. Subcutaneous emphysema, pneumomediastinum and epidural emphysema in a child due to foreign body aspiration mimicking croup syndrome. *Int J Pediatr Otorhinolaryngol Extra.* 2008;3(1):35-8.
- Goodacre CJ. A dislodged and swallowed unilateral removable partial denture. *J Prosthet Dent.* 1987 Jul;58(1):124-5.
- Jacobi R, Shillingburg HT Jr. A method to prevent swallowing or aspiration of cast restorations. *J Prosthet Dent.* 1981 Dec;46(6):642-5.
- Zakaria AA. Methods to preclude aspiration or swallowing of dental appliances. *J Prosthet Dent.* 1975 May;33(5):575-6.
- Bohnenkamp DM. Replacement of a fractured unilateral removable partial denture with a nonrigid fixed prosthesis: a clinical report. *J Prosthet Dent.* 1996 Jun;75(6):591-3.
- Luk K, Tsai T, Hsu S, Wang FL. Unilateral rotational path removable partial dentures for tilted mandibular molars: design and clinical applications. *J Prosthet Dent.* 1997 Jul;78(1):102-5.
- Zitzmann NU, Elsasser S, Fried R, Marinello CP. Foreign body ingestion and aspiration. *Oral Surg Oral Med Oral Pathol Oral Radiol Endod.* 1999 Dec;88(6):657-60.
- Al-Rashed MA. A method to prevent aspiration or ingestion of cast post and core restorations. *J Prosthet Dent.* 2004 May;91(5):501-2.
- Chandler HH, Bowen RL, Paffenbarger GC. The need for radiopaque denture base materials: a review of the literature. *J Biomed Mater Res.* 1971 May;5(3):245-52.
- Chandler HH, Bowen RL, Paffenbarger GC. Development of a radiopaque denture base material. *J Biomed Mater Res.* 1971 May;5(3):253-65.
- Stafford GD, MacCulloch WT. Radiopaque denture base materials. *Br Dent J.* 1971 Jul 6;131(1):22-4.
- Walmsley AD, Walsh TF, Burke FJT, Lumley PJ, Hayes-Hall R. Integrated treatment planning. In: Walmsley AD, Walsh TF, Burke FJT, Lumley PJ, Hayes-Hall R, editors. *Restorative dentistry.* Edinburgh: Churchill Livingstone; 2002. p. 179.
- Nwafo DC, Anyanwu CH, Egbue MO. Impacted esophageal foreign bodies of dental origin. *Ann Otol Rhinol Laryngol.* 1980 Mar-Apr;89(2 Pt 1):129-31.
- Firth AL, Moor J, Goodyear PW, Strachan DR. Dentures may be radiolucent. *Emerg Med J.* 2003 Nov;20(6):562-3.
- Hashmi S, Walter J, Smith W, Latis S. Swallowed partial dentures. *J R Soc Med.* 2004 Feb;97(2):72-5.
- McCabe JF, Wilson HJ. A radio-opaque denture material. *J Dent.* 1976 Sep;4(5):211-7.
- Sarginson DR. Radiopaque substances in denture manufacture. *Br Dent J.* 1991 May 11;170(9):327.
- Yeoh NT. Impacted dentures in the oesophagus. *Med J Malaysia.* 1982 Dec;37(4):344-8.