

VETERINARSKI ARHIV 75 (2), 153-158, 2005

## Transplantation of bovine foetal tendon in rabbit flexor tendon

Seifollah N. Dehghani<sup>1\*</sup>, Mina Tadjalli<sup>2</sup>, and Ali Akbari<sup>1</sup>

<sup>1</sup>Department of Veterinary Surgery, School of Veterinary Medicine, Shiraz University, Shiraz, Iran

<sup>2</sup>Department of Veterinary Anatomy, School of Veterinary Medicine, Shiraz University, Shiraz, Iran

---

**DEHGHANI, S. N., M. TADJALLI, A. AKBARI: Transplantation of bovine foetal tendon in rabbit flexor tendon. Vet. arhiv 75, 153-158, 2005.**

### ABSTRACT

Tendon laceration and rupture are common among large animals. The purpose of this study was to use flexor tendons of foetal calf collected from a slaughterhouse and to transplant them in rabbit flexor tendons experimentally. The tendons of a 6-month-old bovine foetus were collected and preserved in sterile saline solution at 4 °C. About 5 cm of the superficial flexor tendon were resected in 12 rabbits and 5 cm of the bovine embryo flexor tendon were replaced and sutured using 3/0 stainless steel wire in a single locking loop suture pattern. The tendon sheet was sutured over the transplanted tendon completely in the first group (4 rabbits). It was not sutured in the second group (4 rabbits), and in the third group only half of the tendon sheet was sutured over the transplanted tendon (4 rabbits). In the first and second groups the host graft tendon was united firmly, showing no signs of rejection. In the third group there was inflammatory reaction and hypercellularity in three rabbits and with no sign of graft take in the fourth rabbit. It was therefore concluded that using embryonic bovine tendon for reconstruction of severe tendon damage in clinical cases could be helpful.

**Key words:** tendon transplantation, xenograft, heterograft, bovine foetus, rabbit

---

### Introduction

Tendon laceration and rupture are common among large animals and give rise to a clinical situation that excludes the animal from work and exercise (STASCHAK, 1998). Tendon length needs to be improved in conditions such as tendon ossification, flexed tendons, tumours, strain, ruptured tendon and chronic tendosynovitis. Vehicle accidents and burns can also cause severe tendon damage and laceration. Autogenous tendon transplant and allogenic transplantation of tendon have been performed with varying degrees of

---

\* Contact address:

Dr. Seifollah N. Dehghani. DVM. MVSc., Professor and Head. Department of Veterinary Surgery, School of Veterinary Medicine, Shiraz University, Shiraz, 71345 (P.O. Box. 1731). IRAN, Phone: 0098-711-6280702; Fax: 0098-711-6280707; E-mail: sdehghan04@yahoo.com

success (BIRSH et al., 1999; GILLIS, 1997). Allogenic tendon transplantation has been undertaken experimentally in chicken (ZHANG et al., 2001). Hamstring tendon graft was used for anterior cruciate ligament reconstruction (GORDIA and GRANA, 2001). Artificial tendon has been transplanted in man (DONG and SHENG, 1989). There are no reports on heterogenic or xenograft tendon transplantation in the literature. Therefore, the purpose of this study was to use flexor tendons of bovine embryos collected from a slaughterhouse and to transplant them in rabbit flexor tendons experimentally.

### **Materials and methods**

In this study the tendons of a 6-month-old bovine foetus were collected from a slaughterhouse and immediately preserved in sterile saline solution at 4 °C. Twelve white New Zealand rabbits were divided randomly into three equal groups. They were anaesthetized by acetyl promazine HCl (2 mg/kg) and ketamine HCl (20 mg/kg) intramuscularly. The right hind leg was prepared for an aseptic surgical intervention. The skin was incised on the lateral part of distal third of the tibia over the tendons; the fascia and tendon sheet were incised. About 5 cm of the superficial flexor tendon were resected and 5 cm of the bovine foetal flexor tendon were replaced and sutured with 3/0 stainless steel wire in a single locking loop suture pattern. The tendon sheet was sutured over the transplanted tendon completely in the first group. The tendon sheet was not sutured in the second group, while in the third group only half of the tendon sheet was sutured over the transplanted tendon. The operated leg was bandaged after operation and the rabbits were kept in a restricted area individually to limit their movement.

They received gentamycine antibiotic for five days and dexamethazone for three days post-operatively. After seven days the bandage was removed and the rabbits had freedom of movement. The animals were assessed clinically on a daily basis for 60 days. After two months they were euthanized quietly by thiopental overdose and graft tendon unit was resected for histopathological study. Histopathologic sections were stained by H&E and studied under light microscopy. All animals in this study were handled according to the Shiraz University policy for animal rights.

### **Results**

The rabbits were clinically lame for 1 to 2 days post-operation, dragging the affected leg and not putting weight on it. Later, however, the animals used their legs slightly and the condition improved after 7-10 days post-operation. The bandage was removed on the 7<sup>th</sup> day in order to improve their exercise while they were kept in small, restricted cages to prevent violent movement. There was no wound complication although slight inflammation occurred around the operated site for a few days but which reduced to a normal condition by

day 10 post-operation. After 14 days the rabbits were housed together; they were running and chasing each other with no obvious complications. The results of histopathological study of the host graft tendon showed:

1 - In the first group the host graft tendon was united firmly, showing no signs of inflammation, necrosis, eosinophilia or hypercellularity. There was slight granulation tissue formation in the tendon sections of two rabbits.

2 - In the second group only slight inflammatory reactions were observed in tendon sections of two rabbits out of four. The host graft tendon unit was firm and strong.

3 - In the third group inflammatory reaction, necrosis, eosinophilia and hypercellularity with some degree of connective tissue formation were observed in three rabbits and with no sign of graft take in the fourth rabbit (Table 1).

Table 1. Histopathologic results of bovine foetal tendon transplanted to rabbit flexor tendon

Groups	No.	Inflammation	Necrosis	Eosinophilia	Hypecellularity	No-change	Remarks
I	1	-	-	-	-	+	
	2	-	-	-	-	+	
	3	-	-	-	-	+	Sgt
	4	-	-	-	-	+	Sgt
II	1	-	-	-	-	+	
	2	-	-	-	-	+	
	3	slight	-	-	-	+	
	4	slight	-	-	-	+	
III	1	+	+	+	-	-	
	2	-	-	+	+	-	Ct
	3	+	+	+	-	-	
	4	Graft not	Take				

No Change: no change in the graft structure

Sgt: Slight granulation tissue in one corner

Ct: minimal connective tissue

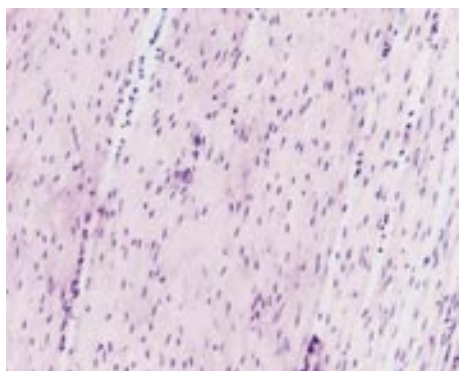


Fig. 1. Normal rabbit tendon. H&E;  $\times 100$ .

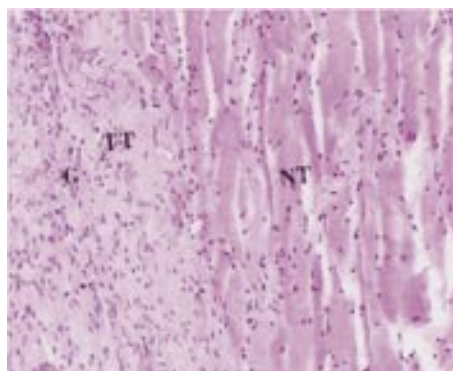


Fig. 2. Histopathologic structure of transplanted bovine foetal tendon in Group 1 showing normal rabbit tendon (NT), transplanted bovine foetal tendon (TT), some granulation tissue (GT). H&E;  $\times 100$ .

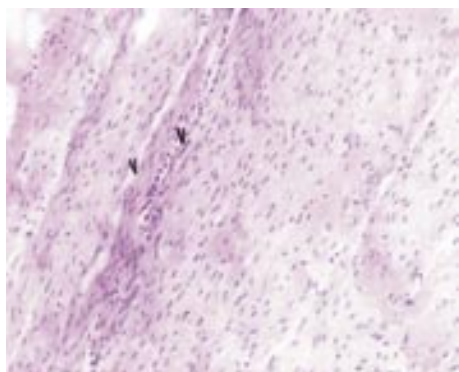


Fig. 3. Transplanted bovine foetal tendon in Group 2 showing granulation tissue and vascularization in the transplanted tendon (V). H&E;  $\times 100$ .

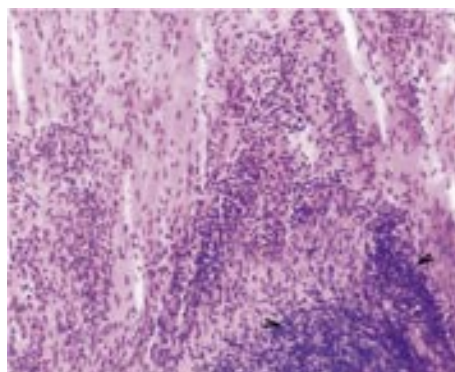


Fig. 4. Histopathologic structure in transplanted bovine foetal tendon showing accumulation of leukocytes. H&E;  $\times 100$ .

## Discussion

Both extrinsic and intrinsic components can be involved in tendon healing. Because the tendon was previously considered as an inert almost avascular structure with low repair potential, healing was thought to take place solely by growth of fibroblasts and capillaries from the peritendinous tissue. Similar to the process of wound healing in the other parts of

the body, tendon healing begins with an inflammatory reaction. Usually, there is outpouring of fibrin and inflammatory cells proportional to the size of the wound, and the amount of trauma and fibroplasia is influenced by the inflammatory reaction (KETCHUM, 1979). It could be that in this study the inflammation was reduced by dexamethazone and antibiotic therapy following operation. In the first group the tendon sheet was completely sutured over the perfectly healed tendon graft unit. In the second group the sheet was not sutured, although it was also firmly healed. In the third group, however, only half of the tendon sheet was sutured over the tendon graft unit, healing produced some complication in three rabbits and no healing in the fourth rabbit. ZHANG et al. (2001) found similar results with experimental allogenic tendon transplantation with sheet grafting in chicken. It is possible that the tendon sheet was overgrown and had caused constriction around the remainder of the tendon and prevented blood supply necessary for the healing process. We were unable to perform biomechanical testing due to small tendon size and the large jaws of the testing instrument, although the appearance of host-graft healed tendon unity was fairly effective in the first and second group. Also, clinical daily evaluation for 60 days showed that the rabbits exercised normally by chasing each other. Immune response to non-specific and altered tissue antigens in soft tissue allografts have been described (PINKOWSKI et al., 1996). No specific reactions were observed in any of the rabbits, generally or locally. Therefore, it is possible that tendon tissue has the least reacting potential, or that the bovine embryo has not developed sufficient antigenic properties to provoke tissue reaction. There were no signs of rejection, clinically or histopathologically, in the first two groups, while complications in the third group could be due to technical problems which caused constriction of blood supply. It was therefore concluded that using embryonic bovine tendon for reconstruction of sever tendon damage in clinical cases could be helpful.

## References

- BIRSH, H. L., J. V. BAILEY, A. J. BAILY, A. E. GOODSHIP (1999): Aged related changes to the molecular and cellular components of equine flexor tendons. *Equine Vet. J.* 31, 391-396.
- DONG, D. Y., C. Y. SHENG (1989): Study of permanent artificial tendon. *Biomater Artif. Cells Artif. Organs* 16, 927-934.
- GILLIS, C. L. (1977): Rehabilitation of tendon and ligaments injuries. *Proc. Am. Ass. Equine Pract.* 43, 306-309.
- GORDIA, V. K., W. A. GRANA (2001): A comparison of outcome at 2 to 6 years of acute and chronic anterior cruciate ligaments reconstruction using hamstring tendon graft. *Arthroscopy* 17, 383-392.
- KETCHUM, L. D. (1979): Tendon healing. *Fundamentals of wound management in surgery.* Hunt and Dunphy. New York. Appleton.

- PINKOWSKI, J. L., J. J. RADRIGO, N. A. SHARKEY, P. B. VASSEUR (1996): Immune response to non specific and altered tissue antigens in soft tissue allografts. *Clic. Orthop.* 326, 80-85.
- STASCHAK, T. (1998): Adams lameness in horse. *Lea & Fabeger. Philadelphia*, pp. 475-485, 762-767.
- ZHANG, Y. L., S. I. WANG, X. S. GAO (2001): Experimental study of allogenic tendon with sheet grafting in chicken. *Zhongguo Xia fu chong Jian wai Ke za zhi* 15, 92-95.

Received: 6 February 2004

Accepted: 1 March 2005

---

**DEGHANI, S. N., M. TADJALLI, A. AKBARI: Presađivanje govede fetalne tetive na fleksornu tetivu kunića. *Vet. arhiv* 75, 153-158, 2005.**

**SAŽETAK**

U velikih životinja česte su rupture i laceracije tetiva. Svrha je ovog rada utvrditi mogućnost presađivanja fleksornih tetiva fetusa teleta uzetih na klaonici i pokusno presađenih na fleksorne tetive kunića. Tetive su uzete od telećeg fetusa starog 6 mjeseci i stavljene u sterilnu fiziološku otopinu na 4 °C. Oko 5 cm površne fleksorne tetive resecirano je u 12 kunića i zamijenjeno s 5 cm fleksorne tetive govedeg fetusa te spojeno jednostrukim "zaključavajućim" šavom tetive učinjenim od 3/0 nerđajuće čelične žice. U prvoj skupini od 4 kunića presadak je bio u cijelosti spojen šavom. U drugoj skupini od 4 kunića presadak nije bio spojen šavom, a u trećoj skupini od 4 kunića polovica presatka bila je spojena šavom. U kunića prve i druge skupine presadak je čvrsto srastao bez vidljivih znakova odbacivanja. U trećoj skupini došlo je do upalne reakcije i hipercelularnosti u tri kunića, a u četvrtog nije bilo znakova prihvaćanja presatka. Stoga se zaključuje da upotreba govede fetalne tetive može biti od koristi pri rekonstrukciji teških oštećenja tetiva u kliničkim slučajevima.

**Ključne riječi:** presađivanje, tetiva, ksenograft, heterograft, fetus, govedo, kunić

---