

Klinika za ginekologiju i porodništvo Opće bolnice Sveti Duh, Sveti Duh 64, Zagreb

## THE EARLY HUMAN DEVELOPMENT: ADVANCES IN IT'S VISUALISATION

### RANI RAZVOJ ČOVJEKA: NAPRETKI U ISTRAŽIVANJU I SLIKOVNOM PRIKAZU

*Iva Laušin, Asim Kurjak*

*Review*

*Key words:* first trimester, sonoembriology, placenta, three dimensional ultrasound

**SUMMARY.** Clinical assessment of anatomy and physiology of placental and early embryonic development was improved in last couple of years by introducing high frequency vaginal transducers as well as three and four dimensional sonography. Usage of new techniques has produced more objective and accurate information of embryonal and early fetal development. For the first time parallel analyses of structural and functional parameters in the first 12 weeks of gestation become possible. This article deals with establishment of human life from ovum and sperm, though fertilisation, detailed histological development and the establishment of the placenta, and early human development visualized by 2- and 3-dimensional ultrasonography.

*Pregled*

*Ključne riječi:* prvo tromjesječje, sonoembriologija, posteljica, trodimenzionalni ultrazvuk

**SAŽETAK.** U zadnjih nekoliko godina klasično vrednovanje anatomije i fiziologije razvoja posteljice i ranog razvoja ploda uvelike je poboljšano uvođenjem vaginalnih sondi visoke frekvencije kao i trodimenzionalnog i četverodimenzionalnog ultrazvuka. Uvođenjem novih tehnika prikaza dobiveni su mnogi novi, objektivniji i točniji podaci prikaza embrionalnog i ranog fetalnog razvoja. Prvi je put moguće istovremeno istražiti strukturalne i funkcionalne parametre ranog razvoja čovjeka. U ovom članku prikazan je razvoj ljudskog života počevši od jajne stanice i spermija, preko oplodnje, detaljnog histološkog razvoja posteljice, kao i rani razvoj čovjeka prikazan koristeći dvodimenzionalnu i trodimenzionalnu ultrazvučnu tehnologiju.

## Introduction

Significant advances have been made in recent years in visualizing and analyzing the earliest human development. Since the introduction of high frequency transvaginal transducer, ultrasonographic visualization of embryos and fetuses in early stage has been remarkably progressed and sonoembriology has been established.<sup>1</sup>

Controverses appear every time when question about beginning of the human life is raised. Does human life begins when oocyte and spermatozoon come together, or when the baby is born, or when the person is accepted by the society? It is difficult to answer that question from the scientific point of view. Often, answer of that question is the matter of the religion. With the development of the science and newer and better technological approaches it is possible to detect and describe development of human life in its early stages. Development of ultrasound made it possible to detect product of conception just few days later after it reaches the uterus. But one early stage of human life was still not possible to visualise except using laparoscopy and salpingoscopy, and that is the time between ovulation, fertilization and implantation of the embryo. New technologies offer fascinating aspects of visualisation of embryonic differentiation and early pregnancy development. Recent introduction of three and four dimensional ultrasonography offer a noninvasive tool of diagnostics and assessment of embryological phenomenon.

To demonstrate embryos and early fetuses in utero, transvaginal 3D ultrasound with 12 MHz transducer enabled to produce highly sophisticated images demonstrating spinal tube of 5.5 mm long embryo, detailed intracranial structures, internal vascularity, facial appearance, craniofacial ossification, thoracoabdominal organs and skeletal structures.<sup>1</sup>

## Preconception

Introduction of the color Doppler made it possible to visualize blood vessels which enabled detailed examination of small vessels i. e. arteries supplying preovulatory follicle, corpus luteum or endometrium (*Fig. 1*). Perifollicular vascularisation can help in identification of follicles that are containing high-quality oocytes with a high probability of recuperating, fertilizing, cleaving and implanting. 3D ultrasound makes it also possible to visualize cumulus oophorus (*Fig. 2*).<sup>2</sup>

## Fertilization to implantation

Fertilization is the end of the complicated process of junction of gametes by entering one spermatozoon into the oocyte. The gametes, ovum and sperm, contain half of the number of the chromosomes (haploid) comparing to the number present in somatic cells (diploid) (*Fig. 3*). They obtain haploid number of cromosomes through the process of meiosis during the gametogenesis.<sup>3,4</sup> The

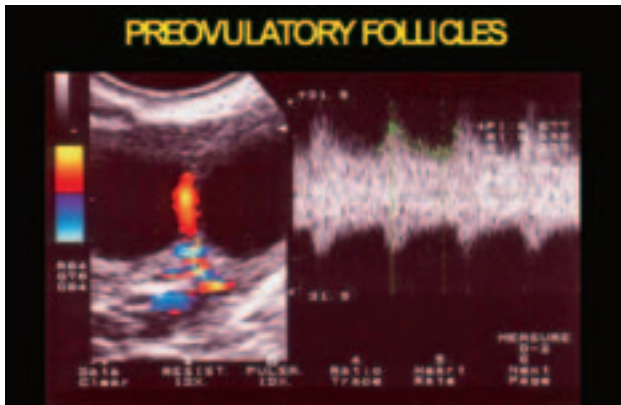


Figure 1. Color Doppler makes possible to depict the vascularisation of follicles helping to identify those follicles which contain high quality oocytes.

Slika 1. Primjena color Dopplera omogućuje prepoznavanje prokrvljenih folikula te na taj način pomaže prepoznavanju folikula koji sadrže kvalitetne jajne stanice.

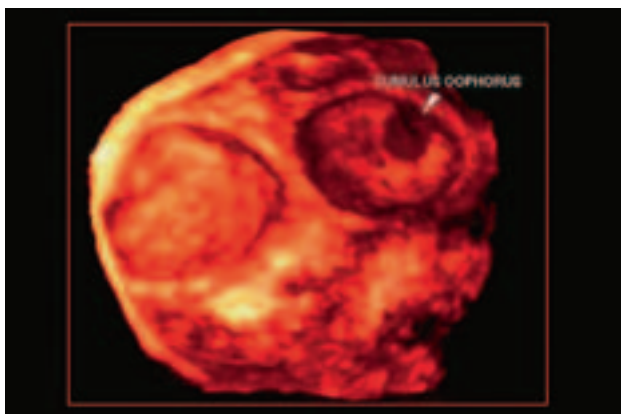


Figure 2. 3D US image showing ovarium containing two follicles; one empty, and other containing cumulus oophorus.

Slika 2. 3D ultrazvučni prikaz jajnika koji sadrži dva folikula; jedan je prazan, dok se unutar drugoga prepoznaje cumulus oophorus.

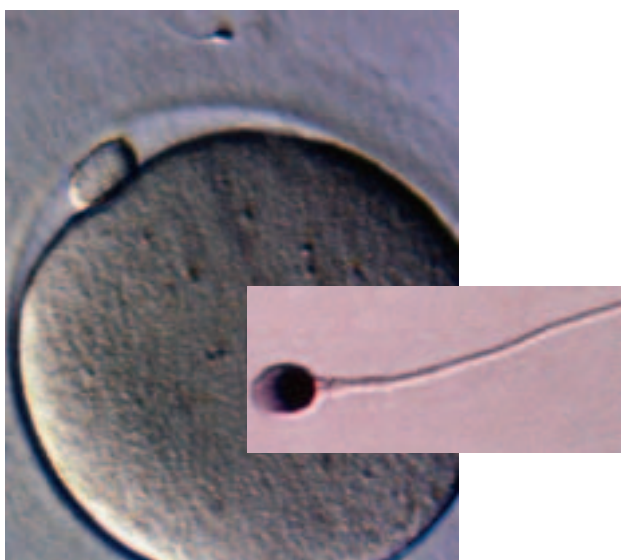


Figure 3. Phase contrast images of ovum and sperm.

Slika 3. Jajna stanica i spermij, prikaz elektronskim mikroskopom.

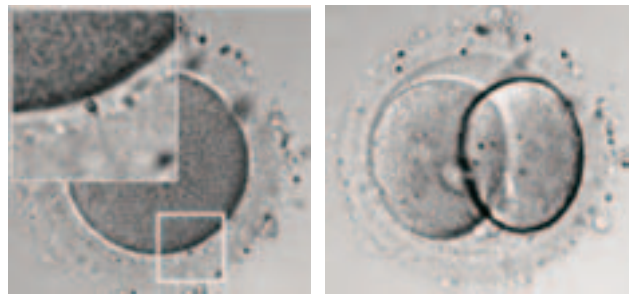


Figure 4. Phase contrast image of fertilisation and the first cleavage.

Slika 4. Oplodnja i prva dioba. Prikaz elektronskim mikroskopom.

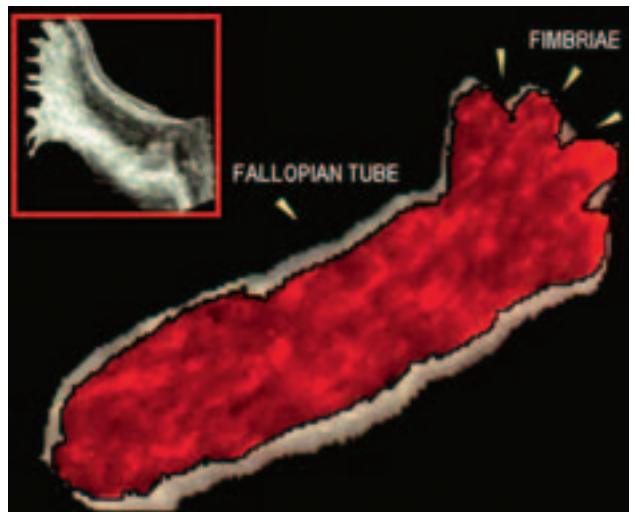


Figure 5. 3D power Doppler image showing fallopian tube. Power Doppler shows movement of the fluid going through the Fallopian tube confirming that it is possible to pass through it.

Slika 5. Prikaz jajovoda pomoću 3D osnaženog doplera. Prikazuje se kretanje tekućine kroz jajovod što potvrđuje da je jajovod prohodan.

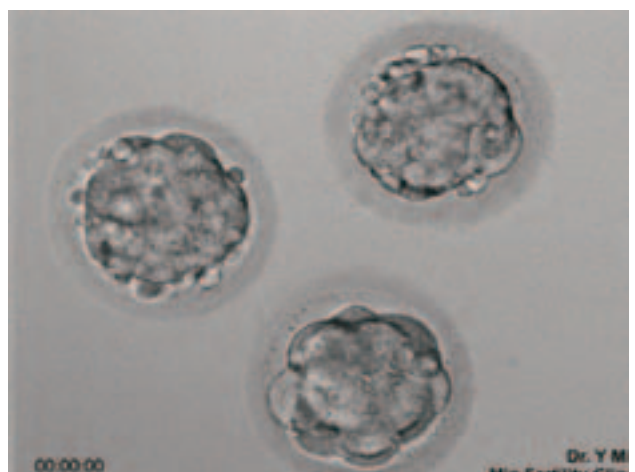


Figure 6. Phase contrast image of blastocyst formation.

Slika 6. Stvaranje blastociste. Prikaz elektronskim mikroskopom.

oocyte is approximately 120  $\mu\text{m}$  in diameter and has a thick membrane known as zona pellucida.

The spermatozoon moves using the flagellum or tail, and the total length of the spermatozoon including the

tail is 60  $\mu\text{m}$ .<sup>2</sup> Both oocyte and spermatozoon are highly specialized sex cells. Oocytes are produced in the ovary and expelled from it during the ovulation after which fimbriae of the fallopian tube sweep the oocyte into the ampulla where it can be fertilized. Sperms are produced in seminiferous tubules of testicles and after that are stored in the epididymis. When sperm enters the oocyte, the nucleus of the mature oocyte consist the female pronucleus and the head of the sperm separates from the tail and enlarges to become male pronucleus. Fertilization is complete when the pronuclei unite and the maternal and paternal chromosomes intermingle during metaphase of the first mitotic division of the zygote (*Fig. 4*). That cell is the primordium of the human being.<sup>5</sup> The unification if the pronuclei restores a haploid number of cromosomes and completes the fertilization. Therefore fertilization is a distinct moment when the diploid cell is formed and the development of an individual human begins.<sup>4</sup>

Transfer of the oocyte is facilitated by the changing endocrine milieu of the early luteal phase with its rising ratio of progesterone to oestrogen, which affects the oviductal and uterine musculature and relaxes the isthmic sphincter. It is probable, however, that the cilia, rather than the musculature are the primary active transporters of the conceptus. Thus, pharmacological inhibition of oviductal muscles do not prevent transfer of the conceptus. Furthermore, if a segment of oviduct is excised, turned around and replaced such that cilia beat away from the uterus, the conceptus moves to that part of the oviduct and then it stops (*Fig. 5*).<sup>3</sup>

Already few minutes after the ovulation oocyte is located in the ampullar part of the Fallopian tube. It is surrounded by the *zona pellucida*. On the surface of the *zona pellucida* there are few rows of the *granulosa cells* which make *corona radiata*. Peripheral of the *corona radiata* are left cells of *cumulus oophorus*. Often, these three units are called *oocyte-corona-cumulus complex*. Capability for the fertilization is limited: oocyte can be fertilized only 6 to 12 hours after the ovulation. Sperms are capable for fertilization 48 to 72 hours, until they are movable. Fertilization occurs in the ampullar part of the Fallopian tube.<sup>6</sup> The process of fertilization begins with conditioning of the spermatozoon in the male and female reproductive tracts. Thereafter, fertilization involves not only the egg itself but also the various investments that surround the egg in the time it is released from the ovary follicle. Fertilization is not an event, it is a complex biochemical process requiring a minimum of 24 hours to complete syngamy (forming of a diploid set of chromosomes). During that process there is no commingling of maternal and paternal chromosomes within a single nuclear membrane (pre-zygote); after this process, the paternal chromosome material is commingled (zygote). The most important activity of this new cell is the recognition of the new genome which presents the principal information centre for the development of the human being and for all its further activities.<sup>2</sup>

## Early development of the embryo, establishment of the placenta

After syngamy, the zygote undergoes mitotic cell division as it moves down the Fallopian tube towards the uterus. Shortly after gene activation conceptus shows marked quantitative increase in its biosynthetic capacity. Net synthesis of mRNA and protein increase, transport of amino acids and nucleotids into the cells rises and changes occur in the synthetic patterns of phospholipids and cholesterol. The growth and methabolic activity of the pre-implantation conceptus in vitro has been shown to be stimulated by a number of growth factors which vary between species and include: insuline like growth factors (IGF-1 and 2), transforming growth factors alpha (TGF-alpha) and beta (TGF beta 1 and 2), epidermal growth factor (EGF), platelet-derived factor A (PDGF-A). Receptors of those factors have been identified on human conceptus. Synthesis of many of those factors has been detected in early conceptus itself or in maternal tissues, therefore, it is reasonable to conclude that these factors act as *autocrine* or *paracrine* agents which promote the early development.<sup>3</sup>

A series of mitotic divisions lead to the development of the pre-embryo. The newly divided cells are called blastomeres. From 1 to 3 days after syngamy, there is a division into 2 cells and then 4 cells. Blastomeres form cellular aggregats of distinct, totipotent, undifferentiated cells that retain the capacity to develop independently into normal pre-embryos.<sup>2</sup> After every division blastomeres become half of their previous size keeping total size the same as in the beginning when it was just one cell. All up to 8 cell phase blastomeres are cluster of cells inside the *zona pellucida*. But, after the third division they lose their round shape and they impact one to the another making compact round cluster of cells which are tightly connected by tight junctions. With that change, which is called *compaction*, cells from the outside start to differentiate from those inside. Third day after the fertilization cells of the compact embryo divide again and *morula* occurs. Morula stage is reached when about 12 to 16 cells are present, outer part from which trophoblast will appear, and inner cells from which embryo will appear.<sup>7</sup>

In the time when morula enters the uterine cavity blastocyst appears (*Fig. 6*). A blastocyst is an embryo which has developed to the point of having 2 different cell components and a fluid cavity. Inner part of the cells is then called embryoblast and it is located on the one side of the blastocyst. Outer part of cells is trophoblast and it makes epithelial surface of the blastocyst.<sup>7</sup> The expansion of the blastocele is stimulated by growth factors EGF and TGF-alpha.<sup>3</sup> Throughout the development, from fertilization to the blastocyst, conceptus remains enclosed in *zona pellucida*. The *zona pellucida* is the extracellular matrix that plays important roles in sperm-egg interaction. The *zona pellucida* is composed of three major glycoproteins that exhibit heterogeneity due to extensive post-translational modifications includ-



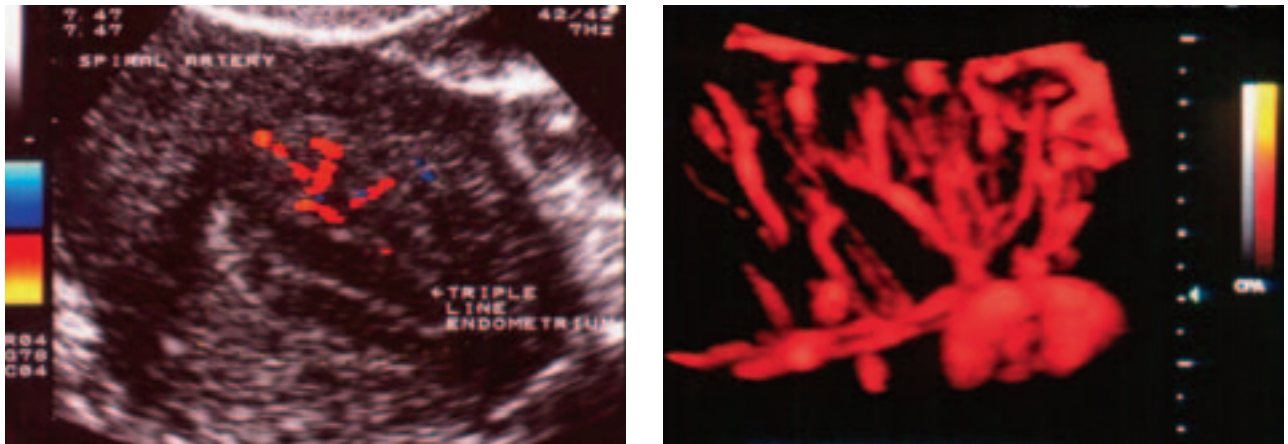


Figure 7. 2D and 3D power Doppler image showing spiral arteries supplying triple-line endometrium, important for future implantation.  
Slika 7. Pomoću 2D i 3D osnaženog doplera prikazane su spiralne arterije koje opskrbljuju trolinijski endometrij, važno za buduću implantaciju.

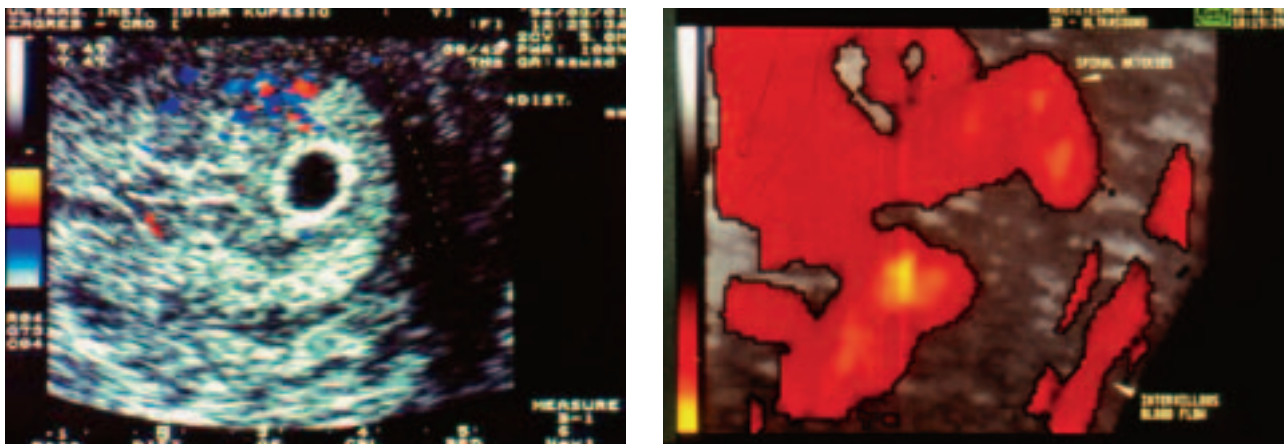


Figure 8. Decidual response to implanted pregnancy. The increase of permeability and growth of new capillaries is present.  
Slika 8. Decidualna reakcija na implantirani produkt koncepcije. Može se vidjeti razvoj novih krvnih žila i povećana propusnost.

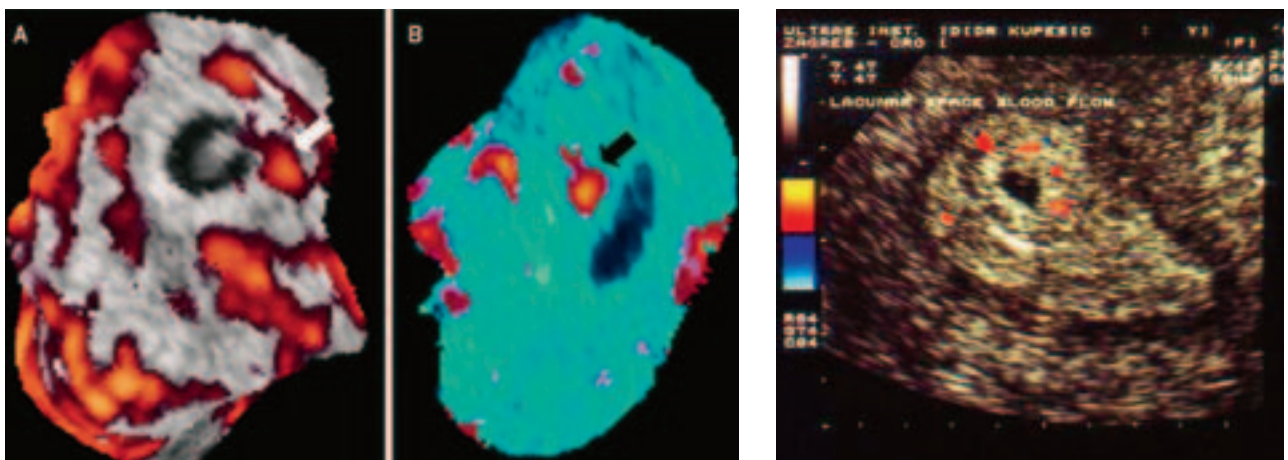
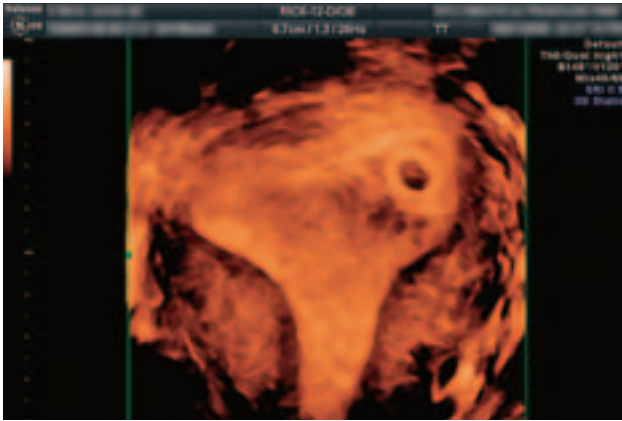


Figure 9. 2D and 3D power Doppler image of five weeks of the pregnancy. Small gestation sac is seen, surrounded with developing vascularisation.  
Slika 9. 2D i 3D osnaženi doplerski prikaz trudnoće od 5 tjedana. Prikazuje se malena gestacijska vreća okružena novostvorenom vaskularizacijom.

ing glycosylation and sulphation. Studies have now shown that the proteins of the ZP are expressed in a stage specific manner and that there is increasing evidence that zona pellucida proteins are expressed by both

granulosa cells and the oocyte and may play a role in granulosa cell differentiation.<sup>8</sup> It prevents blastomeres of the conceptus from falling apart during early cleavage period prior to compaction. If conceptus does divide



into two distinct groups of cells at this time, monozygotic twins result. Secondly it prevents two genetically distinct conceptuses forms ticking together to make a single chimeric conceptus.<sup>3</sup> Headched blastocyst is bathed in uterine secretions from which it draws the oxygen and methabolic substrates important for growth and survival. There is the limit of the size that free living conceptus can attain before such exchanges become inadequate. Before that critical stage is reached, concep-tus grows its own blood vascular system.

Figure 10. 3D image od gestational sac at five weeks of pregnancy seen in a thickened endometrium.

Slika 10. 3D prikaz gestacijske vrećice unutar zadebljala endometrija, 5 tjedana trudnoće.

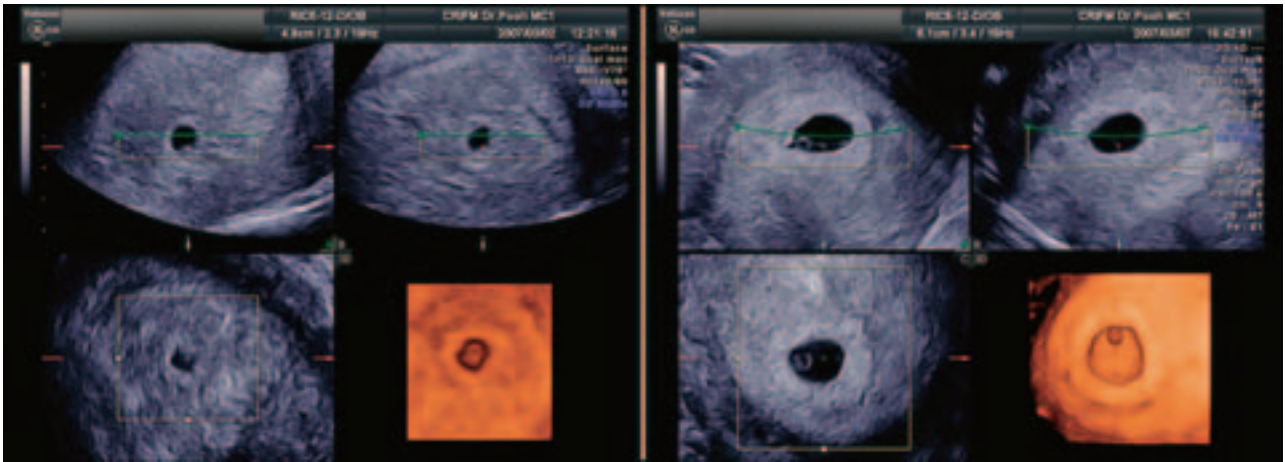


Figure 11. 3D image of five weeks old pregnancy. New softwares make it possible to measure the growing volume of gestational sac.

Slika 11. 3D prikaz trudnoće od 5 tjedana. Novi računalni programi omogućuju mjerenje volumena gestacijske vreće.

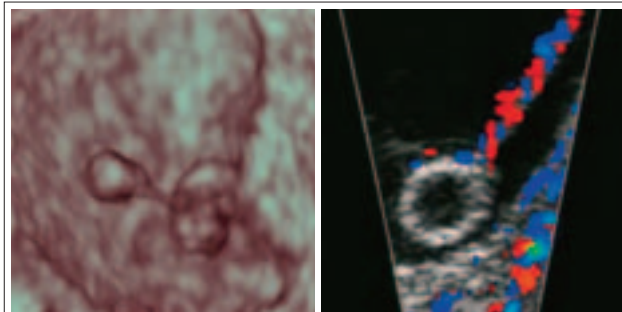


Figure 12. 3D image of embryo and yolk sac on the left. Right image showing vascularisation of the yolk sac. At the tenth weeks it loses its function and begins to degenerate, losing its vascularity.

Slika 12. Na lijevoj strani nalazi se 3D prikaz embrija i žumančane vreće. Desno je prikaz prokrvljenosti žumančane vreće. Oko 9. tjedna trudnoće ona gubi funkciju i počinje degenerirati te se gubi njezina prokrvljenost.

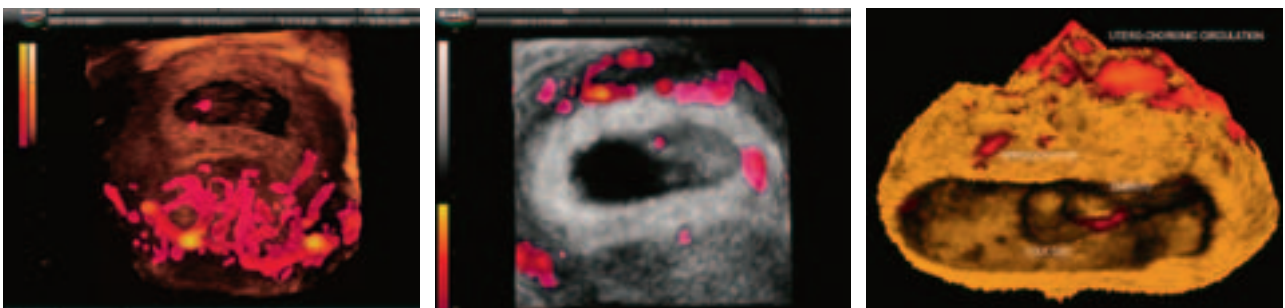


Figure 13. 3 dimensional image of the developing intervillous circulation in the maternal site of placenta at fifth week of gestation. Doppler shows intense vascular activity surrounding the chorionic shell.

Slika 13. 3D prikaz razvoja intervilozne cirkulacije na majčinoj strani placente u 5. tjednu trudnoće. Dopler prikazuje pojačanu vaskularnu aktivnost koja okružuje korion.



When blastocyst leaves zona pellucida, it makes it possible for blastocyst to implant into the endometrium. Once entering the uterus, the conceptus engages in an elaborate interaction with the mother in which several messages are transmitted in both directions. Conceptus establishes physical and nutritional contact with the maternal endometrium at the implantation. Failure to do so would deprive the conceptus as essential nutritional substrates and arrest in growth. Secondly, conceptus signals its presence to maternal pituitary-ovarian axis; somehow it must convert the whole female reproductive system from cyclic pattern to a noncyclic in which progesterone dominates. Different changes in endometrium have been studied with goal to predict successful implantation. In the study of Zohav et al.<sup>9</sup> they have shown that the dynamic changes in endometrial volume and thickness between day of embryo transfer and two weeks later may predict IVF treatment outcome.

A good blood supply towards the endometrium is usually considered to be an essential requirement for implantation and therefore assessment of endometrial blood flow in IVF treatment has attracted a lot of attention in recent years.<sup>10</sup> Doppler study of uterine arteries does not reflect the actual blood flow to the endometrium. Endometrial and subendometrial blood flows can be more objectively and reliably measured with three-dimensional power Doppler ultrasound. However, conflicting results are reported with regard to their role in the prediction of pregnancy in IVF treatment.<sup>10</sup> Endometrial development is largely dependent on a good blood supply to the basal endometrium. The study of Ng et al.<sup>11</sup> evaluated the endometrial and subendometrial vascularity in patients with thin ( $\leq 8$  mm) endometrium and in those with low volume ( $\leq 2.5$  mL) endometrium. It was found that 3D power Doppler flow indices of the endometrial and subendometrial regions were significantly lower in patients with low volume endometrium compared with those with normal volume endometrium. Endometrial and subendometrial vascularity measured by 3D power Doppler ultrasound was significantly lower in patients with low volume endometrium, but not in those with thin endometrium.

In the time when blastocyst is prepared for implantation, in the middle of the luteal phase of cycle, endometrium is about 10 to 14 mm thick. It is prepared for the implantation by various factors: EGF, IGF-I, and local paracrine and autocrine factors. From day 16 to 22 receptivity of the endometrium is highest, that time is called »implantation window«. In that time pinopodes which helps blastocyst to implant are most numbered. When blastocyst leaves zona pellucida, it makes it possible for conceptus to make contact with decidual endometrium. Implantation consists of 3 phases: apposition, adhesion and invasion. Apposition and adhesion are assisted with adhesive molecules of endometrium like laminin, fibronectin, and receptors like integrins. Conceptus produces signals which make change in mother's bloodflow. It produces early pregnancy factor (EPF) which has immunosuppressive effect. By the beginning of

the implantation proteases and matrix metalloproteinases are activated. Conceptus which is close to the surface of the endometrium begins its invasion. Enzymes of the trophoblast invade mother's circulation and build hematochorial placentation.<sup>6</sup>

In some species implantation is invasive (humans) in difference to some where it is non-invasive. Invasive conceptus tends to be smaller at attachment and only a few trophoblast cells are involved in making contact with the maternal endometrium. Within the few hours increased vascular permeability is observed. This is associated with oedema and a progressive sprouting and ingrowth of capillaries. The stromal reaction is particularly marked in primates where it is called *primary decidualization reaction*. The uterine glandular and decidual tissue adjacent to the invading trophoblast of the conceptus is destroyed. It releases primary metabolic substrates: lipids, carbohydrates, nucleic acids and proteins which are taken by the growing conceptus. Decidual tissue thus functions like a large yolk reservoir.<sup>3</sup> The invasiveness of the conceptus is influenced by the effectiveness of the decidual response. A critical oestrogen-induced change is the endometrium that occurs in the attachment process involves leukaemia inhibitory factor (LIF). It is produced by the cells of the endometrial glands under the influence of oestrogen. Receptors for LIF also appear in both the epithelium and stroma of the endometrium around the time of implantation. Seems like LIF promotes endometrial receptivity to attachment and/or subsequent decidualization.<sup>3</sup> The earliest localized uterine response to a mouse blastocyst is appearance of mRNA which codes heparin-binding EGF-like growth factor (HB-EGF). This response occurs only in the cells of the endometrium adjacent to the blastocyst. Significantly, trophoblast cells express both EGF receptors and heparan sulphate proteoglycans (HSPG) providing double binding sites for HB-EGF. The invasiveness of the trophoblast depends of the expression and regulation of the different proteolytic enzymes. TGF-beta promotes decidualization and controls trophoblastic invasion. Histamine and prostaglandins are involved in the stromal response: inhibition of either one of them reduces the decidualization.

An important feature of decidual response is increase in vascular permeability and growth of new capillaries (*angiogenesis*) (Fig. 8).

At the beginning of the fifth week, embryonic echo and yolk sac are still not visible. Spiral arteries open up in the early intervillous space. Increased blood flow that surrounds the gestational sac is a direct consequence of the dilatation of spiral arteries by the trophoblast proteolytic activity. Full complexity of vascular network of spiral arteries and intervillous flow under the placenta can be assessed and depicted using the 3D power Doppler.

A small intradecidual gestation sac can be seen by transvaginal sonography between 32 and 34 days (Fig. 9,10). It can be visualised from the middle of the fifth week of amenorrhea as a small anechoic structure placed inside one of endometrium leaves. Three dimensional sonography enables precise measurement of the exponen-

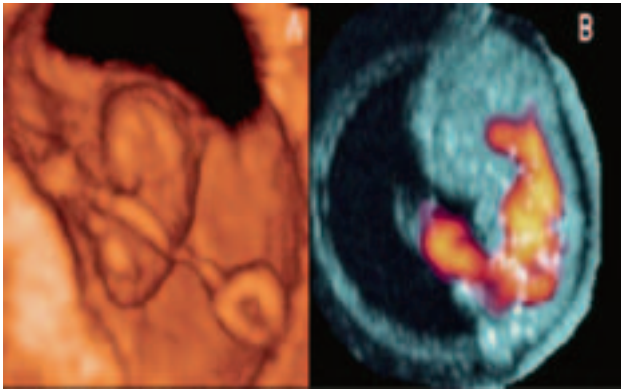


Figure 14. 3D Power Doppler image of fetal and placental circulation.  
Slika 14. 3D osnaženi dopler fetalne i placentarne cirkulacije.

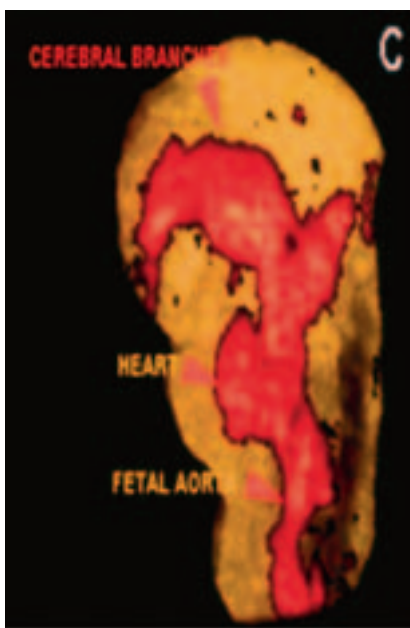


Figure 15. Paralelly with growing of embryo its vascularity branches. At eight weeks of gestation vascularity in embryos brain and heart can be depicted.  
Slika 15. Paralelno s rastom embrija razvija se i grana njegova cirkulacija. S 8 tjedana trudnoće može se prikazati prokrvljenost unutar mozga embrija.

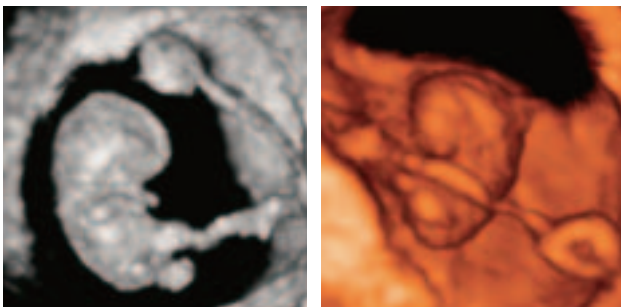


Figure 16. Seven to eight weeks of pregnancy, 3d image showing bulky head almost the same size as the rest of the body. Yolk sac is clearly visualised as well as the first signs of development of embryos limbs.  
Slika 16. 3D prikaz od 7 na 8 tjedana trudnoće. Prikazuje se glava koja veličinom otprilike odgovara veličini tijela embrija. Jasnno se prikazuje žumanjčana vreća kao i početak razvoja udova embrija.

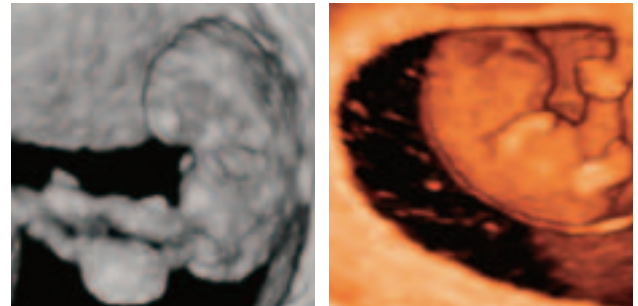


Figure 17. In the eighth week of pregnancy face is becoming apparent.  
Slika 17. U 8. tjednu trudnoće počinje se prepoznavati lice.

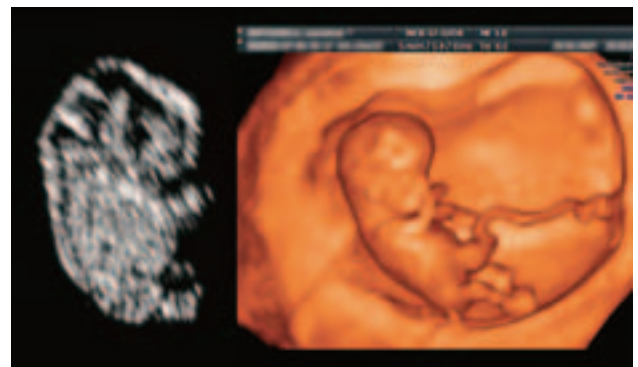

Figure 18. Nine weeks old fetus. Image showing developing intracranial structures. 3D image shows developing fetal face details, legs, arms and fists.  
Slika 18. Fetus od 9 tjedana. Prikaz razvoja intrakranijalnih struktura. 3D prikaz razvoja detalja lica, ruku, nogu i šaka.

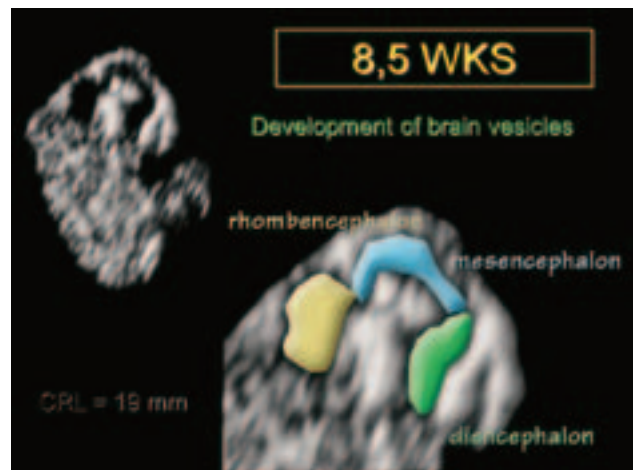


Figure 19. Eight weeks of pregnancy showing the development of the brain. In early embryonic period it appears as cystic formation. First, rhombencephalon is seen, followed with the development of mesencephalon and diencephalon.  
Slika 19. Prikaz razvoja fetalnog mozga s 8 tjedana trudnoće. U ranom embrionalnom periodu prikazuje se kao cistična formacija. Prvo se prepoznaje romboencefalona koji prati razvoj mezencefalona i diencefalona.

tially expanding gestational sac volume during the first trimester.

The secondary yolk sac is the earliest extraembryonic structure normally seen within the gestational sac, be-

ginning at the 5th gestational week (*Fig. 11*). Yolk sac volume increases from week 5 to 10. When it reaches its maximum at the week 10 it already starts to degenerate, which can be seen by the significant reduction in visualization rates of the yolk sac vascularity. The embryonic heart begins beating on about day 22 or 23, accepting blood components from the yolk sac and pushing the blood into the circulation (*Fig. 12*). The embryonic blood begins circulating at the end of the fifth week of the development.

The start of embryo-chorionic circulation changes the source of nourishment to all intraembryonic tissues. Development of the embryo becomes dependent on the circulation of embryonic blood. In the embryo, there are 3 distinct blood vasculary systems: vitelline circulation (from yolk sac to embryo), intraembryonic circulation and feto-placental circulation. It is possible to visualize and assess them virtually from conception.

## Embryonic and fetal circulation

### Five weeks

At 5 weeks it is possible to obtain 3 dimensional image of the developing intervillous circulation in the maternal site of placenta. Doppler shows intense vascular activity surrounding the chorionic shell starting from the first sonographic evidence of the developing pregnancy during the fifth week of gestation (*Figs. 13, 14*). At 7 weeks 3D power Doppler images depict aortic and umbilical blood flow (*Fig. 15*). The initial branches of the umbilical vessels are visible at the placental umbilical insertion.

### Six Weeks

Six weeks embryo is visualized as a rounded bulky head and a thinner body. The head is prominent due to the development of the midbrain (*Fig. 16*).<sup>12</sup>

### Seven weeks

At the seventh week development of the rombencephalon takes place. With the use of the planar mode developing vesicles of the brain can be depicted as anechoic structures inside of the head. The biggest, and usually the only visible, is rombencephalon placed on the top of the head. In the seventh week limbs can be visualized laterally to the body while the head is strongly flexed anterior.<sup>12</sup>

### Eight weeks

During the eight week the shape of the face is becoming apparent but the flexion of the cranial pole makes it difficult to view the face entirely (*Figs. 17, 18*). The vertex is positioned over the position of the midbrain and the expansion of the ventricular system appears (lateral, third and midbrain ventricles). The ventricular cavities are characteristically cystic, particularly the rombencephalon. This should not be confused with an early diagnosis of Dandy Walker cyst (*Figs. 19, 20*).<sup>12</sup> Insertion of the umbilical cord is visible on the anterior abdominal wall (*Fig. 21*).

### Nine and ten weeks

In the developing brain lateral ventricles containing hyperechoic choroid plexuses can be depicted (*Fig. 22*). The head is clearly divided from the body by the neck. Dorsal column, the early spine can be examined the whole length (*Fig. 23*). The arms with elbows and legs with knees are visible. Blaas and colleagues reported successful detection of three cases of lumbosacral myelomeningocele.<sup>13</sup>

Internal vascularity in an early fetus can be visualized by 3D power Doppler imaging. This enables research of longitudinal changes in embryonic and early uteroplacental circulation. Premature internal vascularity at 9 weeks of gestation can be depicted.<sup>1</sup> By using recent 3D power Doppler technology, circulatory orientation can be clearly obtained and the common carotid arteries, internal carotid arteries, circle of Willis and middle cerebral arteries are well visualized (*Fig. 24*).<sup>1</sup>

The umbilical artery is characterized by systolic pulsations with absent end-diastolic velocities. Between 11th and 14th weeks of gestation diastolic velocities gradually emerge (*Fig. 25*).<sup>12,14</sup>

From maternal side of placenta 3D imaging of developing intervillous circulation during the first trimester of pregnancy is possible. 3D power Doppler reveals intensive vascular activity surrounding the chorionic shell starting from the first sonographic evidence during the fifth weeks of gestation.<sup>12,15</sup>

## New possibilities for studying embryonic and fetal movements and behavior

The latest development of 3D and 4D sonography enables precise study of embryonic and fetal activity and behavior. With 4D ultrasound movements of the head, body, and all four limbs the extremities can be seen simultaneously in three dimensions. Therefore, the earliest phases of the human anatomical and motor development can be visualized and studied simultaneously. Neurologic development (ie. early fetal motor activity and behavior) needs to be re-evaluated by this new technique.<sup>16,17</sup> Recently, our group studied the development of the complexity of spontaneous embryonic and fetal movements and produced the first scoring system for the assessment of fetal neurobehavior.<sup>16–19</sup> With advancing gestational age, the movements become more complex. The increase in the number of axodendritic and axosomatic synapses between 8 and 10 weeks and between 12 and 15 weeks correlates with the periods of fetal movement differentiation and with the onset of general movements and complex activity patterns such as swallowing, stretching, and yawning, seen easily by 4D technique. At 7 to 8 weeks of pregnancy, gross body movements appear. They consist of changing the position of head toward the body. At 9 to 10 weeks of pregnancy, limb movements appear. They are characterized by the changing of position of extremities towards the body without the extension or flexion in elbow and knee. At 10 to 12 weeks of pregnancy, complex limb movements appear. This consists of changes in position



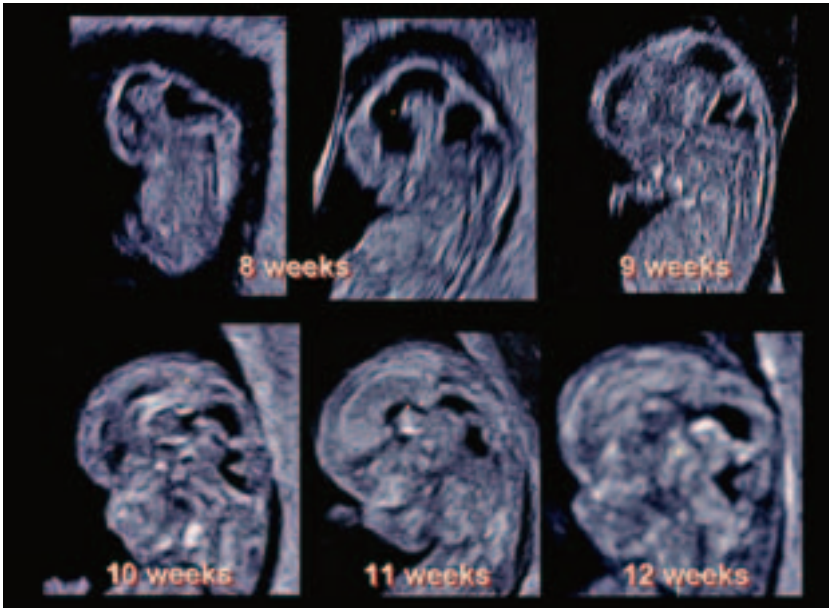


Figure 20. Developing brain in early pregnancy. Fetal central nervous system changes in size and appearance from early premature structure into late mature structure with gyral formation.  
 Slika 20. Razvoj mozga u ranoj trudnoći. Fetalni živčani sustav formiranjem girusa mijenja se veličinom i oblikom iz nezrelih struktura prema zrelijim strukturama.

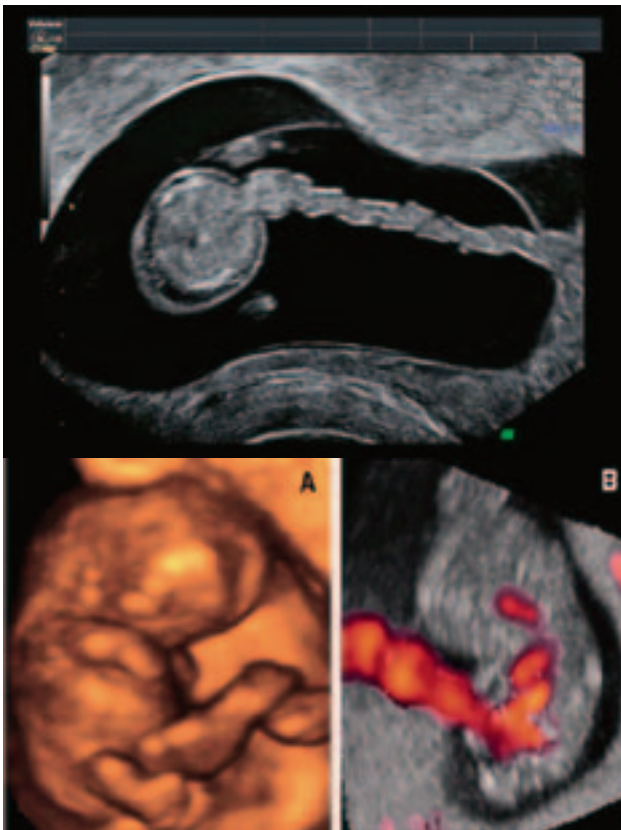


Figure 21. Visualisation of the umbilical cord and its vascularisation using 2D, 3D and 3D power Doppler technique.  
 Slika 21. 2D, 3D i 3D osnaženi dopler. Prikaz pupkovine i njezine vaskularizacije.

of the limb segments toward each other, such as extension and flexion in elbow and knee (Fig. 26).

At 12 to 15 weeks of pregnancy, swallowing, stretching, and yawning activities appear. It is now feasible to study by 4D ultrasound a full range of facial expression,

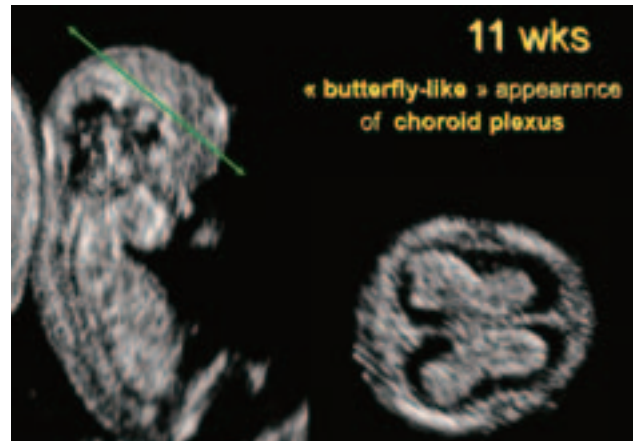

Figure 22. Butterfly shaped choroid plexus- characteristic image at 11 weeks of pregnancy.  
 Slika 22. Plexus choroideus u obliku leptira – karakterističan izgled za 11 tjedana trudnoće.

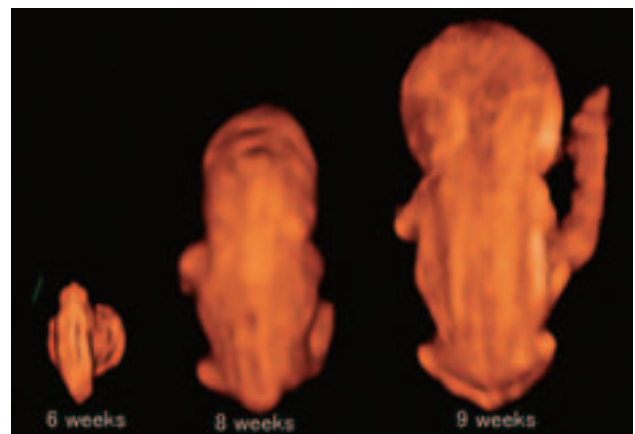


Figure 23. In the ninth week of pregnancy ears spine can be examined in its whole length.  
 Slika 23. U 9 tjednu trudnoće kralježnica se može prikazati čitavom dužinom.

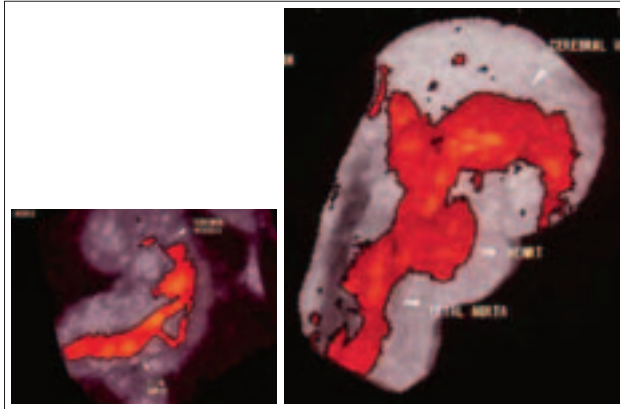


Figure 24. By using recent 3D power Doppler technology, circulatory orientation can be clearly obtained and the common carotid arteries, internal carotid arteries, cerebral arteries visualized. In the eighth weeks of gestation (left image) cerebral vessels are for the first time depicted. Furthermore, vascular anatomy can be seen in increasing details. Note the abdominal aorta with umbilical artery branching at the caudal pole. Umbilical vein can be followed from the abdominal umbilical insertion through the fetal liver and ending below the heart.

Slika 24. Koristeći 3D osnaženi doplerski prikaz može se prikazati cirkulacija fetusa. Prikazane su zajedničke karotidne, unutarnja karotidna i cerebralne arterije. U osmom tjednu trudnoće (slika lijevo) moždane krvne žile mogu se prvi puta vidjeti. Anatomija cirkulacije može se prikazati detaljnije. Na kaudalnom kraju prikazuje se abdominalna aorta i grananje umbilikalne arterije. Umbilikalna vena prati se od insercije preko fetalne jetre do ispod srca.

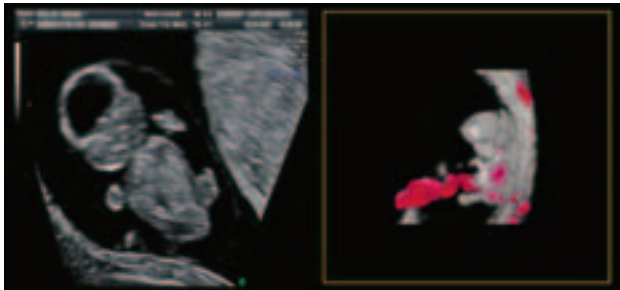


Figure 25. 2D and 3D power Doppler image of nine weeks old fetus. Blood flow through umbilical cord and fetal heart is visualised.

Slika 25. 2D i 3D osnaženi doplerski prikaz fetusa od 9 tjedana. Prikazan je protok krvi kroz pupkovinu i fetalno srce.

including smiling, crying, and eyelid movement. It is hoped that new 4D techniques will help us to better understand the somatic and motoric development of the early embryo. It will also enable the reliable study of fetal and parental behavior.

### Reproductive failure in humans

It seems that human beings suffer from a high risk of reproductive failure. It has been estimated that 15–20% of recognized human pregnancies end in spontaneous abortion, mostly during the first trimester.<sup>20</sup> Whittaker et al. reported that approximately 8% of human pregnancies end in such early stage of gestation that the par-

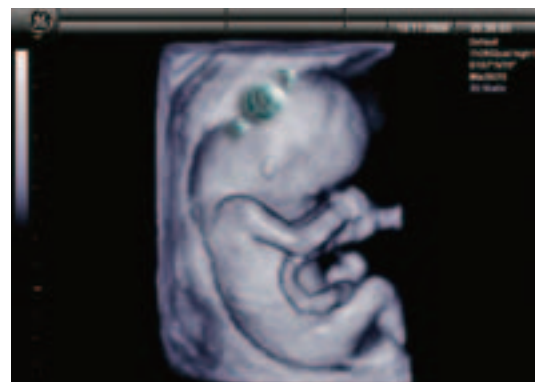
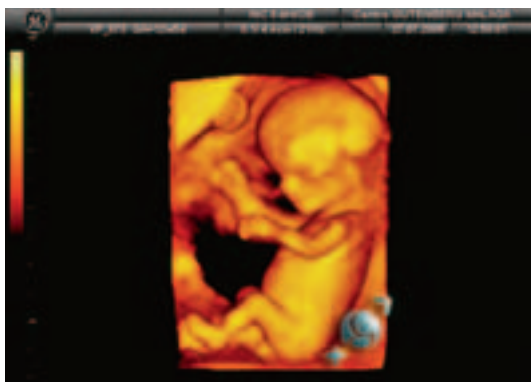
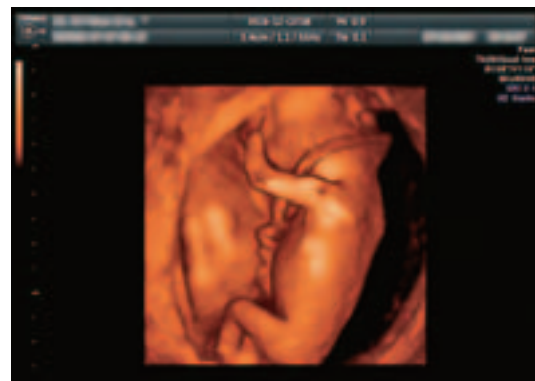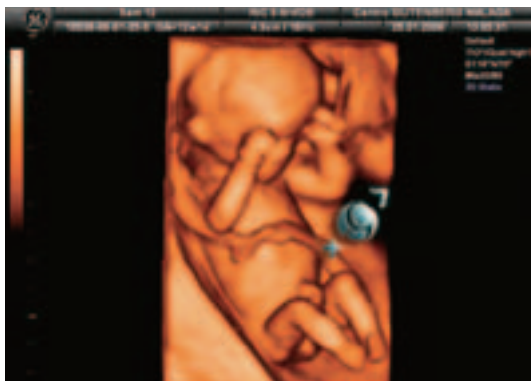Figure 26. From 10 to 12 weeks of pregnancy complex body movements appear. Movements of limbs toward the head, flexion and extension and elbows and knees can be depicted.

Slika 26. Između 10 i 12 tjedana trudnoće pojavljuju se složeni pokreti tijela fetusa. Mogu se prikazati pokreti udova prema glavi te fleksija i ekstenzija laktova i ramena.

ents were unaware that conception has occurred.<sup>20</sup> The prevalency of abnormalities is higher in prenatal than postnatal human populations.<sup>21,22</sup> About a half of spontaneously aborted embryos are associated with structural or chromosomal abnormalities.<sup>21,22</sup> Approximately 3% of newborn infants have one or more congenital abnormalities: including malformations, chromosomal abnormalities and functional disturbances.<sup>24</sup>

Direct observations of preimplantation and postimplantation of human embryos has showed that one third of them are morphologically abnormal.<sup>4,25</sup> That support the assumption that abnormal development is not uncommon and that many of these embryos end as a spontaneous abortion in an early pregnancy. It is likely that the reproductive loss and the appearance of abnormal conceptuses are underestimated because many fertilized ova are lost in early gestation and more than 90% of embryos with severe malformations are spontaneously eliminated without clinical detection.<sup>4</sup>

## Conclusion

Clinical assessment of the anatomy and physiology of placental and early human development rely heavily on new 3D and 4D sonographic techniques. They are one of the most promising forms of non-invasive diagnostic and embryological phenomenon which now can be routinely recorded with outstanding clarity. Different approaches and ways of visualization of early human development accelerates the understanding of a big and important field of early human development.

## References

1. Pooh RK, Pooh K, Nakagawa Y, Nishida S, Ohno Y. Clinical application of three-dimensional ultrasound in fetal brain assessment. *Croat Med J* 2000;41:245–51.
2. Kurjak A. The beginning of human life and its modern scientific approach. *Clin Perinatol* 2003;30:27–44.
3. Johnson MJ. Implantation and the establishment of the placenta. In: Johnson MJ, Everitt BJ. *Essential reproduction*. Oxford: Blackwell science, 1999:173–93.
4. Shiota K. Early human development: An overview. In: Kurjak A, Chervenak FA. *Controversies on the beginning of the human life*. New Delhi: Jaypee Brothers Medical Publishers, 2008:151–66.
5. Moore KL. The first two weeks of human development. In: Moore KL, Persaud TVN, Shiota K. *Color atlas of clinical embryology*. Philadelphia: WB Company, 2000:1–12.
6. Suchanek E, Simunic V. Gamete, oplodnja i rani razvoj zametka. In: Simunic V. *Ginekologija*. Zagreb: Naknada Ljevak, 2001:61–77.
7. Sadler TW. Od ovulacije do implantacije. In: Sadler TW. *Langmanova medicinska embriologija*. Zagreb: Školska knjiga 1996:23–41.
8. Prasada SV, Skinnera M, Carinoa C et al. Structure and function of the proteins of the mammalian zona pellucida. *Cells Tissues Organs* 2000;166:148–64.

9. Zohav E, Bar-Hava I, Meltzer S et al. Early endometrial changes following successful implantation: 2- and 3-dimensional ultrasound study. *Clin Exp Obstet Gynecol* 2008;35:255–6.

10. Ng EH, Chan CC, Tang OS et al. The role of endometrial blood flow measured by three-dimensional power Doppler ultrasound in the prediction of pregnancy during in vitro fertilization treatment. *Eur J Obstet Gynecol Reprod Biol* 2007;135:8–16.

11. Ng EH, Yeung WS, Ho PC. Endometrial and subendometrial vascularity are significantly lower in patients with endometrial volume 2.5 ml or less. *Reprod Biomed Online* 2009;18:262–8.

12. Kurjak A, Pooh RK, Merce LT, Carrera JM, Salihagic-Kadic A, Andonotopo W. Structural and functional early human development assessed by three-dimensional and four-dimensional sonography. *Fertil Steril* 2005;84:1285–99.

13. Blaas HG, Eik-Nes SH, Isaksen CV. The detection of spina bifida before 10 gestational weeks using two- and three-dimensional ultrasound. *Ultrasound Obstet Gynecol* 2000;16:20–9.

14. Pretorius DH, Nelson TR, Baergen RN, Pai E, Cantrell C. Imaging of placental vasculature using three-dimensional ultrasound and color power Doppler: a preliminary study. *Ultrasound Obstet Gynecol* 1998;12:45–9.

15. Kurjak A, Kupesic S, Hafner T. Intervillous blood flow in normal and abnormal early pregnancy. *Croat Med J* 1998;39:10–4.

16. de Vries JI, Visser GH, Prechtel HF. The emergence of fetal behaviour: I. Qualitative aspects. *Early Hum Dev* 1985;12:99–120.

17. Kurjak A, Azumendi G, Andonotopo W, Salihagic-Kadic A. Three- and four-dimensional ultrasonography for the structural and functional evaluation of the fetal face. *Am J Obstet Gynecol* 2007;196:16–28.

18. Kurjak A, Vecek N, Hafner T et al. Prenatal diagnosis: what does four-dimensional ultrasound add? *J Perinat Med* 2002;30:57–62.

19. Kurjak A, Miskovic B, Stanojevic M et al. New scoring system for fetal neurobehavior assessed by three- and four-dimensional sonography. *J Perinat Med* 2008;36:73–81.

20. Warburton D, Fraser FC. Spontaneous abortion risks in man: Data from reproductive histories collected in a medical genetics unit. *Am J Hum Genet.* 1964;16:1–25.

21. Fantel AG, Shepard TH, Vadhaim-Roch C, Stephens TD, Coleman C. Embryonic and fetal phenotypes: Prevalence and other associated factors in a large study of spontaneous abortion. In: Porter IH, Hook EB. *Human Embryonic and Fetal Death*. New York: Academic Press, 1980:71–87.

22. Poland BJ, Miller JR, Harris M, Livingston J. Spontaneous abortion. A study of 1961 women and their conceptuses. *Acta Obstet Gynecol Scand* 1982;102:1–32.

23. Hook EB. Prevalence of chromosome abnormalities during human gestation and implications for studies of environmental mutagens. *Lancet* 1982;2:169–72.

24. Holmes LB. Congenital Malformations. In: Vaughan VC III, McKay RJ, Behrman RE. *Nelson's Textbook of Pediatrics*. Philadelphia, Saunders, 1979:370–1.

25. Hertig AT, Rock J, Adams EC. A description of 34 human ova within the first 17 days of development. *Am J Anat* 1956;98:435–93.

*Paper received: 4. 05. 2009.; accepted: 3. 06. 2009.*

*Address for correspondence: Iva Laušin, dr. med., Klinika za ginekologiju i porodništvo OB Sveti Duh, Sveti Duh 64, 10000 Zagreb*