

Department of Obstetrics and Gynecology, University Hospital Zagreb,\*  
Department of Obstetrics and Gynecology, General Hospital Nova Gradiška,\*\*  
Outpatient Gynecologic Office, Osijek\*\*\*

## **TROCAR SCAR ENDOMETRIOSIS** **ENDOMETRIOZA U OŽILJKU TROAKARA**

*Mihajlo Strelec\*, Romana Dmitrović\*\*, Siniša Matković\*\*\**

*Case report*

*Key words:* laparoscopy, interstitial endometriosis, trocar site implantation

**SUMMARY.** A 24-year-old patient had an 8-month history of intense cyclic pain at the suprapubic trocar scar region. Two years earlier, the patient underwent operative laparoscopy during which endometrioma of the left ovary was removed. We present a case of endometriosis at a suprapubic trocar scar, which, to our knowledge, has previously been described in literature only once. Another rarity involved in this case is that the scar endometriosis developed after the removal of ovarian endometrioma. The most probable source of the trocar scar endometriosis is remnants of the tissue that remained in the abdominal wall during extraction of endometrioma.

*Prikaz bolesnice*

*Ključne riječi:* laparoskopija, intersticijalna endometrioza, implantat na mjestu troakara

**SAŽETAK.** Prikazujemo slučaj endometrioze koja se razvila u ožiljku insercije 10-milimetarskog suprapubičnog troakara. Takav slučaj je, prema našim saznanjima, dosad u literaturi opisan samo jednom. Dodatna rijetkost vezana uz ovaj prikaz slučaja jest da se endometrioza u ožiljku razvila nakon odstranjenja ovarijskog endometrioma. Vjerojatni mehanizam nastanka je vitalno endometriotično tkivo zaostalo u trbušnoj stijenci pri ekstrakciji endometrioma.

We present a case of endometriosis at a 10 mm suprapubic trocar scar, which, to our knowledge, has previously been described in literature only once. Another rarity involved in this case is that the scar endometriosis developed after the removal of ovarian endometrioma.

Clinical experience has demonstrated that gynecologic operative procedures carry the risk of triggering the appearance of endometrial tissue in operative scar tissue, causing endometriomas of the scar tissue. This has been shown for laparotomy/cesarean section and episiotomy scars in a number of reports.<sup>1,2</sup> The number of the reported cases of laparoscopic scar endometriosis is lower compared with laparotomy scars. Besides already known benefits of laparoscopy, this is another reason to avoid laparotomy in patients with endometriosis.

Our patient was a 24-year old nulliparous patient, who was referred to us with an 8-month history of intense cyclic pain at the suprapubic trocar scar region. Two years earlier, the patient underwent operative laparoscopy during which a 7 cm endometrioma of the left ovary was removed by stripping out the capsule. After the removal of the suprapubic 10 mm trocar, the cyst was extracted through the anterior abdominal wall.

Deep beneath the skin at the suprapubic trocar site a painful tumefaction approximately 2x2 cm in size was palpated. A three-centimeter incision was made over the palpable lesion, and sharp dissection of the palpable bluish mass was performed. The underlying fascia and the muscle that contained palpable tumefactions were also excised. The histopathologic report for the mass

revealed mature fat tissue, muscle and connecting tissue with scattered areas of stromal and glandular endometrial tissues.

In previously published case reports, the development of endometriosis at the laparoscopic trocar site was described (*Table 1*). Only two of the seven patients mentioned in the reports had primary laparoscopy for pelvic endometriosis (one with an ovarian endometrioma,<sup>3</sup> the other with peritoneal implants.<sup>4</sup> In our case, primary laparoscopy showed that our patient had an ovarian endometrioma.

Similarly, in reports published for laparotomy scar endometriosis, patients with the preexisting disease appeared to have low incidence of scar endometriosis, yet this incidence was never established. Blanco et al.<sup>1</sup> described 12 cases of abdominal wall endometriomas with only one having preexisting endometriosis, while in another series of 17 patients<sup>2</sup> associated pelvic endometriosis was present in as much as 24% of the cases. It is worth noticing that in only two described cases of endometriosis following laparoscopic surgery for ovarian endometrioma, scar endometriosis appeared at suprapubic 5-mm sites. Our patient had scar endometriosis at the suprapubic midline 10-mm port incision.

We believe that separate mechanisms cause the development of scar endometriosis, and that the mentioned reports could be divided in two groups accordingly. The first group would be scar endometriosis developing after the laparoscopic procedure for primary endometriosis. Since only two reports of scar endometriosis following laparoscopy were published in 16 years (the first

Table 1. Reports on scar endometriosis following laparoscopic surgery.  
 Tablica 1. Izvješće o endometriozii ožiljka nakon laparoscopske kirurgije.

Author, Year Autor, godina	Primary laparoscopic surgery Prvotni laparoscopski zahvat	Scar endometriosis site Mjesto ožiljka endometriozie
Farace, 2005 <sup>5</sup>	Cholecystectomy	Right hypochondrium trocar scar
Sirito, 2005 <sup>3</sup>	Removal of the left ovarian endometrioma	Lateral 5-mm suprapubic trocar scar
Majeski, 2004 <sup>6</sup>	Myomectomy	Umbilical trocar scar
Martinez-Serna, 1998 <sup>7</sup>	Evacuation of a large hemoperitoneum	Lateral suprapubic 5-mm trocar scars
Wakefield, 1996 <sup>4</sup>	Diathermic ablation of endometriotic spots	Near umbilical trocar scar
Healy, 1995 <sup>8</sup>	Chronic pelvic pain, tubal ligation	Near umbilical trocar scar
Denton, 1990 <sup>9</sup>	Tubal ligation	Umbilical trocar scar

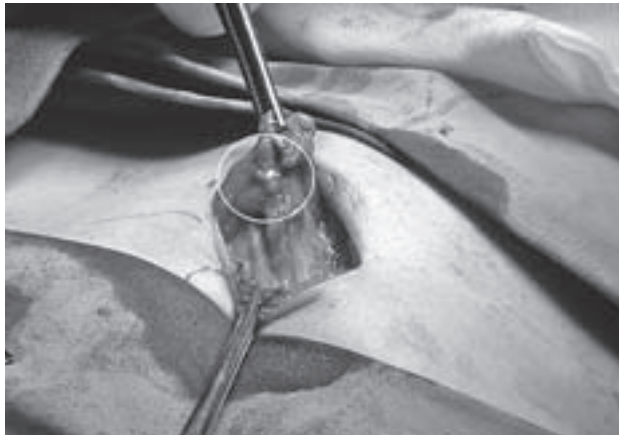


Figure 1. Intraoperative finding  
 Slika 1. Intraoperacijski nalaz

report being published sixteen years before the second one), and there was a small number of reports in the laparotomy case series, scar endometriosis seems to be a very rare occurrence. This may be explained by the presence of already highly differentiated cells in an established case of endometriosis, which makes it unlikely to implant at distant sites, thus ruling out the implantation theory. However, our case clearly supports the implantation theory, as the cyst was extracted directly through the tissue.

The other mechanism of scar endometriosis developing after the laparoscopic procedure seems to be encountered more often. Endometriosis develops here following a laparoscopic surgery for an unrelated condition, preferentially at the 10-mm umbilical scar region, in a previously healthy woman. Since the umbilicus is a preferential site for the development of primary extra-genital endometriosis, explained by physiologic scarring, a laparoscopic surgery may additionally change the umbilical scar to become a *locus minoris resistentiae* for the development of abdominal wall endometrioma. Evidently, regardless of numerous reports published in the literature, a lot of uncertainties about endometriosis

are still present, and thorough research is needed to unveil the basic etiology of this disease.

Presented case of endometriosis in suprapubic scar following laparoscopic removal of endometrioma, strongly suggests use of an endo-bag, a surgical glove or a similar retrieval device. In prevention of »port site« endometriosis, »port site« malignant metastasis, implantation of trophoblastic tissue or »port site« inflammatory infiltrate, the use of endo-bag is effective. Our opinion is that the use of the endo-bag should be obligatory for extraction of tissue from the abdominal cavity.

## References

1. Blanco RG, Parthivel VS, Shah AK, Gumbs MA, Schein M, Gerst PH. Abdominal wall endometriomas. *Am J Surg* 2003;185(6):596–8.
2. Chatterjee SK. Scar endometriosis: a clinicopathologic study of 17 cases. *Obstet Gynecol* 1980;56(1):81–4.
3. Sirito R, Puppo A, Centurioni MG, Gustavino C. Incisional hernia on the 5-mm trocar port site and subsequent wall endometriosis on the same site: a case report. *Am J Obstet Gynecol* 2005;193(3):878–80.
4. Wakefield SE, Hellen EA. Endometrioma of the trocar site after laparoscopy. *Eur J Surg* 1996;162(6):523–4.
5. Farace F, Gallo A, Rubino C, Manca A, Campus GV. Endometriosis in a trocar tract: is it really a rare condition? A case report. *Minerva Chir* 2005;60(1):67–9.
6. Majeski J, Craggie J. Scar endometriosis developing after an umbilical hernia repair with mesh. *South Med J* 2004;97(5):532–4.
7. Martínez-Serna T, Stalter KD, Filipi CJ, Tomonaga T. An unusual case of endometrial trocar site implantation. *Surg Endosc* 1998;12(7):992–4.
8. Healy JT, Wilkinson NW, Sawyer M. Abdominal wall endometrioma in a laparoscopic trocar tract: a case report. *Am Surg* 1995;61(11):962–3.
9. Denton GW, Schofield JB, Gallagher P. Uncommon complications of laparoscopic sterilisation. *Ann R Coll Surg Engl* 1990;72(3):210–1.

Paper received: 03. 07. 2008.; accepted: 07. 01. 2009.

Address for correspondence: Mihajlo Strelec, MD, PhD.,  
 E-mail: mihajlo.strelec@zg.htnet.hr