

Juraj Brozović¹, Dragana Gabrić Pandurić², Davor Katanec², Mato Sušić², Amir Čatić³

Imedijatna implantacija nakon enukleacije odontogene ciste: opis slučaja

Immediate Implant Placement Following Odontogenic Cyst Enucleation: a Case Report

¹ Privatna stomatološka ordinacija
Private Dental Office

² Zavod za oralnu kirurgiju Stomatološkog fakulteta Sveučilišta u Zagrebu
Department of Oral Surgery School of Dental Medicine University of Zagreb

³ Zavod za stomatološku protetiku Stomatološkog fakulteta Sveučilišta u Zagrebu
Department of Prosthodontics School of Dental Medicine University of Zagreb

Sažetak

Svrha ovog prikaza jest opisati restauraciju koštanog defekta nakon enukleacije radikularne ciste koristeći se vodenom koštanom regeneracijom uz imedijatnu implantaciju. Pacijentica je bila u dobi od 50 godina i imala je odontogenu cistu na prvom desnom maksilarnom premolaru i na istoj strani resorpciju korjenova drugog molara uzrokovanu impaktiranim umnjakom. Kirurškim zahvatom enukleirana je cista, a zatim je slijedila vodena koštana regeneracija, imedijatna implantacija te kirurško uklanjanje impaktiranog umnjaka. Pacijentica je nakon toga tijekom osteointegracijskog razdoblja dobila privremeni mobilni protetički nadomjestak. Šest mjeseci nakon zahvata stabilnost implantata provjerena je analizom rezonantne frekvencije. Srednja vrijednost za prvi premolar iznosila je 74, a za prvi molar 78. Oba implantata šest su mjeseci promatrana klinički i radiografski. Njihova stabilnost ocijenjena je umjerenom. U tom postoperativnom razdoblju nije bilo nikakvih kliničkih ili radioloških komplikacija. Implantati su iskorišteni kao sidra za fiksni protetički nadomjestak. Imedijatne implantacije nakon enukleacije odontogene ciste daju zadovoljavajuće rezultate te su smanjile broj kirurških zahvata.

Zaprimljen: 10. siječnja 2011.

Prihvaćen: 11. veljače 2011.

Adresa za dopisivanje

Dragana Gabrić Pandurić
Sveučilište u Zagrebu Stomatološki
fakultet
Gundulićeva 5, 10000 Zagreb
Tel: +385 1 4899210
Fax: +385 1 4802159
dgabric@sfzg.hr

Ključne riječi

odontogene ciste; gornja čeljust; zubni implantati; koštani nadomjestci; umnjak, cista, radikularna

Uvod

Odontogene ciste (OC) među glavnim su uzrocima razaranja čeljusne kosti (1). Nastaju iz epitelnih sastavnica ili ostataka odontogenog aparata unutar kosti ili gingivalnog tkiva. Smatra se da ih potiču proliferacija i cistična degeneracija (2-4). Odontogene ciste imaju različitu histogenezu i relativne stope frekvencije te klinička i biološka obilježja (3). Određen broj čeljusnih cista ima slična klinička, radiografska i histološka obilježja. Podaci o incidenciji, mjestima gdje se češće pojavljuju i dobnoj raspodjeli tih lezija važni su pri postavljanju vjerojatne dijagnoze (4,5). Točna dijagnoza odontogenih cista vrlo je važna jer se zna da su neke agresivne te nakon terapije sklone recidivima. Pogrešna dijagnoza moguća je zato što mnoge ciste imaju slična klinička i radiološka obilježja (6). Zato bi sve kirurški uklonjeno tkivo trebalo biti podvrgnuto histološkoj dijagnostici.

Radikularne ciste najčešće su među odontogenim cistama, imaju otprilike jednaku spolnu razdiobu i razmjerno se jednostavno dijagnosticiraju (4,6). U njihovoj incidenciji postoji nagli porast do trećeg desetljeća života, a zatim slijedi

Introduction

Odontogenic cysts (OC) are among main causes of jaw destruction (1). OC's develop from the epithelial constituents of the odontogenic apparatus, or its remnants, that lie entrapped within the bone or in the gingival tissue. It is considered that proliferation and cystic degeneration of epithelium lead to the development of OC (2-4). OC's show varied histogenesis, relative frequency rates, clinical features, and biological behavior (3). A number of cystic lesions in the jaw share similar clinical, radiographic, and histologic features. The incidences as well as more common sites of presentation, and age distribution are important clues when formulating an initial clinical diagnosis (4, 5). Correct diagnosis of odontogenic cysts is essential since some of these lesions are known to have aggressive behavior and a tendency to recur after treatment. Clinical misdiagnosis is possible as both clinical presentation and radiological signs are analogous for many of these cysts (6). Therefore, all surgically removed tissue should be submitted for histological examination.

postupno opadanje od četvrtog desetljeća pa dalje (4,6–9). Najčešća lokalizacija je u maksili, posebice u prednjoj regiji, a slijedi mandibularno molarno područje (4,6). Budući da je OC među glavnim uzrocima destrukcije čeljusti, iznimno je važno što prije dijagnosticirati ga kako bi se smanjio opseg kirurškog zahvata (6).

U opisanom slučaju restaurirali smo koštani defekt nakon enukleacije radikularne ciste koristeći se vođenom regeneracijom kosti (GBR-om) s imedijatnim postavljanjem implantata u postekstrakcijsku alveolu prvog premolara i u područje prvog molara. Kirurški zahvat obavljen je u Zavodu za oralnu kirurgiju Stomatološkog fakulteta u Zagrebu.

Opis slučaja

Pacijentica je bila 50-godišnja žena s odontogenom cistom na prvom premolaru u desnom dijelu maksile i s resorpcijom korjenova drugog molara uzrokovanom impaktiranim umnjakom. Anamnestički podaci nisu pokazivali relevantnu povezanost s OC-om. Zahvat je planiran nakon informiranog pristanka. Pregledom rendgenske snimke posumnjalo se na radikularnu cistu povezanu s prvim maksilarnim premolarom (Slika 1.) i na parcijalnu resorpciju korjenova drugoga maksilarnog molara uzrokovanu impaktiranim umnjakom (Slika 2.). Prije zahvata pacijentica se liječila antibioticima. Nakon toga joj je pod lokalnom anestezijom izvađen prvi maksilarni premolar i drugi molar s resorbiranim korjenovima. Nakon odizanja mukoperiostalnog režnja enukleirali smo cistu (Slika 3.) i imedijatno postavili implantat (Slika 4.). Preostali koštani defekt napunili smo ksenogenim koštanim nadomjestkom (Bio-Oss, Geistlich, Njemačka) (Slika 5.), te ga prekrili bioresorbirajućom kolagenom membranom (Bio-Gide®, Geistlich, Njemačka). Zatim smo kirurški izvadili impaktirani umnjak (Slika 6.). Rezultat je bio stabilan cilindrični implantat 3 x 11 milimetara hrapave površine (Ankylos Implant System, Friadent-Dentsply, SAD-Njemačka) imedijatno postavljen u alveolu ekstrahiranog prvog premolara. Također smo postavili i cilindrični implantat 3,5 x 11 milimetara s hrapavom površinom (Ankylos Implant System, Friadent-Dentsply, SAD-Njemačka) u područje prvoga desnog maksilarnog molara (Slika 7.). Kirurška šablona nije upotrijebljena.

Patohistološka analiza enukleiranog sadržaja potvrdila je dijagnozu radikularne odontogene ciste.

Tijekom nošenja privremene parcijalne proteze nije bilo nikakvih većih kliničkih ili subjektivnih problema. Nakon šest mjeseci cijeljenja, uređajem za analizu rezonantne frekvencije procijenili smo osteointegraciju postavljenih implantata (Osstell, Osstell AB, Göteborg, Švedska). Srednja vrijednost kvocijenta stabilnosti implantata (ISQ) za prvi premolar bila je 74, a za prvi molar 78. Osim toga implantati su iskorišteni kao sidrišta metal-keramičkog mosta (Slika 8.). U šest mjeseci kliničkog promatranja, nakon konačne fiksno-

Radicular cyst is the most common type of all odontogenic cysts and a fairly easily diagnosed entity with approximately equal sex distribution (4, 6). There is a sharp increase in their incidence until the third decade and then a gradual decline from the fourth decade onwards (4, 6-9). The most common localization of the radicular cysts is the maxilla, mainly in the anterior region, followed by the mandibular molar region (4, 6). Since OCs are one of the main causes of jaw destruction, it is necessary to detect these lesions as early as possible to minimize any necessary surgery (6).

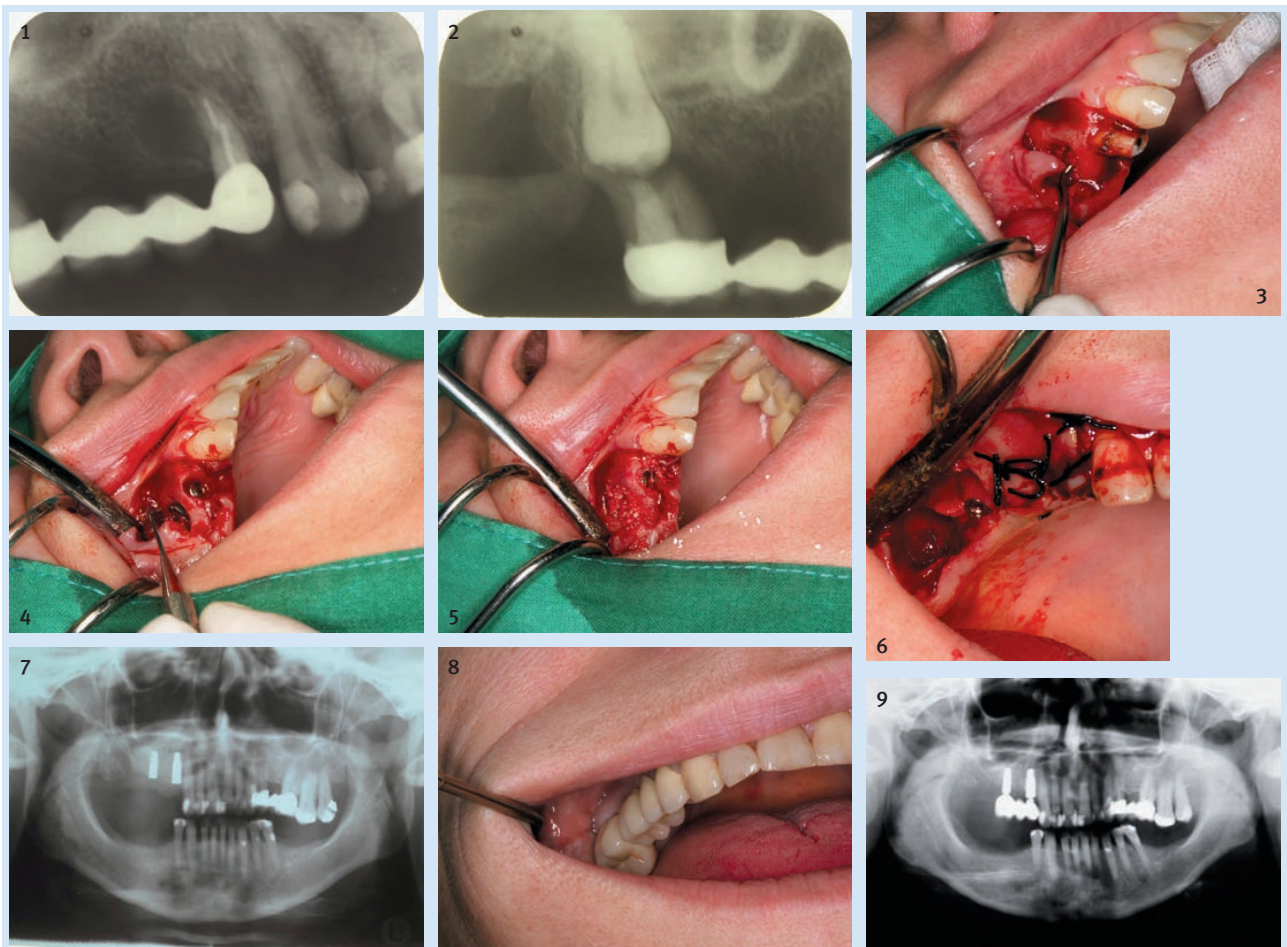
A case of bone defect restoration after a radicular cyst enucleation using guided bone regeneration (GBR) procedure with immediate implant placements in the first premolar post-extraction alveolus and in the first molar region is presented. The surgical procedure was carried out at the Department of Oral Surgery, School of Dental Medicine, Zagreb, Croatia.

Case report

The patient was a 50-year old female with an odontogenic cyst of the first premolar in the right maxilla and a second molar root resorption caused by an impacted third molar. The patient's medical history was unrelated to the OC. Treatment planning followed after the patient signed the written informed consent. A dental radiograph revealed a suspected radicular cyst lesion associated with the first maxillary premolar (Figure 1), and partially resorbed roots of the second maxillary molar caused by an impacted maxillary third molar (Figure 2). Systemic prophylactic antibiotics were administered preoperatively. Patient had undergone local anesthesia and the extractions of the maxillary first premolar and second molar with partially resorbed roots were carried out. Enucleation of the cyst was performed after a full-thickness periosteal flap creation (Figure 3) and an immediate implant was inserted (Figure 4). The remaining bone defect was filled with a xenogenic bone substitute (Bio-Oss, Geistlich, Germany) (Figure 5). The filled bone defect was covered by a bioresorbable collagen membrane (Bio-Gide®, Geistlich, Germany) and a surgical extraction of the impacted maxillary third molar was performed (Figure 6). We placed a stable, 3.5 x 11 mm cylindrical, roughened-surface (Ankylos Implant System, Friadent-Dentsply, USA-Germany) implant immediately in the alveolus of the extracted first premolar. We also placed a 3.5 x 11 mm cylindrical, roughened-surface (Ankylos Implant System, Friadent-Dentsply, USA-Germany) implant in the area of the right first maxillary molar (Figure 7). No surgical guide was used during implant placement.

A histopathological analysis was performed on the enucleated specimen which confirmed the diagnosis of a radicular OC.

No significant clinical or subjective problems were noted during the interim partial denture wearing period. After a healing period of 6 months, osseointegration of the inserted dental implants was assessed by a resonance frequency device (Osstell, Osstell AB, Göteborg, Sweden). Implant stability quotient (ISQ) mean scores for the first premolar and first molar implants were 74 and 78, respectively. The implants were further used as a base for a fixed partial denture (Figure 8). The pa-



Slika 1. Retroalveolarna rendgenska snimka sa suspektom lezijom nalik na radikularnu cistu povezanu s prvim maksilarnim premolarnom
Figure 1 Dental radiograph revealing a suspected radicular cyst lesion associated with the first maxillary premolar

Slika 2. Retroalveolarna rendgenska snimka s parcijalno resorbiranim korijenovima drugog maksilarnog molara zbog impaktiranog maksilarnog umnjaka
Figure 2 Dental radiograph showing partially resorbed roots of the second maxillary molar caused by an impacted maxillary third molar

Slika 3. Enukleacija ciste nakon odizanja mukoperiostalnog režnja
Figure 3 Cyst enucleation after a full-thickness flap elevation

Slika 4. Imedijatno postavljanje implantata
Figure 4 Immediate implant placement

Slika 5. Koštani defekt ispunjen ksenogenim koštanim nadomjestkom
Figure 5 Bone defect filled with xenogenic bone substitute

Slika 6. Kirurško uklanjanje impaktiranog umnjaka
Figure 6 Surgical extraction of the impacted maxillary third molar

Slika 7. Postoperativni ortopantomogram
Figure 7 Postoperative panoramic radiograph

Slika 8. Konačni fiksoprotetički nadomjestak, metalkeramički most
Figure 8 Final fixed partial denture

Slika 9. Postoperativni ortopantomogram s funkcionalno opterećenim implantatima
Figure 9 Postoperative panoramic radiograph showing functionally loaded implants

Slika 9. Postoperativni ortopantomogram s funkcionalno opterećenim implantatima
Figure 9 Postoperative panoramic radiograph showing functionally loaded implants

protetičke rehabilitacije i funkcionalnog opterećenja postavljenih implantata, nije bilo nikakvih kliničkih ili radioloških komplikacija (Slika 9.).

Rasprava

Ekstrakcija zuba i zamjena imedijatnim dentalnim implantatom prikladno su rješenje za zube s patološkim promjenama kao što su karijes, frakture te kronične apikalne lezije koje se ne poboljšavaju nakon konvencionalnog pristupa. Kontraindikacija za takve zahvate jest akutni periapikalni upalni proces (10-

tient exhibited neither clinical nor radiological complications throughout the following 6-month period of clinical monitoring after the final prosthodontic rehabilitation and functional loading of the inserted implants (Figure 9).

Discussion

The tooth extraction and replacement with immediate dental implants present a suitable treatment option for teeth with pathology such as caries or fractures, as well as for teeth with chronic apical lesions that are not likely to improve after conventional treatment. An absolute contraindication for this treat-

14). U tom slučaju prisutna je kronična apikalna lezija, odontogena cista te se ne preporučuje imedijatna implantacija.

U istraživanju Jonesa i suradnika (6) kao OC dijagnosticirano je 12,8 posto uzoraka – od toga su 52,3 posto bile radikularne ciste koje uglavnom zahvaćaju gornju čeljust. Pechalova i njezini kolege (15) potvrdili su 603 (97,2%) odontogene ciste, a pregledali su 621. Manjunatha i njegov tim (16) opisali su rijedak slučaj dentinogene ciste upalnog podrijetla (IDC-a) u lijevoj mandibularnoj kaninoj regiji i njezino liječenje enukleacijom te vađenje toga zuba. Bataineh i suradnici (17) u svojem su istraživanju zaključili da su među ostalim odontogenim cistama najbrojnije bile one radikularne (41,7%). U našem je slučaju OC desnog dijela maksile dijagnosticirana i enukleirana, što je rezultiralo koštanim defektom. Kompjutorizirana aksijalna tomografija (CAT) nije bila obavljena jer se dovoljnom smatrala intraoralna retroalveolarna snimka. No, dijagnostika poput kompjutorizirane aksijalne tomografije i magnetske rezonancije (MRI-a) može razjasniti neobične nalaze i ponekad je potrebna kako bi se dobila konačna dijagnoza (18). Kao posljedica enukleacije ciste ostao je volumni defekt kosti te je zato bio indiciran GBR. Postavili smo imedijatni implantat u koštani defekt prije toga napunjen ksenogenim koštanim nadomjestkom i prekriven bioresorbirajućom kolagenskom membranom. Takvo višestruko rješavanje problema tijekom jednog posjeta smanjuje broj kirurških postupaka (19). Berglundh i kolege (20) uočili su da koštani defekti ispunjeni ksenogenom kosti nestaju tri do sedam mjeseci nakon cijeljenja te da se ksenogene čestice okruže i dijelom zamijene lamelarnom kosti paralelnih vlakana. No, Galzignato i njegov tim (21) opisali su slučaj apikalne migracije dentalnog implantata u šupljinu rezidualne ciste maksile nakon što je kost bila ispunjena. U našem slučaju je, nakon ispunjenja ksenogenom kosti, cijeljenje bilo normalno. Krhen i suradnici (22) uočili su znatnu razliku u ISQ-vrijednostima kad su u pitanju spolovi i širine implantata. U studiji Bhole i njegovih kolega (23) imedijatni implantati preživljavali su u 94 do 100 posto slučajeva tijekom razdoblja cijeljenja od tri mjeseca do sedam godina. Wagenberg i suradnici (24) istaknuli su da implantati imedijatno postavljeni u pažljivo odabrane postekstrakcijske alveole, imaju visoke stope preživljenja ako ih se uspoređi s onima postavljenima u zacijeljena područja. Casado i njegovi kolege (25) izvijestili su o neuspjehu nakon postavljanja imedijatnog implantata u postekstrakcijsku alveolu zuba s periapikalnom lezijom jer se stvorila cista u nazopalatinalnom kanalu. U našem se slučaju imedijatni implantat postavljen u koštani defekt ispunjen ksenogenim koštanim nadomjestkom adekvatno osteointegrirao nakon šest mjeseci isto kao i implantat postavljen u netaknutu kost.

Zaključak

U složenim terapijama vrlo su važni pravilna dijagnoza i odgovarajuće planiranje zahvata. U opisanom slučaju demonstrirano je višestruko rješavanje problema tijekom jednog posjeta. Istodobno vođena regeneracija kosti nakon enukleacije odontogene ciste i imedijatna implantacija te kirurško uklanjanje umnjaka, znatno su smanjili broj potrebnih kirurških zahvata i dali zadovoljavajuće rezultate.

ment is a presence of an acute periapical inflammatory process (10-14). This case involves a chronic apical lesion, an odontogenic cyst, where an immediate implantation is recommended.

In a study by Jones et al. (6), 12.8% of the specimens analyzed were diagnosed as OC, 52.3% of which were radicular cysts mainly affecting the upper jaw. Pechalova et al. (15) diagnosed 603 (97.2%) odontogenic cysts out of 621 jaw cysts studied. Manjunatha et al. (16) reported a rare case of an inflammatory dentigerous cyst (IDC) in the left mandibular canine region treated by enucleation of the cyst along with the tooth associated. Bataineh et al. (17) reported radicular cysts as the most common type (41.7%) among other odontogenic cysts. In the present case an OC in the right maxilla was diagnosed and enucleated, leaving a bone defect behind. Computerized axial tomography scans were not taken since the retroalveolar dental radiograph was considered to be sufficient. Nevertheless, diagnostic procedures such as computerized axial tomography (CAT) scans and magnetic resonance imaging (MRI) can reveal unusual findings and are sometimes needed in order to make the final diagnosis (18). As a consequence of the cyst enucleation, a volume deficiency in the residual ridge was present and GBR was indicated. An immediate implant was placed into the bony defect previously filled with xenogenic bone substitute and covered by a bioresorbable collagen membrane. Such multiple problem solving in a single visit lowers the number of future surgical procedures (19). Berglundh et al. (20) reported that the bony defects filled with xenogenic bone were eliminated after 3 to 7 months of healing and that the graft particles became surrounded and partially substituted by parallel fibered and lamellar bone. However, Galzignato et al. (21) reported an apical migration of a dental implant into a residual cyst cavity in the maxilla after bone grafting. The present case showed normal healing after the xenogenic bone filling. Implant stability was assessed by RFA 6 months after surgery and proven adequate. Krhen et al. (22) reported a significant difference of ISQ values regarding gender and implant widths. In a study by Bhole et al. (23), immediate implant placement showed survival rates of 94 to 100% during the healing period of 3 months to 7 years. Wagenberg et al. (24) showed that dental implants placed immediately into carefully selected extraction sockets had high survival rates in comparison with implants placed in healed sites. Casado et al. (25) reported failure after the placement of an immediate implant in the extraction socket of a tooth with a periapical lesion due to nasopalatine duct cyst development associated with the implant. In the present case, it was noted that the immediate implant placed into the bony defect filled with xenogenic bone substitute showed an adequate osseointegration after a 6-month period as well as the implant placed into the intact bone.

Conclusion

Proper nosology and correct treatment strategy are essential in a complex therapy. The presented case demonstrated multiple problem solving in a single visit. Guided bone regeneration after odontogenic cyst enucleation, followed by immediate implantations and a surgical removal of a wisdom tooth in a single visit drastically lowered the number of surgical procedures and led to a satisfactory result.

Abstract

The purpose of this case report is to present a bone defect restoration after radicular cyst enucleation using guided bone regeneration procedure with immediate implant insertions. The patient was a 50-year old female with an odontogenic cyst of the first premolar in the right maxilla and a second molar root resorption caused by an impacted third molar. The surgical procedure involved a cyst enucleation followed by guided bone regeneration, immediate implantations, and surgical removal of the impacted third molar. The patient was supplied with an interim partial denture during the osseointegration period. Six months after surgical treatment, the implant stability was assessed by resonance frequency analysis. Mean scores for the first premolar and first molar implants were 74 and 78, respectively. Both implants were monitored clinically and radiographically during the following 6-month period. Implant stability was considered adequate. Neither clinical nor radiological complications were present throughout the postoperative 6-month period. The implants were used to support a fixed partial denture. Immediate implantations after odontogenic cyst enucleation minimized the number of surgical procedures and led to a satisfactory result.

Received: January 10, 2011

Accepted: February 11, 2011

Address for correspondence

Dragana Gabrić Pandurić
University of Zagreb School of Dental
Medicine
Department of Oral Surgery
Gundulićeva 5, HR-10000 Zagreb
Tel: +385 1 4899210
Fax: +385 1 4802159
dgabric@sfzg.hr

Key words

Odontogenic Cysts; Maxilla; Dental
Implants; Bone Substitutes; Molar, Third;
Radicular Cyst

References

- Mosqueda-Taylor A, Irigoyen-Camacho ME, Diaz-Franco MA, Torres-Tejero MA. Odontogenic cysts. Analysis of 856 cases. *Med Oral*. 2002 Mar-Apr;7(2):89-96.
- Grossmann SM, Machado VC, Xavier GM, Moura MD, Gomez RS, Aguiar MC et al. Demographic profile of odontogenic and selected nonodontogenic cysts in a Brazilian population. *Oral Surg Oral Med Oral Pathol Oral Radiol Endod*. 2007 Dec;104(6):e35-41.
- Carter LC, Carney YL, Perez-Pudlewski D. Lateral periodontal cyst. Multifactorial analysis of a previously unreported series. *Oral Surg Oral Med Oral Pathol Oral Radiol Endod*. 1996 Feb;81(2):210-6.
- Avelar RL, Antunes AA, Carvalho RW, Bezerra PG, Oliveira Neto PJ, Andrade ES. Odontogenic cysts: a clinicopathological study of 507 cases. *J Oral Sci*. 2009 Dec;51(4):581-6.
- Kim J, Ellis GL. Dental follicular tissue: misinterpretation as odontogenic tumors. *J Oral Maxillofac Surg*. 1993 Jul;51(7):762-7.
- Jones AV, Craig GT, Franklin CD. Range and demographics of odontogenic cysts diagnosed in a UK population over a 30-year period. *J Oral Pathol Med*. 2006 Sep;35(8):500-7.
- Shear M, editor. Cysts of the oral region. Oxford: Butterworth-Heinemann; 1992.
- Bhaskar SN. Oral pathology in the dental office: survey of 20,575 biopsy specimens. *J Am Dent Assoc*. 1968 Apr;76(4):761-6.
- Kreidler JF, Raubenheimer EJ, van Heerden WF. A retrospective analysis of 367 cystic lesions of the jaw--the Ulm experience. *J Craniomaxillofac Surg*. 1993 Dec;21(8):339-41.
- Henry PJ. Tooth loss and implant replacement. *Aust Dent J*. 2000 Sep;45(3):150-72.
- O'Sullivan D, Senneryby L, Meredith N. Measurements comparing the initial stability of five designs of dental implants: a human cadaver study. *Clin Implant Dent Relat Res*. 2000;2(2):85-92.
- Gelb DA. Immediate implant surgery: three-year retrospective evaluation of 50 consecutive cases. *Int J Oral Maxillofac Implants*. 1993;8(4):388-99.
- Grunder U, Polizzi G, Goené R, Hatano N, Henry P, Jackson WJ et al. A 3-year prospective multicenter follow-up report on the immediate and delayed-immediate placement of implants. *Int J Oral Maxillofac Implants*. 1999 Mar-Apr;14(2):210-6.
- Lindeboom JA, Tjiook Y, Kroon FH. Immediate placement of implants in periapical infected sites: a prospective randomized study in 50 patients. *Oral Surg Oral Med Oral Pathol Oral Radiol Endod*. 2006 Jun;101(6):705-10.
- Pechalova PF, Bakardjiev AG. Cysts of the Jaws: a Clinical Study of 621 Cases. *Acta Stomatol Croat*. 2009;43(3):215-24.
- Manjunatha BS, Deepak Pateel GS. Dentigerous cyst of inflammatory origin: a diagnostic challenge. *Acta Stomatol Croat*. 2010;44(1):61-4.
- Bataineh AB, Rawashdeh MA, Al Qudah MA. The prevalence of inflammatory and developmental odontogenic cysts in a Jordanian population: a clinicopathologic study. *Quintessence Int*. 2004 Nov-Dec;35(10):815-9.
- Bornstein MM, Wiest R, Balsiger R, Reichart PA. Anterior Stafne's bone cavity mimicking a periapical lesion of endodontic origin: report of two cases. *J Endod*. 2009 Nov;35(11):1598-602.
- Gabrić Pandurić D, Sušić M, Čatić A, Katanec D. Minimally invasive one-stage flapless technique with immediate non-functional implant loading. *Acta Stomatol Croat*. 2008;42(1):79-85.
- Berglundh T, Lindhe J. Healing around implants placed in bone defects treated with Bio-Oss. An experimental study in the dog. *Clin Oral Implants Res*. 1997 Apr;8(2):117-24.
- Galzignato PF, Sivolella S, Cavallin G, Ferronato G. Dental implant failure associated with a residual maxillary cyst. *Br Dent J*. 2010 Feb 27;208(4):153-4.
- Krhen J, Canjuga I, Jerolimov V, Krhen T. Implant Stability Measurement Six Weeks After Implantation. *Acta Stomatol Croat*. 2009;43(1):45-51.
- Bhola M, Neely AL, Kolhatkar S. Immediate implant placement: clinical decisions, advantages, and disadvantages. *J Prosthodont*. 2008 Oct;17(7):576-81.
- Wagenberg B, Froum SJ. A retrospective study of 1925 consecutively placed immediate implants from 1988 to 2004. *Int J Oral Maxillofac Implants*. 2006 Jan-Feb;21(1):71-80.
- Casado PL, Donner M, Pascarelli B, Derocy C, Duarte ME, Barboza EP. Immediate dental implant failure associated with nasopalatine duct cyst. *Implant Dent*. 2008 Jun;17(2):169-75.