

Salmonella Ovarian Abscess in Young Girl Presented as Acute Abdomen – Case Report

Nina Miksić Gorišek¹, Slavko Orešković² and Igor But³

¹ Maribor University Medical Center, Department of Infectious Diseases, Maribor, Slovenia

² University of Zagreb, Zagreb University Hospital Center, Department of Gynecology and Obstetrics, Zagreb, Croatia

³ Maribor University Medical Center, Division of Gynaecology and Obstetrics, Maribor, Slovenia

ABSTRACT

Ovarian abscess in young sexually non-active girls can represent a diagnostic challenge. 15-years old girl was admitted to the Clinic for Gynaecology and Obstetrics under the suspicion of torsion of an ovarian cyst. Her clinical status deteriorated after the admission with development of acute abdomen. Laparoscopic exploration was performed and unilateral ovarian abscess was found without involvement of other pelvic structures. The surgical procedure was minimal invasive for a young girl and *Salmonella* staleyville was isolated from pus. Solitary ovarian abscess can be of hematogenous origin and the causative pathogens are different from pathogens usually involved in pelvic inflammatory disease. To avoid later fertility problems it is of great importance to treat infections in pelvic region correctly according to the isolated microorganism and that surgery is the least invasive.

Key words: ovary abscess, *Salmonella* staleyville, pelvic inflammation

Introduction

Pelvic inflammatory disease with abscess formation is rare in sexually non-active adolescent girls. We report a case of *Salmonella stanleyville* unilateral ovarian abscess in 15-years old virgin presented with a clinical manifestation of acute abdomen. The patient did not have any previous symptoms of gastrointestinal nor clinically manifest bacteraemic *Salmonella* spp. infection.

Case Report

A 15-years old girl was transferred to the Clinic for Gynaecology and Obstetrics from a regional hospital under the suspicion of torsion of an ovarian cyst. The patient was admitted to the regional hospital 2 days earlier with high fever (39.2 °C) and lower abdominal pain. Ultrasonography of pelvis was performed on admission to the regional hospital and unilocular cystic structure in the right ovary was confirmed. At admission to our hospital the patient had high fever 38.8 °C and clinical examination revealed tenderness in lower right abdomen. Rectal examination confirmed normal sized non-tender anteverted uterus, right adnexal area was very tender on pal-

pation, although no mass was palpable. The vaginal examination was not performed since she was a virgin. The ultrasound examination of the pelvic region showed hypoechogenic cystic formation 64×56 mm in the right ovary with irregular echogenitiy inside and highly vascularized cysts wall (Figure 1). Left ovary and uterus were normal. Small amount of free fluid was seen in the pelvic cavity. The laboratory tests performed on admission showed leucocytosis of $21.9 \times 10^9/L$ with left shift, other inflammatory markers were only slightly elevated (C-reactive protein was 37 mg/L, procalcitonin 0.43 ng/L). She was prescribed empiric parenteral antibiotic therapy with ciprofloxacin and clindamycin.

Her condition did not improved in the next 36 hours. She was constantly febrile with temperature above 38.5 °C and right abdominal pain deteriorated with development of local contracture of the anterior abdominal wall (defence musculaire). The repeated laboratory examination on the third day showed persistent leucocytosis (WBC $20.5 \times 10^9/L$) and marked elevation of C-reactive protein (213 mg/L), the tumor marker CA 125 was elevated as well (104 U/mL).

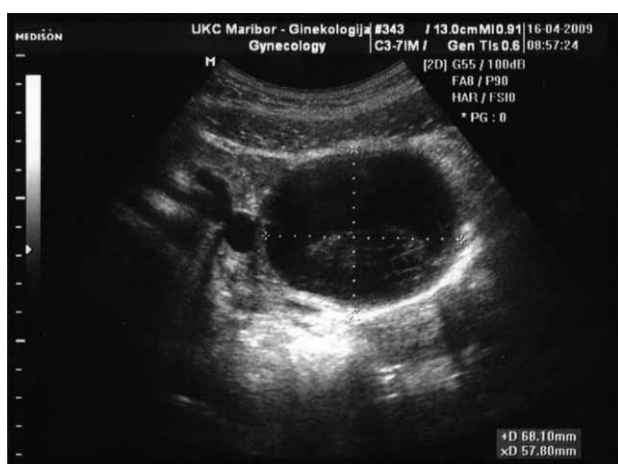

Fig. 1. Ultrasound imaging of pelvis showing hypoechoic cystic formation 64×56 mm in the right ovary with irregular echogenity inside and highly vascularized cysts inside and highly vascularized cysts inside and highly vascularized cysts inside.

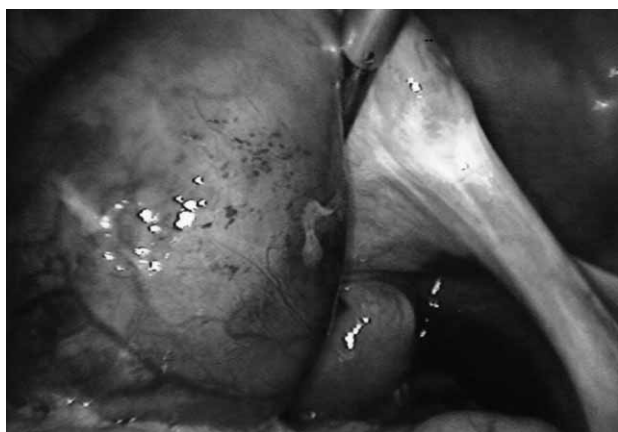


Fig. 2. Laparoscopic view of enlarged right ovary without torsion.

The abdominal surgeon was consulted and bowel inflammatory disease and perityphlitic abscess were ruled out.

The explorative laparoscopy was performed 44 hours after the admission to the hospital. We found an enlarged right ovary without torsion (Figure 2); the overlying omentum was adhering to it. The other organs in pelvis (both fallopian tubes and left ovary) were normal as well as the appendix.

The cyst in right ovary was incised and 100 mL of whitish-green pus was aspirated and sent for microbiological examination. The abscess cavity was rinsed and 2 drains were left in pelvic cavity for abdominal lavage for the next 18 hours.

Her condition improved rapidly after the procedure. She was afebrile and clinical stable, inflammatory markers decreased, only the CA 125 marker was still elevated (320 U/mL). On the fourth postoperative day she was discharged from the hospital.

Before the discharge we received the result of microbiological examination of abscess fluid and nontyphoid *Salmonella stanleyville* was isolated. The blood culture and urine culture were negative. The strain was susceptible to ceftriaxon, ampicillin, ciprofloxacin, trimetoprim/sulfametoxasole.

At discharge we changed the antibiotic therapy to oral ciprofloxacin alone for another 10 days.

On account of this finding we performed also the microbiological examination of stool, however we did not proved *Salmonella* spp. nor other pathogenic bacteria. After detailed questioning, the patient denied any gastrointestinal problems or febrile illnesses during the last 6 months, all the family members were healthy as well. She did not recall having any *Salmonella* infection in the past. She did not travel abroad and does not possess any exotic pet at home (reptiles, turtles, snakes).

Discussion

Ovarian abscess in young sexually non-active girls can represent a diagnostic challenge, since it is rare and can be unrecognized or mistaken for other pathology like cysts or tumour as reported in literature^{1,2}. Our preoperative diagnosis was ovarian cysts torsion and purulent content of the cyst was unexpected.

Ovarian abscesses are commonly associated with pelvic inflammation. Generally, they develop by ascending route as a part of salpingo-oophoritis. In contrast isolated ovarian abscesses without tubal involvement are very rare. They can follow pelvic surgery with traumatization of ovarium most commonly³, however can be a consequence of haematogenous or lymphatic spread of an organism during sepsis or bacteraemia. Commonly isolated organisms in ovarian abscesses following haematogenous spread are *Enterobacteriaceae*, streptococci, enterococci and *Staphylococcus aureus*. *Salmonella* spp. is a rare cause of ovarian abscess, reported in few cases in literature. In most cases it is of haematogenous origin, although the ovary can be infected by direct propagation from inflamed bowel wall or by ascending route.

Nontyphoidal *Salmonella* infections are most common cause of bacterial gastroenterocolitis in developed world. Invasive infections are rare in immunocompetent patients. Focal metastatic infections occur in 5–10% of patients with invasive salmonellosis in various organs⁶. The presence of pre-existing disease favours *Salmonella* local infection. It is known that persons with malignancy, anatomical abnormalities, sickle cell disease, systemic lupus erythematosus, hemoglobinopathies etc. are at increased risk to develop localized infection after invasive salmonellosis. Tumours, cysts, bone infarction and damaged tissue are all predilection sites for focal *Salmonella* infections. Most patients with ovarian *Salmonella* infection had pre-existing abnormalities of ovaries like cysts or endometriotic foci^{4,7}. In our case the patient did not have any visible abnormality of the ovary nor any pre-existing diseases.

The interesting point is the patient did not have any history of gastrointestinal infection or bacteraemic episode, also the stool samples, blood cultures and urine cultures were all negative for *Salmonella*. Most cases in the literature have a history of *Salmonella* infection; however there are also 5 reports in the literature with negative history and negative stool samples⁴.

It is well known that *Salmonella* can survive in a dormant state for a long period of time in protected locations such as gall-bladder stones and kidney stones. Ovarian cysts have been accused to be a similiar location. The time interval from acute salmonellosis to the clinical presentation of an ovarian abscess can be from a few weeks up to 35 years⁸. This long interval can be explained by altered cell-immune response triggering proliferation of dormant bacteria in ovary.

In *Salmonella* focal infection in pelvic area are commonly treated with the combination of surgery followed by 7–14 days of appropriate antibiotic treatment. We performed laparoscopic surgery in adolescent girl which was minimal invasive for the young patient. The antibiotic of choice for *Salmonella* infection, depending the susceptibility of isolated strain is ampicillin, ceftriaxon or ciprofloxacin. We continued the empirically prescribed ciprofloxacin for 14 days.

Our case presents *Salmonella* spp. ovarian abscess as a cause of acute abdomen in young sexually non-active girl without predisposing ovarian abnormalities. It emphasizes the importance of microbiological diagnostics in ovarian abscesses, especially in sexually non-active population. To avoid later fertility problems it is of great importance to treat infections in pelvic region correctly and that surgery is the least invasive.

REFERENCES

1. MILLER AS, HUNSTAD D, *Pediatr Infect Dis J*, 26 (2007) 548. —
2. LATAWIEC-MAZURKIEWICZ I, JUSZKIEWICZ P, PACANOWSKI J, KWAS A, RYBKIEWICZ M, *Eur J Pediatr Surg*, 15 (2005) 38. —
3. VERMA A, MITTAL S, KUMAR S, *Int J Gynaecol Obstet*, 68 (2000) 263. —
4. BURGMANS JPJ, VAN ERP EJM, BRIMICOMBE RW, KAZAZ BA, *Eur J Obstet Gynecol Reprod Biol*, 72 (1997) 2007. —
5. TOHYA T, YOSHIMURA T, ONODA C, *Infect Dis Obstet Gynecol*, 11 (2003) 217. —
6. PEGUES D, OHL ME, MILLER SI, *Salmonella* species, including *Salmonella typhi*. In: MANDELL GL, BENNETT JE, DOLIN R (Eds) *Mandell, Douglas, and Bennett's Principles and Practice of Infectious diseases*. 6th ed. (Philadelphia, USA, Elsevier Churchill Livingstone, 2005). —
7. CHIN HY, CHIANG PC, CHEN KC, *J Reprod Med*, 49 (2004) 762. —
8. EVANS-JONES JC, FRENCH GL, *Br J Obstet Gynaecol*, 90 (1983) 680.

S. Orešković

University of Zagreb, Zagreb University Hospital Center, Department of Gynecology and Obstetrics, Petrova 13, 10 000 Zagreb, Croatia
e-mail: predstojnik_gin@kbc-zagreb.hr

SALMONELLA OVARISJKI APSCES U MLADE DJEVOJKJE SA SLIKOM AKUTNOG ABDOMENA: PRIKAZ SLUČAJA

SAŽETAK

Ovarijski apsces u spolno neaktivnih djevojaka može predstavljati dijagnostički izazov. Petnaestogodišnja djevojka primljena je u Kliniku za ginekologiju i porodništvo pod sumnjom torzije ciste jajnika. Njeno kliničko stanje pogoršalo se nakon prijama razvojem akutnog abdomena. Učinjena je laparoscopska eksploracija te je nađen jednostrani ovarijski apsces bez zahvaćenosti drugih struktura zdjelice. Kirurški postupak za maldu djevojku je bio minimalno invazivan, a iz gnoja je izolirana *Salmonella staleyville*. Solitarni ovarijski apsces može biti hematogenog podrijetla i uzočnici su različiti od patogena koji su obično uključeni u upalnu bolest zdjelice. Kako bi se izbjegli kasniji problemi plodnosti žena, od velike je važnosti ciljano liječiti upale zdjelice regije ovisno o izoliranom mikroorganizmu kao i primjena minimalno invazivnog kirurškog postupka.