

# Influence of Surgery onto the Appearance of the Hip Joint Periarticular Calcification in Patients with the Acetabular Fracture

Ivan Lovrić<sup>1</sup>, Bruno Splavski<sup>2</sup>, Savo Jovanović<sup>3</sup>, Ivan Soldo<sup>4</sup> and Branko Radanović<sup>5</sup>

<sup>1</sup> »J. J. Strossmayer« University, Osijek University Hospital Centre, Department of Surgery, Osijek, Croatia

<sup>2</sup> »J. J. Strossmayer« University, Osijek University Hospital Centre, Department of Neurosurgery, Osijek, Croatia

<sup>3</sup> »J. J. Strossmayer« University, Osijek University Hospital Centre, Division of Orthopaedic Surgery, Osijek, Croatia

<sup>4</sup> »J. J. Strossmayer« University, Osijek University Hospital Centre, Department of Infectious Disease, Osijek, Croatia

<sup>5</sup> »J. J. Strossmayer« University, Osijek University Hospital Centre, Department of Neurology, Osijek, Croatia

## ABSTRACT

*The intention of this study was to investigate the influence of surgery onto the appearance of the hip joint periarticular calcification in different groups of patients who suffered the acetabular fracture. A series of 103 patients with the acetabular fracture was analysed in a retrospective case-control study during a seven-year period. The patients were divided into two groups. The case group was comprised of 21 patients who were operated on due to the posterior acetabular wall fracture, while the control group was formed from 82 patients who underwent conservative treatment and who suffered complex acetabular fracture. To obtain the results, the rate and grade of the hip joint post-injury periarticular calcification formation were observed and analysed. They were considerably lower in patients from the case group who were operated on, compared to patients from the control group where the hip joint arthrosis was more common. In conclusion, considering the results of this paper, the rate and grade of the hip joint osteodegenerative changes may be highly decreased by surgery in patients who sustained the acetabular fracture.*

**Key words:** acetabular fracture, hip joint, periarticular calcification, surgery

## Introduction

The purpose of the study was to analyze the influence of surgery onto the rate and grade of the hip joint periarticular calcification formation in different groups of surgically and conservatively treated patients suffering the acetabular fracture.

The acetabular fracture surgery has always been a demanding procedure which necessitates a thorough professional surgical practice. Such an injury with bone fragment dislocation requires open reduction and internal fixation (ORIF) of the displaced fractures<sup>1-4</sup>, that is followed by an early physical rehabilitation<sup>5</sup>. The fracture typically appears at the particular side of the body where neuromuscular function is less powerful and loading forces are stronger<sup>6,7</sup>. As a consequence of the acetabular fracture, bone fragments may be displaced in badly aligned locations. Subsequently, post-traumatic ar-

thritic changes of the hip joint may occur as usual complication of such an injury. Less frequent osteodegenerative complications include post-traumatic osteoarthritis, osteonecrosis and heterotopic ossification of the femoral head<sup>2</sup>.

Periarticular calcification is a condition distinguished by atypical alteration of the hip joint soft tissues into bone, taking place in a diversity of clinical circumstances<sup>8</sup>. The development of post-injury heterotopic ossification strongly influences the hip joint functional status<sup>9</sup>, that is dependent on the degree of ossification itself, differing from small femoral head osteophytes to complete ankylosis of the hip joint<sup>10</sup>. Although some authors<sup>11</sup> have suggested that even a lower degree of ossification may reduce the hip function, it seems that only a higher

degree of periarticular calcification is responsible for grave hip joint functional limitation, noticeably reducing hip range of motion<sup>9,12,13</sup>.

In a view of all the above mentioned, major hypothesis of this paper is that surgery may be the most relevant factor to reduce the rate and grade of the hip joint periarticular calcification formation and consequently improve the mobility of patients who sustained the acetabular fracture.

## Patients and Methods

A series of 103 patients with the acetabular fracture was analyzed in a retrospective case-control study during a seven-year period.

The study case group was formed of 21 patients who were treated surgically, while 82 patients who were treated conservatively comprised the control group. They were followed-up for a 5-year period, when clinical examination was performed and the appearance of osteodegenerative changes, such as periarticular calcification formation, was observed and measured at the hip joint plain radiographs.

Patients were allocated to the case or the control group dependant on the indications for the treatment selection. According to the Letournel-Judet classification and fracture location<sup>14</sup>, all patients from the case group (n=21) in whom the dislocation of the acetabular roof was less than 40 degrees, were selected for surgery by ORIF. The angle of dislocation was measured in degrees by goniometer on plain hip radiographs. Surgery was only performed when the patients' general condition became stable and diagnostics procedures completed, except in case of the femoral head luxation which was promptly repositioned. In such patients, physical rehabilitation and gradual loading of the injured limb were started earlier. All other patients, including those with the transversal acetabular fractures, were allocated to the control group (n=82) and treated conservatively by skeletal traction and weight bearing dome while in bed, and were insisted on active tonization of the leg muscle. Exceptionally, the patients with hip joint luxation, or those with dorsocranial acetabular minor bone fragment were allowed to walk with orthopaedic aids after the reposition.

A prophylactic low-dose irradiation and postoperative treatment with indomethacin for the prevention of he-

terotopic ossification were not applied, since it was not a part of our standard protocol of the acetabular fracture management.

The follow-up period for all the patients was at least 5 years, to make sure that the fracture was healed and rehabilitation completed. Then, the control pelvic plain radiographs were made to register the extent and measure the grade of the hip joint periarticular calcifications by goniometer in degrees.

The time between the injury and appearance of periarticular calcification formations was also recorded and the location, rate and grade of their appearances were analyzed in both surgically and conservatively treated patients.

The evaluation of heterotopic ossification was done according to the original Brooker classification<sup>15</sup>, which has also been frequently used in similar studies<sup>8,11–13,16,17</sup>. Regarding this, patients in whom Booker Score I-II (lower degree grade) was recorded were considered having minor to mild hip joint periarticular changes, while those with Booker Score III-IV (higher degree grade) were the ones with grave periarticular calcifications including the hip ankylosis.

The data of patients from the case group considering the rate and grade of the hip joint ectopic ossification were statistically analysed and compared to the similar data of patients from the control group. A PC application SAS for Windows (SAS Institute Inc., Cary, NC, USA) was employed for the data statistical analysis. A Chi-Square Test ( $\chi^2$ ) and Fisher Exact Test for independent samples were used to investigate the difference in frequencies of rate and grade of periarticular calcification within the groups, as well as between the case and the control group. The level of significance was set at  $p < 0.001$ .

## Results

Out of 103 patients with the acetabular fractures there were 79 males (76.7%) and 24 females (23.3%). The average age was 43.7 years. It was 54.7 years for men and 40.3 years for women respectively. The patients were predominantly middle aged males who were mostly injured in traffic accidents (Table 1). Twenty one (20.4%) of them were treated surgically, and 82 (79.6%) underwent a conservative protocol.

TABLE 1  
DIVISION OF PATIENTS ACCORDING TO THE SEX AND THE CAUSE OF INJURY

Cause of fracture	Males		Females		Total	
	n	%	n	%	n	%
Traffic accident	65	63.11	12	11.65	77	74.76
Fall	14	13.59	10	9.71	24	23.30
Other	0	0.00	2	1.94	2	1.94
Total	79	76.70	24	23.30	103	100.00

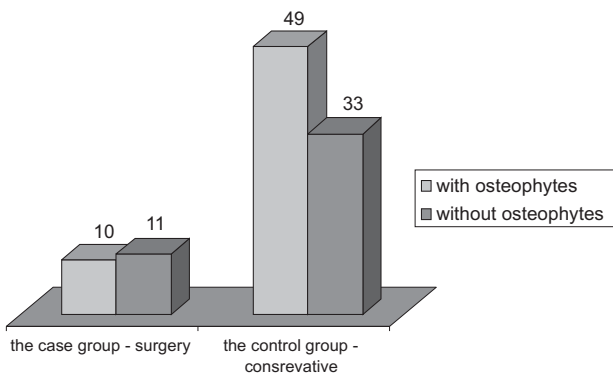


Fig. 1. Distribution of the femoral head periarticular calcification appearance in both groups of patients.

The fracture of the acetabular posterior wall was recorded in 12 (57%) out of 21 surgically treated patients. Operative reposition and fracture stabilization by spongy screws and adaptive plates were performed in all of them.

Complex, transversal acetabular fractures were observed in 34 out of 82 (41.5%) patients from the control group who were not operated on.

The mean duration of the treatment time was 11 months for the case group, and 12.4 months for the patients from the control group.

Regarding the time needed for the development of osteodegenerative hip joint changes, they occurred approximately 7.7 months after conservative treatment and 11 months after surgery respectively.

Considering periarticular calcification appearances, the hip joint calcification was not found in 11 out of 21 (52.4%) surgical patients from the case group. (Figure 1). In the remaining 10 patients from the same group, the locations of periarticular calcification were noticed medially in 4 (19%) patients, followed by lateral and medial, and cranio-lateral position in 3 (14.3%) patients each. (Figure 2).

The femoral head periarticular ossifications were found in 49 out of 82 (59.8%) conservatively treated patients from the control group. (Figure 1). Calcifications were positioned medially in 19 (23.2%) patients, laterally and medially in 14 (17.1%), cranio-laterally in 10 (7.3%), and caudomedially in 6 (9.23%) patients. No femoral head calcifications were later developed in 33 out of 82 (40.2%) non-surgically treated patients. (Figure 3). Therefore, the femoral head periarticular calcifications were found in 10/21 (47.6%) of patients from the case group and in 49/82 (59.8%) of patients from the control group. Still, the difference in rate of periarticular calcification appearance between the groups was not statistically significant.

The majority of surgically treated patients (11/21; 52.4%) did not develop the hip joint osteodegenerative changes in comparison to those who did. However, the case group sample was too low to tell the statistical difference within the group.

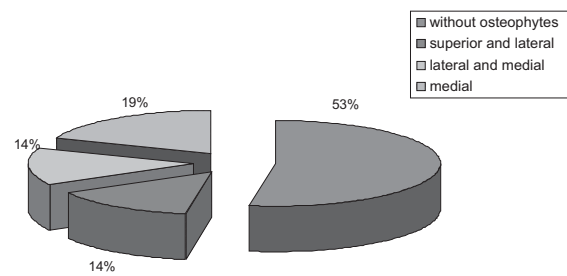


Fig. 2. Prevalence of the femoral head periarticular calcification appearance in the group of surgically treated patients (the case group).

In all 10 (100%) patients from the case group who developed femoral head periarticular calcifications, lower degree ectopic ossifications were found (Brooker Score I-II). At the same time, among 49 patients who developed periarticular calcifications from the control group, there were 22 (44.9%) patients with lower degree ossifications (Brooker Score I-II), while in the remaining 27 (55.1%) patients higher degree of ectopic femoral head ossification were found (Brooker Score III-IV), including 3 (6.1%) patients with the hip ankylosis (Brooker Score IV). (Table 2). The difference in grade of periarticular calcification between the case and the control group was statistically significant ( $p=0.001$ ), since all 10 surgical patients developed lower degree calcifications, while in the majority (27/49) of those treated conservatively, calcifications of a higher degree were found.

## Discussion

The majority of surgically treated patients from the case group in our series (53%) did not develop the femoral head periarticular calcifications compared to those treated conservatively, where the calcifications were not observed in 41% of the cases (Figure 1). At the same time, among surgically treated patients who gained them, only calcifications of a lower degree were found (Brooker Score I-II). On the contrary, in the majority of patients from the control group who were treated conservatively, ossification of a higher degree (Brooker Score III-IV) was most frequent (55%), (Table 2). Among the conservatively treated patients a lot of severe cases with multiple

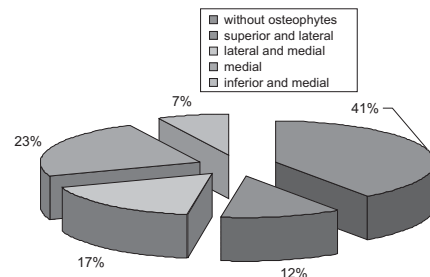


Fig. 3. Prevalence of the femoral head periarticular calcification appearance in the group of conservatively treated patients (the control group).

**TABLE 2**  
DIVISION OF PATIENTS WITH THE HIP JOINT PERIARTICULAR CALCIFICATION ACCORDING TO THE BROOKER SCORE

	Brooker I-II	Brooker III-IV	Total
Case group – surgery	10 (47.6%)	0 (0%)	10
Control group – conservative	22 (44.9%)	27 (55.1%)	49
Total	32 (54.2%)	27 (45.8%)	59

fragments acetabular fracture were noticed. Those patients were mostly immobile throughout the prolonged period of a conservative treatment, what may explain the prevalence of periarticular ossification, particularly those of a higher degree in the control group.

The difference in grade of periarticular calcification between surgically and conservatively treated patients was statistically significant ( $p < 0.001$ ).

Periarticular hip joint changes of different grades occurred sooner after a conservative treatment (7.7 months post injury) in comparison to surgery, where they appeared later (11 months after surgery). Concerning the period between injury and the appearance of the periarticular femoral head changes, our findings indicate that it was the longest in surgically treated patients with fractures of the anterior acetabular wall and the anterior column, while it was the shortest in those with the posterior acetabular wall and the posterior column fractures that were not operated on. According to our clinical observation, it seems that fractures of the posterior column and the posterior acetabular wall were mainly responsible for early appearance of periarticular calcifications of the hip joint.

Ghalambor et al.<sup>18</sup> found a significant correlation between poor clinical results at the follow ups and a higher degree of the hip joint ectopic bone formation. Several other authors found reduced walking ability and capacity in patients with a higher degree of heterotopic ossification, while some concluded that only a severe grade of such ossification (Brooker Score IV) is clinically significant<sup>19,20</sup>. Nevertheless, most studies show trends towards a worse functional outcome with an increasing grade of heterotopic ossification<sup>11</sup>.

Considering this, it seems that the development of periarticular calcifications influences the physical hip joint function dependent on its grade<sup>10</sup>, since a number of reports described significantly reduced range of motion at follow-ups in patients with a severe heterotopic ossification<sup>13,21</sup>. Kromann-Andersen et al.<sup>19</sup> have also reported that reduction in motion is directly proportional to the severity of the heterotopic ossification. However, only rare reports exist showing no significant difference in motion range between patients with and without heterotopic ossification<sup>22</sup>, as well as between those with lower degree grade of heterotopic ossification compared to ones with a higher grade of ossification<sup>20</sup>. Accordingly, the hip joint periarticular calcifications were recorded less often in the case group of patients in our series in comparison to the control group of patients who were not operated on, indicating better functional outcome in surgically treated patients (Figure 1).

Some authors suggested a prophylactic low-dose irradiation for prevention of heterotopic ossification as a complication of acetabular fracture<sup>23</sup>. Others described prophylactic postoperative treatment with indomethacin<sup>24</sup>, or non-steroidal anti-inflammatory drugs<sup>17</sup> which inhibit the formation of periarticular calcifications. However, we have no experience regarding this, since it was not a part of our standard protocol of treatment.

In conclusion, an adequate reposition of the fractured bone fragments, as well as an early physical rehabilitation, resulted in less frequent appearance of the hip joint periarticular calcifications after the acetabular fracture in the patients who were operated on. The management overall length was shorter, the development of osteodegenerative changes fewer, and the grade of periarticular ossifications was of a lesser degree in surgically treated patients in our series. Therefore, surgery has strong influence in reducing the hip joint periarticular calcification in patients who sustained the acetabular fracture. Hence, the results of this paper support our initial hypothesis.

Considering our findings, it is worth keeping in mind certain restrictions of this article arising from its retrospective quality and relatively small number of surgically treated patients in our series. Obviously, further research is necessary to confirm our results.

## REFERENCES

- GIANNOUDIS PV, GROTZ MR, PAPAPOSTIDIS C, DINOPOULOS H, *J Bone Joint Surg*, 87B (1) (2005) 2. — 2. MATTA JM, *J Bone Joint Surg (Am)*, 78A (1996) 1632. — 3. YU JK, CHIU FY, FENG C-K, CHUNG T-Y, CHEN T-H, *Injury*, 35 (2004) 766. — 4. KUMAR A, SHAH NA, KERSHAW SA, CLAYSON AD, *Injury*, 36(5) (2005) 605. — 5. MATTA JM, *Clin Orthop*, 305 (1994) 10. — 6. HAS B, NAGY A, HAS-SCHÖN E, PAVIĆ R, KRISTEK J, SPLAVSKI B, *Coll Antropol*, 30 (2006) 823. — 7. LOVRIĆ I, SPLAVSKI B, JOVANOVIĆ S, SOLDI I, KVOLIK S, HAS B, *Coll Antropol*, 33(4) (2009) 1103. — 8. WRIGHT JG, MORGAN E, BROOCH E, *J Arthroplasty*, 9(5) (1994) 549. — 9. LOVRIĆ I, JOVANOVIĆ S, LEKŠAN I, BIUK E, KRISTEK J, RADIĆ R, *Coll Antropol*, 31(1) (2007) 285. — 10. KOCIC M, LAZOVIC M, MITKOVIC M, DJOKIC B, *Orthopedics*, 33(1) (2010) 16. — 11. NEAL B, *ANZ J Surg*, 73(6) (2003) 422. — 12. RAMA KR, VENDITTOLI PA, GANAPATHI M, BORGMANN

- ROY A, LAVIGNE M, *J Arthroplasty*, 24(2) (2009) 256. — 13. POHL F, SEUFERT J, TAUSCHER A, LEHMANN H, SPRINGORUM HW, FLENTJE M, KOELBL O, *Strahlenther Onkol*, 181(8) (2005) 529. — 14. LE-TOURNEL E, JUDET R, In: ELSON RA (Ed) *Fractures of the acetabulum*, 2nd ed. (New York, Springer-Verlag, 1993). — 15. BROOKER AF, BOWERMAN JW, ROBINSON RA, RILEY LH JR, *J Bone Joint Surg (Am)*, 55A (8) (1973) 1629. — 16. BACK DL, SMITH JD, DALZIEL RE, YOUNG DA, SHIMMIN A, *ANZ J Surg*, 77(8) (2007) 642. — 17. PAGNANI MJ, PELLICCI PM, SALVATI EA, *J Bone Joint Surg (Am)*, 73A (6) (1991) 924. — 18. GHALAMBOR N, MATTA JM, BERNSTEIN L, *Clin Orthop*, 305 (1994) 96. — 19. KROMANN-ANDERSEN C, SØRENSEN TS, HOU-GAARD K, ZDRAVKOVIC D, FRIGAARD E, *Acta Orthop Scand*, 51(4) (1980) 633. — 20. GEBUHR P, SOELBERG M, ORSNES T, WILBEK H, *Acta Orthop Scand*, 62(3) (1991) 226. — 21. SCHMIDT SA, KJAERSGA-

ARD-ANDERSEN P, PEDERSEN NW, KRISTENSEN SS, PEDERSEN P, NIELSEN JB, *J Bone Joint Surg (Am)*, 70A (6) (1988) 834. — 22. ELMSTEDT E, LINDHOLM TS, NILSSON OS, TÖRNKVIST H, *Acta Orthop Scand*, 56(1) (1985) 25. — 23. SEEGENSCHMIEDT MH, MAKOSKI HB, MICKE O, *Int J Radiat Oncol Biol Phys*, 51(3) (2001) 756. — 24. FRAN-

SEN M, ANDERSON C, DOUGLAS J, MACMAHON S, NEAL B, NORTON R, WOODWARD M, CAMERON ID, CRAWFORD R, LO SK, TREGONNING G, WINDOLF M, *BMJ*, 333(7567) (2006) 519.

*B. Splavski*

»J. J. Strossmayer University«, Osijek University Hospital Centre, Department of Neurosurgery, Huttlerova 4, 31000 Osijek, Croatia

e-mail: splavuno@hotmail.com

## UTJECAJ KIRURŠKOGA LIJEČENJA NA NASTANAK PERARTIKULARNIH KALCIFIKACIJA ZGLOBA KUKA U BOLESNIKA S PRIJELOMOM ACETABULA

### SAŽETAK

Cilj rada bio je istražiti utjecaj kirurškoga liječenja na nastanak periartikularnih kalcifikacija zgloba kuka u operacijski i konzervativno liječenih bolesnika s prijelomom acetabula. U retrospektivskom sedmogodišnjem istraživanju analizirana su 103 bolesnika s prijelomom acetabula. Ispitanici su bili podijeljeni u dvije skupine. Ogleđnu skupinu činio je 21 operacijski liječen ispitanik s prijelomima stražnjeg zida acetabula, dok je kontrolnu skupinu sačinjavalo 82 konzervativno liječena ispitanika sa združenim prijelomom acetabula. Promatrani su i analizirani učestalost i stupanj nastanka poslijetraumatskih periartikularnih kalcifikacija zgloba kuka, koji su zabilježeni u značajno manjem obimu u skupini kirurški liječenih ispitanika u usporedbi s ispitanicima iz kontrolne skupine, u kojoj je učestalija artroza kuka. Temeljem rezultata ovoga istraživanja može se zaključiti kako operacijsko liječenje znatno utječe na umanjenje učestalosti i stupnja periartikularnih kalcifikacija zgloba kuka u bolesnika s prijelomom acetabula.