

Coexistence of Intradural Spinal Arteriovenous Malformation and Associated Developmental Anomalies – Report of Two Cases

Srdana Telarović¹, Helena Šarac², Marija Žagar¹, Jasenka Markeljević³, Davorka Vranješ² and Marko Radoš⁴

¹ University of Zagreb, Zagreb University Hospital Center, Department of Neurology, Zagreb, Croatia

² University of Zagreb, School of Medicine, Zagreb University Hospital Center, Department of Neurology and Croatian Institute for Brain Research, »Neuron« Diagnostic Center, Zagreb, Croatia

³ University of Zagreb, School of Medicine, Zagreb University Hospital Center, Department of Internal Medicine, Zagreb, Croatia

⁴ University of Zagreb, School of Medicine, Zagreb University Hospital Center, Department of Interventional Radiology, Zagreb, Croatia

ABSTRACT

Spinal arteriovenous malformations (AVM) have been divided into dural (Type I), intramedullary glomus (Type II), juvenile (Type III), and perimedullary direct arteriovenous fistulae (Type IV). AVMs are usually associated with subacute myelopathy in what has been known as Foix-Alajouanine syndrome. We presented two patients with two intradural spinal arteriovenous malformations associated in what we call Foix-Alajouanine syndrome. The both patient developed acute back pain and paresthesias, followed by paraplegia and incontinence. The clinical status of one patient has been improved after particle embolization for a 17 years when he deteriorated up to paraplegia after spinal angiography for follow up. Clinical status in another patient deteriorated, because particle embolisation cannot be performed due to very discrete presentation of the feeding artery. Extensive neuroradiological examination in both patients revealed coexistence of numerous associated developmental anomalies in both patients. We conclude that arteriovenous malformations occasionally are associated with other vascular and nonvascular developmental anomalies elsewhere in the body. These findings rise attention about keep in mind the suspicion of mutual etiopathogenesis and congenital origin of these anomalies. Early timing of the diagnostic and therapeutic interventions are stressed to prevent or delay irreversible ischaemic myelopathy or haemorrhage. For the definitive diagnosis of spinal arteriovenous malformations and evaluation of its occlusion grade after the therapy spinal angiography is needed

Key words: spinal arteriovenous malformation, angiography, developmental anomalies, Foix-Alajouanine

Introduction

Spinal arteriovenous malformations (AVMs) are rare. In the USA on average, 299 patients were annually admitted to hospitals nationwide with the new diagnosis of spinal AVM¹. In 1992 Anson and Spetzler classified spinal cord vascular malformations by location into dural (Type I) and intradural subtypes. Intradural AVMs are further subcategorized into intramedullary glomus (Type II), juvenile (Type III), and pial or perimedullary direct arteriovenous (AV) fistulae (Type IV)^{2–4}. In contrast to dural AVFs, intradural AVMs are believed to be congenital and typically presents in younger than 30 years^{5–8}. MRI typically shows a central medullar signal enhance-

ment, initially indicative of a congestive edema and later of an irreversible infarction, as well as enlarged and tortuous perimedullary venous complexes, the condition most consistent with Foix-Alajouanine syndrome (FAS)^{2,3}. With improvements in spinal angiography and endovascular techniques, these lesions may be embolized as a primary treatment or as a complement to open microsurgical techniques^{4,9,10–14}. Intradural AVM is condition considered to be congenital, nonhereditary, and without sex or race predilection. Concomitant vascular malformations may be present such as intracranial AVM, retinal AVM, vascular malformation in the skin, oropharynx, or-

bit, lung and other locations^{15,16}. Spinal AVM occasionally are accompanied by other developmental anomalies elsewhere in the body, but it seems to be extremely rare. Anamnesis, clinical aspects, diagnosis, therapy and prognosis of congestive myelopathy caused by spinal dural fistulas were frequently studied before¹⁷, but, to our knowledge, these associations have not been systematically studied before in the terms of their causal relationship.

Case Reports

Patient 1

A 32-year-old man first developed lower limbs weakness and sphincter disturbances when he was 14 years old. He became nearly paraplegic within a short period of time. Urinary retention and stool impaction were also noticed. Physical examination in September 1989 showed sensory impairment over Th8-Th12 level, with facilitated tendon reflexes and affected muscle power. Preoperative computerized tomography (CT) of the spine from 1989 revealed extensive and global thoracic and lumbar left side scoliosis. CT of the brain exhibited giant arachnoidal cyst in the frontomedial-temporobasal region. Aortography showed congenital renovascular anomaly, twofold larger right kidney, irrigated by two very broad renal arteries and hypoplastic left kidney irrigated by one hypoplastic renal artery and appropriate renal functions. An angiography was performed and the patient was diagnosed being an arteriovenous fistula of the Adamkiewicz artery with extensive ascending and descending venous drainage. Repeated embolization of this malformation resulted in a clinically improvement and the patient was able to finish school and university, but complete recovery has not been achieved. Upon questioning, the patient recalled several episodes of bilateral leg paraparesis. In September 2006, after 10 years break, he approached to the Cancer Institute Zagreb, because of progressing spasm of the lower extremities. At angio-

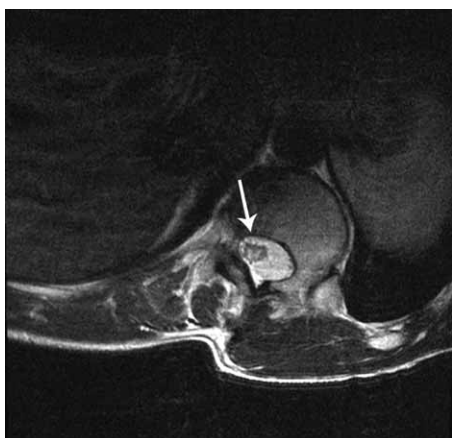


Fig. 1. Axial MRI in T2-weighted images shows atrophic thoracic spinal cord with intramedullary lesion within the conus medullaris restricted to the gray matter, consistent to the subacute myelopathy or Foix-Alajouanine syndrome (2006).

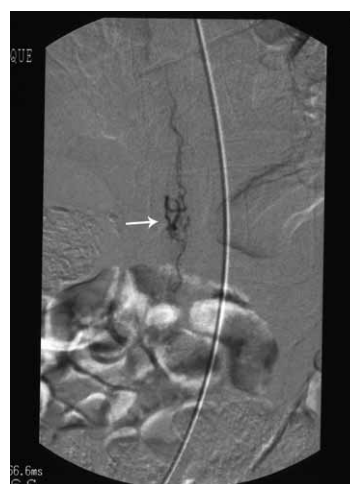


Fig. 2. Spinal angiography demonstrates arteriovenous fistula of the Adamkiewicz artery with extensive ascending and descending venous drainage (2006).

graphy, the patient experienced a sudden worsening of clinical symptoms, characterized by pain in the Th8/Th9 level followed by complete paraplegia, that did not significantly improve in the following years. At examination, in November 2007, he was wheelchair bound, cannot stand without help, complained total bowel and bladder dysfunction. Tibial SSEP N 10, N 22 as well as SSEP 40 on the right can be reproducibly elicited. P 40 on the left is slowed with 48.4 mL/sek. The upper extremities were normal. Conclusion was a lesion of the somatosensory tracts on the left. MRI of the thoracic spinal cord showed hyperintense signal gripped lateral columns of the left segments (Figure 1). Follow up spinal angiography (Figure 2) showed very gracile ascendent ramus, and hypertrophic, elongated descendent ramus with typical tortuosity in the conus medullaris which continues into intradural, perimedullary fistula. Follow up thoracolumbar MRI in January 2007 showed atrophy of the thoracic spinal cord with a reduced diameter in sagittal and transverse orientation. There was a small intramedullary lesion at the level Th7 that seems of gliotic nature. With the technique high resolution T2 weighted images show signal increase within the conus medullaris restricted to the gray matter without swelling of the cord. In the dorsal aspect of the epiconus there was a single vascular structure restricted to two axial slices without an incidence of dilated veins in the thoracic or lumbar spinal canal. Magnetic resonance arteriography (MRA) to demonstrate the anterior spinal artery in the artery of Adamkiewicz but there was no demonstration of intraspinal dilated veins. A control spinal angiography (Figure 3) of the radicular arteries from Th3 to L5 including the bronchial arteries and the iliac arteries. During intaction of the left Th9 radicular artery, there was felling of the arteries and the iliac arteries. During intaction of the left Th9 radicular artery, there is felling of the arteries of Adamkiewicz and the anterior spinal artery cranially and caudally. On its caudal course there is some elonga-

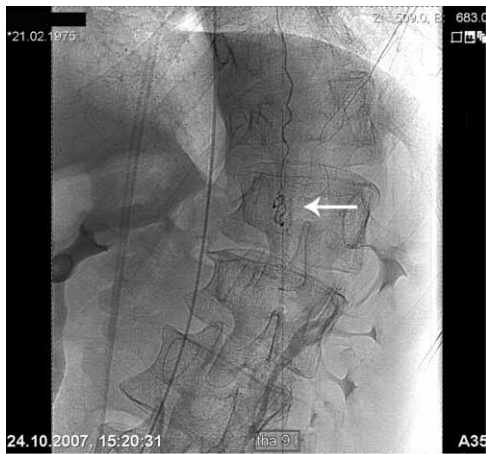


Fig. 3. Follow up digital subtraction angiography of the radicular arteries showed felling of the artery of Adamkiewicz and the anterior spinal arteries cranially and caudally during intaction of the left Th9 radicular artery. On its caudal course there is some elongation at the level of the conus and here where was a residuum of the original arteriovenous malformation.

tion at the level of the conus and here where was a residuum of the original arteriovenous malformation with a contrasting of a vein that circumflexes the epiconus and than stops. In this situation, without significant arteriovenous shunt, no selling of the spinal cord, no contrast enhancement of the spinal cord and presence of two lesions within atrophic spinal cord, there was no benefit to be expected from an occlusion of the remaining vein that circumflexes the conus. From an endovascular neurointerventional point of view any attempt to canalize the anterior spinal artery would be unsuccessfull and no benefit was expected from an occlusion of the remaining part of the AVM, because there is no significant arteriovenous shunt and no residual ascending or descending venous drainage. There was no indication for endovascular or microsurgical treatment.

Patient 2

A 59-year-old retired female with positive family of vascular malformation, currently presented with back pain, paraparesis and bowel disturbances which has been progressively worsend for a one year. There is a positive family history of central nervous system (CNS) vascular malformation. Her 11-year-old grandson with a history of headache and behavioral disturbances was recently diagnosed of venous angioma, 2 cm in diameter placed deeply in the white matter of the left frontal lobe. In our patient, there was a 15-year history of central retinal vein occlusion due to a retinal arteriovenous malformation. Within a short period, she patient became nearly paraplegic. On examination, she exhibited a flaccide paraparesis with force reduction 2/5 in all muscle groups of both legs. There was a sensory level at approximately the L1 dermatome bilaterally without sacral sparing and anal disturbances. There were marked loss of pinprick, vibration, and proprioception on both legs. There is an

kle clonus brisk tendon reflexes on both sides. Babinski sign was positive on both side. Bladder felling was present, while there was no bowel feeling. The results of the laboratory processing revealed normal range and results of coagulation studies were unremarkable including lupus anticoagulant, anticardiolipin antibodies, factor V Leiden, PCR analysis for FII 20210A for FV R506Q. Only factor VIII was significantly elevated up to 2.05 IU/L. The results of a cerebrospinal fluid (CSF) evaluation were unremarkable. MRI investigations were conducted with a 2.0 T (GE Medical Systems) and control examination with a 3.0 T imager (Siemens) at the Croatian Institute for Brain Research, School of Medicine, University of Zagreb, Diagnostic Centre »Neuron«. Thoracolumbar MRI (Figure 4, 5 and 6) in T2-weighted images showed high signal at the level Th8-Th9 and an extensive intradural extradural arteriovenous malformation ascending over the dorsal thoracic cord from Th4-Th11. Selective spinal angiography of the radicular arteries from Th4 to Th5 demonstrated very gracile interlaced of abnormal spinal cord blood vessels constituting the discrete pial AVM. As the appearance of the feeding artery and AVM

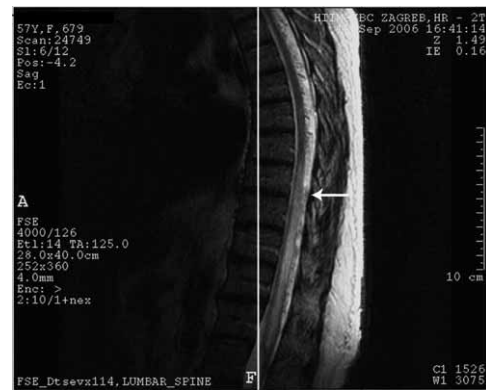

Fig. 4. Initial sagittal thoracolumbar MRI in FSE weighted images demonstrated high signal at the level Th8-th9 and an extensive intradural extradural arteriovenous malformation ascending over the dorsal thoracic cord from Th4-th11.

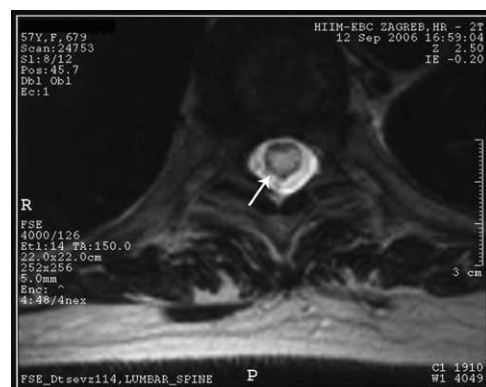

Fig. 5. Initial axial thoracolumbar MRI in FSE weighted images showed intramedullary high signal intensity at the level Th8-th9 restricted to the gray matter which is consistent to the Foix-Alajouanine syndrome.

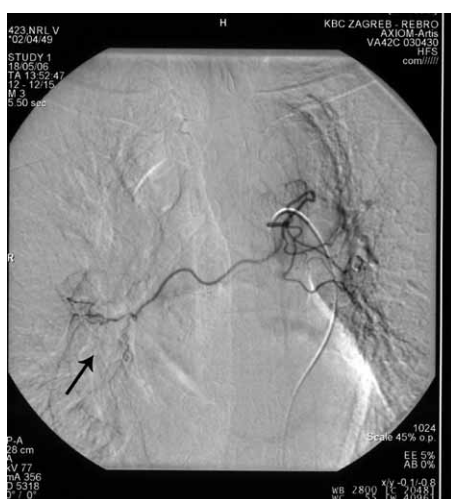

Fig. 6. Selective spinal angiography of the radicular arteries from Th4 to Th5 demonstrated very gracile interlaced of the abnormal spinal cord blood vessels constituting the discrete pial AVM.

was very discrete, endovascular embolization was not performed. Thoracoabdominal spiral CT imaging excluded aortic coarctation or any blood vessels anomaly, but demonstrated supradiaphragmal expansive mass 4,5 cm in diameter extended to Th10. Abdominal X-ray examination with contrast detected hiatal hernia protruded to the thorax. Electromyography suggested radicular or spinal lesion. Somatosensory evoked potentials (SSEP) detected serious conductional block in the both sensory fibers for nervus tibialis as well as for neuronal lesion in the sensory fiber for left side nervus tibialis, but the sensory level could not be determined. MRI of the brain has not revealed additional vascular lesions. There were no cutaneous nevi on the face or in the belonging dermatome. As the arterial endovascular embolisation could not be performed, the patient was discharged. During the two years of antithrombotic therapy (Zyllt), no further clinical decline was noted until October when she clinically deteriorated up to paraplegia after benign falls.

Discussion

In this study we analyzed the clinical features, diagnostic data and results of treatment of two spinal AVM. We studied coexistence of associated vascular and other developmental anomalies and discussed causal relationship between these conditions.

We used a classification for spinal AVM that consider the anatomical characteristics^{3,18} and haemodynamic features of AVM. MRI and selective spinal angiography were performed in the objectivization of spinal AVM as well as in detection of other developmental anomalies. In both cases presented, spinal intradural AVMs caused sub acute congestive myelopathy in what has been known as Foix-Alajouanine syndrome which reflects ischemic lesion within spinal cord which appeared as hyper intense areas in T2 weighted images, enlarged venous complexes

along the spinal cord and high blood flow in the vascular malformation^{12,17}. Endovascular embolization of the arterial feeders may potentially decrease the blood supply, decrease venous congestion, and improve spinal cord function^{7,20}.

We demonstrated the clinical symptoms, diagnostic procedure and treatment results in two patients with intradural spinal AVM. The patients material consisted of one juvenile perimedullary AVM and one pial-perimedullary AVM. In both cases MRI typically revealed enlarged intradural venous complexes and central medullary signal enhancement in T2 weighted images which correspond with subacute necrotic myelopathy due to ischemia which is fully consistent with previous results¹⁹⁻²².

The clinical status of the first patient improved after repetitive particle embolisations. Embolization targeted toward feeding artery that felt to be responsible for the symptoms (venous congestion) and resulted in complete closure of the shunt and clinical status improvement after the embolization and offered 17 years long clinical stabilisation. The clinical status deteriorated up to paraplegia after last spinal angiography for follow up.

Embolisation cannot be performed in the second patient due to a very gracile appearance of feeding arteries. Because the first patient underwent for endovascular treatment with successful result for many years and second patient did not underwent embolization, all proposed way of treatments are revised, and we have hypothesized that probably for patients with intradural AVM with good appearance of the feeding artery embolization treatment provide good benefits.

The elderly age of onset, progressive deterioration, caudal location, and intramedullary pathological appearance of the first patient is usual for a dural AV fistula^{6,7,10,11,23,24}. The intradural AVM (Type II, III, IV) intramedullary glomus, perimedullary direct AVF and juvenile AVM are probably congenital, typically appear in patient younger than 30 years and present with a vascular steal phenomenon (Foix-Alajouanine syndrome) or hemorrhage when the patient presents with sudden neurologic deterioration, a sudden onset of pain, and a distinct spinal level of neurologic dysfunction⁵⁻⁸. Rarely, patients approach due to a vascular steal phenomenon, in which arterial blood shunted through the AVM causes hypoperfusion of the surrounding parenchyma.

The first patient had Type III (juvenile-perimedullary AVM). He was diagnosed of AVM in childhood what is usual for congenital, intradural AVM^{5,7,23}. The second patient is an elderly woman, what is an unusual case, because pial, perimedullary AVMs, usually appear in young patients, considered to be congenital, developing during embryogenesis and are present in an even distribution through the spinal cord²⁶. Pial AVM of the spine represent about 8-10% of all spinal AVM and are characterized by intradural location of the shunt, constant involvement of arteries supplying the spinal cord and lack of intervening nidus in most cases. They are believed to be congenital lesions, likely to cerebral AVM, and are usually placed in lower thoracic and lumbar region. Patients

present most commonly in their second through 4th decade progressive asymmetrical radiculomedullary signs involving the lower extremities. Hemorrhage is also common. Pial AVMs (Type IV) are congenital lesions, occur in adulthood, lie completely outside the spinal cord and pia mater, fed by the anterior or posterior spinal artery, occur near the conus medullaris and cause progressive paraparesis secondary to venous hypertension. Pial AVM have been further categorized into: (Subtype 1) fistula is small and barely detectable place of change vessel's calibre, venous drainage ascends over the dorsal cervical cord and minimally dilated veins; (Subtype 2) feeding artery, shunt side and draining vein are moderately dilated and, and (Subtype 3) is a giant fistula with multiple feeding arteries and giant draining vein^{5,7,8,23}. The first and second type of AVF can be treated only surgically but results are very limited due to a significant risk of medullar ischemia, while the third type could be treated only by endovascular embolisation when the length of the feeding artery is appropriate. About half of the patient experience significant improvement after the endovascular embolisation. From the listed data, subtype 1 of the PAVM best describes our first patient and subtype 3 of the PAVM corresponded to second patient.

In order to understand and treat spinal AVMs, spinal cord vascular supply is important to understand. Cervicothoracic region receives segmental blood vessels from the vertebral arteries and the main vessels of the neck, aorta, subclavian and carotid arteries. Midthoracic region receives most of its segmental blood supply from the aorta²⁷.

In the diagnostic procedures no laboratory studies are useful for the diagnosis of spinal cord AVM. Rosendaal FR found that individuals with levels of factor VIII C exceeding ≥ 1.5 IU/L had a 3-fold increased risk compared to those with levels below ≥ 1.5 IU/L and a 6-fold increased risk compared to those with levels below 100 IU/L.²⁸ Serum profiles were within normal limits in the first patient, while second patient has had elevated factor VIII in amount of 2.05 IU/L (normal range 0.60–1.80 IU/L). Factor VIII is an independent risk factor for venous thrombosis and important prothrombotic risk factor. There are several studies reporting that high levels of factor VIII are associated with an increased risk of recurrences of thrombosis. Kraaijenhagen et al.²⁹ found that elevated levels of factor VIIIc are a significant, prevalent, independent and dose-dependent risk factor for venous thromboembolism. It is also predisposes to recurrent venous thromboembolism.

Moreover, central retinal vein occlusion associated with retinal AVM which was diagnosed in the second patient 15 years before last admission, could also correspond with increased thromboembolic risk. From the very limited literature describing complication of spinal and retinal AVM, the joint occurrence of retinal AVM and spinal AVM, has not been previously reported. Our case represents a combination of unusual and rare features in a single individual, that has not been previously reported.

A normal MRI finding of the brain was not suggestive of the Wyburn-Mason syndrome (retinoencephalofacial angiomatosis)³⁰. Clinically, there was no congenital epidermal nevus distributed in a dermatomal pattern excluding syndrome of cutaneomeningospinal angiomatosis, so called Cobb syndrome³¹. Intracranial and spinal vascular malformations have been described in association with Klippel-Trenaunay-Weber syndrome where one or multiple angiomatic nevi occur in association with limb varices and limb hypertrophy^{31,32}, but our patient has not presented neither cutaneous nevi nor limb hypertrophy.

Clark et al. reported retinal hemorrhages associated with spinal cord arteriovenous malformation³³ Rosenblum et al. concluded that associated vascular anomalies occurred only in cases of intradural AVM's suggesting their congenital origin⁵.

Since the retina is a part of the central nervous system (CNS) retinal AVM are frequently associated with intracranial vascular malformation, although other vascular malformations occasionally be found elsewhere in the body, such as spinal location. Retinal AVM are classified by Archer et al. into 3 groups^{34,35}. Group I is characterized by small arteriole-venule anastomoses, group II represents direct artery-vein communication and group III are characterized by markedly convoluted, dilated and tortuous retinal vessels. The last group best describes our patient and these patients are at higher risk for systemic vascular involvement. Retinal AVM is a rare ophthalmic condition which rarely lead to CRVO and loss of vision¹⁵. The diagnosis of CRVO can usually be made on the basis of characteristic ophthalmoscopic findings, including hemorrhage in all quadrants, dilated and tortuous veins, and cotton-wool spots. Macular edema and foveal ischemia can lead to vision loss. Ophthalmoscopic examination in our patient revealed unclear edge pupile veiled by tiny flame bleeding and edema, edematous and haemorrhaged macula, extensive retinal hemorrhages and a cotton-wool spots, suggesting an ischemic CRVO. Fluorescein angiography was not performed in the absence of the patient's consent. Functional test including visual acuity of bad eye was 1/60, a relative afferent pupillary defect (RAPD) was >1.2 log units suggesting an ischemic CRVO with a 91% and 94% certainty.

Multiple developmental anomalies in both may be better understood by addressing the embryological relationship of the involved vessels. Streeter (1942)³⁶ described periods in the development of the cerebral blood vessels in the paraxial mesoderm. Dysgenesis of the paraxial mesoderm, may caused broad spectrum of manifestations depends largely on the timing of the embryonic insult³⁷. Any defect in the mesenchymal vessels in the anterior plexus would likely affect the retina as well. The authors explained unusual association of the retinal AVM and spinal AVM by the differentiation potential of the »ectomesenchyme-neural crest« cells. Mesodermal origin of blood vessels and muscles could explain potential origin of the spinal AVM. These developmental defects may arise from a common embryonic insult. Patient

in the group of FAS are at higher risk for systemic vascular involvement.

As the multiple vascular malformation or other developmental anomalies occasionally occur elsewhere in the body, extensive radiological examination was performed in both patients. CT of the spine revealed extensive and global thoracic and lumbar left side scoliosis in the first patient, and CT of the brain exhibited giant arachnoid cyst in the frontomedial-temporobasal region. Furthermore, aortography showed congenital renovascular anomaly, twofold larger right kidney, irrigated by two very broad renal arteries and hypoplastic left kidney irrigated by one hypoplastic renal artery and appropriate renal functions. Arachnoid cysts (AC) are benign fluid collections, and they occur in the cerebrospinal axis, in 50–60% occur in the middle fossa^{38,39}. They are commonly discovered incidentally or post-mortem autopsy⁴⁰. The most are developmental anomalies, but their pathogenesis and natural course remain to be clarified.

MR of the brain revealed atrophy of the optic nerve and no other CNS AVM in the second patient. Spiral computed tomography (MSCT) ruled out associated vascular malformation in the thorax and abdomen, but a giant hiatal hernia has been detected in the same case.

Treatment options are dictated by the location of the lesion. The most important factor in determining treatment options is the presence of intramedullary or extramedullary shunting. Pial AVM that are supplied by circumferential branches of the ASA may be easily treated by embolization or surgery. Subpial AVM are usually supplied by subcommissural branches of the anterior spinal artery (ASA) and hardly to be treated.

Diagnosis is established by the history of acute and intermittent symptoms of back pain and sphincter disturbances and the imaging studies including MRI of the spinal cord and spinal angiography. Spinal angiography is the definitive diagnostic procedure in the evaluation of spinal AVM's. The preoperative evaluation is necessary and consist of detailed physical examination, laboratory processing, urodynamics evaluation, imaging studies. Type of the malformation is defined with spinal arteriography.

With ligation of the dural AVE, most patients show neurologic improvement, followed by physical rehabilita-

tion. Patient should be permanently monitored with neurologist and radiologist. The prognosis of this disease depends on the underlying etiology for the symptoms, type of AVM, recognition of the clinical syndrome, and availability of specialized techniques. Venous congestion, may block the draining veins and compromise spinal cord function. Thus embolization of the arterial feeders may potentially decrease the blood supply, decrease venous congestion, and improve spinal cord dysfunction.

One of the drawbacks of this study is a very small sample (only two patients). A more comprehensive study in investigating coexistence of spinal arteriovenous anomalies and associated anomalies need to be used by involving larger sample size of patients.

Conclusion

Traditionally thought to represent congenital malformation, the pathogenesis of some AVMs is more extensive and frequently involve heterogenous condition caused by multiple factors which may lead to vessel wall damage, thrombosis, and occlusion, and finally in ischemia due to a hypoperfusion from a steal phenomenon. Furthermore, mesodermal origin of blood vessels and muscles could explain congenital origin of the spinal AVMs, whereas these developmental defects may arise from a common embryonic insult. MRI should be the first diagnostic modality. Spinal angiography is considered if a lesion is detected and for follow up. Particle embolisation is the first-choice treatment for types II, III and IV AVM, whereas surgery may be a better option for type I AVM. The prognosis of these lesions are variable. Being aware of possible associated anomalies, patients with spinal AVM should be managed by a team of medical doctors. These patient are at higher risk especially for systemic vascular involvement, and there is a great need for systemic diagnostic evaluation, especially neuroradiological examination. We also propose the term of Foix-Alajouanine syndrome »Plus« for those patients with multiple associated deformities rather than to add new eponyms to the long list that already exist.

REFERENCES

1. LAD SP, SANTARELLI JG, ATIL CG, STEINBERG GK, BOAKYE M, Neurosurg Focus, 26 (2009) 1. — 2. CRISCUOLO GG, OLDFIELD EH, DOPPMAN JL, J Neurosurg, 70 (1989) 354. — 3. ANSON JA, SPETZLER RF, BNI Quarterly, 8 (1992) 2. — 4. KENDALL BE, LOGUE V, Neuro-radiology, 13 (1977) 181. — 5. ROSENBLUM BR (Ed) Cerebral and Spinal Arteriovenous Malformations (Hanley & Belfus, Philadelphia, 1988). — 6. SYMON L, KUYAMA H, KENDALL B, J Neurosurg, 60 (1984) 238. — 7. ROBERTS G, BRENNAN P, PIDGEON C, British Journal of Neurosurgery, 15(3) (1001) 254. — 8. MORGAN MK, Neurosurg Clin N Am, 10(1) (1999) 113. — 9. NIIMI Y, BERENSTEIN A, Neurosurg Clin N Am, 10(1) (1999) 47. — 10. NIIMI Y, BERENSTEIN A, SETTON A, NEOPHYTIDES A, Neurosurgery, 40(4) (1977) 675. — 11. SONG JK, VINUELA F, GOBIN YP, J Neurosurg Spine, 94(2) (2001) 199. — 12. VEZNEDARGLU E, NELSON P, JABBOUR P, Neurosurgery, 59(5) Suppl 3 (2006) 202. — 13. WATSON JC, OLDFIELD EH, Neurosurg Clin N Am, 10(1) (1999)

73. — 14. WYBURN-MASON R, Brain, 66 (1943) 163. — 15. WYBURN-MASON R, Brain, 66 (1963) 163. — 16. PONCE FA, HAN PE, SPETZLER RF, CANADY A, FEIZ-ERFAN I, J Neurosurg, 95 (2001) 346. — 17. KOCH C, HANSEN HC, WESTPHAL M, KUCINSKI T, ZEUMER H, Nervenartz, 69(4) (1998) 279. — 18. ZOZLYA YP, SLINKO EI, AL-QASHQISH II, Neurosurg Focus, 15 (2006) E7. — 19. RODESH G, LASJAUNIAS P, Eur J Radiol, 46 (3) (2003) 221. — 20. KÄHÄRÄ VJ, SEPPÄNEN SK, KUURNE T, LAESONEN EM, Ann Med, 29(5) (1997) 377. — 21. SCHWARTZ TH, CHANG Y, STEIN BM, Neurosurgery, 40(6) (1997) 1295. — 22. AMINOFF MJ, LOGUE V, Brain, 97 (1974) 197. — 23. ROSENBLUM B, OLDFIELD EH, DOPPMAN JL, DI CHIRO G, J Neurosurg, 67 (1987) 795. — 24. TOBIN WD, LAYTON DD, Mayo Clin Proc, 51 (1976) 637. — 25. THOMAS AM, Langman's Medical Embryology (Chapter 20) (Williams & Wilkins, Lippincott, 2006). — 26. KRAUSS WE, Neurosurg Clin N Am, 10(1) (1999) 9. — 27. OLDFIELD EH, DOPPMAN JL, Clin Neurosurg,

- 34 (1988) 161. — 28. ROSENDAAL FR, Thromb Haemost, 83 (2000) 1. — 29. KRAALJENHAGEN RA, ANKER ES, KOOPMAN MMW, REITSMA PH, PRINS MH, VAN DEN ENDE A, BULLER HR, Thromb Haemost, 83 (1999) 5. — 30. PATEL U, GUPTA SC, Neuroradiology, 31 (1990) 544. — 31. KISSEL P, DUREUX JB, Cobb syndrome, cutaneomeningospinal angiomas In: VINKEN PJ, BRUYN GW (Eds) Handbook of clinical neurology, vol 14. (North Holland Publishing Co., Amsterdam, 1972. — 32. FUKATAKE T, KAWAMURA M, MOROO I, ASAHINA M, HIRAYAMA K, Rinsho Shinkeigaku, 31 (1991) 275. — 33. CLARK RS, ATKINSON CS, TOWBIN RB, PANG D, Clin Pediatr, 34(5) (1995) 281. — 34. KHAIRALLAH M, ALLAGUI M, CHACHI, N Journal Francais d Ophthalmologie, 16(2) (1993) 117. — 35. ARCHER DB, DEUTMAN A, ERNEST JT, KRILL AE, Ophtalmol, 75(2) (1973) 224. — 36. STREETER GL, Embryol, 30 (1942) 211. — 37. LEMIRE RJ, LOESER JD, LEECH RW, ALVORD EC, Normal and abnormal development of the human nervous system (Harper & Row, New York, 1975). — 38. DI ROCCO C, CALDARELLI M, CEDDIA A, Incidence anatomical distribution and classification of arachnoidal cysts. In: RAIMONDI A, CHOUX M, DI ROCCO C (Eds) Intracranial cyst lesions (Springer-Verlag, New York, 1993). — 39. HOPKIN J, MAMOURIAN A, LOLLIS S, DUHAIME T, Br J Neurosurg, 20 (2006) 111. — 40. TSITSOPOULOS PP, PANTAZIS GC, SYRMOU EC, TSITSOPOULOS PD, Hippokratia, 12(1) (2008) 53.

H. Šarac

»Neuron« Diagnostic Centre, Croatian Institute for Brain Research, Šalata 12, 10 000 Zagreb, Croatia
e-mail: helenasarac@hi.t-com.hr

INTRADURALNA SPINALNA ATRIOVENSKA MAFORMACIJA UDRUŽENA S RAZVOJNIM ANOMALIJAMA: PRIKAZ DVA SLUČAJA

SAŽETAK

Spinalne arteriovenske malformacije su klasificirane u intraduralne (Tip I), intramedularni glomus (Tip II), juvenilne (Tip III) i perimedularne direktne arteriovenske fistule (Tip IV). Arteriovenske malformacije su obično udružene sa subakutnom mijelopatijom u sindromu Foix-Alajouanine. U ovoj studiji, opisuju se dijagnostičke i terapijske procedure u dva bolesnika sa spinalnom arteriovenskom malformacijom i Foix-Alajouanine sindromom. Oba bolesnika u početku su imali simptome akutne boli u leđima i parestezije, a potom se stanje klinički pogoršalo do potpune paraplegije i inkontinencije. Jedan bolesnik bio je klinički stabilan 17 godina nakon višekratnih postupaka endovaskularne embolizacije, ali je nakon zadnjeg rutinskog postupka kontrolne spinalne angiografije doživio kliničko pogoršanje do potpune paraplegije, vjerojatno uslijed vazospazma. Kod drugog bolesnika klinički status se progresivno pogoršavao do parapareze budući da se terapijska endovaskularna embolizacija nije mogla provesti zbog izrazito diskretne prezentacije »hranidbenih« arterija. Opsežna radiološka obrada u oba bolesnika otkrila je niz konkomitantnih razvojnih anomalija. Iz ovih podataka možemo zaključiti da spinalne arteriovenske malformacije mogu ponekad biti udružene s drugim krvožilnim i drugim razvojnim malformacijama, ne samo u centralnom živčanom sustavu nego u bilo kojem dijelu tijela. Iz toga slijedi da kod bolesnika kod kojih se objektivizira spinalna arteriovenska malformacija, treba biti učinjena šira dijagnostička obrada. Iz ovoga se također može pretpostaviti da bi ove anomalije mogle imati zajedničku etiopatogenezu koja sugerira kongenitalno porijeklo i uzroke ovih razvojnih anomalija. Rana dijagnostika i terapijski postupci mogu spriječiti ili odgoditi ireverzibilnu ishemijsku mijelopatiju ili hemoragiju. Za konačnu dijagnoszu spinalnih arteriovenskih malformacija i evaluaciju okluzija nakon terapijskog postupka neophodna je spinalna angiografija.