

Infantile Spasms in Children with Down Syndrome

Lucija Lujic¹, Vlatka Mejaški Bošnjak¹, Sanja Delin², Vlasta Đuranović¹ and Goran Krakar¹

¹ University of Zagreb, Zagreb Children's Hospital, Department for Child Neurology, Zagreb, Croatia

² Zadar General Hospital, Pediatric Department, Zadar, Croatia

ABSTRACT

Down syndrome (DS) is the most common genetic cause of mental retardation. It is estimated that 5–13% of persons affected by DS have seizures. Infantile spasms are the most common type of seizures and usually are well controlled with steroids and antiepileptic drugs. We present 11 children at the age of 3 years and 4 months to 10 years and 7 months with DS and infantile spasms, treated at Children's Hospital Zagreb from January 2000 until July 2009. Infantile spasms began at the age of 5 to 10.5 months in 10 children, in one child at the age of 16 months. Only one child had perinatal risk factors for the development of IS. Changes in EEG correlated to hypsarrhythmia. Infantile spasms were treated initially with antiepileptic drugs, most often with valproic acid. Treatment was inefficient in 10/11 patients. After application of ACTH, infantile spasms stopped between 7 and 15 days in 6 patients, until 28th day in 4 patients. Hypsarrhythmia vanished in all children. During follow-up period (2 years and 7 months to 9 years and 5 months) none of the children developed another type of seizures. No major epileptogenic changes were registered in EEG. Antiepileptic therapy was discontinued in 4 children (aged 4 years and 2 months to 5 years). In this group is the boy who died of heart failure. Infantile spasms associated with DS are categorized into symptomatic group. The existence of cerebral pathology and delayed psycho-motor development precedes occurrence of seizures. It is possible to achieve good control of seizures and disappearance of hypsarrhythmia with application of ACTH and antiepileptic drugs.

Key words: infantile spasms, Down syndrome, antiepileptic drugs, hypsarrhythmia, ACTH

Introduction

Down syndrome (DS) is the most common genetic cause of intellectual disability. It is a chromosomal disorder caused by defect in cell splitting. In 95% of the patients exists a regular form of trisomy 21 caused by inherent chromosomes, translocation form in 3–4% and the mosaic form in 1–2% of patients. In addition to the typical phenotypic features and intellectual disability, in patients with DS there is greater incidence of congenital hypothyroidism, deafness, congenital heart defects, visual disturbances, immune deficits and malignant disease than the general population. It is estimated that 5–13% of persons suffering from DS have convulsions^{1–4}. Higher incidence is found in children younger than one year². Particularly high is the incidence of infantile spasms^{1–5}. Among the etiological factors associated with infantile spasms (IS), 1% belongs to DS⁶. Infantile spasms in DS can be subtle or very mild, which makes diagnosing somewhat difficult⁷. Although the IS in children with DS are categorized in symptomatic group, by implementing antiepileptic drugs and adrenocorticotropic hormone

(ACTH), good control of seizures and disappearance hypsarrhythmia is achieved^{4,5,8,9}.

The aim of this paper is to present 11 children with Down syndrome who had IS seizure type, their course of disease, the effect of corticosteroid therapy and outcome.

Materials and Methods

Since January 2000 – July 2009 in Zagreb Children's Hospital, 11 children (9 male and 2 female) suffering from Down's syndrome have been treated. All children were referred to the Clinic because of infantile spasms. Five children began treatment in other hospitals, prior admittance to our hospital. Despite oral antiepileptic therapy they received (valproic acid, vigabatrin, topiramate, lamotrigine), seizures repeated, and they were referred to our Clinic for corticosteroid therapy.

The children are now at the age of 3 years and 4 months to 10 years and 7 months. All patients were pro-

spectively followed during period of 2 years and 7 months to 9 years and 5 months. Follow-up of one boy aged 4 years and 3 months was discontinued because of death.

Results

Clinical characteristics of our patients are shown in Table 1. Ten children were born after full gestation and one child was born in the 34th week of gestation (patient 1). Two children had intrauterine growth retardation, one of them with heart defect *AV canalis communis* (patient 6), and the other with pulmonary artery stenosis, hemodynamically insignificant (patient 10). Assessment of the vitality of newborn in the 1st and 5th minute after birth was made using the Apgar score. One child with *AV canalis communis* heart disease had abnormal Apgar score in 1st and 5th minute after birth (patient 6), one child only in 1st minute (patient 8), and 9 other children had normal Apgar score. Because of premature rupture of amniotic membrane and amniotic fluid leak during the period of 7 hours before birth with increasing inflammation parameters, patient 11 received antibiotic treatment. Causative pathogen was not bacteriologically proven.

All children had dysmorphic features typical of Down syndrome at birth. Cytogenetic analysis demonstrated a regular trisomy 21st. Two children have karyotype 47, XX+1 (patients 5 and 11), the other nine have karyotype 47, XY+1.

Congenital heart disease was found in 9/11 children. There was no need of surgical treatment in 8/9 children, because the shunt had no evident affect on hemodynamics. In one child (patient 6) surgical correction of heart disease (*AV canalis communis*) was required. The first surgery was performed at the age of 6 months (1.5 months before the infantile spasms), and the second at age of 3 years and 4 months. After the first surgery there was no prolonged hypoxia. This child died at age of 4 years and 3 months due to cardiopulmonary failure.

Only one child (patient 5) has a positive family history of epilepsy in second-degree relative. Before IS not one child had any other types of attacks.

Infantile spasms began at the age of 5 to 10.5 months in 10 of our patients, in one child at the age of 16 months (patient 10). Seizures repeated daily, often in clusters several times a day, while awake, often after awakening, as flexion type. In one child IS were very mild (patient 9).

Only one child had perinatal risk factors for the development of IS. It is a male child with intrauterine growth retardation, induced birth at 37 weeks of gestation, birth weight 2150 g, birth length 47 cm, Apgar score 6/7 and *AV canalis communis* heart disease, which is surgically treated (patient 6). Perinatal factors in some of our patients were low risk for the development of IS.

All children had abnormal EEG in term of hypsarrhythmia. During treatment hypsarrhythmia disappeared in all patients (Figure 1a and 1b). Neuroimaging analysis

TABLE 1
CLINICAL CHARACTERISTICS OF OUR PATIENTS

Patient N/Sex	Age Yr:mo	Perinatal history	Age at onset of IS (mo)	EEG	Treatment	IS duration before/after ACTH	Follow up Y:m/Seizure	Current th
1/M	10:7	GA 34; elev. bil.; PT	6.5	HA	VGB. LTG. VPA. CZP	9.5 mo	9:4/No	No
2/M	10:7	GA 38; elev. bil.; PT	5.5	HA	VGB. LTG.TPM. VPA. ACTH	10 mo/10d	9:5/No	No
3/M	5:7	GA 38; VSD; ASD II	10	HA	VPA. VGB. ACTH	7 mo/12 d	4:3/No	VPA
4/M	4:7	GA 39; ASD II (FOA)	5	HA	VGB. VPA. ACTH	1 mo/10 d	4:1/No	VPA
5/F	3:4	GA 39; ASD II	6	HA	VPA. ACTH	3 mo/7 d	2:7/No	VPA
6/M	*	GA 37; Apgar 6/7; IUGR; A-V canalis communis	7.5	HA	VPA. ACTH	4 mo/28 d	4:3/No	*
7/M	7:6	GA 40; elev. bil.; PT; FOA	7.5	HA	VPA. ACTH. VGB	3.5 mo/28 d	6:9/No	No
8/M	5:1	GA 38; Apgar 7/8; DAP	10.5	HA	VPA. ACTH	1.5 mo/22 d	4:1/No	VPA
9/M	4:2	GA 38; FOA	5.5	HA	VPA. ACTH	2 mo/15 d	3:6/No	VPA
10/M	4:10	GA 38; IUGR	16	HA	VPA. ACTH	1 mo/10 d	3:5/No	VPA
11/F	4:1	GA 37; SC; elev. bil.; PT; VSD; ASD II	8.5	HA	VPA. ACTH	5 mo/17 d	3:0/No	VPA

GA – gestation age, VSD – ventricular septal defect, VPA – valproic acid, ASD – atrial septal defect, VGB – vigabatrin, FOA – foramen ovale apertus, TPM – topiramate, DAP – ductus arteriosus persistens, LTG – lamotrigine, IUGR – intrauterine growth retardation, CZP – clonazepam, ACTH – adrenocorticotropic hormone, HA – hypsarrhythmia

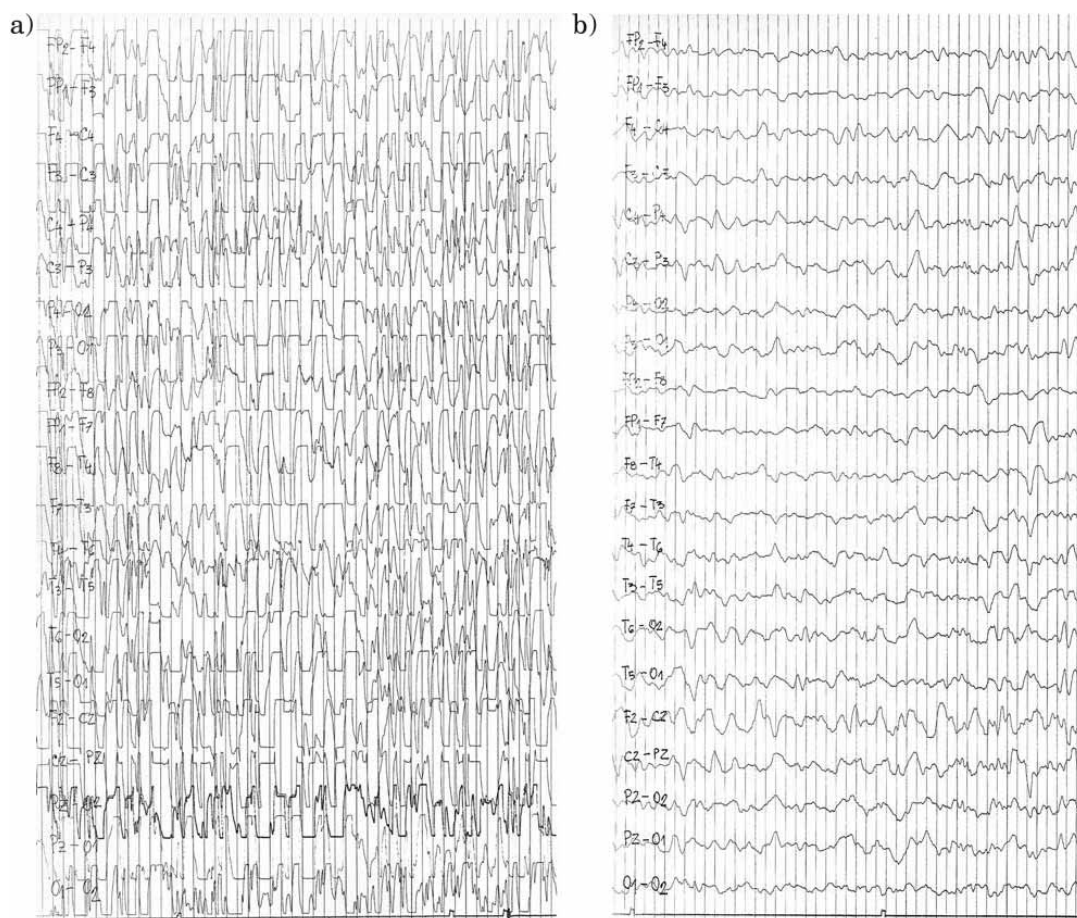


Fig. 1a and 1b. EEG of patient 10 before (left) ACTH therapy showing hypsarrhythmia and after (right) ACTH therapy showing only slow brain activity but any paroxysmal abnormalities.

was done with computed tomography (CT) in 7, and magnetic resonance imaging (MRI) in 2 children. All had cortical atrophy. In two children only intracranial ultrasound was performed, which was normal (patients 1 and 9). Treatment of IS in the first 5 patients started in other hospitals (Table 1). Vigabatrin (VGB) was the initial therapy in three children (patient 1, 2 and 4). Due to the unsuccessful treatment in two children lamotrigine (LTG) was added, and in one of them topiramate (TPM). Valproic acid (VPA) was the initial therapy in two of five children (patients 3 and 5), one was added VGB. Nor in one child the cessation of seizures occurred, hypsarrhythmia persisted in EEG. The remaining six children were treated in our Hospital from the beginning of the disease (Table 1). Valproic acid was the initial therapy in all. After 8–10 days of VPA application, as the therapy failed, ACTH therapy was implemented in all 6 children and in 4 of 5 children who were initially treated in other institutions. We used a synthetic ACTH (Synachten Depot tetracosactide with zinc chloride) in a dose of 5 IU/kg body weight intramuscular every other day during period of 4 weeks in 8 children. Lower dose of ACTH, due to side effects, but also for persisting of epileptogenic potentials in EEG, one child received for 5 weeks (patient 8),

and one for 6 weeks (patient 10). In 6 children IS stopped between 7th and 15th day from the beginning of ACTH therapy, and in 4 children until 28 days of treatment.

Only one boy was not treated with ACTH. Because of contact with varicellae, ACTH was postponed. Stabilization of the disease occurred after the application of VPA and clonazepam (previous therapy with VGB and LTG was abolished).

During the application of ACTH in two children we had to reduce the dose because of arterial hypertension (patient 8) and pneumonia (patient 10). In two children (patients 4 and 5) we reduced the dose because the therapeutic effect was very good (seizure free and satisfactory improvement of EEG findings) in order to minimize the possibility of side effects.

Arterial hypertension appeared in three children during ACTH therapy, 7 had mild electrolyte imbalance (low potassium and alkalosis). Four children had mild respiratory infection, one child had bronchiolitis and three pneumonia.

During the follow-up period (from 2 years and 7 months to 9 years and 5 months), and after completing corticosteroid therapy, no child had other types of at-

tacks. On the final evaluation, in only one child EEG registered epileptogenic focal potentials (patient 8).

Antiepileptic therapy was discontinued in four children at the age of 4 years and 2 months to 5 years. Among them was a boy (patient 6) who died. Other 7 children received antiepileptic therapy at the last outpatient visit.

Discussion

Infantile spasms represent a particular type of seizures that affect axial muscles, causing flexion, extension, or mixed. Variants of IS are described, with the emphasis that they can be very subtle, isolated and obscure for long time^{7,10}. IS may present in clusters, in infancy or early childhood. In infancy are often associated with hypsarrhythmia in EEG¹¹. Spasms can be part of the epileptic syndrome, or as a separate type of seizure characteristic in some chronic epileptic conditions. Infantile spasms, hypsarrhythmia in EEG and psycho-motor retardation in development are known as West syndrome (WS)¹². According to the classification of epilepsies and epileptic syndromes of International league against epilepsy (ILAE) from 1989, WS is included in the age dependent, generalized epilepsies and syndromes, cryptogenic or symptomatic etiology¹³. Osborne et al. (2001) proposed the use of the term non-symptomatic, secession of the term cryptogenic and idiopathic, and for the etiology or cause of WS accent the relationship with primary disease¹⁴. Among the known diseases and conditions that may be associated with about 2/3 WS are chromosomal abnormalities such as DS.

We presented 11 children suffering from DS with infantile spasms. Very subtle, hardly noticeable IS were in one child. The other 10 children had a flexion type of IS.

In our group, there were significantly more male children (9/11) than female. In some studies, there was more affected males^{4,8,9,15} in other females^{16,17}. Goldberg-Stern et al. stated that of 350 people suffering from DS, aged 0–20 years, genetically confirmed, 28 (8%) had epilepsy³. Partial seizures had 13 (47%), primarily generalized tonic-clonic 6 (21%) and infantile spasms 9 (32%) children, of which 8 male and 1 female³.

Infantile spasms were reported in DS children with regular trisomy 21, as well as with translocation and mosaic form of DS^{15,16,18}. Karyotype of all our patients showed a regular form of trisomy 21st.

Infantile spasms may be precipitated by relatively common medical complication of DS: perinatal hypoxia-ischemia, infection and hypoxia due to congenital heart disease. Stafstrom and Konkal described a group of 17 children with DS who had IS. In 14 of 17 children etiology was not identified¹⁵. Two children had a perinatal hypoxic-ischemic brain damage, a third child, after surgery of congenital heart disease, also developed hypoxic brain damage¹⁵. Silva et al. described 14 children with DS who had IS. No child had perinatal brain damage, or congenital cardiomyopathy¹⁶. In our group, one child had

perinatal hypoxia and congenital heart disease that was surgically corrected 1.5 months before the start of IS. There were no complications during and even after surgery. In the majority of our patients as well as in reports from the literature, no etiological factor for IS except DS was found^{1,9,15,16,18,19}. Stafstrom (1993) presented in review article background knowledge about neuropathology and neurophysiology of the brain in DS, with special emphasis on characteristics that could increase the predisposition for seizures²⁰. Structural abnormalities include frontal and temporal lobe hypoplasia, reduction of brain volume at birth, which with increasing age reduces even more. The most characteristic finding is the narrow upper temporal gyrus. Neocortex contains 20–50% less granular cells, especially in layers II and IV. Granular cells are typical small inhibitory GABA-ergic cortical interneurons. Their reduction can change the balance in favor of excitation cortical networks. Branching of dendrites is reduced, the total number dendritic spines are smaller, and the existing have altered appearance (often with a long thin neck). Reduction in the number of spines can contribute to the emergence of abnormal tendency to seizures. Neuronal membranes are pathologically hyperexcitable due to changes in the ion channels. Although the exact mechanism for the increased tendency to seizures in children with DS is still unknown, the available facts point to a joined pathological interaction of hyperexcitable membrane properties (ion channels), changed neuronal structure (pathological dendritic spine and synaptic density is smaller) and abnormal neurotransmission inhibitors (less inhibitory interneurons)²⁰. However, since not all children with DS have seizures, most likely there are other factors involved. All our patients had epileptogenic changes in EEG. Changes corresponded to hypsarrhythmia that vanished after adding of ACTG to exiting antiepileptic drugs (AED) in 10/11 patients, and in one after oral AED (Patient 1.).

Treatment of our patients was conducted in accordance with the recommendations about the treatment of IS and WS^{21–23}. Initial treatment with VGB in 3 of our patients was not effective. Nabbout et al. reported that IS stopped within 2 weeks from the application of VGB in 4 of 5 children. During the follow-up period of 2–4 years there was no recurrence of IS or occurrence of other types of seizures. One child was excluded from the study because IS did not stop on VGB, the child was treated with corticosteroids and VPA⁹. Infantile spasms in 8 of our patients did not stop after the initial treatment with valproic acid. Only after adding of synthetic ACTH in 10 patients, disappearance of IS and hypsarrhythmia occurred. Hancock et al. (2008) analyzed the results of the treatment of IS in 14 published studies. They concluded that hormonal treatment leads to rapid disappearance of IS in the larger number of children compared to VGB, which may be drug of choice in tuberous sclerosis²⁴. Beneficial effect of vitamin B6 on IS in the Down syndrome was described. The authors believe that oral application of vitamin B6 in doses of 25–50 mg/kg/day as mono or add on therapy in combination with classic antiepileptic

drugs would be the first therapy in patients with IS and DS²⁵.

In accordance with the present knowledge on the treatment of IS, we recommend to start treatment with vigabatrin, but if the seizures do not cease to carry out the treatment with ACTH.

Our children with DS and IS have had favorable outcome. During the follow-up period (from 2 years and 7 months to 9 years and 5 months) none of our children developed another type of seizures. Three children no longer take AEDs, 7 still have therapy, and they are all on mono therapy with VPA. Antiepileptic therapy was also discontinued in a boy before his lethal outcome. On the final evaluation only one of our patients has had EEG focal epileptogenic graphoelements. Half of 14 children with DS and IS without congenital cardiomyopathy and perinatal hypoxic-ischemic insult, which are described by Silva et al., did not develop another type of seizures after the cessation of IS. The second half had other types of seizures, in which in 5 cases seizure control was rela-

tively easy accomplished with conventional antiepileptic drugs¹⁶. In the report from Stafstrom and Konkola, 3/16 children with DS and IS have persistent epilepsy¹⁵. On the final evaluation (follow-up period 11–114 months) persistent attacks had 5/18 children, reported by Eisermann et al.¹⁹. Favorable outcome in children with IS and DS is described in other reports^{17,26,27}.

Conclusion

Infantile spasms are the most common type of seizures in children with Down syndrome. According to the current classification of Epilepsy and epileptic syndromes of ILAE since 1989, IS associated with Down syndrome are categorized in symptomatic group. The existence of cerebral pathology and delayed psycho-motor development precedes occurrence of seizures. It is possible to achieve good control of infantile spasms and disappearance of hypsarrhythmia using ACTH and conventional antiepileptic drugs.

REFERENCES

1. STAFSTROM CE, PATXOT OF, GILMORE HE, WISNIEWSKI KE, Dev Med Child Neurol, 33 (1991) 191. — 2. PUESCHEL SM, LOUIS S, MCKNIGHT P, Arch Neurol, 48 (1991) 318. — 3. GOLDENBERG-STERN H, STRAWSBURG RH, PATTERSON B, HICKEY F, BARE M, GADOTH N, DEGRAUW TJ, Brain Dev, 23 (2001) 375. — 4. ESCOFET C, POO P, VALBUENA O, GASSIO R, SANMARTI FX, CAMPISTOL J, Rev Neurol, 23 (1995) 315. — 5. GUERRINI R, DRAVET C, FERRARI AR, BATTAGLIA A, MATTEI MG, SALVADORI P, GENTON P, PFANNER P, Pediatr Med Chir, 15 Suppl 1 (1993) 19. — 6. KUROKAWA T, GOYA N, FUKUYAMA Y, SUZUKI M, SEKI T, OHTAHARA S, Pediatrics, 65 (1980) 81. — 7. DONNAT JF, FRANCIS S, WRIGHT S, J Child Neurol, 6 (1991) 313. — 8. POLLAK MA, GOLDEN GS, SCHMIDT R, JESSICA AD, LEEDS N, Ann Neurol, 3 (1978) 406. — 9. NABOUT R, MELKI I, GERBAKA B, DULAC O, AKATCHERIAN C, Epilepsia, 42 (2001) 1580. — 10. APPLETON RE, Arch Dis Child, 69 (1993) 614. — 11. COMMISSION ON PEDIATRIC EPILEPSY OF THE INTERNATIONAL LEAGUE AGAINST EPILEPSY, Epilepsia, 23 (1992) 195. — 12. VASQUEZ HJ, TURNER M, Arch Argent Pediatr, 35 (1951) 111. — 13. COMMISSION ON CLASSIFICATION AND TERMINOLOGY OF THE INTERNATIONAL LEAGUE AGAINST EPILEPSY, Epilepsia, 30 (1989) 389. — 14. OSBORNE JP, LUX A, Brain Dev, 23 (2001) 677. — 15. STAFSTROM EC, KONKOLA JR, Dev Med Child Neurol, 36 (1994) 576. — 16. SILVA ML, CIEUTA C, GUERRINI R, PLOUIN P, LIVET MO, DULAC O, Epilepsia, 37 (1996) 977. — 17. TATSUNO M, HAYASHI M, IWAMOTO H, SUZUKI Y, KUROKI Y, Brain Dev, 6 (1984) 37. — 18. KAJIMOTO M, ICHIYAMA T, AKASHI A, SUENAGA N, MATSUFUJI H, FURUKAWA S, Brain Dev, 29 (2007) 44. — 19. EISERMANN MM, DELARAILLIERE A, DELLATOLAS G, TOZZI E, NABOUT R, DULAC O, CHIRON C, Epilepsy Res, 55 (2008) 21. — 20. STAFSTROM CE, Am J Ment Retard, 98 (1993) 12. — 21. RIIKONEN R, Brain Dev, 23 (2001) 642. — 22. MIKATI MA, LEPEJIAN GA, HOLMES GL, Clin Neuropharmacol, 25 (2002) 61. — 23. CVITANOVIC-ŠOJAT LJ, GJERGJA R, SABOL Z, HAJNŽIĆ TF, ŠOJAT T, Acta Med Croatica 59 (2005) 19. — 24. HANCOCK EC, OSBORNE JP, EDWARDS SW, Cochrane Database Syst Rev, 4 (2008) CD001770. — 25. CARABALLO RH, CERSOSIMO RO, GARRO F, DESLER K, FEJARMAN N, J Pediatr Neurol, 2 (2004) 15. — 26. MARKS WA, REARDEN S, WILSON S, Epilepsia, 31 (1990) 664. — 27. CARABALLO R, CERSOSIMO R, ARROYO H, FEJARMAN N, Rev Neuro, 26 (1998) 372.

L. Lujčić

University of Zagreb, Zagreb Children's Hospital, Department for Child Neurology, Klaićeva 16, 10000 Zagreb, Croatia
e-mail: lucija.lujic@kdb.hr

INFANTILNI SPAZMI U DJECE S DOWN SINDROMOM

SAŽETAK

Downov sindrom (DS) najčešći je genetički uzrok mentalne retardacije. Procjenjuje se da 5–13% osoba koje boluju od DS ima konvulzije. Infantilni spazmi najčešći su tip napadaja i obično dobro kontrolirani steroidima i antiepilepticima. Prikazujemo 11 djece u dobi od 3 godine i 4 mjeseca do 10 godina i 7 mjeseci, s DS i infantilnim spazmima, koja su liječena u Klinici za dječje bolesti Zagreb od siječnja 2000. do srpnja 2009. godine. Infantilni spazmi počeli su u dobi od 5 do 10,5 mjeseci u 10 djece, u jednog djeteta u dobi 16 mjeseci. Samo jedno dijete imalo je i perinatalne čimbenike rizika za razvoj IS. Promjene u EEG odgovarale su hipsaritmiji. Infantilni spazmi inicijalno su liječeni antiepilepticima, najčešće valproatom. Liječenje nije bilo učinkovito u 10/11. Nakon primjene ACTH infantilni spazmi su prestali između 7. i

15. dana u 6, a do 28 dana u 4 djece. Hipsaritmija se izgubila u sve djece. Tijekom perioda praćenja (2 godine i 7 mjeseci do 9 godina i 5 mjeseci) niti jedno dijete nije razvilo drugi tip napadaja. Nisu registrirane niti veće epileptogene promjene u EEGu. Antiepileptička terapija ukinuta je u 4 djece (u dobi od 4 godine i 2 mjeseca do 5 godina). U toj grupi je i dječak koji je umro zbog srčane insuficijencije. Infantilni spazmi povezani s DS spadaju u simptomatsku grupu. Pojavi napadaja prethodi usporen psihomotorički razvoj i postojanje cerebralne patologije. Moguće je postići dobru kontrolu napadaja i nestanak hipsaritmije primjenom ACTH i antiepileptika.