

Hematology Department, Emergency University Hospital, Bucharest,\*  
Hematology Department, General County Hospital, Pitesti,\*\*  
Obstetrics and Gynecology Department, Elias Emergency University Hospital, Bucharest\*\*\*

## LEUKEMIA AND PREGNANCY. NO LONGER A DANGEROUS LIAISON? – CASE REPORT AND REVIEW OF LITERATURE

### LEUKEMIJA I TRUDNOĆA. NIJE DALJE ŠTETNA POVEZANOST

*Ana-Maria Vladareanu,\* Viola Popov,\*\* Veronica Vasilache,\* Cristina Marinescu,\*  
Horia Bumba,\* Mona Zvanca,\*\*\* Diana Cisleanu,\* Madalina Begu,\* Minodora Onisai,\*  
Sinziana Radesi,\* Cristian Andrei,\*\*\* Radu Vladareanu\*\*\**

*Professional paper*

*Key words:* leukemia, pregnancy, chemotherapy, imatinib

**SUMMARY. Purpose.** Even though there are no solid data regarding chemotherapy treated leukemia during pregnancy, the results based on short series reports show that the management of such condition can be safely achieved during the second and third trimester. We present three personal cases of pregnant women treated with cytostatic agents, two of them accidentally receiving complete chemotherapy during the entire pregnancy without malformative consequences. **First case.** A 19 yrs old woman diagnosed with chronic myeloid leukemia who conceived spontaneously and mistook the pregnancy signs for a relapse of the disease. During the pregnancy she continued the treatment, receiving until the fifth month an association of Hydroxyurea and alfa-interferon and afterwards switched to Imatinib until term. She presented at 38–39 weeks and delivered by cesarean section a little girl of 3510 g in a perfect state of health. The blood count of both mother and child were normal. **Second case.** A similar situation in a young woman with lymphoblastic acute leukemia under treatment with Vincristin, Methotrexat, Purinethol. She presented in advanced spontaneous labour at 33–34 weeks and delivered a little girl of 1700 g without malformative signs and normal blood count. **Third case.** A 17 years old girl who was diagnosed with acute myeloid leukemia at 29 weeks pregnancy. She received induction chemotherapy with Ara-C, due to the significant bone marrow infiltrate and disease induced disseminated intravascular coagulopathy. She presented premature uterine contractions at 32 weeks and delivered by cesarean section a premature boy of 1750g with Apgar score 8. The infant did not present any malformation (by clinical and ultrasound examination) and the blood count was normal.

The studies have shown so far that in the case of chronic myeloid leukemia, the treatment with Imatinib was associated with 50% apparently normal live infants and that chemotherapy for acute leukemia during the second or third trimester may not require termination of pregnancy, because both remission and delivery of a normal infant are likely to be obtained.

*Stručni članak*

*Ključne riječi:* leukemija, trudnoća, kemoterapija, imatinib

**SAŽETAK. Cilj.** Uopće nema čvrstih podataka o kemoterapijom liječenim leukemijama tijekom trudnoće. Rezultati na temelju kratkih izvješća pokazuju da liječenje tijekom drugog i trećeg tromjesečja može biti uspješno obavljeno. Prikazujemo tri trudnice liječene citostaticima, dvije od njih su bez posljedičnih malformacija primale kompletnu kemoterapiju tijekom cijele trudnoće. **Prvi slučaj.** Žena od 19 godina koja je spontano zanjela i krivo shvatila znakove trudnoće kao recidiv bolesti. Tijekom trudnoće je nastavila liječenjem, primivši do petog mjeseca smjesu hidroksiureje i  $\alpha$ -interferona i zatim do termina imatinib. Javila se s 38–39 tjedana trudnoće te je carskim rezom rodila savršeno zdravu malu djevojčicu težine 3510 grama. Krvna slika majke i djeteta je bila potpuno normalna. **Drugi slučaj.** Sličan slučaj mlade žene s limfoblastičnom akutnom leukemijom, liječenom vinkristinom, metotretksatom, purinetolom. Javila se u uznapredovalom porodu s 33–34 tjedana te je rodila djevojčicu tešku 1700 grama, bez malformacija i s normalnom krvnom slikom. **Treći slučaj.** Djevojka od 17 godina kojoj je s 29 tjedana trudnoće dijagnosticirana akutna mijeloična leukemija. Primila je indukcijsku kemoterapiju Ara-C-om, zbog značajne infiltracije koštane srži te boleću uzrokovanu diseminiranom intravaskularnom koagulopatijom. S 32 tjedna počeli su trudovi te je carskim rezom rodila nedonošena dječačica težine 1750 grama s Apgar zbrojem 8. Dijete nije imalo malformacija ni klinički niti ultrazvučnim pregledom. Krvna slika je bila normalna.

Do sada su studije pokazale da kronična mijeloična leukemija, liječena imatinibom, u 50% slučajeva rezultira rođanjem zdrava djeteta te da kemoterapija akutne leukemije tijekom drugog i trećeg tromjesečja trudnoće na zahtijeva prekid trudnoće, jer se može postići remisija bolesti i rođanje normalna djeteta.

The real incidence of leukemia during gestation is not well known. It is estimated to range from 1 in 75,000 to 1 in 100,000 pregnant women. Acute forms are more

frequent than chronic ones. Among them, acute myeloid leukemias are diagnosed twice as often as acute lymphoblastic leukemias. Concerning chronic leukemias,

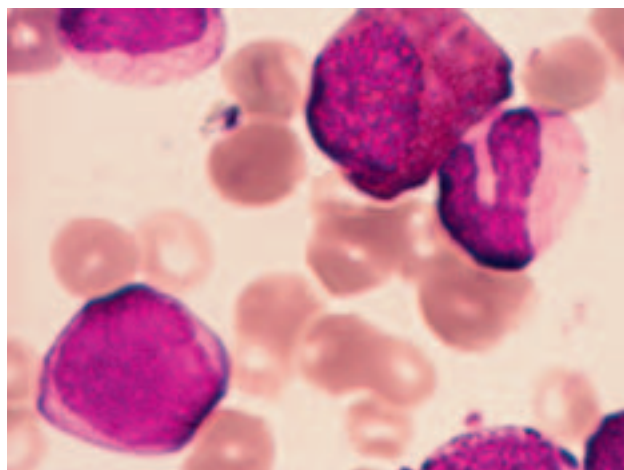


Figure 1. CML – peripheral blood: myeloblast, eosinophil-myelocyte, neutrophil band (May-Grünwald-Giemsa stain, 100×)

Slika 1. CML – periferna krv: mijeloblast, eozinofilni mijelocit, nesegmentirani neutrofil (bojanje May-Grünwald-Giemsa, povećanje 100×)

chronic myeloid leukemia (CML) accounts for less than 10% of all cases.<sup>1</sup>

Acute leukemia (AL) requiring cytotoxic treatment occurring during pregnancy poses a very difficult therapeutic dilemma. Acute leukemia during the pregnancy is associated with an unfavourable outcome.<sup>2</sup>

The coincidence of CML and pregnancy is an uncommon event, in part because CML occurs mostly in older age groups. The management of CML during pregnancy represents a difficult problem, because of the potential effects of the therapy on the mother and fetus. Although CML may not need to be treated immediately, and pregnancy does not appear to affect the course of CML, there still is a risk of leukostasis, as well as the risk of placental insufficiency with consequent low fetal birth weight, increased fetal prematurity, and increased mortality if CML is left untreated for the duration of the pregnancy.<sup>5</sup>

## Clinical cases

### Case I.

A 19 years old woman was diagnosed on October 2003 with chronic myeloid leukemia (CML). She conceived spontaneously and mistook the pregnancy signs for a relapse of the disease. At the onset she had the spleen diameter 30 cm below the costal margin. Her peripheral blood count and bone marrow aspiration suggested chronic myeloproliferative disorder. She had over 100 000 leucocytes/mm<sup>3</sup> in the peripheral blood with a typical CML features (Figures 1 and 2). Cytogenetic study showed the presence of the Philadelphia chromosome, the PCR exam finding an a2b3 BCR-ABL transcript. The treatment was initiated with hydroxyurea. After 6 months the number of the leukocytes decreased to 17 000 leucocytes/mm<sup>3</sup> and her spleen diameter was at 10 cm below the costal margin. Until May 2004 the patient was followed up monthly with clinical

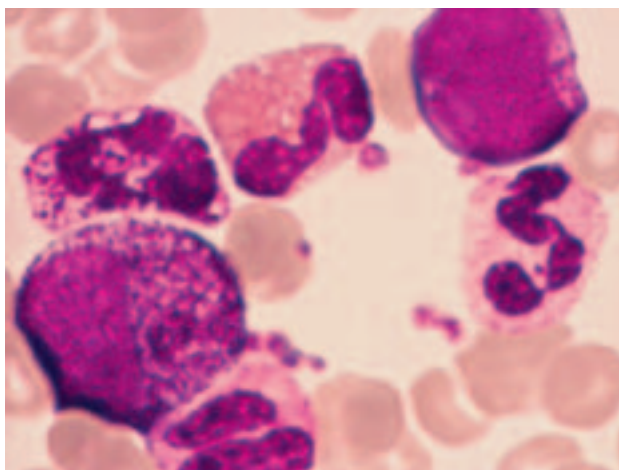


Figure 2. CML – peripheral blood: myeloblasts with cytoplasmic granules, hypergranular myelocyte, eosinophil, basophil, neutrophil band, neutrophil segmented (May-Grünwald-Giemsa stain, 100×)

Slika 2. CML – periferna krv: mijeloblasti s citoplazmatskim granulama, hipergranularni mijelocit, eozinofil, bazofil, segmentirani i nesegmentirani neutrofil (bojanje May-Grünwald-Giemsa, povećanje 100×)

and hematological exams, but than she was lost till December 2004, when she presented with giant splenomegaly and severe leucocytosis 250 000/mm<sup>3</sup>. The treatment administered was Hydroxyurea 3g/day, Ara-C 200 mg/month and Interferon 3 mil IU/day. In a few months, the leukocyte count returned to normal and the spleen was at the costal margin. This treatment schedule was maintained for one year and a half, followed by the same scheme without AraC for another almost half of year. Starting with October 2006 she was switched on Imatinib 400 mg/day.

She returned after 4 months reporting that she was followed up by her obstetrician and her last ultrasound

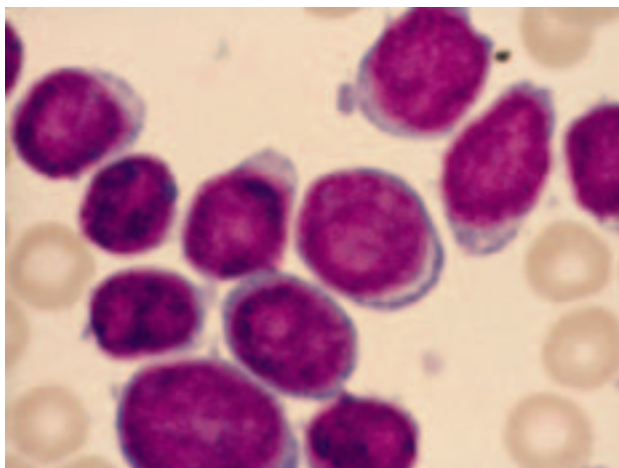
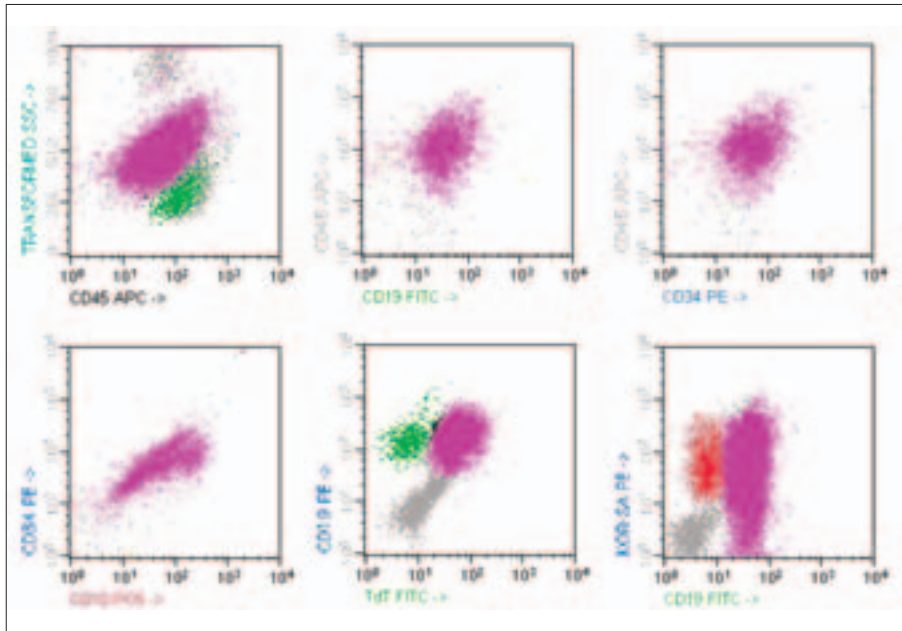


Figure 3. ALL – peripheral blood: round/oval lymphoblasts with high nuclear/cytoplasmic ratio, visible nucleoli (brighter than chromatin), basophilic cytoplasm (May-Grünwald-Giemsa stain, 100×)

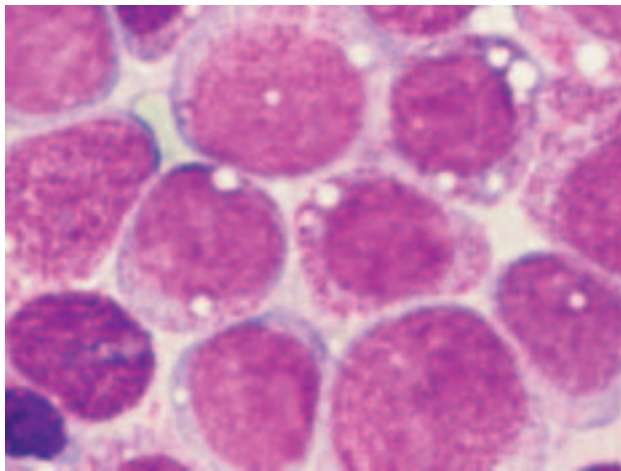
Slika 3. ALL – periferna krv: okrugli/ovalni limfoblasti s visokim nuklearno/citoplazmatskim omjerom, vidljivim nukleolima (svjetlijim od kromatina), bazofilnom citoplazmom (bojanje May-Grünwald-Giemsa, povećanje 100×)



**Figure 4.** B-ALL – Flowcytometric examination of the bone marrow aspirate, showing 84% B lymphoblasts (in violet) that are highly CD45+, CD19+ and CD10+ (B cell lineage markers), CD34+ and TdT+ (young undifferentiated cell) and KOR-SA+ [correlated with the presence of t(9;22)]; the population marked in green represents normal B lymphocytes and the population marked in red represents normal granulocytes.

*Slika 4.* B-ALL – protočna citometrijska analiza aspirata koštane srži pokazuje 84% B limfoblasta (ljubičasto) koji su visoko CD45+, CD19+ i CD10+ (B stanični linijski biljezi, CD34+ i TdT+ (mlade nediferencirane stanice) i KOR-SA+ (odgovara nazočnosti t(9,22)); populacija obojena zeleno predstavlja normalne B limfocite i populacija obojena crveno predstavlja normalne granulocite

showed a 8 month pregnancy with a normal fetus. She had not stopped Imatinib during all this period, suggest-



**Figure 5.** AML 2 – bone marrow aspirate: round/oval myeloblasts, high or relatively high nuclear/cytoplasmic ratio, fine, reticular chromatin, visible nucleoli (brighter than chromatin), vacuolated basophilic cytoplasm with azurophilic granules (May-Grünwald-Giemsa stain, 100×)

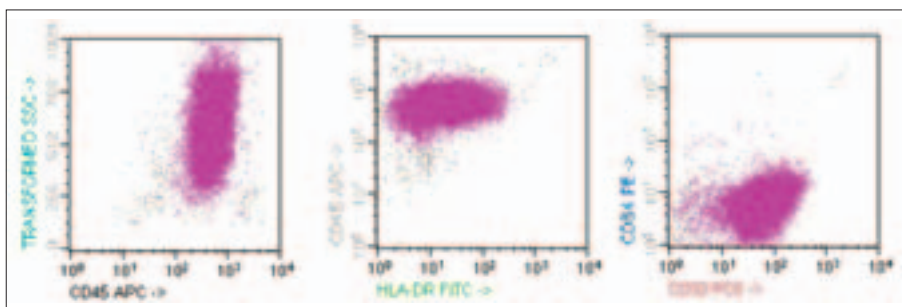
*Slika 5.* AML 2 – aspirat koštane srži: okrugli/ovalni mijeloblasti, visok ili relativno visok nuklearno/citoplazmatski omjer, fini, retikularni kromatin, vidljivi nukleoli (svjetliji nego kromatin), vakuolizirana bazofilna citoplazma s azurofilnim granulama (bojanje May-Grünwald-Giemsa, povećanje 100×)

ing that the fetus had been exposed to imatinib since the age of four months. It was decided to continue imatinib as the fetus had already been exposed to imatinib and the patient's CML was well controlled. Subsequently, the patient delivered by cesarean section a girl of 3510 g in a perfect state of health. The blood count of both mother and child were normal. At present the patient is in complete hematological remission, the cytogenetic response being unknown. This will be done in a few weeks. The baby is seven month old and she is in a good health state.

## Case II.

An 18 years old woman was diagnosed with acute lymphoblastic leukemia in May 2003. The diagnosis was made on morphological examination of the peripheral blood and the bone marrow aspirate (*Figure 3*) and was confirmed by flow-cytometry (*Figure 4*). She was in complete remission at the onset of her pregnancy. During all her pregnancy she received maintenance chemotherapy with Vincristin 2 mg/month, Methotrexat 5 mg twice weekly, Purinethol 2 mg/day, associated with occasional intrathecal injection of Methotrexat and Dexamethasone.

The diagnosis of pregnancy was established at 32 weeks. She presented in advanced spontaneous labour at



**Figure 6.** AML 2 – Flowcytometric examination of the bone marrow aspirate, showing 94% B lymphoblasts (in violet) that are highly CD45+, CD33+ (myeloid lineage marker), CD34+ (stem cell marker), HLA-DR+ partially.

*Slika 6.* AML 2 – protočna citometrijska analiza aspirata koštane srži pokazuje 94% B limfoblasta (ljubičasto) koji su visoko CD45+, CD33+ (mijeloidni linijski biljeg), CD34+ (biljeg matičnih stanica), HLA-DR+ djelomično

33–34 weeks and delivered a little girl of 1700 g without malformation signs and normal blood count. The baby is now 10 months old and is in a good health.

### Case III.

A 17 years old girl was diagnosed with acute myeloid leukemia – AML 2 (FAB) at 28 weeks pregnancy. She presented with fever, pallor, gingival hypertrophy and generalized polyadenopathy. Her peripheral blood count showed leucocytosis 24 400/mm<sup>3</sup> with 58% blast cells, low hemoglobin 7,6 g/dl and low platelets 56 000/mm<sup>3</sup>. The biochemistry showed a four-times increased LDH and the presence of D-dimers, raising the suspicion of a subacute disseminated intravascular coagulopathy and imposing a differential diagnosis with acute promyelocytic leukemia. The bone marrow was hypercellular with important infiltrate (94%) with hypergranular blast cells (*Figure 5*). Immunophenotyping revealed an atypical pattern with CD2 low positive, CD33 positive, CD34 positive, CD15 negative and HLA-DR partial positive (*Figure 6*). The diagnosis was acute myeloblastic leukemia – AML 2 (FAB). The cytogenetic exam could not be done. During the remaining pregnancy she received induction chemotherapy with Ara-C. She presented premature uterine contractions at 32 weeks and delivered by cesarean section a premature boy of 1750 g and 41 cm with Apgar score 8. The blood loss was normal during operation in spite of bone marrow aplasia after induction chemotherapy and severe thrombocytopenia (PLT 10.000/ $\mu$ l). The small boy had no malformation and the blood count was normal. Now he is 5 month and is perfectly normal.

### Discussion

The pregnancy of a patient with a neoplastic disease requiring cytotoxic treatment poses a very difficult therapeutic dilemma.<sup>3</sup> A related problem arises when a woman becomes pregnant during or shortly after chemotherapy or radiotherapy, due to the side effects of most cytotoxic agents and radiotherapy. Most information on this subject stems from animal experiments, but there are relatively few data about human abnormalities. To a large extent, the data in humans depend only on case reports. The effects of cytotoxic drugs on the fetuses may be studied from two perspectives: 1. Immediate effects, which are well known in terms of abortive and teratogenic effects; and 2. Late effects, which are less well known, the most important ones being gonadal and other endocrinological disorders, growth and developmental problems involving the central nervous system, immunosuppression and genetic and teratogenic disorders that may affect future generations. These risks are increased if the treatment is administered in the first trimester of the gestation and depend on the chemotherapeutic agents or combination of agents used.<sup>4</sup> Review of the cases receiving chemotherapy revealed no harm to the children in cases of late onset and poor prognosis for the children in cases of early onset.

However, the overall results seemed to indicate that the earlier the chemotherapy was instituted and the more appropriate the doses, the better the outcome will be for the mothers.<sup>5</sup> Once remission has been achieved, decisions regarding adjustments of the intensity of therapy must be adapted with each individual patient. Such dose alterations may diminish the mother's potential for long-term leukemia control, while possibly securing the viability of the fetus.

One study showed that hematologic tumors, which also can invade the placenta, may cross into the fetal circulation. The transmission of maternal leukemia to the fetus has been documented by immunologic similarities between the leukemic cells in the mother and those in the fetus.<sup>6</sup>

There are two important considerations in the management of a patient with leukemia during pregnancy: these are the mother, who needs optimal cancer therapy, and the developing fetus, that could potentially be affected by the disease and/or the teratogenicity of antineoplastic agents.<sup>1</sup>

Some studies showed spontaneous abortions or intrauterine death developed during combination chemotherapy (Daunorubicin, Cytarabine).<sup>7</sup> Other studies reported that infants were born prematurely, or they had low birth-weights for their gestational age. Some of them were cytopenic at birth, but other perinatal complications were not increased. One child (of present series) had obvious congenital malformations, and this same infant later developed a neuroblastoma arising in the adrenal gland and a papillary carcinoma of the thyroid.<sup>8</sup> Other fetal abnormalities included acrocyanosis, shallow sacral dimple, short digits and limbs, prominent frontal skull with mild macrognathia and membranous ventricular septal defect.<sup>5</sup> When aggressive chemotherapy is administered to the mother during the first trimester, most fetuses develop normally. With all this, the risk of placental injury, sepsis, and spontaneous abortion or premature birth is undoubtedly increased in women who experience the periodic episodes of myelosuppression that accompany leukemia treatment. Also, the drugs that preferentially interfere with rapidly growing tissues, such as methotrexate, can harm the fetus. The use of antagonists of folate, purine, or pyrimidine synthesis during organogenesis results in congenital malformations in 10 to 25 percent of fetuses, although this percent is much lower if the mother receives only single-agent therapy. Treatment after the first trimester, when structural development is largely complete, is reasonably safe in many diseases and more appropriate than postponement of the treatment for several weeks or months, until a mature infant can be delivered. Chemotherapy after the first trimester has been associated with a slightly increase in the incidence of preterm birth and fetal growth restriction and, when administered shortly before delivery, with transient neonatal myelosuppression. Nevertheless, the long-term outcomes of the children of women who received chemotherapy during the second

or third trimester are generally good. More information is needed with regard to subsequent gonadal function and the risk of cancer among children who were exposed to chemotherapeutic agents in utero, but the existing data suggest that if aggressive chemotherapy administered after the first trimester improves maternal outcome, physicians should not be reluctant to use it.<sup>3</sup> In the first trimester, termination of pregnancy should be discussed because of the potential fetal consequences of chemotherapy. Chemotherapy treatment during the second or third trimester may not require termination of pregnancy, because both the remission of the leukemia and delivery of a normal infant are likely to be obtained.<sup>3</sup>

There is limited information regarding the successful management of CML during pregnancy; most of this information arises from case reports using leukapheresis, hydroxyurea, and interferon. Hydroxyurea and Busulfan inhibit DNA synthesis and therefore have the potential to cause abortion, intrauterine growth retardation and congenital malformations. However, neither teratogenic effects nor hematologic consequences to the fetus have been reported with Hydroxyurea treatment. Busulfan crosses the placenta and causes severe stunting of growth and gonadal aplasia in the offspring of pregnant rats. Busulfan has been successfully used in CML during pregnancy, but fetal malformations have been reported. Alpha-Interferon has been used for the treatment of CML with variable success. Laboratory evidence suggests that it crosses the placental barrier and increases the incidence of abortion in rhesus monkeys. There are no reports about its adverse effects on pregnancy and on the developing fetuses in humans, but there are reports of normal infants deliveries following  $\alpha$ -interferon treatment during gestation, although it may decrease fertility due to decreases in serum estradiol and progesterone levels.<sup>4</sup>

Imatinib inhibits the tyrosine kinase of BCR-ABL and also inhibits the tyrosine kinases associated with c-ABL, ARG, the platelet-derived growth factor receptor (PDGF-r), and c-Kit. Imatinib has been found to be antiangiogenic in animal models. This effect is mediated by platelet-derived growth factor receptor (PDGFR); however, it does not affect human umbilical vein endothelial cells as they do not express PDGFR. Initially, there were safety concerns about Imatinib because the effects of these other tyrosine kinases on normal cell function were not known. The animal studies showed that it is potentially teratogenic. Male rats who received Imatinib 70 days before mating had a decrease in testicular and epididymal weights and in sperm motility. Imatinib was teratogenic in rats when administered during organogenesis at doses more than 100 mg/kg, which is approximately equivalent to a dose of 800 mg/d in adults based on body-surface area, causing anencephaly or encephalocele, and absent or incompletely developed frontal and parietal bones. Female rats that received doses of 45 mg/kg Imatinib experienced postimplantation loss, with no fetal losses at doses less than 30 mg/kg. At doses more than 100 mg/kg, total fetal loss

occurred in all animals. The most critical period for teratogenicity is the first trimester of gestation, as this period correlates with active organogenesis. According to the product label, patients who are pregnant or become pregnant while on therapy with Imatinib should be apprised for the potential hazards to the fetus. In addition, the possible effects which the exposure to anagrelide and hydroxyurea may have on the occurrence of hypospadias cannot be determined.<sup>1,4,9,10</sup>

There are few data about Imatinib effects concerning human pregnancies. They come from spontaneous reports, some clinical trials (Novartis and others) and case reports.

Some pregnancies ended with spontaneous abortion, and one patient had an elective abortion. Two of the 16 babies had minor abnormalities at or shortly after birth (hypospadias in one baby and rotation of small intestine in one baby) that were surgically repaired. Hypospadias may occur during embryogenesis when urethra develops, respectively between the eighth and twentieth weeks of gestation with an incidence of approximately 1 in 300 males. Neonatal intestinal obstruction may appear in 1 in 1,500 live births and may result from a variety of causes including intrinsic developmental defects, abnormalities of peristalsis, and other insults happening in utero after the formation of the normal bowel. All babies have continued normal growth and development.<sup>1</sup> The median weight of the babies was 5 pounds, 13 ounces (range, 5 pounds, 2 ounces to 6 pounds, 13 ounces).<sup>1</sup> Some studies reported some babies who had low birth weight. Other studies reported hydrocephalus, congenital heart defect, 2-vessel cord.

So, this information about the possible effects that cytotoxic agents may have on spermatogenesis and the eventual consequences for the developing fetus should be taken into account when talking about male patients. While on therapy with Imatinib, both males and females are advised to practice adequate contraception and to abstain.<sup>1</sup>

The largest report of women exposed to Imatinib during pregnancy in the present is on 180 cases.<sup>11</sup> Timing of exposure to Imatinib by trimester is known in 146 cases (81%), respectively: 71% in the first trimester, 3% after first trimester and 26% throughout their pregnancy.<sup>11</sup> The outcome of the pregnancies is known in 125 cases of the 180 (63%). Of these, 50%, respectively 63 cases delivered apparently normal live infants, 28% – 35 cases had elective termination (including 3 cases terminated following identification of fetal abnormalities), 14,4% – 18 cases had spontaneous abortions and 9,6% – 12 cases presented with fetal abnormalities.

The fetal abnormalities recorded were: premature closure of skull sutures (craniosynostosis) (1 case), hypoplastic lungs, exomphalos, left duplex kidney, right absent kidney, hemivertebrae, and right shoulder anomaly (1 case), exomphalos, right renal agenesis, and hemivertebrae (1 case), small exomphalos, scoliosis (1 case), communicating hydrocephalus, cerebellar hypoplasia,

atrial septal defect, overriding aorta, ascites, and pericardial effusion (1 case), stillborn meningomyelocele (1 case). The remaining cases presented: 1 cleft palate and polydactyly, 2 cases hypospadias (incidence in GP: 1/300), 1 pyloric stenosis, 1 abnormal ultrasound with raised AFP, 1 warfarin embryopathy.<sup>11</sup>

So, although the data are still not conclusive, the estimated risk of fetal abnormalities is considered 7–10%. It is currently advised to avoid Imatinib in pregnancy unless it is absolutely essential. Also, the women of child-bearing age receiving Imatinib should take adequate contraceptive measures and in case of accidental pregnancy, a risk-benefit evaluation on an individual basis should be performed. Novartis intends to establish an international pregnancy registry that may provide further information as experience with Imatinib continues to grow.

There is no evidence that pregnancy itself has any adverse effect on the course of CML, so pregnant women diagnosed with CML should not feel they must terminate their pregnancies. If a woman with CML chooses to continue her pregnancy, however, chemotherapy should probably be delayed for as long as possible, since Imatinib and Hydroxyurea may damage the developing fetus. There are also debates about the therapeutic attitude in women with diagnosed CML becoming pregnant, the implications of interruption of therapy on the outcome of the disease being unclear. In a recent report, two patients who were in complete cytogenetic and molecular remission sustained for several months, interrupted therapy to become pregnant, and both had a cytogenetic relapse as early as 3 months after discontinuation of the therapy. In other report, only three female patients out of 10 who interrupted therapy because of pregnancy, have achieved a cytogenetic response after a median of 18 months of therapy started after delivery or abortion. Thus, patients who want to interrupt therapy to become pregnant should be advised of the risk of suboptimal response or relapse even if they have already achieved a complete molecular remission. To our knowledge, there are three instances in which continuation of imatinib throughout the pregnancy has been reported. Some studies reported that five of nine female patients who were in complete hematologic remission and interrupted therapy, eventually lost remission, and six experienced an increase in Philadelphia chromosome-positive metaphases. At a median of 18 months after resuming therapy with Imatinib, eight patients achieved a cytogenetic response (complete in three patients).<sup>1,5,9</sup>

For patients with acute leukemia some reports show that pregnancy itself does not seem to affect the prognosis of the disease.<sup>3,12,13</sup>

One Italian study has reported a late relapse during the first pregnancy at the 17th week of gestation for one patient with acute lymphoblastic leukemia. A partial remission was obtained with mild chemotherapy (vincristine and prednisone) in a month, then the treatment was intensified, but only partial remission was achieved.

This case suggests that: a) pregnancy might be associated with an increased risk of relapse in women in continuous complete remission from leukemia; b) chemotherapy, even intensive, can be safely administered to pregnant women without damaging the fetus, after the first trimester.<sup>14</sup> Another study has reported that all mothers with acute leukemia and relapses but they were still alive at 15, 37, and 42 months after diagnosis. The authors feel that current chemotherapy could improve the high post-partum maternal mortality rate and the chance of producing live babies without excessive risk to the fetus or the mother, even if administered relatively early in the course of pregnancy.<sup>12</sup> In the first trimester, termination of pregnancy should be discussed because of the potential fetal consequences of chemotherapy. Chemotherapy treatment during the second or third trimester may not require termination of pregnancy, because both remission of AL and delivery of a normal infant are likely to be obtained.<sup>3</sup>

In conclusion, the association between leukemia and pregnancy represents a challenge for hematologist and obstetrician, concerning both the fetus and the mother. Although there are insufficient data regarding chemotherapy treated leukemia during pregnancy, it is considered that chemotherapy has teratogenic effects especially when administered in the first trimester of gestation, but in the second or third trimester there may be a successful outcome. Also, the long-term outcomes of the children of women who received chemotherapy during the second or third trimester are generally good. Regarding the mother, the overall results indicate that the earlier the chemotherapy is initiated and the more appropriate the doses, the better the outcome will be.<sup>5</sup>

## References

1. Ault P, Kantarjian H, O'Brien S, et al. Pregnancy among patients with chronic myeloid leukemia treated with imatinib. *J Clin Oncol*, 2006; 24(7):1204–8.
2. Aboujaoude R, Alvarez J, Alvarez M, Khan AA. Acute myelogenous leukemia mimicking a hemolysis, elevated liver enzymes, and low platelets syndrome during pregnancy: Case report and review of the literature. *Am J Perinatol* 2007;24(1):1–4. Epub 2006 Nov 8.
3. Chelghoum Y, Vey N, Raffoux E, et al. Acute leukemia during pregnancy: a report on 37 patients and a review of the literature. *Cancer* 2005;104(1):110–7.
4. Ali R, Özkalemkas F, Özkocaman V, et al. Successful pregnancy and delivery in a patient with chronic myelogenous leukemia (CML), and management of CML with leukapheresis during pregnancy: a case report and review of the literature. *Jap J Clin Oncol* 2004;34:215–7.
5. Ali R, Ozkalemkas F, Ozcelik T, et al. Maternal and fetal outcomes in pregnancy complicated with acute leukemia: a single institutional experience with 10 pregnancies at 16 years. *Leuk Res* 2003;27(5):381–5.
6. Resnik R. Cancer during Pregnancy. *New Engl J Med* 1999;341(2):1201.
7. Fassas A, Kartalis G, Klearchou N, Tsatalas K, Sinacos Z, Mantalenakis S. Chemotherapy for acute leukemia during

pregnancy. Five case reports. *Nouv Rev Fr Hematol* 1984;26(1):19–24.

8. Reynoso EE, Shepherd FA, Messner HA, Farquharson HA, Garvey MB and Baker MA. Acute leukemia during pregnancy: the Toronto Leukemia Study Group experience with long-term follow-up of children exposed in utero to chemotherapeutic agents. *Clin Oncol* 2005;5:1098–106.

9. Prabhaskar K, Sastry PSRK, Biswas GA et al. Pregnancy outcome of two patients treated with imatinib. *Annals Oncol* 2005;16(12):1983–4.

10. Choudhary DR, Mishra P, Kumar R, Mahapatra M and Choudh VP. Pregnancy on imatinib: fatal outcome with meningococci. *Annals Oncol* 2006;17(1):178–9.

11. Rosti G. Institute of Hematology and Medical Oncology »Seràgnoli« Bologna, Italy. Richard Pilot – Novartis Pharma.

12. Camera A, Campanile M, Catalano D, Mattace Raso A, Rotoli B. Relapse of acute lymphoblastic leukemia during pregnancy. *Eur J Gynaecol Oncol* 1996;17(4):303–5.

13. Chelghoum Y, Vey N, Raffoux E et al. Acute leukemia during pregnancy: a report on 37 patients and a review of the literature. *Cancer* 2005;104(1):110–7.

14. Niedermeier DM, Frei-Lahr DA, Hall PD. Treatment of acute myeloid leukemia during the second and third trimesters of pregnancy. *Pharmacotherapy* 2005; 25(8):1134–40.

*Paper received:* 18. 08. 2007.; *accepted:* 25. 03. 2008.

*Address for correspondence:* Ana-Maria Vladareanu, Chairman, Assistant Professor, Department of Hematology, Emergency University Hospital, Carol Davila University Bucharest, 169 Splaiul Independentei, 050098, Bucharest, Romania, E-mail: anamariavladareanu@yahoo.com

\* \* \*

**VIJESTI**  
**NEWS**

## 12<sup>th</sup> MEETING OF INTERNATIONAL GYNECOLOGIC CANCER SOCIETY (IGCS) Bangkok, Thailand, October 25–28, 2008

**Chairmen:** Ignace Vergote, *President IGCS*; Wui-Jin Koh, *Scientific Program*; Pornsom Hutacharen, *Local Organizing Committee*

### Highlighted topics:

Half day unopposed focused course on cervical cancer: covering screening, vaccination, staging controversy, therapeutic advances, quality of life and symptom management, resource allocation, research directions • State of the art-summary sessions in cervical, endometrial and ovarian cancer • Management of gestational trophoblastic neoplasia • Ovarian cancer – familial/genetic risk assessment and risk reduction • Breast cancer – screening, familial risk assessment, and risk reduction • Pathology and management of rare gynecologic tumors • Advances in surgical techniques, including robotics • Advances in imaging, including metabolic imaging as a predictor/early assessment for response to therapy • Emerging biologics and drug discovery • Promising basic/translational science developments • Symptom management, palliation, and quality of life • ‘Mini-symposiums’ on Pathology, Nursing and Fellows

**Free papers** should be submitted on-line to [www.kenes.com/igcs](http://www.kenes.com/igcs). The dead-line is May, 15, 2008. Abstract should have not more than 250 words. Abstract will be selected by the Scientific Committee for oral or poster presentation.

**Registration fees:** for IGCS members: before 10. Aug. 2008 US \$ 550, 10 Aug.–25 Sept. US \$ 600, after 26 Sept. US \$ 650; for participants from Bosnia-Herzegovina, Croatia, Macedonia, Montenegro, Serbia etc. US \$ 150, 200, 250.

**Hotel Prices:** For single room US \$ 110 to 230, for double room 10–15 US \$ over.

**Information:** (including registration and hotel booking): KENES International, 1-3 rue de Chantepoulet, CH- 1211 Geneva 1; [www.kenes.com/igcs](http://www.kenes.com/igcs); Fax: +41 22 732 2850; e-mail: [reg\\_igcs@kenes.com](mailto:reg_igcs@kenes.com)