

## OSTEOCHONDRITIS DISSECANS OF THE KNEE IN A SUBADULT FROM A MEDIEVAL (NINTH CENTURY A.D.) SITE IN CROATIA

Mario Šlaus<sup>1</sup>, Tatjana Cicvara-Pećina<sup>2</sup>, Ivica Lucijanić<sup>3</sup>, Marko Pećina<sup>4</sup> and Davor Stilinović<sup>5</sup>

<sup>1</sup>Department of Archeology, Croatian Academy of Sciences and Arts; <sup>2</sup>Department of Radiology, Dubrava University Hospital, Zagreb; <sup>3</sup>Department of Orthopedic Surgery, Karlovac General Hospital, Karlovac; <sup>4</sup>Department of Orthopedic Surgery, School of Medicine, University of Zagreb, Zagreb, Croatia  
<sup>5</sup>Department of Forensic Medicine, School of Medicine, University of Zagreb, Croatia

**SUMMARY** – Although osteochondritis dissecans of the knee has been known for a long time, we still do not fully understand why it develops. This prompted us to present and describe an example of osteochondritis dissecans identified in the Osteological Collection of the Croatian Academy of Sciences and Arts. The case of osteochondritis dissecans described in this report was recovered from the Gluvine kuće cemetery in the Dalmatian hinterland, approximately 28 km north-east of Split. A total of 77 graves were excavated and the individual exhibiting osteochondritis dissecans was recovered from grave number 16 that belongs to the younger phase of the cemetery that lasted during the second half of the 9<sup>th</sup> century A.D. Osteochondritis dissecans was noted in a subadult individual. The pathological changes consistent with osteochondritis dissecans are present on both medial femoral condyles. The lesion on the right femoral condyle is an oval crater-like defect with well defined margins and a porous floor of rough trabecular bone. The lesion on the left femoral condyle is basically, with two small provisions, identical to the one on the right side. The first is that it is slightly smaller, while the second is that unlike its antimer, it has a well preserved bone fragment that fits perfectly into the osteochondritic pit. Radiographic analyses of the femoral condyles support a diagnosis of osteochondritis dissecans and show a well-demarcated radiolucent defect in the articular surfaces of both joints surrounded by a thin sclerotic repair zone. According to the classification systems this degree of change corresponds to stage 3 or grade 3 osteochondritis dissecans – a detached but non-displaced fragment. Returning, for a second, to the opinion that prompted us to present this case, it is clear that during the last 1100 years there have been no significant morphological or radiological changes in the characteristics of osteochondritis dissecans.

**Key words:** *Bone diseases – history; Osteochondritis – history; Osteochondritis – etiology; Knee joint – history; History, medieval; Croatia*

### Introduction

“Although osteochondritis dissecans of the knee has been known for a long time, we still do not fully understand why it develops”<sup>1</sup>. This recently published

opinion of Eriksson prompted us to present and describe an example of osteochondritis dissecans identified in the Osteological Collection of the Croatian Academy of Sciences and Arts. The Collection founded in 1993 contains skeletons from 37 archeological sites in Croatia that cover the period from approximately 9000 B.C. to the 19<sup>th</sup> century A.D. The purported case was found at an 8<sup>th</sup> to 9<sup>th</sup> century A.D. archeological site located in the Dalmatian hinterland, approximately 28 km north-east of Split.

Correspondence to: *Marko Pećina, MD, PhD*, Department of Orthopedic Surgery, School of Medicine, Šalata 7, HR-10000 Zagreb, Croatia

E-mail: [marko.pecina@zg.t-com.hr](mailto:marko.pecina@zg.t-com.hr)

Received March 10, 2010, accepted May 3, 2010

Osteochondritis dissecans was first described in medical literature in 1558 by Ambroise Pare and later by Paget in 1870<sup>2</sup> and König in 1888<sup>3</sup> (in older medical texts the disease is often referred to as König's disease). König introduced the term 'osteochondritis dissecans', osteochondritis referring to inflammation of the joint surface, and dissecans from Latin *dissecare*, meaning to separate, and the name has persisted till today although it has been challenged as the disease is not characterized by inflammation.

Subsequent descriptions and case analysis of osteochondritis dissecans showed that two basic forms, based on the age of the patient, exist: juvenile and adult osteochondritis dissecans. Juvenile osteochondritis dissecans occurs in skeletally immature patients in whom the epiphyseal plate is still open, while adult osteochondritis dissecans occurs in individuals in whom the epiphyseal plate has completely fused with the diaphyses. The two forms have very different natural histories. Overall, the prognosis is better for the juvenile form.

The male to female ratio of osteochondritis dissecans is about 2-3:1, but the number in women rises after menopause. The disease is uncommon in patients younger than 10 and older than 50 years and most often affects individuals aged 10-25. Children younger than 10 are very infrequently involved, and those that do suffer from it are frequently obese.

In descending order, the most common sites of osteochondritis dissecans in modern populations are as follows: in the knee – on the femoral condyles or much more infrequently on the proximal tibia; in the ankle – on the proximal talus; and in the elbow – on the capitulum of the distal humerus.

Overall, approximately 80% of osteochondritis dissecans cases occur in the knee<sup>4</sup>. It is bilateral in only 20% of patients<sup>5</sup>. In osteochondritis dissecans of the knee, approximately 85%-90% of cases are found on the medial femoral condyle<sup>6</sup>, and the classic presentation is on the lateral and anterior part of the medial femoral condyle, near the attachment of the posterior cruciate ligament. The lesion usually covers an area of 2-4 cm<sup>2</sup> and contains a 5- to 10-mm thick rim of subchondral bone.

There is no consensus on the exact etiology of the disease. The initial pathologic process is a focal area of bone necrosis beneath the articular cartilage. There is

a spectrum of pathologic changes, but in a classic case the disease is associated with separation of a small, in profile view typically triangular sequestrum that consists of articular cartilage and necrotic subchondral compact and cancellous bone. In the course of the disease, this loose osteocartilaginous body (sometimes referred to as a 'joint mouse') can remodel into other shapes and sizes; in some cases it has been known to enlarge due to continuing growth of the surviving cartilage. In the most common scenario, however, it remains unchanged or is eventually resorbed. The residual bone defect (sometimes referred to as the 'mouse bed') can be covered by a thin layer of bone and is eventually surrounded by reactive bone sclerosis. It remains, however, an always visible depression on the bony articular surface.

As most modern cases of the disease are noted in young athletes, it has been postulated that trauma, especially repeated low-grade chronic or microtrauma, plays a role in the etiology of the disease. Murray *et al.* (1990) suggest, for example, that a better name for the disease would be post-traumatic subarticular necrosis<sup>7</sup>. Other contributing factors include a defect in the development of subchondral bone, and defective blood flow<sup>6,8</sup>.

In modern cases, the progression of the disease and the stage of its development is determined through various clinical, arthroscopic, radiographic, and magnetic resonance imaging (MRI) classifications<sup>9</sup>. An important aspect of modern clinical cases concerns radiographic methods used to identify the disease. Standard radiographic methods for identification of osteochondritis dissecans include the following views: anteroposterior, lateral, tunnel, and sunrise views. When osteochondritis dissecans is suspected, an intercondylar notch or tunnel view is mandatory because lesions on the posterior portion of the medial femoral condyle are commonly missed on standard anteroposterior views<sup>10</sup>. The classic radiographic appearance is that of a well-circumscribed area of subchondral bone, separated from the remaining femoral condyle by a crescent-shaped radiolucent line. Computed tomography (CT) and MRI have also been found to be helpful in the evaluation of osteochondritis dissecans. MRI is capable of detecting focal defects in articular cartilage as small as 2 mm and can differentiate *in situ versus* unstable fragments<sup>11</sup>. Bone scanning is

also used for diagnostic purposes, and for following the healing and pathologic processes. Arthroscopy directly visualizes the involved area and allows the examiner to probe the zone of involvement to determine the degree of articular cartilage separation.

In modern clinical cases, with appropriate treatment a non-displaced fragment in a skeletally immature patient can heal with no adverse side effects. In adult osteochondritis dissecans, surgical treatment is frequently prescribed with the goals of the surgery defined as: (a) to reestablish the joint surface; (b) to improve blood supply to the bone fragment; (c) rigid fixation to allow for early motion until bony union; and (d) to prevent subsequent osteoarthritis (which is the ultimate goal). Surgical treatment is minimally invasive, i.e. arthroscopic. Several operative procedures are available if it is impossible to refit the osteochondral fragment: retrograde or antegrade drilling of the condylar defect, microfractures, mosaicplasty autograft, fresh-frozen osteochondral autograft, and chondrocyte transplantation<sup>12</sup>.

## Case Report

The case of osteochondritis dissecans described in this report was recovered from the Gluvine kuće cemetery in the Dalmatian hinterland, approximately 28 km northeast of Split. Excavation of the site began in 1996 and finished in 2001. The total extension of the cemetery was investigated. A total of 77 graves were excavated, 25 of which contained archeological artifacts that allowed for precise dating of the time that the cemetery had been in use<sup>13</sup>. Two inhumation phases in the cemetery have been identified: an older phase that encompasses the whole of the 8<sup>th</sup> century A.D., and a younger phase that lasted during the second half of the 9<sup>th</sup> century A.D. The individual exhibiting osteochondritis dissecans was recovered from grave number 16 that belongs to the younger phase of the cemetery.

This phase is characterized by well defined cist-like graves made of shaped local stone plates that were interconnected by grooves and flutes. The floors of the graves were paved and the whole structure was covered by large rectangular plates. The graves were arranged in (more or less) parallel rows, and the deceased were oriented in the east (feet) to west (head) direction. While graves from the older phase were, with only

one exception, individual inhumations, those from the second phase frequently contained more than one individual. Four individuals were recovered in grave number 16: an adult male with the age-at-death of 50 to 60 years, two adult females one of which had an approximated age-at-death of 45 to 55 years and the other with the age-at-death of 25 to 35 years, and a subadult that had an age-at-death of 13.5 and 15.0 years.

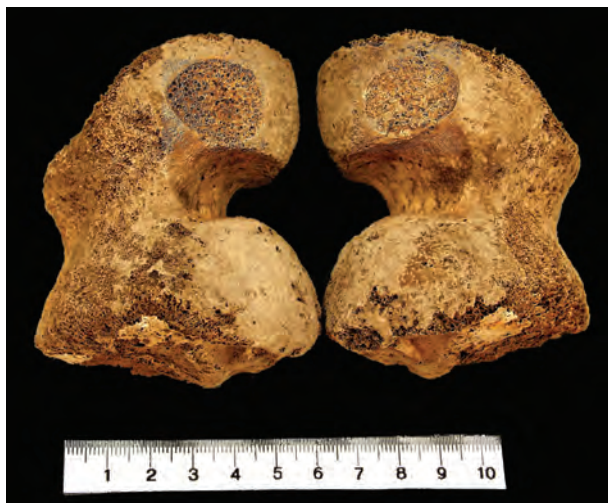
Osteochondritis dissecans was noted in the subadult individual. Preservation of the osseous material was generally good. The bones are of a homogeneous light brown-yellow color, and are reasonably well preserved.

The recovered remains were aged and sexed according to the following criteria. Sex was determined based on pelvic<sup>14</sup> and cranial morphology<sup>15</sup>. When these elements were missing or poorly preserved, discriminant functions for the femur and tibia developed for antique and medieval Croatian populations were employed<sup>16,17</sup>. No attempt was made to estimate the sex of the subadult individual.

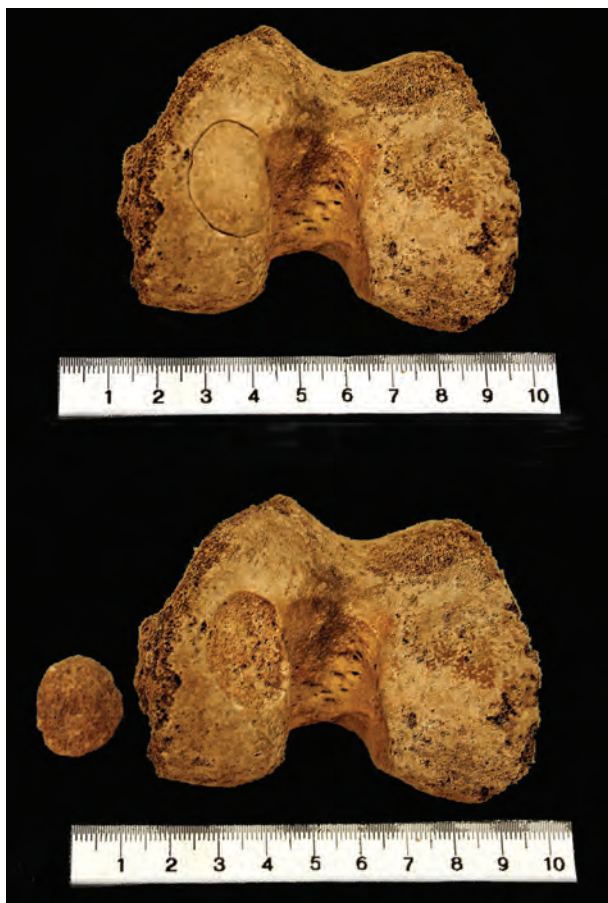Adult age at death was estimated using pubic symphysis morphology<sup>18</sup>, auricular surface morphology<sup>19</sup>, sternal rib end changes<sup>20</sup>, and ectocranial suture fusion<sup>21</sup>. The age-at-death of the subadult was estimated using epiphyseal fusion, diaphyseal lengths, and dental eruption criteria<sup>22</sup>.

Besides osteochondritis dissecans, the subadult recovered from grave number 16 exhibits three additional pathologic changes. These changes are: cribra orbitalia, a sieve-like expansion in the orbital plates of the frontal bone linked with acquired iron deficiency anemia<sup>23</sup>; linear enamel hypoplasia, a nonspecific indicator of systemic physiologic stress in subadults<sup>24</sup>; and spondylolysis of the fifth lumbar vertebra, a break in bone continuity resulting from a defect in the junction between the superior and inferior processus articularis that has been linked to trauma and overuse syndromes<sup>25</sup>. None of these changes is directly associated with the presence of osteochondritis dissecans in the knees.

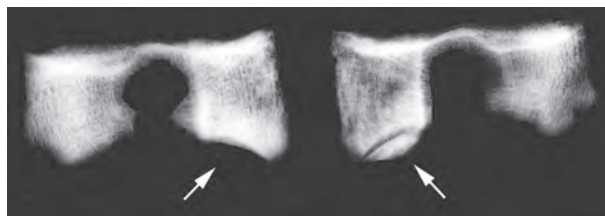
The pathologic changes consistent with osteochondritis dissecans are present on both medial femoral condyles (Fig. 1). The lesion on the right femoral condyle is an oval crater-like defect with well defined margins and a porous floor of rough trabecular bone. The defect is slightly larger than the one on the left



*Fig. 1. The lesions characteristic of osteochondritis dissecans are present on the medial femoral condyles of both knees.*



*Fig. 2. The lesion on the left femoral medial condyle has a well-preserved bone fragment that fits perfectly into the osteochondritic pit.*

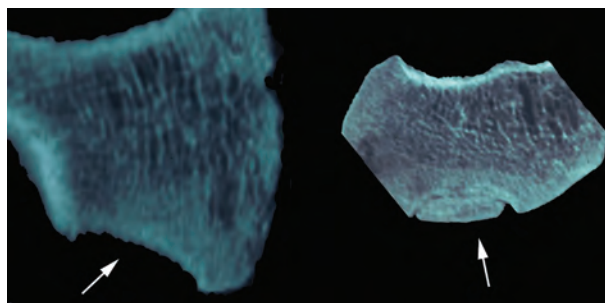


*Fig. 3. The radiological appearance of the lesions made with computed tomography in horizontal direction on both medial femoral condyles is typical for osteochondritis dissecans. The osteochondral lesions are marked with arrows.*

side with an anteroposterior diameter of 24 mm and a transverse diameter of 19 mm. Careful analyses of all of the recovered osseous material from the grave failed to identify the displaced bone fragment. The lesion on the left femoral condyle is basically, with two small provisions, identical to the one on the right side. The first is that it is slightly smaller, with an anteroposterior diameter of 22 mm and a transverse diameter of 18 mm, while the second is that unlike its antimere, it has a well preserved bone fragment that fits perfectly into the osteochondritic pit (Fig. 3 and 4).

Radiographic analyses (CT) of the femoral condyles support the diagnosis of osteochondritis dissecans and show a well-demarcated radiolucent defect in the articular surfaces of both joints surrounded by a thin sclerotic repair zone (Figs. 3-4).

According to the classification systems of Cahill<sup>26</sup> and Berg, this degree of change corresponds to stage 3 or grade 3 osteochondritis dissecans, a detached but non-displaced fragment.



*Fig. 4. Radiological presentations made with computed tomography in sagittal direction of the medial femoral condyles of both knees. The osteochondral lesions are marked with arrows.*

## Discussion

In terms of differential diagnosis, very few reasonable alternative causes for the defects noted in the distal femurs of the analyzed subadult are possible. As previously noted, the most frequent localization of osteochondritis dissecans in modern populations is on the medial femoral condyle and this is consistent with the location of the defects in the subadult from grave 16. The lesion is bilateral in approximately 20% of cases, so the bilateral presence of the defects is not an eliminating factor. The age-at-death of the subadult from Gluvine kuće of 13.5 to 15.0 years is compatible with the period during which the development of osteochondritis dissecans is most common. In modern populations, osteochondritis dissecans most commonly affects patients between 10 and 25 years of age<sup>6</sup>. Theoretically, the defects could be the result of trauma, but the absence of any type of defect on the preserved bone fragment, the absence of fracture lines surrounding or leading from the defects, and the identical morphology and location of the defects on both medial femoral condyles makes this highly unlikely.

In terms of the etiology of the disease, a few familial cases have been reported in which osteochondritis dissecans appears to have been transmitted in an autosomal dominant pattern, but in these cases the disease usually affects multiple joints<sup>27</sup>. Most cases are limited to one joint and are thought to result from: (a) exogenous trauma; (b) endogenous trauma; (c) repetitive stress; (d) ischemia; and (e) abnormal ossification within the epiphysis. Significant knee trauma is found in approximately 50% of patients with osteochondritis dissecans. Endogenous trauma, patellar dislocations, or instability syndromes have also been associated with the disease. Repetitive stress caused, for example, from patellar impingement of the medial femoral condyle in extension, or impingement of the medial femoral condyle by the tibial spine is also a possible cause of osteochondritis dissecans.

Given that repetitive stress and various types of trauma are strongly correlated with the development of the disease, it is interesting that osteochondritis dissecans is rarely described in skeletal remains from archeological contexts. One could reasonably expect that the lifestyle of most archeological populations, with its heavy emphasis on continuous manual labor, is conducive to elevated levels of the disease. So far,

however, this has not been the case. An interesting example of bilateral osteochondritis dissecans on the humeral trochleae in a 17<sup>th</sup> century helmsman from the Swedish warship VASA has been reported and interpreted as an occupational lesion<sup>28</sup>. Schulz<sup>29</sup> noted osteochondritis dissecans in 17 individuals from a 6<sup>th</sup> to 8<sup>th</sup> century A.D. Merovingian German populations, while Martin Oval and Rodriguez-Martin report high frequencies of the disease in the ancient inhabitants of the Tenerife Canary islands<sup>30</sup>.

Wells<sup>31</sup> found osteochondritic lesions to be more frequent in Romano-British and Anglo Saxon populations than in the earlier Bronze Age populations from Britain, and interpreted this dichotomy as a result of differing lifestyles. The Bronze Age populations that inhabited Britain were primarily pastoralists while the Romano-British and Anglo Saxons had a subsistence strategy largely based on agriculture, a lifestyle that necessitated a considerably greater amount of strenuous physical labor. In this context, it is interesting to note that recent bioarcheological analyses of Early Medieval Croat populations suggest they had a very similar lifestyle<sup>32,33</sup>. According to these studies, as well as to the archeological and historical data available, the Early Medieval Croat populations that settled the Dalmatian hinterland in the 8<sup>th</sup> century had a subsistence strategy primarily based on agriculture and, therefore, faced not only all of the challenges encountered by the Romano-British and Anglo Saxons, but also challenges specific to populations trying to earn a living in the inhospitable karst formations that characterize this part of Croatia. The simultaneous presence of cribra orbitalia, linear enamel hypoplasia, spondylolysis, and bilateral osteochondritis dissecans in the subadult from Gluvine kuće shows just how arduous this challenge was.

Returning for a while to the opinion of Eriksson<sup>1</sup>, which prompted us to present this case, it is clear that during the last 1100 years there have been no significant morphological or radiological changes in the characteristics of osteochondritis dissecans. A future goal is to analyze the frequency and distribution of this disease in Croatian archeological populations from an epidemiological point of view.

**Acknowledgment.** The study was financially supported by a grant from the Ministry of Science, Education and Sports of the Republic of Croatia (grant number 101-197-0677-0670).

## References

- ERIKSSON E. Long term prognosis of osteochondritis dissecans of the knee. *Knee Surg Sports Traumatol Arthrosc* 2008;16:435.
- PAGET J. Of the production of some of the loose bodies in joints. *St. Bartholomew's Hospital Reports* 1870;6:1-4.
- KÖNIG P. Über freie Körper in den Gelenken. *Dtsch Z Chir* 1888;27:90-109.
- ROBERTS C, MANCHESTER K. The archaeology of diseases, 3<sup>rd</sup> ed. New York: Cornell University Press, 2005.
- MUNOZ GOMEZ J. Osteonecrosis y fracturas de marcha (Osteonecrosis and fatigue fractures). In: Rotés Querol J, editor. *Reumatología clínica (Clinical rheumatology)*, Vol. 2. Barcelona: Expans, 1983:408-17.
- AUFDERHEID AC, RODRIGUEZ-MARTIN C. The Cambridge encyclopaedia of human paleopathology. Cambridge: Cambridge University Press, 1998.
- MURRAY RO, JACOBSON HG, STOCKER DJ. The radiology of skeletal disorders, Vol. 1. Fundamentals of skeletal radiology, 3<sup>rd</sup> ed. London: Churchill Livingstone, 1990.
- ORTNER DJ. Identification of pathological conditions in human skeletal remains. New York: Academic Press, 2003.
- PEĆINA M, HAŠPL M. Koljeno i potkoljenica. In: Pećina M, *et al.*, editors. *Ortopedija*, 3<sup>rd</sup> ed. Zagreb: Naklada Ljevak, 2004.
- BROWDY JA, NEUMANN RD. Osteochondritis dissecans of the knee. In: Brown DE, Neumann RD, editors. *Orthopedic secrets*, 3<sup>rd</sup> ed. Philadelphia: Hanley and Belfus, 2004: 349-53.
- LEFORT G. Osteochondrite dissequante des condyles femoraux. *Rev Chir Orthop* 2006;92:2S99-2S102.
- BRUNS J, RAYF M, STEINHAGEN J. Longitudinal long-term results of surgical treatment in patients with osteochondritis dissecans of the femoral condyles. *Knee Surg Sports Traumatol Arthrosc* 2008;16:436-41.
- PETRINEC M. Dosadašnji rezultati istraživanja ranosred-njovjekovnog groblja u Glavicama kraj Sinja kao prilog razrješavanju problema kronologije starohrvatskih grobalja. *Opuscula Archaeologica* 2002;26:205-46.
- BASS WM. Human osteology. A laboratory and field manual of the human skeleton. Columbia, MO: Missouri Archaeological Society, 1987.
- KROGMAN WM, ISCAN MY. The human skeleton in forensic medicine, 2<sup>nd</sup> ed. Springfield, IL: C.C. Thomas, 1986.
- ŠLAUS M. Discriminant function sexing of fragmentary and complete femora from medieval sites in continental Croatia. *Opuscula Archaeologica* 1997;21:167-75.
- ŠLAUS M, TOMIČIĆ Ž. Discriminant function sexing of fragmentary and complete tibiae from medieval Croatian sites. *Forensic Sci Int* 2005;147:147-52.
- BROOKS S, SUCHEY JM. Skeletal age determination based on the os pubis: a comparison of the Acsjdi-Nemeskéri and Suchey-Brooks methods. *Hum Evol* 1990;5:227-38.
- LOVEJOY CO, MEINDL RS, PRYSBECK TR, MENSFORTH RP. Chronological metamorphosis of the auricular surface of the ilium: a new method for the determination of age at death. *Am J Phys Anthropol* 1985;68:15-28.
- ISCAN MY, LOTH SR, WRIGHT RK. Age estimation from the rib by phase analysis: white females. *J Forensic Sci* 1985;30:853-63.
- MEINDL RS, LOVEJOY CO. Ectocranial suture closure: a revised method for the determination of skeletal age at death based on the lateral-anterior sutures. *Am J Phys Anthropol* 1985;68:57-66.
- SCHEUER L, BLACK S. Developmental juvenile osteology. San Diego: Academic Press, 2000.
- LARSEN CS. Bioarchaeology. Interpreting behavior from the human skeleton. Cambridge, UK: Cambridge University Press, 1997.
- GOODMAN AH, ROSE JC. Assessment of systemic physiologic perturbations from dental enamel hypoplasias and associated histological structure. *Yrbk Phys Anthropol* 1990;33:59-110.
- PEĆINA M, BOJANIĆ I. Overuse injuries of the musculo-skeletal system, 2<sup>nd</sup> ed. Boca Raton: CRC Press, 2003.
- CAHILL BR. Osteochondritis dissecans of the knee. Treatment of juvenile and adult forms. *J Am Acad Orthop Surg* 1995;3:237-47.
- BULLOUGH PG. Atlas of orthopedic pathology with clinical and radiologic correlations, 2<sup>nd</sup> ed. New York: Gower Medical Publishers, 1992.
- DURING E, ZIMMERMAN MR, KRIKUN ME, RYDBERG J. Helmsman's elbow: an occupational disease of the seventeenth century. *J Paleopathol* 1994;6:19-27.
- SCHULZ M. Aseptic bone necrosis found in the skeletal material from the Merovingian cemetery of Kleinjangleim, southern Germany. *Paleopathol Newslett* 1981;34:7-9.
- MARTIN OVAL M, RODRIGUEZ-MARTIN C. Osteochondritis dissecans among the Gauche population of Tenerife (Canary Islands). *HOMO* 1994;45(Suppl):S83. (Abstract).
- WELLS C. Osteochondritis dissecans in ancient British skeletal material. *Med Hist* 1974;18:365-9.
- ŠLAUS M. Bioarheologija. Demografija, zdravlje, traume i prehrana starohrvatskih populacija. Zagreb: Školska knjiga, 2006.
- ŠLAUS M. Osteological and dental markers of health in the transition from the Late Antique to the Early Medieval period in Croatia. *Am J Phys Anthropol* 2008;136:455-69.

## Sažetak

## DISEKANTNI OSTEOHONDRITIS NA KOLJENU ADOLESCENTA IZ STAROHRVATSKOGA GROBLJA GLUVINE KUĆE (DEVETO STOLJEĆE N.E.)

*M. Šlaus, T. Cicvara-Pećina, I. Lucijanić i M. Pećina*

Disekantni osteochondritis, osobito onaj u području femoralnih kondila, poznat je stoljećima, ali se još uvijek raspravlja o uzrocima njegova nastanka. To nas je potaknulo da prikazemo slučaj osteochondritisa u području kondila femura iz Osteološke zbirke Zavoda za arheologiju Hrvatske akademije znanosti i umjetnosti. Kostur na kojem je nađen disekantni osteochondritis otkopan je na arheološkom nalazištu Gluvine kuće u Dalmatinskom zaleđu oko 28 kilometara sjeveroistočno od Splita. Na nalazištu je ukupno otkopano 77 grobova, a kostur s patološkim nalazom nađen je u grobu broj 16 koji se vremenski datira u drugu polovinu 9. stoljeća poslije Krista. Disekantni osteochondritis je nađen na kosturu osobe koja je u trenutku smrti imala 13,5 do 15 godina. Kostur je dobro očuvan, sa svijetlo smeđim kostima čiji je korteks imao relativno malo post-mortalnih oštećenja. Patološke promjene u smislu nalaza disekantnog osteochondritisa prisutne su na medijalnim kondilima obaju koljena. Lezija na desnom medijalnom kondilu femura imala je jasno omeđene rubove, a dno mu je činila gruba trabekularna kost. Gotovo jednaka lezija nađena je i na lijevom medijalnom kondilu, samo što je ova bila nešto manjeg promjera i, što je naročito zanimljivo, posjedovala je slobodni fragment kosti koji je točno odgovarao defektu na kondilu femura. Radiografska analiza medijalnih kondila obaju femura pokazala je karakterističnu radiolucentnu demarkacijsku liniju na zglobnoj ploštini obaju kondila okruženu sklerotičnom zonom kosti, što je tipičan radiološki nalaz kao i kod današnjih nativnih rendgenograma. U skladu s postojećim klasifikacijama u stupnjeve patoloških promjena pri postojanju disekantnog osteochondritisa u prikazanom slučaju radilo se o 3. stupnju, tj. stupnju s demarkiranim fragmentom. Na temelju našeg prikazanog slučaja može se zaključiti da u proteklih 1100 godina nije došlo do morfoloških i radioloških promjena u slici disekantnog osteochondritisa u području koljena.

**Ključne riječi:** *Bolesti kostiju – povijest; Osteochondritis – povijest; Osteochondritis – etiologija; Koljenski zglob – povijest; Povijest, srednjovjekova; Hrvatska*