

VETERINARSKI ARHIV 80 (4), 509-522, 2010

Effect of aqueous extract of *Aloe vera* on experimental cutaneous wound healing in rat

Ahmad Oryan¹, Aboutorab T. Naeini², Behrooz Nikahval^{2*},
and Effat Gorjian¹

¹Department of Pathobiology, School of Veterinary Medicine, Shiraz University, Shiraz, Iran

²Department of Surgery and Radiology, School of Veterinary Medicine, Shiraz University, Shiraz, Iran

ORYAN, A., A. T. NAEINI, B. NIKAHVAL, E. GORJIAN: Effect of aqueous extract of *Aloe vera* on experimental cutaneous wound healing in rat. *Vet. arhiv* 80, 509-522, 2010.

ABSTRACT

This study was undertaken to evaluate the wound healing properties of *Aloe vera* (*Aloe barbadensis*) on cutaneous wounds. Forty rats were randomly divided into two equal groups (control and experimental). 1.5 mL of filtered *Aloe vera* aqueous extract was used on the lesions of the experimental group. Wound contraction was measured planimetrically on day 5, 10, 15 and 20. Twenty rats (10 of each group) were sacrificed on day 10 and then histopathological and biomechanical samplings were done. The remaining animals were sacrificed on day 20. Treated animals showed a non-significant improvement in wound contraction and histopathology on day 10. Wound contraction started showing significant differences between groups from day 15 onwards. The lesions of the treated animals showed a better alignment, fewer inflammatory cells infiltration and significantly improved biomechanical properties on day 20 ($P < 0.05$). These results suggested that application of *Aloe vera* aqueous extract on open wounds induces significant wound contraction and accelerates healing.

Key words: *Aloe vera*, aqueous extract, wound healing, rat

Introduction

Proper scientific investigations on *Aloe vera* (*Aloe barbadensis* Miller) have gained more attention over the last decade due to its reputable, medicinal, pharmaceutical and food properties. *Aloe vera* (Av) belongs to the *Liliaceae* family, of which about 360 species are identified. Av is a cactus-like plant that grows readily in hot, dry climates and currently, because of demand, is cultivated in large quantities (VOGLER and ERNST, 1999). *Aloe barbadensis* Miller (Ab), one of the Av types, is the most commonly used

*Corresponding author:

Behrooz Nikahval, Department of Surgery and Radiology, School of Veterinary Medicine, Shiraz University, Shiraz, P.O. Box 1731-71345, Iran, Phone: +98 711 2286950; Fax: +98 711 2286940; E-mail: nikahval@shirazu.ac.ir

form for commercial and also therapeutic purposes in North America, Europe, and Asia (HU et al., 2003). Ab have been used as an anti-inflammatory natural agent, for treatment of ulcers, hepatitis and neoplasms, and also for wound healing. It has also been used in the traditional medicine of many cultures and said to be beneficial in the treatment of disorders such as gout, acne, dermatitis and of wounds such as peptic ulcers and burns (REYNOLDS and DWECK, 1999) and also as an anti diabetic agent (NOOR et al., 2008). Cosmetic and some medicinal products called Av gel are made from the mucilaginous tissue in the centre of the Av leaf (VOGLER and ERNST, 1999). Av contains Anthraquinone, Glycosaminoglycans, Acemannan and Carbohydrates. Anthraquinone is extracted from the plant before use (VINSON et al., 2005). It has been reported that Anthraquinone and acemannan activate macrophages, stimulate T lymphocytes and have antiviral effects (LEE et al., 2000; KIM and LEE, 1997). Antioxidative effects of Ab has been shown in several studies (LEE et al., 2000; HU et al., 2003). The antigenotoxic and chemopreventive effects of this drug have been described in several studies (HU et al., 2003). It has been reported that Av gel has angiogenic effects and causes new vessel formation in cingulated cortex and septal areas in gerbil brain after ischaemia/reperfusion injury (CHOI et al., 2002). Its depressive effects on neurotransmission, blocking axonal reflex and anti-inflammatory and analgesic effects in most body organs was already stated (FRIEDMAN and SI, 1999). It has been shown that it does not have any toxic effects on central nervous system cells in rat models (KOSIF et al., 2008). Av leaf gel was found to contain Vitamin C, E and aminoacids which are essential for wound healing (DAVIS, 1991). In order to fully understand the effects of this valuable herbal extract on wound healing a large amount of research has been recently conducted to elucidate the various therapeutic aspects of this drug on lesions of various organs (KOSIF et al., 2008; KILIÇ, 2005; CHITHRA et al., 1998a; RAMACHANDRA and RAO, 2008; SUBRAMANIAN et al., 2006). In contrast to the reported positive effects of this herb, some researchers have stated that the topical application of Av does not seem to enhance healing of the damaged skin (WILLIAMS et al., 1996). Reviews of the evidence regarding the wound healing efficacy of this herb show that the results of various pieces of research are still contradictory (VOGLER and ERNST, 1999).

Therefore, in the light of Av use as a wound healing agent in folk and modern medicine, the present study was undertaken to fully evaluate the dermal wound healing potential of this drug after topical application of its aqueous extract on experimentally induced cutaneous wounds in rat models.

Materials and methods

All the procedures were conducted in accordance with the Iranian community guidelines for laboratory animals and the principles of laboratory animal care (NIH publication NO. 86-23, revised 1985) were followed.

Experimental animals. Forty mature male Sprague-Dawley rats, weighing 200-250 g were housed in individual cages with controlled light, temperature and humidity. The rats were fed commercial rat feed and water *ad libitum*.

Wound creation. The rats were weighed prior to the surgical procedure. The animals were anesthetized by intra muscular injection of ketamine hydrochloride (40 mg/kg) plus xylazine hydrochloride (5 mg/kg). Carprofen was injected into all animals (4 mg/kg subcutaneously) just before the operation for pre-emptive analgesia and then every 24 h for 3 days postoperatively. The backs of the animals, in the cervical region of each animal, were surgically prepared for aseptic surgery. An excision wound of size 4 cm² was made by cutting out a 2×2 cm piece of skin from the shaved area. The wounds were of full thickness type extending up to the subcutaneous tissue.

Experimental protocol. After wound creation, the animals were randomly divided into two equal groups; group I (n = 20): untreated control rats; and group II (n = 20): rats treated topically with Av. Twenty rats (10 of each group) were sacrificed on day 10 PI (post injury) and the samples from 5 animals of each group were used for histopathological evaluation and the remaining 5 samples of each group, were stored at -20 °C until biomechanical analysis. The rest of the animals (n = 20) were sacrificed on day 20 PI in the same manner and sampling was done as on the 10th day.

Preparation and administration of aqueous Aloe vera extract (AAvE). Full size mature leaves were cut from the plant and the rind removed (CHITHRA et al., 1998b). To make the gel thicker, the plant's leaves were given sufficient time to be relatively dried at room temperature without exposure to direct sunshine. After adding a small quantity of water, the leaves were then ground in a blender and centrifuged at 10,000 g, to remove the fibers and then filtered through filter papers (Qualitative Papers, Retention(um): 20-25, Porosity: course, No. 4, The Lab Depot Inc., Dawsonville, USA). The filtered aqueous extract was stored at +4 °C before use and allowed to warm up to room temperature a few hours before 1.5 mL of it was applied to the wounds (RAMACHANDRA and RAO, 2008). All the wounds (Treated and Control) were rinsed daily with 10 mL sterile saline solution. The treated group then received 1.5 mL of the prepared AAvE topically once a day, for five days, whereas the wounds of the control group remained untreated. The wounds remained uncovered in both groups throughout the experiment.

Determination of rate of wound contraction. The progressive changes in wound contraction were monitored planimetrically by tracing the wound margin on clean graph paper on days 5, 10, 15 and 20. The graph paper was laid on the wound surface, smoothed, and held flat and immobile by an assistant while the tracing was made by the examiner, wearing 2.5× loupes. The outlined area was defined as 'wound area'. Wound tracings were digitized using digital scanning software and hardware (Sigma Scan® Pro 5.0, SPSS Science, Chicago, IL, USA).

Histopathological evaluation. Skin samples from both the wound and comparable adjoining normal skin were fixed in 10% neutral-buffered formalin. After fixation, the tissues were embedded in paraffin, and sections of 5 μm in thickness were stained using hematoxylin and eosin (H&E), Masson green trichrome and alcian blue/PAS and studied by a routine light microscope. Histological examinations were performed in a double-blind fashion. The criteria that were studied in histopathological sections consisted of hemorrhage, fibrin deposition, polymorphonuclear cell and mononuclear cell infiltration, reepithelialization, cornification of the epithelium, fibroblast content, glycosaminoglycan secretions, collagen content, revascularizations, necrosis, presence of fibrocytes, maturation and organization of collagen, elastic fibers, fibroblasts and blood vessels. The concentration of glycosaminoglycans was estimated qualitatively based on the concentration of the ground substance of the histopathological sections of the lesions after staining with alcian blue/PAS and a higher concentration of the ground substance was stated as larger amounts of the glycosaminoglycans and proteoglycans. Collagen content was measured on the basis of the connective tissue density measurement on the histopathological sections stained with Masson green trichrome, of the experimental and control lesions.

In every skin section an area just beneath the epidermis at the incised area was randomly selected. Thereafter, three other consecutive areas moving towards the deep dermis were selected. An eyepiece graticule with 24 squares with known dimensions was used for cell counting. The cells present in all 24 squares were counted at constant objective magnification of $\times 40$. The cells present in each square were counted three times for accuracy and the average cell count was calculated as cells per mm^2 . Duplicate counts were carried out by two observers independently (ORYAN and SHOUSHARI, 2008). The number of fibroblast, macrophages, lymphocytes and blood vessels were counted and their mean and standard deviations were calculated.

Biomechanical studies. After shaving, the skin containing the incision area was excised in a rectangular shape (10 \times 2 cm). Another similar skin sample from the intact skin of the comparable area far from the site of the initial excision of the same animal was excised as intact control skin. The samples were kept frozen ($-20\text{ }^\circ\text{C}$), promptly after sampling for a maximum of 5 days before being tested (ORYAN and ZAKER, 1998). Prior to testing they were then thawed at room temperature (ORYAN et al., 2008; BUTLER et al., 2000). A Universal Instron testing machine was used for biomechanical testing of the specimens (TT-CM-L, England). After thawing, the skin pieces were mounted on a frame and care was taken that the skin was not stretched in any direction, and then both sides of the skin flap were clamped into a pair of grips so that a constant length of 4 cm, with the wound in the middle of the skin piece, was used for tensile testing. The skin flap was stretched using a constant strain rate of 10 mm/min and a chart speed of 5 cm/min, and the

ultimate tensile strength, yield strength and stiffness were calculated based on the load-deformation curve (ORYAN et al., 2007).

Statistical analysis. One-way analysis of variance ANOVA was used to evaluate the differences of biomechanical parameters between treated and control groups. Student's t-test was used to evaluate the significant differences of biomechanical parameters between treated and untreated lesions and with those of their normal contra-lateral skin samples. Neutrophils, macrophages, fibroblasts scores and vessel counts were analysed using one-way ANOVA. When the differences among the groups were significant, Duncan's multiple range test was used. All analyses were performed using SPSS 13.0 (SPSS Inc., Chicago, IL, USA). A *P*-value lower than 0.05 was considered significant.

Results

Observations during daily wound care. Wound surface area was calculated and expressed in cm² as shown in Table 1. There was a significant reduction in the wound surface area of the treated lesions on days 15 and 20 compared to those of the untreated ones.

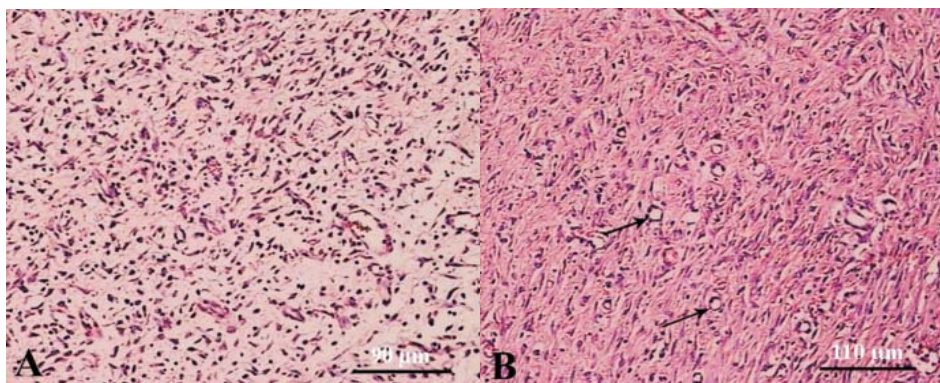


Fig. 1. A) The untreated lesion on day 10 post-injury. The connective tissue of the dermis is highly infiltrated with inflammatory cells (arrows); the newly formed collagen fibers are unorganized and show a haphazardly distributed pattern. The glycosaminoglycan formation in the dermis is scanty (H&E; $\times 220$). B) The treated lesion on day 10 post-injury. Numerous blood vessels of different sizes are seen in this section (arrows). The collagen fibers show a primitive organized pattern and the tissue alignment is greater as compared to untreated lesions (H&E; $\times 180$).

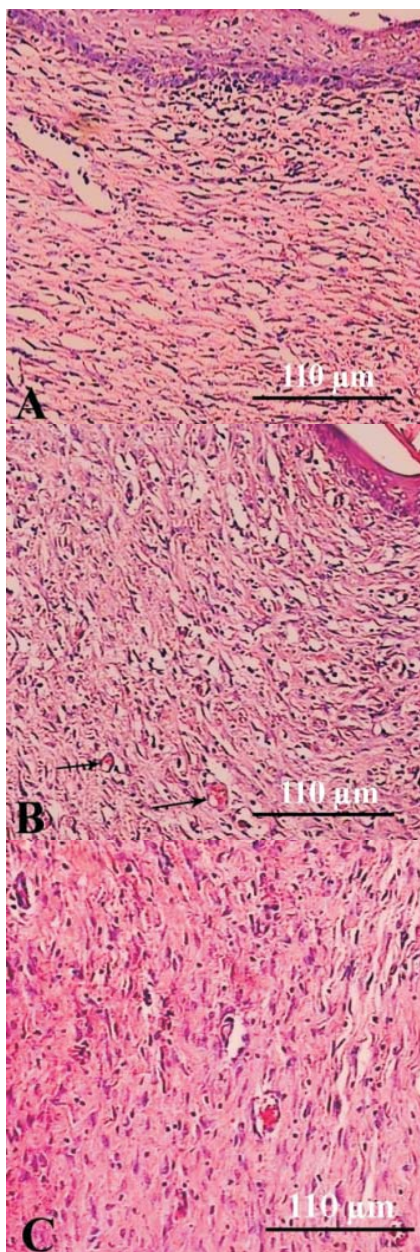


Fig. 2. A) Untreated lesion on day 20 post-injury. Re-epithelialization is well developed but cornification has not yet taken place. The number of blood vessels is fewer than those of the treated lesions on day 20 post-injury and in comparison to those of the untreated lesions on day 10 post-injury. Many mononuclear inflammatory cells have infiltrated between the collagen fibers of the dermis (H&E; $\times 180$). B) Treated lesion on day 20 post-injury. Re-epithelialization and cornification is well developed. Compared to those of day 10 post-injury the number of blood vessels is reduced (arrows). Fewer macrophages and lymphocytes are seen in this section, compared to those of the untreated lesions tissue alignment is improved (H&E; $\times 180$). C) Treated lesion on day 20 post-injury. Compared to those of the untreated lesions a lower number of lymphocytes and macrophages have infiltrated the dermis. Collagen fibers are organizing and the tissue is aligned (H&E; $\times 180$).

Table 1. Mean \pm SD of wound surface area (cm²) in treated and control groups on different days post surgery

Groups	Day 5	Day 10	Day 15*	Day 20*
Control	3.62 \pm 0.73 (n = 20)	2.01 \pm 0.36 (n = 20)	1.12 \pm 0.56 (n = 10)	0.25 \pm 0.41 (n = 10)
Treated	3.51 \pm 0.61 (n = 20)	2.22 \pm 0.49 (n = 20)	0.89 \pm 0.70 (n = 10)	0.1 \pm 0.01 (n = 10)

* There was a significant difference in wound surface areas on days 15 and 20 post-injury.

Table 2. Mean \pm SD of the number of lymphocytes, macrophages, fibroblasts and blood vessels of treated and untreated sections obtained on day 10 post-injury

Groups	Lymphocytes	Macrophages	Fibroblasts	Blood vessel
Control	87.67 \pm 6.12	53.33 \pm 5.09	52.33 \pm 11.91	12.66 \pm 3.08
Treatment	53.5 \pm 7.97	36.00 \pm 5.73	47.00 \pm 6.47	22.83 \pm 7.08

There was a non-significantly lower number of inflammatory cells and higher blood vessel count of the treated lesions on day 10 (counted through objective lens with \times 40 magnification).

Table 3. Mean \pm SD of the number of lymphocytes, macrophages, fibroblasts and blood vessels of treated and untreated sections obtained on day 20 post-injury

Groups	Lymphocytes*	Macrophages*	Fibroblasts	Blood vessel*
Control	41.67 \pm 4.55	28.33 \pm 6.80	45.00 \pm 8.58	6.5 \pm 2.59
Treatment	15.00 \pm 4.93	9.83 \pm 3.76	39.83 \pm 8.52	13.5 \pm 2.73

There was a significantly lower number of lymphocytes, macrophages and a higher number of blood vessels in the treated group as compared to the untreated one (counted through objective lens with \times 40 magnification).

Histopathological findings. Numerous inflammatory cells including lymphocytes, plasma cells and macrophages infiltrated the dermis, particularly the deeper dermis of the untreated lesions on day 10 PI. Many immature fibroblasts and fewer mature fibrocytes were also present in the dermis of the untreated lesions. The newly formed collagen fibers of the untreated lesions were still unorganized and showed a haphazardly distributed pattern at this stage. Angiogenesis was evident in the untreated wounds (Fig. 1). New blood vessels were evident in the lesions of untreated lesions at this stage and re-epithelialization was not complete in the lesions of three of these animals of the untreated group on day 10 PI, however, the lesions of the remaining two rats showed a thicker epithelium and much mitotic figures. The Mean \pm SD of the inflammatory cells and the blood vessels of the treated and untreated lesions are presented in Table 2. As shown in Table 2, compared to those of the control lesions, fewer lymphocytes and macrophages infiltrated the lesions of the treated animals on day 10 PI. Greater numbers of blood

vessels were seen in the treated lesions than those of the untreated ones. The collagen fibers showed a more organized pattern and the tissue alignment was greater as compared to the untreated lesions at the same stage. The lesions of four animals showed proper re-epithelialization at this stage, however, re-epithelialization was not complete in one of these animals. There was no evidence of pus accumulation, or polymorphonuclear cell infiltration, fibrin deposition or edema accumulation in the lesions of treated or untreated animals on day 10 PI (Fig. 1). Apart from in one animal, the lesions of the untreated group showed proper re-epithelialization and cornification on day 20 PI. The blood vessels of the untreated lesions were fewer than those of the treated lesions; however, their diameter was larger as compared to the untreated lesions on day 10. Lymphocytes and macrophages were still present in the lesions of untreated animals on day 20 PI and their number was significantly greater than those of the treated lesions ($P < 0.05$). Some sections showed an improved alignment of the collagen fibers and fibroblasts, however, most of the lesions were still improperly organized at this stage (Table 3 and Fig. 2A).

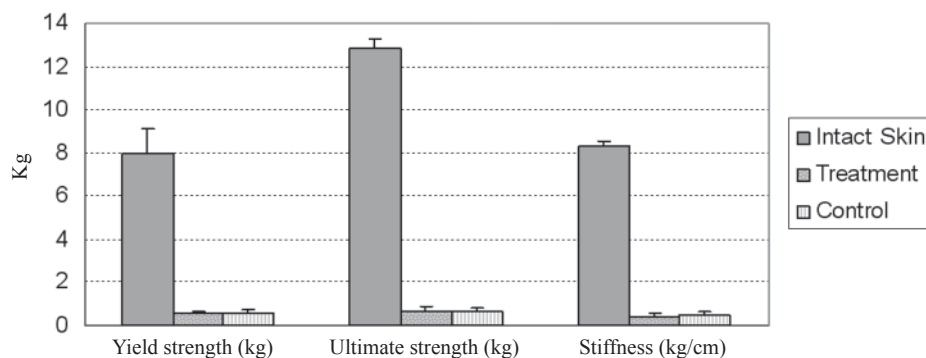


Fig. 3. Yield strength, ultimate strength and stiffness of the treated, untreated and intact skin samples on day 10 post-injury. There was no significant difference between the biomechanical properties of the treated and untreated lesions on day 10 post-injury ($P > 0.05$), and all items were significantly lower than those of their intact contra-lateral skins.

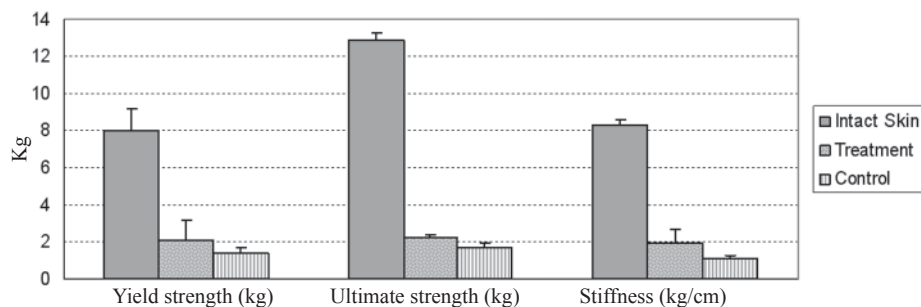


Fig. 4. Yield strength, ultimate strength and stiffness of the treated, untreated and normal skin samples on day 20 post-injury. Treated samples showed significant improvement in biomechanical properties as compared to control ones on day 20 ($P < 0.05$). Neither the treated nor the untreated samples reached the original normal values of the intact skin.

The histopathological sections of all the treated animals on day PI showed a proper re-epithelization and unique epithelial formation. Fewer lymphocytes and macrophages infiltrated the lesions of the treated compared to the untreated animals (Table 3). Most of the fibroblasts of the injured treated lesions were relatively mature at this stage but they had not yet developed into fibrocytes. Collagen fibers and fibroblasts were organizing and the tissue was aligning (Fig. 2B and C). Compared to those of the untreated lesions, the treated lesions showed significantly greater maturation, better tissue alignment, a lower number of inflammatory cells and higher biomechanical properties on day 20 PI.

Biomechanical findings. As shown in Figures 3 and 4, there was no improvement in biomechanical properties on day 10 PI; however, the yield strength, ultimate strength and tissue stiffness of the treated samples were significantly higher on day 20 PI compared to those of the untreated lesions. These parameters were lower in the treated or untreated lesions, compared to those of their intact contra-lateral skins.

Discussion

The results on day 10 PI showed that healing was well underway in both the treated and untreated groups considering wound contraction and cell proliferation, which are shown in Tables 1 and 2. As shown in Fig. 1, the biomechanical properties of the treated and untreated samples were almost similar and did not show a significant difference on day 10 PI, moreover, both were inferior to their intact contra-lateral skin samples. The

observed reduction in the mechanical properties of both treated and untreated healing skins compared with uninjured controls would be expected at the early stage of repair investigated in this study and correlated with the histopathological findings. At this stage the newly formed collagen fibers are immature, their cross-links were not properly developed and are mostly of type III collagen with small sized collagen fibrils that have a haphazard pattern of distribution (CHITHRA et al., 1998a). It has been reported that Av increases the collagen content of the granulation tissue as well as its degree of cross-linking, as seen by increased aldehyde content and decreased acid solubility (CHITHRA et al., 1998a). Although the present study showed the beneficial effects of the Av on the morphology of dermal wound healing in rats on both days 10 and 20 PI., the differences on day 10 PI were not significant but they improved to a significant difference on day 20 PI. The overall number of inflammatory cells was also less in the treated than the untreated lesions which implies more progression in healing in the treated group than the untreated ones. Our results on the effects of AAvE on the early stages of wound healing were in contrast to those of SUBRAMANIAN et al. (2006) and MOGHBEL et al. (2007). SUBRAMANIAN et al. (2006) reported a significant improvement in the reduction of wound size of the treated animals on day 7 PI. They reported a well organized granulation tissue in the treated lesions on day 7 PI that contained significantly higher hydroxyproline, collagen and DNA contents. They stated that the antioxidative criteria of the plant extract may be responsible for these enhanced wound healing properties.

During the early wound healing process, epithelial cells proliferate and migrate from the edges of the wounds and eventually cover it. Proliferation and migration of the epithelial cells and fibroblasts is dependant on an adequate oxygen supply. This amount of oxygen is supplied either by increasing the rate of blood flow in the existing blood vessels, or the granulation tissue receives its oxygen requirements through the newly formed blood vessels. Increase in the blood flow by this reagent is very unlikely and the angiogenic activity of this extract possibly is responsible for providing more blood and oxygen supply and therefore an enhanced wound healing outcome (RUBIN, 1984). In addition to an improved alignment and reduced inflammatory cell infiltration of the treated lesions compared to those of the untreated ones, the treated lesions after both 10 and 20 days PI in the present study were more vascular. It has been said that Av speeds up the healing of damaged epithelial tissue in wounds by providing essential micronutrients by its angiogenic behavior, eliciting an anti-inflammatory effect and stimulation of skin fibroblasts (DANHOFF and McANALLY, 1983). MOGHBEL et al. (2007) reported that the rate of wound healing of burn wounds treated with Av gel was 50% faster than routine treatment with silver sulfadiazine. They were not able to propose the exact mechanisms of the action of Av natural gel on burn wounds but suggested that the mannose-6-phosphate present in Av, which contains glucose and mannose chains may be effective in improving the healing rate (MOGHBEL et al., 2007). Mannose-6-phosphate has been introduced as

the active part of Av responsible in wound healing (DAVIS et al., 1994). This substance also contains enzymes, glycoproteins, growth factors, vitamins and minerals (DAVIS, 1991) that have been shown to improve healing with enhanced epithelialization and rapid formation and maturation of granulation tissue in burn wounds (VISUTHIKOSOL et al., 1995). It has been stated that insulin-like growth factor II and mannose-6-phosphate bind to the same receptor on the fibroblast (WESTLUND et al., 1991). These two ligands activate the fibroblasts to enhance the wound healing process. An important criterion that might make SUBRAMANIAN et al. (2006) and MOGHBEL et al. (2007) findings different from the finding of the present study is that they applied the gel for longer time. SUBRAMANIAN et al. (2006) applied the gel twice a day for a period of 14 days and MOGHBEL et al. (2007) applied the gel twice a day for 18 days, while in the present experiment the AAvE was applied once a day for five days.

Higher rate of wound contraction on days 15 and 20 PI together with significant improvement of biomechanical and histopathological findings in the treated lesions on day 20 PI compared to those of the untreated ones in the present study are in accordance with findings of most of the previous investigators (FEILY and NAMAZI, 2009; CHITHRA et al., 1998a; MOGHBEL et al., 2007; SUBRAMANIAN et al., 2006). The enhanced rate of wound contraction and reduction in healing time in treated rats might be due to the anti-inflammatory effects of this material together with its effect on maturation and organization of the granulation tissue. Another and perhaps significant feature in the treated group was that their newly formed collagen fibers were aligned and were not randomly distributed as in the untreated lesions. The histological appearance indicated a greater degree of organization of the collagen orientation in the treated lesions and a more normal alignment of new collagen, which was strikingly similar to that of the normal undamaged, skins. It is possible that this was brought about by a modification of the inflammatory reaction or organization of the fibrin network in the tissue spaces at early stages of inflammatory phase of healing by the Av extract, which may act as a 'scaffold' or template for fibroblast activity. It also appears that Av may have enhanced the return of cellularity to within normal level. This could merely reflect the anti-inflammatory effect of the drug in reducing the number of adventitious phagocytic cells in the area.

Although SUBRAMANIAN et al. (2006) reported that the most possible wound healing explanation of this extract is that Av increases wound healing by stimulating fibroblasts directly, compared to those of the untreated ones, the fibroblast count of the treated lesions in the present study did not improve significantly. It seems that Av is not effective in the proliferation of fibroblasts but it exerts its effects on the further maturation and alignment of the fibroblasts and collagen fibrils and eventually improves the biomechanical characteristics of the granulation tissue. However, more investigation, especially *in vitro*, is needed to fully evaluate the effects of Av on fibroblast metabolism and proliferation.

The treatment accelerated a return to normal values, thus contributing to a possible improvement in the efficiency of the healing process. So, the high degree of tissue organization and repair at 20 days PI suggests the likelihood of more rapid and complete restoration of normal functional mechanics as the granulation tissue matures. Provided that the new, small-diameter unorganized fibrils subsequently mature in a normal manner and give rise to large diameter fibrils, mechanical strength should increase with time. Further experimental studies and longer term studies after treatment with Av will be required to confirm this.

Conclusions

Therefore, from these findings it could be concluded that application of Av to an open wound induces significant wound contraction and accelerates wound healing and this herbal aqueous extract may be a promising medication for open wounds. Macroscopic, microscopic and biomechanical results indicated that topically administered Av accelerated epithelialization, wound contraction, tissue alignment and tissue strength at the later stage of wound healing.

Acknowledgements

The authors wish to thank Shiraz School of Veterinary Medicine for financial support of this study.

References

- BUTLER, D. L., S. A. GOLDSTEIN, F. GUILAK (2000): Functional tissue engineering: The role of biomechanics. *J. Biomech. Eng.* 122, 570-575.
- CHITHRA, P., G. SAJITHLAL, G. CHANDRAKASAN (1998a): Influence of *Aloe vera* on collagen characteristics in healing dermal wounds in rats. *Mol. Cell Biochem.* 181, 71-76.
- CHITHRA, P., G. B. SAJITHLAL, G. CHANDRAKASAN (1998b): Influence of *Aloe vera* on the healing of dermal wounds in diabetic rats. *J. Ethnopharmacol.* 59, 195-201.
- CHOI, S., K. KIM, J. CHOI, S. HAN, Y. PARK, S. LEE, J. KIM, M. CHUNG (2002): Angiogenic activity of β -sitosterol in the ischaemia/reperfusion-damaged brain of Mongolian gerbil. *Planta Med.* 68, 330-335.
- DANHOFF, I. E., B. H. McANALLY (1983): Stabilised *Aloe vera*, its effect on human skin cells. *Drug Cosmet. Ind.* 133, 152-196.
- DAVIS, R. (1991): Inhibitory and stimulatory systems in *Aloe vera*. *Aloe Today*, Dallas, Winter 1991-1992.
- DAVIS, R. H., J. J. DONATO, G. M. HARTMAN, R. C. HAAS (1994): Anti-inflammatory and wound healing activity of a growth substance in *Aloe vera*. *J. Am. Pediatr. Med. Assoc.* 84, 77-81.
- FEILY, A., M. R. NAMAZI (2009): *Aloe vera* in dermatology: a brief review. *G. Ital. Dermatol. Venereol.* 144, 85-91.

- FRIEDMAN, R., K. SI (1999): Initial characterization of the effects of *Aloe vera* at a crayfish neuromuscular junction. *Phytother. Res.* 13, 580-583.
- HU, Y., J. XU, Q. HU (2003): Evaluation of antioxidant potential of *Aloe vera* (*Aloe barbadensis* Miller) extracts. *J. Agr. Food Chem.* 51, 7788-7791.
- KILIÇ, N. (2005): The effect of *Aloe vera* gel on experimentally induced peritoneal adhesions in rats. *Rev. Med. Vet.* 156, 409-413.
- KIM, H., B. LEE (1997): Inhibition of benzo [a] pyrene-DNA adduct formation by *Aloe barbadensis* Miller. *Carcinogenesis.* 18, 771-776.
- KOSIF, R., R. AKTAS, A. OZTEKIN (2008): The effects of oral administration of *Aloe vera* [*barbadensis*] on rat central nervous system: An experimental preliminary study. *Neuroanatomy* 7, 22-27.
- LEE, K., S. WEINTRAUB, B. YU (2000): Isolation and identification of a phenolic antioxidant from *Aloe barbadensis*. *Free Radical Bio. Med.* 28, 261-265.
- MOGHBEL, A., A. GHALAMBOR, S. ALLIPANAH (2007): Wound healing and toxicity evaluation of *Aloe vera* cream on outpatients with second degree burns. *Iran J. Pharmacet. Sci.* 3, 157-160.
- NOOR, A., S. GUNASEKARAN, A. MANICKAM, M. VIJAYALAKSHMI (2008): Antidiabetic activity of *Aloe vera* and histology of organs in streptozotocininduced diabetic rats. *Curr. Sci.* 94, 1070-1076.
- ORYAN, A., A. E. GOODSHIP, I. A. SILVER (2008): Response of a collagenase-induced tendon injury to treatment with a polysulphated glycosaminoglycan (Adequan). *Connect Tissue Res.* 49, 351-60.
- ORYAN, A., A. KHALAFI-NEZHAD, N. TOLOO, M. N. SOLTANI RAD (2007): Effects of 4-chloro-2, 6-bis-(2-hydroxyl-benzyl)-phenol on healing of skin wounds and growth of bacteria. *J. Vet. Med. Sci.* 54, 585-591.
- ORYAN, A., A. SHOUSHTARI (2008): Histology and ultrastructure of the developing superficial digital flexor tendon in rabbits. *Anat. Histol. Embryol.* 37, 134-140.
- ORYAN, A., S. R. ZAKER (1998): Effects of topical application of honey on cutaneous wound healing in rabbits. *J. Vet. Med. Sci.* 45, 181-188.
- RAMACHANDRA, C., P. RAO (2008): Processing of *Aloe vera* leaf gel: a review. *Am. J. Agr. Biol. Sci.* 3, 502-510.
- REYNOLDS, T., A. DWECK (1999): *Aloe vera* leaf gel: a review update. *J. Ethnopharmacol.* 68, 3-37.
- RUBIN, P. C. (1984): Opioid peptides in blood pressure regulation in man. *Clin. Sci.* 66, 625-630.
- SUBRAMANIAN, S., D. SATHISH KUMAR, P. ARULSELVAN (2006): Wound healing potential of *Aloe vera* leaf gel studied in experimental rabbits. *Asian J. Biochem.* 1, 178-185.
- VINSON, J., H. AL KHARRAT, L. ANDREOLI (2005): Effect of *Aloe vera* preparations on the human bioavailability of vitamins C and E. *Phytomedicine* 12, 760-765.

- VISUTHIKOSOL, V., B. CHOWCHUEN, Y. SUKWANARAT, S. SRIURAIRATANA, V. BOONPUCKNAVIG (1995): Effect of *Aloe vera* gel to healing of burn wound a clinical and histologic study. *J. Med. Assoc. Thai.* 78, 403-409.
- VOGLER, B. K., E. ERNST (1999): *Aloe vera*: a systematic review of its clinical effectiveness. *Brit. J. Gen. Pract.* 49, 823-828.
- WESTLUND, B., N. DAHMS, S. KORNFELD (1991): The bovine mannose 6-phosphate/insulin-like growth factor II receptor. Localization of mannose 6-phosphate binding sites to domains 1-3 and 7-11 of the extracytoplasmic region. *J. Biol. Chem.* 266, 23233-23239.
- WILLIAMS, M., M. BURK, C. LOPRINZI, M. HILL, P. SCHOMBERG, K. NEARHOOD, J. O'FALLON, J. LAURIE, T. SHANAHAN, R. MOORE (1996): Phase III double-blind evaluation of an *Aloe vera* gel as a prophylactic agent for radiation-induced skin toxicity. *Int. J. Radiat. Oncol.* 36, 345-349.

Received: 7 August 2009

Accepted: 22 December 2009

ORYAN, A., A. T. NAEINI, B. NIKAHVAL, E. GORJIAN: Učinak vodenoga iscrpka aloje *Aloe vera* na cijeljenje pokusnih kožnih rana u štakora. *Vet. arhiv* 80, 509-522, 2010.

SAŽETAK

Istraživanje je poduzeto radi prosudbe učinka iscrpka aloje *Aloe vera* (*Aloe barbadensis*) na cijeljenje kožnih rana. Četrdeset štakora bilo je nasumce podijeljeno u dvije jednake skupine (kontrolnu i pokusnu). Filtrirani vodeni iscrpak *Aloe vera* u količini od 1,5 mL bio je primijenjen na ozljede kože štakora pokusne skupine. Veličina ožiljka mjerena je planimetrijski 5., 10., 15. i 20. dana. Dvadeset štakora (10 iz svake skupine) bilo je žrtvovano 10. dana pri čemu su uzeti uzorci za patohistološku i biomehaničku pretragu. Ostale životinje bile su žrtvovane 20. dana od početka pokusa. Liječene životinje pokazivale su nesigifikantno poboljšanje cikatrizacije i patohistoloških promjena rana. Značajna razlika u veličini ožiljka između dviju skupina ustanovljena je nakon 15. dana. U pokusnih životinja ustanovljeno je bolje zacjeljivanje, slabija infiltracija upalnih stanica i značajno poboljšanje biomehaničkih svojstava 20. dana ($P < 0,05$). Rezultati upućuju na zaključak da primjena vodenoga iscrpka aloje *Aloe vera* na otvorene rane znatno potiče tvorbu ožiljka i ubrzava njihovo cijeljenje.

Ključne riječi: *Aloe vera*, vodeni iscrpak, cijeljenje rana, štakor
