

Clinical Cytology and Primary Health Care of Children and Adults

Željka Znidarčić¹, Tatjana Jeren², Gordana Kaić², Ika Kardum-Skelin^{4,8}, Anka Knežević-Obad⁵, Silvana Smojver-Ježek^{6,8} and Adrijana Vince^{7,8}

¹ Croatian Society for Clinical Cytology, Croatian Medical Association, Zagreb, Croatia

² The Academy of Medical Sciences of Croatia, Zagreb, Croatia

³ Department of Clinical Cytology and Cytometry, Dubrava University Hospital, Zagreb, Croatia

⁴ Department of Medicine, »Merkur« University Hospital, Zagreb, Croatia

⁵ Clinical Department of Nuclear Medicine and Radiation Protection, Zagreb University Hospital Centre, Zagreb, Croatia

⁶ »Jordanovac« University Hospital for Lung Diseases, Zagreb, Croatia

⁷ University Hospital for Infectious Diseases, Zagreb, Croatia

⁸ Zagreb University, School of Medicine, Zagreb, Croatia

ABSTRACT

Clinical cytology is a diagnostic branch of medicine, best known by the Papanicolaou test in gynaecology. But, cytology can be applied in almost all fields of clinical medicine. Its advantages – high accuracy, simplicity, with little or no aggressiveness and low cost – are not used as widely as they could be. Medical practice, as well as medical research, and also medical education, are nowadays often directed at profitable use and not at the real benefit of the patient. Primary practitioners do not have enough chance to get acquainted with clinical cytology as a whole although they need true information, based on the cost-effectiveness and patient-benefit. A panel discussion on this subject was organised at the 4th Croatian Congress of Clinical Cytology, in Split, October 11–14, 2009 by the Croatian Society for Clinical Cytology-Croatian Medical Association, to inform primary practitioners about the possibilities of cytodiagnosics in the health care of children and adults. Indications for cytodiagnosics in infectious diseases (T. Jeren and A. Vince), haematology (I. Kardum-Skelin), pulmonology (S. Smojver-Ježek), thyroid diseases (A. Knežević-Obad), breast diseases (I. Kardum-Skelin), gastroenterology and urology (G. Kaić) were discussed, as well as technical procedures and the interpretation of the cytological findings. Moderator (Ž. Znidarčić) opened the panel with presentation about the role of clinical cytology, particularly in the primary health care. The discussion finally pointed at the necessity of better communication between primary practitioners and cytologists. This review article presents contents of the panel discussion.

Key words: clinical cytology, primary health care

Introduction

The actual problem in modern medicine is its fragmentation into many small parts without an adequate connection among them. The target of interest now is not the patient as a whole person with some health problems. The actual medicine is concentrated on the distinct parts of this person, his organ, or just a part of an organ. Doctors are overloaded with everyday developments of medical science and are therefore specialized in very narrow branches. In such circumstances complete survey of the whole medical knowledge is inevitable lost. This situation has been profitably used at the expense of both patients and doctors. In diagnostics, efforts are constantly

directed at new technologies, with expensive equipment and at the laboratory tests with numerically expressed results. The doctors increasingly turn into technicians¹. »Evidence based medicine« is the expression often used to justify this transformation. The medical science is also directed at providing new technologies and medicaments used for the profit and not for the general improvement of health. Modern medicine is becoming more and more expensive and this is the world-wide problem. The accessibility of medical procedures is inversely proportional to the quantity of these procedures. That results in reduced effects of the medical treatment, which is an absurd. The

primary practitioners are the first ones handicapped by this problem. Medical education is not concerned about the economics in the health care and the physicians are exposed to advertising of various diagnostic technologies, laboratory procedures and chemical substances. It is obvious that the main goal of advertising is the profit and not the patients benefit, although great efforts are made to demonstrate this benefit »scientifically«. There already are a great number of articles in respectable medical journals, or even books, where the truth about various new technologies and medicaments is exposed². But, in the health care management the physicians should have true information, based on the cost- and patient-benefit. Thus, it is necessary for primary care practitioners to be informed about possibilities of diagnostic cytology, especially because of insufficient information they get during medical studies. The indications for cytodiagnosics, the way of specimen collection for cytoanalysis and the interpretation of cytological findings are therefore stressed in our discussion. We hope, nevertheless, that in the near future the situation in medicine will change and that the cost-effectiveness and patients benefit, rather than profitability, will be the primary concern in the health care management. We are all invited to do our best to promote this change.

Cytology as a Clinical Diagnostic Branch

The discovery of cells, as the consequence of the microscope construction in the 17th century, marked the beginning of cytological investigations. Technical improvements of the microscope gave successively more knowledge about the structure and the function of the cells and of their morphological changes in various functional and pathological conditions. The statement of Rudolf Virchow, that each pathological process begins in the cell, has led the scientists to investigate the cells and their morphological changes. Thus the diagnostic role of the cytologic analysis was established. But, nevertheless, a rather long period was necessary for the development of clinical cytology as a medical diagnostic branch. It started with Papanicolaou in the first decades of the 20th century, in gynaecology, and then it was successively introduced into other medical fields as a morphologic diagnostics, with many advantages. In short, cytology has a high diagnostic accuracy, the methods of the material collection are simple, with little or no aggressiveness, and at a low cost. The diagnosis can often be given in a very short time, even intraoperatively. Cytology can save time and money, and avoid the hospitalization – the advantages needed in the actual medicine, but not sufficiently used^{3,4}. Perhaps the main reason for neglecting diagnostic cytology in modern medical practice and education, is lack of financial profitability of this diagnostic branch.

Our medical students are informed about gynaecological part of cytology during the gynaecological course, and the general cytology is a short optional subject in some medical schools in Croatia. The main factors necessary for appropriate use of cytology are a sufficient num-

ber of adequately educated and trained cytologists and cytotechnicians and a properly organized team-work with the hospital doctors and other personnel as well as with the primary practitioners, who should be also adequately educated. The specialization in cytology exists in Croatia for 35 years now and it was established to qualify doctors in the complete cytodiagnosics. Cytotechnicians are educated to do the technical part of cytology and to screen slides and separate normal slides from the pathological ones, which should be analysed by the cytologists. According to the way of obtaining the material for cytoanalysis, two main parts of cytology are distinguished: exfoliative and aspiration cytology. When the cells are obtained from a surface where they are scaled, as in the exfoliative cytology, the specimen collection is simple and it can be used for the screening of asymptomatic population to discover premalignant changes or early stages of malignant ones. A great number of normal slides, without pathological changes, are obtained in such a way, and an insufficient number of cytotechnicians is often the reason for the prolonged waiting for the cytological reports in gynaecology. In the aspiration cytology, where the material is obtained by fine-needle aspiration, done usually under radiological guidance (ultrasound, CT, x-ray), the cytotechnicians can separate slides with unsatisfactory material (e.g. blood only) but the cytologists should always analyse smears with satisfactory material. Current cytological service in Croatia is organized in 46 cytological units (in 23 towns), with 101 specialist of clinical cytology, 20 residents in clinical cytology, 141 cytotechnicians and 45 medical technicians without cytotechnological training⁵. The cytologists: cytotechnicians ratio is unsatisfactory, but there is another problem with the total number of the cytological personnel. To make the best of cytology with all its advantages, the number of cytologists, as well as cytotechnicians, should correspond to the number of specialists in other medical branches who need cytology in their diagnostic work. Cytology can be used in the early diagnosis or even prevention of malignancy, but also in the diagnosis of various non-malignant diseases, as well as in the follow-up of the treatment. The number of cytological staff should be considerably greater and the cytologists: cytotechnicians ratio should be at least 1:2.

The aim of this round table discussion was to inform primary practitioners about cytology, especially in the medical fields where it is widely used. The participants in the discussion should provide information about the indications for cytodiagnosics in these fields, as well as information about the collection of material and about the interpretation of the cytological reports. Better communication between the cytologists and the primary practitioners is necessary to improve the rule of cytodiagnosics in the health care⁶.

Cytology in Infectology

Infectious diseases, most often with inflammatory pathogenesis, can be caused by various microorganisms:

bacteria, fungi, viruses, parasites, or there is sometimes a combination of inflammatory and degenerative process, like in the prionic diseases. There are special problems in infectious diseases accompanying immunological disorders⁷.

The role of cytology in the diagnosis of infectious diseases is very important. Many infectious diseases, with common infectious symptoms like fever, chills, headache, prostration, have specific, diagnostically significant symptoms which help in their differentiation. So there are skin signs: rash, maculas, papulas, vesiculas or other manifestations. Mucous lesions are also often present: vesiculas, infiltrates (serous or purulent) or other changes.

Very often there are enlarged lymph nodes in one or several regions, sometimes adherent to each other, sometimes with fistulation and skin inflammation around them. They are usually painful. Respiratory organs are often involved, sometimes with mild serous inflammation, but sometimes with serious pneumonia, where analysis of sputum is important in the differential diagnosis. Gastrointestinal infections can produce diarrhoea with various appearance of feces. In the urogenital infections, qualitative and quantitative changes of urine or some other excreted (prostate, vagina) can appear.

Indications for cytological examination in differential-diagnostic procedures in the infectology are various specific and non-specific symptoms mentioned above, which should also be investigated by laboratory analyses (haematological, microbiological, biochemical and others). Cytological examinations in various infectious diseases are simple, minimally invasive, and can be repeated when necessary. They can be performed in every institution where persons trained in cytology (cytologist and cytotechnician) are available. The material for cytological analysis is sometimes obtained by exfoliation (skin, mucous membranes – smear, vesicular fluid), as in herpetic or pemphigoid lesions^{8,9}.

Fine needle aspiration (FNA) of enlarged lymph nodes is a very frequent procedure for obtaining material for cytodiagnosis in infectology. Lymphatic tissue is reacting in almost all infectious diseases, and lymphadenopathy can be localized or generalized. Such reactions are present even without clinical symptoms. Reactive changes of the lymphatic tissue cannot be always palpably evident, but cytological and pathohistological changes are always present. The primary practitioner should know that, in the first 30 years of life, about 80% of lymphadenopathies are benign, but later the percentage of malignant diseases increases (40% are benign after 50 years of age)¹⁰. In the diagnostic procedure, a thorough anamnesis and clinical examination of the patient with enlarged lymph nodes are followed by the FNA of lymph node(s).

The dynamics of cytomorphological picture in infectious diseases should be stressed, so that a process can begin with lymphocytic hyperplasia and end as a granulomatous inflammation. It is also necessary to know that some malignant processes can begin as lymphocytic

hyperplasia, follow-up of the disease is therefore recommended in such cases.

Sputum cytology is important for the differentiation of an inflammatory from a malignant process¹¹. The expectorate and not just saliva should be obtained from the patient. Urogenital infections can often be diagnosed by urine examination. The patient must be informed to give the first morning urine (but not nocturnal), at best in the medical institution as it should be fresh for cellular examination. The cytological examination of the feces is necessary especially in children with diarrhoea, to differentiate the viral from the bacterial process. In adults it can help in the diagnosis of ulcerous inflammation of the colon as well as in the follow-up of the disease and the therapy. Fresh samples of feces should be taken several times.

In all inflammatory processes of the central nervous system (CNS), cytological examination of the CSF (obtained by lumbar puncture) is the first step in diagnostic procedure. In purulent inflammatory processes, most commonly caused by bacteria, and possibly by fungi and some parasites, pleocytosis in CSF is detected with several hundreds to tens of thousands of cells per cubic millimeter. Cytological analysis reveals neutrophils that dominate from 3 to 8 days depending on the etiology, pathogen virulence and time of initiation of adequate therapy, after which the neutrophil curve is crossed by the mononuclear cells (lymphocytes, monocytes and macrophages) curve.

In viral inflammations, most commonly caused by neurotropic viruses, pleocytosis is milder, with several dozens to several hundreds of cells per cubic millimeter. Immediately after initial neutrophilia that lasts for 4–6 hours, maximum 24 hours, mononuclear pleocytosis mainly occurs with lymphocytes, monocytes, various stimulatory forms of these cells, immunocompetent cells and some macrophages. In inflammatory processes that affect mainly the brain (encephalitis), pleocytosis is mild and immunocompetent cells are often found. Cytological findings of the CSF in tumor processes are important in the diagnostics of hematogenous metastases in the CNS, because tumor cells are largely found in the CSF itself. In primary CNS tumors that affect the CSF spaces (e.g. ependymoma), tumor cells are also detected in the CSF, and in primary tumors that are located away from the CSF spaces, tumor cells may not be found in the CSF, only the so called reactive pleocytosis, which is not sufficient for establishing the diagnosis.

The cytological examinations and findings described here contribute in the diagnosis of an infectious disease, which should be etiologically proved (data from personal lectures at the School of medicine, Zagreb University). The communication between primary practitioners and cytologists is a »conditio sine qua non«. It consists of the informations about significant anamnestic, clinical and laboratory data and a presumed working diagnosis, on the side of primary practitioner. The cytologist, on his side, should give the answer after a thorough cytological analysis – compatible with presumed diagnosis, defini-

tive diagnosis or differential diagnostic possibilities. The communication is as yet not sufficient and it should be improved, to get more objective diagnoses and more success in the treatment of our patients.

Hematologic Cytology

Enlarged lymph node is a perfect model for the patient, the clinician/primary practitioner and the cytologist to see how a sample obtained by cytologic fine-needle aspiration (FNA) can serve to differentiate a non-malignant from a malignant process with certainty, which is the main cytologist's responsibility, by use of cytomorphology and adjuvant technologies¹². The indications for lymph node FNA depend on the patients age, clinical presentation, and size, consistency and localization of enlarged lymph nodes. Lymph node enlargement is part of the patient's normal immune response to various agents. In childhood, when the body encounters various causative agents for the first time, lymph node enlargement is an almost daily phenomenon. Unnecessary exposure of pediatric patients to FNA procedure can be avoided by appropriate clinical follow up. FNA is indicated in cases where clinical picture offers no explanation for lymph node enlargement, when lymph node enlargement persists or even increases in spite of therapy administered. In adult patients, any lymph node enlargement requires attention and search for the causative agent (local or systemic infection). Injuries or skin changes on lower extremities and genitourinary tract inflammation are the most common causes of inguinal lymph node enlargement. By analogy, axillary lymph nodes respond with enlargement to respective lesions of upper extremities, thorax and breast. Inflammatory lesions in the head and neck region generally lead to reactive changes in cervical lymph nodes. In addition to reactive and inflammatory changes in acute inflammation, lymph nodes may also be involved in granulomatous changes (such as tuberculosis, sarcoidosis, etc.), fungal diseases, parasitoses (toxoplasmosis, leishmaniasis), etc. All these localizations may also be involved in storage diseases in children, metastatic lesions of epithelial and non-epithelial tumors, or at the onset of primary malignant lymph node diseases, i.e. malignant lymphomas (Hodgkin's and non-Hodgkin's). In particular, FNA is indicated in case of solid, painless nodes that occur in clusters, do not decrease with therapy, or are found supraclavicularly, in the mediastinum or intra-abdominally. Recently, useful data in the differential diagnosis of enlarged lymph nodes have been provided by ultrasonography (US) diagnosis. The US characteristics of enlarged lymph node can prove useful for node selection for FNA, and US guidance is irreplaceable in FNA of deep non-palpable nodes at any localization (e.g., neck, groin, axilla, abdomen).

In order to issue reports that will be comprehensible, clear and useful for both the patients and primary care physicians, the cytologist has to be familiar with clinical manifestations of the diseases, and to have all relevant

clinical data on the patient available. The best results are obtained when cytologist performs FNA by himself¹³. The procedure also requires close collaboration of the cytologist, the patient and the primary care physician. Collaboration with other diagnostic professions, e.g., pathology, laboratory, molecular and cytogenetic diagnosis, is no less important. In such an environment, cytology can provide optimal results, within the shortest time and at lowest cost possible. Cytologic report of lymph node FNA includes description of the cytologic picture, conclusive opinion in case of definitive finding, and recommendations for additional diagnostic work-up when the nature or cause of the disease could not be identified on the cytologic grounds alone, in spite of all additional technologies applied¹⁴.

There are virtually no contraindications for lymph node FNA, and all lymph nodes are accessible for FNA. Besides superficial, palpable lymph nodes, FNA can also be performed in deep seated lymph nodes (abdominal or mediastinal) with the help of US, computerized tomography (CT), magnetic resonance (MR), or endoscopic instruments. Superficial lymph node FNA is performed as an outpatient procedure, without anesthesia, by means of thin needles (0.5–0.7 mm in diameter, 25 or 22 gauge), and the patient can resume his/her regular daily activities immediately upon the procedure. There are no special instructions for the patient prior to the procedure, which causes only minor painful sensation. With due caution, FNA can also be performed in patients with decreased platelet count, minor coagulogram aberrations, and even those on anticoagulant therapy. Complications such as hemorrhage at the puncture site or infections are very rare. Antiseptic measures taken before and after FNA and appropriate compression at the puncture site can generally prevent any undesired events. Intra-abdominal and intrathoracic node FNA for diagnostic purpose requires one-day hospitalization (intrathoracic and retroperitoneal nodes in particular). In case of enlarged mesenteric nodes or nodes located more superficially in the abdomen, FNA can be performed in day hospital where the patient stays for several hours for observation. These FNA procedures are done under US, CT or MR guidance, mostly also without local or general anesthesia, with the use of longer and very thin, CHIBA needles (0.7 mm in diameter, 22 gauge).

Lymphatic tissue is very limited in its ability for morphological reaction to various living agents and their products (toxins), or chemical substances or other agents that most commonly cause benign lymphadenopathies. That means that a number of etiologic entities will result in a limited number of types of inflammatory reaction or hyperplasia in affected lymph node¹⁵. Various adjuvant laboratory techniques can help when the morphology alone is not sufficient in achieving an accurate diagnosis, in lymphomas in particular. The primary role of cytology is in the diagnosis of reactive hyperplasias, infections, granulomatous and metastatic processes¹⁶.

Reactive and inflammatory lesions (nonspecific and specific) have a characteristic cytologic picture and can

be quite easily differentiated in the majority of cases, along with morphology and history data. Malignant lymphomas are a heterogeneous group of monoclonal neoplastic diseases that originate from the immune system. Various types of non-Hodgkin's lymphoma may have similar morphology with great variations in the origin, immunophenotype and other biological characteristics.

The most widely used adjuvant technologies in the diagnosis of lymphoma include flow cytometry, immunocytochemistry, polymerase chain reaction (PCR), conventional cytogenetics and/or fluorescent *in situ* hybridization (FISH), and kinetic methods (DNA cytometry). FNA sample can be used in for all these analyses and, depending on the clinical picture, can be obtained on initial FNA or later, after in the first cytological report the suspicion of lymphoma was raised. Immunocytochemistry plays a major role in the diagnosis and subtyping of malignant lymphomas, and also in the differential diagnosis of lymphomas versus poorly differentiated tumors of another cell origin. In the latter, there are a number of cellular antigens, and using the combinations of various antibodies, in most cases it can be determined whether it is a lymphoma or a non-lymphoid neoplasm of epithelial, neuroendocrine, histiocytic, smooth muscle, striated muscle, embryonal, etc. origin; even, in some cases the organ of tumor origin can be determined¹⁶. Flow cytometry helps in differentiating reactive hyperplasias and malignant lymphomas by determining the lymphatic cell clonality (light kappa/lambda chain restriction) and in lymphoma subtyping by determining the degree of lymphatic cell differentiation¹⁷. Very useful is information on rearrangement of the immunoglobulin heavy or light chain gene or T lymphocyte receptor gene, suggesting the lymphatic cell B or T clonality, i.e. the diagnosis of malignant lymphoma. It is determined by molecular diagnosis using polymerase chain reaction (PCR). Chromosomal aberrations can be identified by conventional cytogenetics or FISH, that are highly relevant in the diagnosis, subclassification and prognostic assessment of lymphoma. When lymphoma is cytologically verified on initial testing, it should be followed by lymph node biopsy and histopathologic analysis. In case of relapse, determination of disease dissemination and detection of minimal residual disease, cytologic sample supplemented with adjuvant technologies is adequate to make the diagnosis¹².

The algorithms for the diagnosis of enlarged lymph node include FNA as the first diagnostic method, followed by the adjuvant technologies described above (Figure 1)¹³. It should be noted that FNA is associated with lower risk than operative procedure, especially in immunocompromised patients (e.g., HIV positive), while the risk of infection for medical staff performing the procedure is also reduced¹⁸. Unfortunately, patients with benign lymphadenopathy continue to be quite frequently referred for surgical extirpation and histopathologic diagnosis as the first differential diagnostic option¹⁴.

Besides blood cell count (red and white blood cells and platelet), a hematologic patient's condition is monitored by morphological analysis of blood smear, i.e. differential

blood count. In addition to quantitative parameters (approximate assessment of white blood cell count and platelet count), differential blood count is irreplaceable in qualitative analysis of all three blood cell types, i.e. in the assessment of diseases of red cell line (variation in the size, shape, chromasia, red blood cell inclusions, etc.), white cell line (neutrophilic, eosinophilic or basophilic granulocytes, lymphocytes, monocytes, and other cells that are not normally found in peripheral blood, a finding of immature forms), and platelet cell line (macroplatelets, platelet aggregates), which can help in reaching an accurate diagnosis earlier or redirect additional differential diagnosis. Special attention should be paid to pancytopenia (a condition characterized by the presence of anemia, leukopenia and thrombocytopenia), where bone marrow aspiration is absolutely indicated.

The next step in the diagnosis of hematologic conditions and diseases is bone marrow analysis. FNA is performed in the region of the sternum, spina cristae anterior or posterior, and in small children in the tibial area. When performed by an experienced professional, the procedure is very simple, easily done in outpatient setting, and the patient can immediately resume his/her daily activities. Upon disinfection of the puncture site, anesthesia is induced with 2% Xylocaine solution, which acts promptly and puncture can be performed immediately upon injecting the anesthetic. The patient should be warned of the possible allergic reaction and, if there are data on previous reaction to the anesthetic, bone marrow aspiration should be performed without anesthesia. Experience has suggested that the procedure performed in the region of pelvic bone is less painful and more comfortable for the patient. It is essential to have data on the possible irradiation in the regions where bone marrow is usually aspirated. Blood cells generally do not recover or show only poor recovery in the irradiated area so there is a possibility of getting inadequate marrow specimen. The very act of marrow aspiration is painful but it only takes a moment. The site of puncture is sterile covered, and the patient can remove sterile gauze in 12–24 hours, followed by normal hygiene of the site. Complications are extremely rare. Like in other punctures, hemorrhage at the puncture site may occur in case of inappropriate compression for several minutes required to stop bleeding, or in case of hemorrhagic disorder. Another complication is the site infection due to nonsterile manipulation or premature removal of sterile cover. Very rare complications are fractures (sternum in particular) in case of extensive osteolytic lesions due to metastatic bone lesions or multiple myeloma (plasmacytoma). Therefore, the person performing FNA should be familiar with the indication and should have all history data available. In addition to skillful morphological recognition of normal and pathologic blood cells and their precursors, the analysis also requires synthesis of other laboratory and clinical data, so that the report does not only give description that will not be useful to the primary care physician or clinician. When the patient is referred for bone marrow FNA, it is very useful to produce his/her basic hematologic and lab-

oratory findings, while the cytologist will briefly examine the patient prior to the procedure to see whether there are enlarged lymph nodes, spleen enlargement, petechiae or hematomas on the skin, etc. Upon quantitative (myelogram) and qualitative analysis of cells in bone marrow aspirates, the cytologist gives conclusive opinion, integrating his/her finding in other clinical and laboratory findings, thus making the analysis meaningful, comprehensible and useful to the clinician. If the cytologist considers adjuvant technologies (immunophenotyping, cytogenetics, molecular diagnosis, bone biopsy) necessary for complete evaluation of the disease, he/she can consult with the primary care physician or hematologist/oncologist in advance, to arrange for all examinations to be performed in a single act thus avoiding repeating the procedure¹⁵.

Thyroid Cytology

Thyroid gland was the first endocrine gland accessible to fine needle aspiration and cytologic analysis that was performed on the palpable thyroid enlargement, nodular or diffuse. Ultrasound (US) diagnostics enabled controlled – targeted FNA of the nonpalpable lesions.

The introduction of US into the algorithm for thyroid diagnostics has provoked several questions. The former incidence of 4–5% palpable thyroid enlargements in the adult population, suddenly increased: nodular lesions are found in 40–50% thyroid glands examined by US. The questions are now: does any thyroid nodule seen on the US examination mean it is an ill thyroid gland¹⁹? Should we perform FNA on any thyroid nodule seen by US? If not – how to choose? Then, who is competent to indicate the FNA of a nonpalpable node? And, finally, who should perform US-guided FNA of thyroid gland?

In the actual algorithm of the thyroid diagnostics the palpation and serum TSH estimation are followed by the US examination, performed by specially trained doctors – sometimes even cytologists with relevant additional training in US diagnostics. The same person then indicates the FNA which is performed under the US control by a cytologist or specially trained doctor (with minimally 100 FNA of the thyroid performed yearly). Then the cytologist analyses the smears of the aspirated material (also with at least 100 thyroid aspirations examined yearly). It should be emphasised that palpable nodes should also be aspirated under the US control because of the possibility of cystic degeneration (the bigger the node, the more frequent cystic degeneration), where aspirated material often has few cellular elements. The fact that the most frequent thyroid cancer, papillary, has cystic variant in 10–15% of cases, must also be taken into consideration^{20,21}. Besides the indications for FNA of the thyroid, there are also some contraindications. One of them is anticoagulant therapy, because of many blood vessels in the thyroid. If the aspiration is indicated, an abstinence of minimum three days is necessary from such therapy. The cytologist has to be informed about all therapeutic measures applied, since the morphology of the

thyrocytes can be changed by hormonal or thyrostatic therapy.

US-guided FNA of the thyroid and cytological analysis are simple, low-cost and rapid diagnostic methods and usually give the final diagnosis. The aspirated material is smeared on the slides, air-dried and stained according to the May Grunewald-Giemsa method. The cytological report can be issued on the same day. The cytologist can indicate various additional analyses if necessary (cytochemistry, immunocytochemistry, PCR, thyroglobulin or calcitonin level determination in the aspirate).

The cytological report should contain the description of the smears and the conclusion – the diagnosis if possible, or suggestions for additional procedures, if necessary. The aspirated material can be adequate or inadequate for cytoanalysis. The inadequate material may be obtained because of insufficient education or experience of the cytologist or the US specialist, but also because of too much blood in the aspirate, when there are not enough cellular elements in the smears, or smears cannot be made if the blood coagulates on the slide. Inadequate samples should not exceed 15% of all thyroid aspirations. The cytologist indicates repeating of FNA in such case. The adequate material can be classified into three main groups: benign lesions (50–90%), malignant lesions (1–10%) and suspect lesions (5–20%). The benign lesions can be diffuse (hyperthyreosis – Graves disease, hypothyreosis – struma lymphomatosa), or, more frequently, nodular. The inflammatory thyroid diseases can be diffuse or focal. The thyroid nodes are most often colloid cysts and they can be diagnosed by the US without cytological verification. The nodular cystic degeneration or hyperplastic nodes should be diagnosed cytologically, and the epithelial atypia is an indication for the control. Cytologically diagnosed inflammatory lesions should be ultrasonographically controlled 1–2 times yearly. Subacute thyroiditis should be controlled by the US 3–4 months after the diagnosis, since the thyroid should be completely restored during this period. The US control is recommended after a period of six months in all other benign lesions.

Malignant lesions of the thyroid gland are present in 1–10% of all thyroid diseases, depending on statistical method (investigation of thyroid nodes or of the total gland). The number of newly detected thyroid cancers has increased threefold in the last 35 years, owing (at least partially) to new methods of detection (US, FNA). Papillary cancer is the most frequent one (80–90%) and it is usually easily recognized in FNA smears. The cytologist indicates the US examination of the neck lymph nodes and FNA if needed, as well as the surgical therapy. There are no solid cytologic criteria for differentiating malignant from benign follicular tumors of the thyroid. The preoperative diagnostics – cytomorphology, cytochemistry, immunocytochemistry, PCR and genetics cannot differentiate an adenoma and a follicular carcinoma. Pathohistological finding of capsular or vascular penetration of tumor is the only evidence of malignancy. Some hormonal analyses (thyroglobulin estimation in aspi-

rate or serum) and scintigraphy of the thyroid can distinguish a hormonally active tumor (adenoma) from a hormonally inactive tumor and nodular hyperplasia. The endocrinologist can decide a follow-up or surgical treatment on the basis of the US finding (size or dynamics of the node enlargement), scintigraphy findings, age, function of the thyroid^{22,23}. Oncocytic tumors, according to the WHO, represent a subtype of follicular tumor, but they are cytologically quite different from other tumors²⁴. The percentage of follicular cancers has declined after the introduction of iodine addition to the salt and this has caused relative increase of papillary tumors. The same is the case with anaplastic thyroid cancers²⁵. The third thyroid cancer by prevalence is medullary carcinoma (5–10%). This tumor is of genetic origin in nature, caused by a mutation in the RET proto-oncogene in 25–30% of cases^{25,26}. This form is classified as familial medullary carcinoma or as a part of the multiple endocrine neoplasia type 2 (MEN2). Preoperatively, cytological analysis and estimation of calcitonin level are the diagnostic methods for this type of tumor. According to the WHO, there are twelve histological variants of medullary carcinoma²⁴. In 30–40% of the cases, metastases in neck lymph nodes are found by the US examination. Such examination is very important, since there is no other therapeutic measure except surgical removing of both the primary tumor and the metastatic lymph nodes. It should be mentioned here that all family members have to be genetically examined and, if the pathological gene is found, total thyroidectomy is indicated, especially in children under five years of age.

Mixed, follicular-medullary, poorly differentiated thyroid cancer and other rare types of thyroid malignancies are now surgically treated. The finding of p53 gene mutation is characteristic for anaplastic thyroid cancer (90%)²⁷. The primary thyroid lymphoma is present with 2–4% of thyroid malignancies. The women: men ratio is 5:1 and lymphomatous struma is often the underlying condition. They appear in older age (after 60 years). It is important to recognize them cytologically since surgical excision is not an adequate treatment²⁸.

Metastatic tumors in the thyroid gland are rare. In those rare cases, the rule of cytology is in the evaluation of the tumor extension (or in searching for an unknown primary tumor), as well as in the choice of the treatment. Most frequently, metastases are from kidney, breast, lung, gastrointestinal organs and from melanoma²⁹.

In children, thyroid disorders should be evaluated by the TSH estimation, US examination – especially for detection of congenital aberrations as ectopic thyroid gland, dysgenesis of a lobe or thyroglossal duct cyst. Scintigraphy is not recommended in children. Thyroid tumors in childhood are very rare (1–2/1,000,000) and they usually present as palpable nodes or enlargement of the thyroid, often with metastases (neck lymph nodes 50–90%, distant metastases 15–30%). But, their prognosis is better than in adults, regardless of the extension of the tumor. They are papillary cancers in more than 90% of cases. Thyroid cancers which can be related to Chernobyl

accident are more aggressive and have gene mutation RET-PTC 3³⁰. They are cytologically most often diffuse and sclerosing. In the relevant articles the incidence of thyroid cancer in children from the Chernobyl area is described to be up to 20 times higher than in general population.

Papillary cancer can also be found in the cyst of the ductus thyroglossus and the surgical removing of such cyst is therefore recommended³¹.

As known, tumors of the thyroid are more frequent in women and differentiate cancers are frequent in the generative age, so they can appear in the pregnancy. Diagnostic methods are palpation, US examination and FNA if necessary. Surgical treatment is recommended in the second trimester of the pregnancy. Scintigraphy is not permitted during the whole pregnancy period as well as in the period of nursing^{32,33}.

Finally, the role of cytology and the responsibility of the cytologist should be emphasized since every cytologically diagnosed thyroid cancer, regardless of its dimensions, should be removed by total thyroidectomy. It is clear that the communication between primary practitioners and cytologists is very important and it can and should be improved.

Pulmonary Cytology

Most patients with lesions suitable for specific pulmonary cytological analysis in primary care are symptomatic ones. Predominant indication for cytological analysis is productive cough with or without blood traces in sputum³⁴. Abnormal radiological finding in asymptomatic patient is also indication for further diagnostic procedures as bronchoscopy that can be performed in outpatients, or other invasive procedures. Asthma and allergic reactions with productive cough are suitable for sputum examination, therefore finding of eosinophilic granulocytes is important for further treatment. Screening for asymptomatic patients with lung cancer was promising, but results are controversial^{35,36}. Sputum immunocytology promises much greater sensitivity than conventional sputum cytology. There are a series of both genetic and molecular alterations found in lung cancers and preneoplastic lesions. The presence of these genetic and molecular changes in sputum may be clinically useful in identifying patients with cancer or those at high-risk of developing cancer. Identified changes in lung cancer include the detection of loss of heterozygosity (LOH), microsatellite alterations or instability (MIN), mutations in specific genes, cancer specific methylation changes and the detection of mutant gene products. This suggests that chromosomal analysis may allow detection of premalignant changes in the airway epithelium long before it would be apparent on CT and may serve as a high-risk marker for lung cancer³⁷.

Some studies include sputum cytological and molecular biomarkers analysis in subjects at high-risk for lung cancer (≥ 30 pack-years smoking history and chronic obstructive pulmonary disease defined by spirometry). Prelimi-

nary results showed that severe atypia or worse cytological changes in the sputum represent a high-risk for developing lung cancer within a short time³⁶. Specimens in pulmonary cytology can be exfoliative and FNA-s. Among exfoliative most common are spontaneously obtained sputum, rarely induced sputum, smears of nasal mucosa, aspirates, bronchoalveolar lavage fluid (BALF), brush imprints and biopsy imprints (lesions in bronchus or lungs) obtained during bronchoscopy, pleural effusions and imprints of pleural needle biopsies, intraoperatively obtained imprints of lung, pleural and mediastinal tumours, lesions and lymph nodes³⁸. Instructions for sputum sampling are necessary for adequate cytological analysis. FNA-s can be obtained during bronchoscopy: lesions in bronchus, transtracheal, transbronchial puncture of lymph nodes, substrates and tumours in lungs and mediastinum in local and general anaesthesia^{38,39}. Of great diagnostic value is radiologically guided (ultrasound, x-ray or CT) percutaneous transthoracic FNA. Subcutaneous and cutaneous lesions and peripheral lymph nodes are suitable for FNA-s and cytological analysis. All cytological reports have to be properly described with conclusion made by clinical cytologist wherever possible. Malignant cytological reports are usually made according to working WHO classification of lung neoplasm's and serve as clear directions for further procedures⁴⁰. Cytological classification in small and non-small cell lung cancer is still in use, but is inadequate. New strategies in cancer treatment require differentiation between squamous cell carcinoma and adenocarcinoma. More complex are non-specific cytological reports with mild epithelial abnormalities, goblet or basal cells hyperplasia's, regular or atypical squamous metaplasia. Interpretation of these reports requires knowledge of other clinical data known to general practitioner or other specialist^{38,39}. Presence of inflammatory cells with fungi or bacteria is usually conclusive for specific cytological diagnosis. Reports with atypical squamous metaplasia and granulomatous lesions with or without necrosis require verification with repeated or different diagnostic procedures.

Gastrointestinal Cytology

Cytodiagnosis has an important place in routine evaluation of gastrointestinal organs, and has been dramatically improved by development of endoscopic techniques. The primary care physician does not have direct influence on the decision whether such a cytologic evaluation will be performed, but must be aware of the option. The cytologic analysis is made upon gastroenterologist's request, in the course of patient evaluation or during endoscopic examinations. These examinations are expensive and unpleasant for the patient. It must be kept in mind that tissue biopsies and cytologic specimens are diagnostically complementary and their combination improves the overall diagnostic accuracy. Currently, cytology is underused in the gastroenterology workup. An aim of cytology in everyday gastroenterology practice is early detection of malignancy, but some inflammatory conditions

can also be discerned. Except for primary diseases of gastrointestinal organs, it has become possible to diagnose malignant processes in neighbouring organs like lungs, lymph nodes, spleen, kidney, adrenal gland and retroperitoneal region. The metastatic disease can be readily diagnosed too, often in the liver, the lymph nodes or in the peritoneal space. Distinguishing a primary malignant process from a secondary one is necessary because the metastases may be the first sign of disease. In this case, the cytologic analysis can render a definitive diagnosis or indicate the need for other diagnostic procedures. Other clinical findings are of great value to a cytologist and have a great influence on the final cytologic report^{41,42}.

The material for cytologic analysis can be obtained by brushing during endoscopic interventions, e.g. oesophago-gastroduodenoscopy, colonoscopy or retrograde cholangiopancreatography. The flexible fiberoptic endoscope permits visually directed brushings of any grossly evident mucosal abnormality. During these procedures, a small, circular brush is pushed through the endoscope and moved over the suspected lesion. An advantage of this technique is that it permits sampling of a larger area than by biopsy forceps. It is important in cases of dysplastic changes and early carcinomas when the appearance of mucosa is still normal. Another advantage is that the brush is more flexible and allows evaluation of stenotic lesions. It should be noted that collecting material for cytology should be performed before biopsy in order to avoid contamination by blood and debris. Exfoliative cytology is the method used for superficial lesions^{41,43}. Transmucosal fine-needle aspiration (FNA) cytology has its greatest advantage in diagnosing submucosal neoplasms (carcinoids, gastrointestinal stromal tumors and lymphomas), stenosing tumors, highly infiltrative and necrotic lesions. An ultrasound (US), or other imaging technique guided percutaneous FNA cytology is often performed not only on liver, but on deeply seated retroperitoneal lesions and other abdominal organs as well. Ascites is sampled in the same way^{41,44}. Endoscopic ultrasound guided fine-needle aspiration (EUS FNA) is a relatively new technique which improves visualization of the gastrointestinal wall, abdominal organs (pancreas, liver, left kidney, spleen, adrenal glands), and periluminal lymph nodes (intrathoracic and intra-abdominal)^{45,46}. These endoscopes possess specific channels through which the ultrasound device and cytologic needle, may be inserted. It is used most frequently to diagnose early pancreatic tumors but virtually all solid or cystic structures in the scope of the instrument can be sampled. It is possible to sample more than one site during the same procedure. The brushes or aspirated material is placed on glass slides, then air-dried or immersed in 95% alcohol. It is possible to obtain additional material for cytospin and flow cytometry if the brush or needle is rinsed in saline. The accuracy of EUS-FNA is enhanced with the cytopathologist presence during the procedure, with immediate macroscopic examination of yielded material and, in some cases, rapid microscopic evaluation for material ade-

quacy. The ability to obtain cytologic material under direct visualisation provides an opportunity for prompt and accurate diagnosis. The cytologic examination provides information to guide disease-specific therapeutic interventions and prevent unnecessary operative procedures. An effective collaboration between the cytopathologist and endoscopist is necessary. The probability of yielding satisfactory material for cytologic analysis depends on the gastroenterologist's experience, nature of sampled lesion, and presence of cytotechnologist who prepares smears on site, but also depends on the brush or needle type. The cytologist's experience and access to relevant clinical data is another important issue. A cytologist must be aware of morphology of normal tissue or artifacts that can be found in specimens from the gastrointestinal tract. The same cytomorphologic picture may have varying importance in different clinical conditions. The decision about repeating the procedure is based on cellularity and adequacy of the yielded material and on fitting the finding into particular clinical circumstances. The neoplastic cells may have various levels of differentiation with respect to morphological and functional resemblance to normal cells. When they are well-differentiated there may be some difficulties to recognize their neoplastic nature. A similar problem is when they are poorly differentiated and the trouble is to reveal their origin. The cytologic diagnosis is based on a variety of cytomorphologic characteristics like nuclear and cytoplasmic appearance, presence of nucleoli, chromatin structure, cohesion between the cells, way of cell's clustering, presence of extracellular material etc. That counts for any cytologic specimen, and any organ. The ancillary diagnostic tests like immunocytochemistry and flow cytometry make a useful contribution in these situations. These techniques, including molecular testing, have both a prognostic and a diagnostic value. The cytologic report may be final or indefinite, which would indicate necessity to repeat the examination.

Although there is no direct information exchange between the cytologist and primary care physician because communication towards the primary care is done by the gastroenterologist, this is no reason for the primary physician to hesitate to contact the cytologist in order to clarify the dilemmas and seek out new information about his patient.

Breast Cytology

Breast cancer is the most common malignant disease in women and its early detection is vital for women, offering timely treatment and in many cases complete cure. Approximately 50% of patients develop metastatic disease, which is usually a terminal state. The symptoms of breast cancer are changes in the shape and size of the breast, enlarged node in the breast or axillary region, nipple retraction, changes in the appearance of the skin of the breast or nipple (thickening, redness, inflammation) and nipple discharge bloody or clear fluid that

arises from the nipple). These warning signs can be found by breast self-examination, which is necessary to perform on a regular basis, e.g. monthly, at the same time (5th to 8th day of the menstrual cycle, counting from the first appearance of menstruation). If the woman does not have menstrual cycle anymore, breast self-examination should continue on the same day each month. However, any breast nodule does not necessarily mean a malignant tumor, but it is important that the woman sees the doctor immediately to identify the origin of the lump. The risk of breast cancer increases with age. Attention should be paid to history data such as breast cancer in the family (mother, grandmother or sister, age of family members at disease onset), older primigravida (delivery of the first child after age 30), time of exposure to estrogens, etc. The women that carry inherited mutations in the BRCA1 or BRCA2 gene have a lifetime risk of breast cancer of more than 80 percent; this also applies to the women with diagnosed malignant changes of breast (especially if the lesions were bilateral) as well as those with previously diagnosed atypical lesions (atypical ductal or lobular hyperplasia), and with lobular or ductal carcinoma *in situ*.

What is the place of cytology in the diagnosis of breast disease? Algorithms for early detection of breast cancer cannot prevent the disease, but can help identify cancer in the earliest stages when treatment is most successful. Primary care physician is the first professional to identify the risk group of women according to the above listed parameters and to inform them how to do breast self-examination in addition to clinical examination (inspection and palpation). Ultrasonography (US) as a diagnostic method in early detection of breast cancer is the method of choice for younger women (age ≤ 40). Mammography is an irreplaceable imaging diagnostic method in detecting malignant breast disease, especially in the early stages. It is performed in premenopausal women in the first half of the cycle, significantly increasing the accuracy of US diagnosis of malignant and benign breast disease. In women younger than 40, mammography is only performed if needed⁴⁷. In recent years, there have been even more requests for magnetic resonance imaging (MRI). It is preferred for being a noninvasive diagnostic method and women are not exposed to radiation. However, MRI disadvantage lies in the fact that it significantly raises the cost of diagnostic work-up and is unavailable for most patients. The question remains whether it can fully replace tissue diagnosis (cytology or histopathology). Fine needle aspiration cytology (FNAC) has been used in the diagnosis of breast lesions for years and remains a cost-effective option for diagnosing breast changes. FNAC has a unique role in three main areas: (a) diagnosis of symptomatic patients as part of triple assessment; (b) staging of breast cancer, especially preoperative aspiration of axillary lymph nodes and/or intraoperative imprint cytology of sentinel lymph nodes; and (c) screening for distant metastases⁴⁸. Indications for FNA and other tissue diagnostic tests are: clinically suspicious (palpable) breast lesions, enlarged regional lymph nodes, skin changes, if

necessary bone marrow aspiration, US or mammographic suspicious (impalpable) lesions of the breast and regional lymph nodes, discharge (either spontaneous or provoked); breast nipple changes, and intraoperative cytology (imprint).

What conditions are required for successful breast FNA? Guidance for FNA is usually provided under stereotactic-, US- and more recently MRI guidance. FNA requires team work. As noted, cytologists training is crucial, but educating referring clinicians and patients about the benefits and potential pitfalls of FNA is as important^{49,50}. The accuracy of cytological diagnosis of cancer depends on team work⁵¹, visualization of the lesion during the FNA (US or stereotaxis), experience of the staff performing FNA, and adequacy of the sample obtained, proper smear preparation and processing and, finally, the experience of the cytologist in interpreting the breast samples⁴⁷. FNA may be performed by a cytologist, clinician, or radiologist. It has been repeatedly demonstrated that the best FNA result is obtained if the person interpreting the smears is the same person that performed the FNA. In women of childbearing age, samples for cytologic analysis of palpable and impalpable lesions are obtained by use of a fine needle (diameter 0.8 to 0.9 mm in diameter and 18–20 gauge) in the first half of the menstrual cycle (usually day 5–8 of the cycle), and further procedure depends on the cytologic, US and/or mammography findings. If the cytology finding is negative, and the mammography and US findings are suspicious, then the patient is referred for histopathologic verification. Discharge is also obtained in premenopausal women in the first half of the cycle (three independent samples in three days); further procedure depends on the cytology finding. Core biopsy as an alternative diagnostic method

should be used when it is likely to provide valuable diagnostic information, e.g. in the presence of microcalcifications and overt clinical malignancies scheduled for preoperative chemotherapy⁴⁸.

According to the recommendations issued by the Croatian Society of Clinical Cytology Task Force, the breast FNAC report includes: material adequacy, microscopic description, and cytological opinion. Cytological opinion includes definitive diagnosis if possible: cysts, inflammatory lesions, fibroadenoma, fibrocystic disease with or without proliferative epithelial changes (with or without atypical hyperplasia), or malignant lesions. If it is not possible to make definitive diagnosis on FNA sample, we follow mandatory recommendations for further management: (A) repeat FNAC if diagnosis is: [1] atypical hyperplasia, probably benign; and 2) atypical hyperplasia and hormone replacement therapy (HRT) – repeat FNAC after 3-month pause in taking HRT]; (B) core biopsy if diagnosis is: [1] repeat FNAC with atypical hyperplasia; 2) FNAC negative, but US – and/or mammography-suspect lesions; 3) cytologically undefined, suspect lesions; and 4) microcalcifications if stereotactic aspiration biopsy is negative]; or C) open surgical biopsy [1] CB-suspect lesions or 2) FNAC/CB – malignant lesions]⁵² (Figure 2).

Urologic Cytology

Family physicians must be informed about the possibilities of cytologic analysis in their everyday work. It is an inexpensive and noninvasive method for the evaluation of the most common patients' complaints and abnormal results of routine urine analysis. It is useful in the detection and monitoring of both renal and urinary tract disorders. The scope of clinical cytology in urology is wider than cytological analysis of urine, but limited to urologist's decision. This is particularly true when it comes to the diagnosis of prostate diseases, evaluation of renal masses or in clinical staging of malignant neoplasms. The common prostate diseases, benign hyperpla-

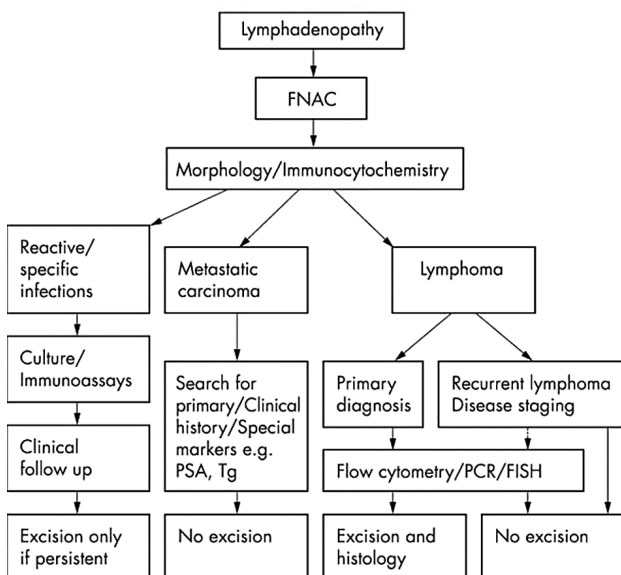


Fig. 1. Algorithm for the diagnosis of lymphadenopathy. FISH – fluorescence in situ hybridisation, FNAC – fine needle aspiration cytology, PCR – polymerase chain reaction, PSA – prostate specific antigen, Tg – thyroglobulin [KOCJAN G, 58 (2005) 561].

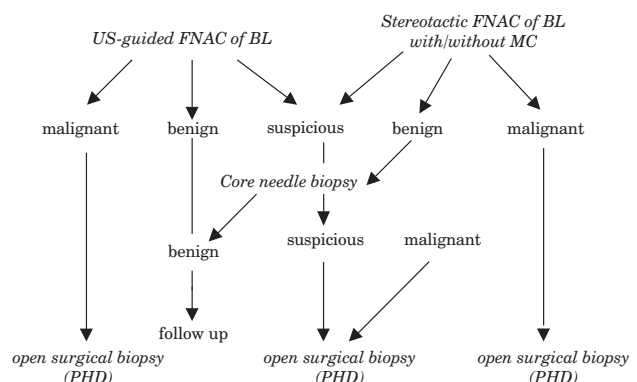


Fig. 2. Algorithm for the tissue diagnosis of breast lesions (according to the recommendations issued by the Croatian Society of Clinical Cytology). BL – breast lesions, US – ultrasound, FNAC – fine needle aspiration cytology, MC – microcalcifications, PHD – pathohistological diagnosis.

sia and carcinoma are very frequent in older male population and are generally present with obstructive symptoms and/or elevated serum prostate specific antigen (PSA). In the last two decades there is a trend to diagnose them only by core-needle biopsy. The fine-needle aspiration of prostate is underestimated and underused despite its advantages like fast, accurate diagnosis, minimal discomfort for patients, lower costs and lower frequency of complications. Bladder cancer, one of the most common malignancy in adults commonly presents with painless hematuria, but sometimes may cause cystitis-like symptoms. Obstructive symptoms are characteristic for tumours of the renal pelvis, ureter and urethra. Transitiocellular carcinomas, the most common type of urinary tract tumors, may evolve at any point of urothelial lining, including bladder, ureters, urethra and renal pelvis. These carcinomas may arise simultaneously at various points along the urinary tract, frequently recur and show heterogeneous ability to invade and metastasize. Early detection prevent tumor invasion into the tissue, therefore improving the patient's prognosis. In both acute and chronic infections cytologic urine analysis demonstrates many leukocytes and characteristic cell changes, and the infectious agent may also be identified (bacteria, yeasts, parasites or cytopathogenic effect on cells caused by viruses). It has the possibility to indicate kidney disease by the finding of renal tubular cells, casts and morphologically changed erythrocytes^{53–55}.

The volume of urine samples to be collected into a clean container should be about 50ml. Three consecutive samples of urine appear to be optimal for the cytologic evaluation. The urine specimens can be spontaneously voided or obtained instrumentally by catheterization. Washings and brushings are other methods for collecting abundant, well-preserved specimens from the urinary tract and can be performed during cystoscopy, but these procedures are invasive and expensive and carry the risk of infection. Selective catheterization of the ureters and renal pelvis with irrigation of saline improves cytologic detection of tumors in these areas and allow determination of precise origin of abnormal cells – the information that can not be obtained from voided urine specimen. Although the first spontaneously voided morning urine may provide a more cellular sample, degenerative changes are more prominent. The cells in a midday urine specimen are often better preserved, but fewer cells may be present. Patients provide their fresh urine samples in the cytology laboratory after the usual morning hygiene

at home. Lowering the urine pH by the administration of 1 g of vitamin C at bedtime, prior to collection of the urine, may improve cellular preservation. A midstream, clean-catch specimen is recommended to avoid vaginal contamination in female patients. A midstream specimen, not necessarily clean catch, is recommended for male patients. Clinical history is of utmost importance. This information includes the present symptoms, basic laboratory findings and any kind of previous urologic treatment, surgery, chemotherapy or immunotherapy. Prior history of cancer and any condition that places a patient in a high risk category for malignant or pre-malignant disease must be noted.

Cytologic urine analysis has low sensitivity and high specificity for detecting carcinomas. This means that there are no or few false positive findings and significant number of false negative results caused by reasons listed here. The likelihood of correctly diagnosed carcinoma in urine specimen rises with grade of differentiation and aggressiveness, whether in situ or invasive. Some of these tumours are small and may not be apparent at cystoscopy or by other diagnostic procedures. Similarly, the cytologic diagnosis of low grade carcinoma is often difficult, because these tumours do not shed abundant cells as the higher grade lesions do. Neoplastic cells can morphologically resemble normal urothelial cells or their changes may be reminiscent of reactive changes caused by calculi or instrumentation. The mechanical damage in these cases may induce cellular atypia and the shedding of more numerous epithelial cells⁵⁶. Unsatisfactory samples due to contamination by squamous cells, degenerative changes and inflammation contribute to this problem. Finding nonspecific changes on cells, such as atypia or dyskaryosis require follow-up on the patient. Similarly, cytologic diagnosis of an atypia on the prostate gland epithelial cells means morphologic changes, different from normal cells but not displayed enough to diagnose carcinoma. It encompasses both reactive and neoplastic changes on cells. In such situations, repeating the cytology examination after a certain time is the only choice.

General practitioners should be familiar with options and limitations of cytology. Ideally, a physician should know exactly which cytology laboratory is receiving specimens or patients referred by him or her, in order to be able to clarify possible dilemmas in direct contact. When indicated, the cytological report contains a recommendation on further management of the patient.

REFERENCES

1. MATULIĆ T, *Metamorfoze kulture* (Glas Koncila, Zagreb, 2009).
2. GAJSKI L, *Lijekovi ili priča o obmani* (Pergamena, Zagreb, 2009).
3. LOPES-CARDOZO P, *Atlas of Clinical Cytology* (Targa b.v.s., Hertogenbosch, 1976).
4. NAYLOR B, *Acta Cytol*, 44 (2000) 709.
5. MILIČIĆ-JUHAS V, LONČAR B, MAHOVLIĆ V, KARDUM-SKELIN I, PAJTLER M, *Current organisation of clinical cytology in Croatia*. In: *Proceedings (4th Croatian Congress of Clinical Cytology, Split, 2009)*.
6. ZNIDARČIĆ Z, PAJTLER M, *Clinical cytology in Croatia today and tomorrow*. In: *STULHOFER M, KURJAK A, Clinical medicine in Croatia today and tomorrow* (Akademija medicinskih znanosti Hrvatske, Zagreb, 2002).
7. BEGOVAC J, BOŽINOVIĆ D, LISIĆ M, BARŠIĆ B, SCHÖNWALD S, *Infektologija* (Profil, Zagreb, 2006).
8. BIBBO M, *Comprehensive cytopatology*. (WB Saunders Comp., USA, 1991).
9. CHANDRA A, CROSS P, DENTON K, GILES T, HEMMING D, PAYNE C, WILSON A, WILSON P, *Cytopathol*, 20 (2009) 211.
10. LICHTMAN MA, BEUTLER E, KIPPS TJ, SELIGSOHN U, KAUSHANSKY K, PRCHAL JT, *Williams Hematology* (Mc Graw-Hill Comp. Inc., USA, 2001).
11. KATZENSTEIN AL, MUKHOPADHYAY S, MYERS JL, *Hum Pathol*, 39 (2008) 75.
12. KARDUM-SKELIN I, ŠUŠTERČIĆ D, JELIĆ PUŠKARIĆ B, FABIJANIĆ I, MILAS M, ŠIFTAR Z, KARDUM-PARO MM, KUŠEC R,

LASAN-TRČIĆ R, MINIGO H, OSTOJIĆ-KOLONIĆ S, PLANINC-PE-RAICA A, VRHOVAČ R, Bilten Krohema, 1 (2009) 40. — 13. KOCJAN G, Cytopathol, 14 (2003) 307. — 14. KARDUM-SKELIN I, FABJANIĆ I, JELIĆ PUŠKARIĆ B, ŠIFTAR Z, KARDUM-PARO MM, LASAN-TRČIĆ R, MAHOVLIĆ V, KUŠEC R, SEILI-BEKAFIGO I, Acta Med Croatica, 62 (2008) 334. — 15. ZNIDARČIĆ Ž, ČREPINKO I, JEREN T, ROGLIĆ M, NAKIĆ M, MARKOV-GLAVAŠ D, KRALJIĆ I, KARDUM-SKELIN I, Lijec Vjes, 124 (2002) 360. — 16. SABOORIAN MH, ASHFAG R, Semin Diagn Pathol, 18 (2001) 110. — 17. ZEPPA P, MARINO G, TRONCONE G, FULCINITI F, DE RENZO A, PICARDI M, BENINCASA G, ROTOLI B, VETRANI A, PALOMBINI L, Cancer, 102 (2004) 55. — 18. KARDUM-SKELIN I, Može li citomorfologija i dodatne tehnologije iz citološkog uzorka zamijeniti patohistološku dijagnozu malignih limfoma u bolesnika oboljelih od AIDS-a. In: Proceedings (7. Simpozij o spolno prenosivim bolestima i urogenitalnim infekcijama, Opatija, 2005). — 19. DOUGLAS PC, WILLIAM CE, Thyroid Cytopathology, (Springer, New York 2005). — 20. DE LOS SANTOS E, KEYHANI-ROFAGHA S, CUNNINGHAM JJ, MAZZAFERRI EL, Arch Intern Med, 150 (1990) 1422. — 21. CASTRO-GOMEZ L, KORDOVA-RAMIREZ S, DUARTE-TORRES R, ALONSO DE RUIZ P, HURTADO-LOPEZ LM, Acta Cytol, 47 (2003) 590. — 22. LIVOLIS VA, Am J Clin Patol, 97 (1992) 4234. — 23. NIKIFOROVA MN, LYNCH RA, BIDDINGER PW, ALEXANDER EK, DORN GW 2nd, TALLINI G, KROLL TG, NIKIFOROV YE, J Clin Endocrinol Metab, 88 (2003) 2318. — 24. DELELLIS RA, LLOYD RV, HEITZ PU, ENG C, (Eds) WHO classification of tumors. Pathology et genetics. Tumors of endocrine organs (IARC Press, Lyon, 2004). — 25. ROSS MCDUGALL I, Management of thyroid cancer and related nodular disease (Springer-Verlag Ltd, London, 2006). — 26. DONIS-KELLER H, DOU S, CHI D, CARLSON KM, TOSHIMA K, LAIRMORE TC, HOWE JR, MOLEY JF, GOODFELLOW P, WELLS SA Jr, Hum Mol Genet, 2 (1993) 851. — 27. ENG C, J Clin Oncol, 17 (1999) 380. — 28. LERMA E, ARGUELLES R, RIGLA M, OTAL C, CUBERTO JM, BAGUE S, CARRERAS AM, EULALIA E, GONZALES-CAMPORA R, GALERA H, PRAT J, Acta Cytol, 47 (2003) 575. — 29. GIUFFRIDA D, FERRAU F, PAPALLARDO A, AIELLO RA, BORDONARO R, CORDIO S, GIORGIO CG, SQUATRITO S, Endocrinol Invest, 26 (2003) 560. — 30. FARAHATI J, DEMIDECHIK EP, BIKO J, REINERS C, Cancer, 88 (2000) 1470. — 31. PERETZ A, LEIBERMAN E, KAPELUSHNIK J, HERSKOVITZ E, Thyroid, 14 (2004) 777. — 32. CHOE W, MCDUGALL IR, Thyroid, 4 (1994) 433. — 33. WEMEAU JL, DO CAO C, Ann Endocrinol, 63 (2002) 438. — 34. HAMILTON W, SHARP D, Fam Pract, 21 (2004) 605. — 35. ROSSI A, MAIONE P, COLANTUONI

G, DEL GAIZO F, GUERRIERO C, NICOLELLA D, FERRARA C, GRIDELLI C, Crit Rev Oncol Hemat, 56 (2005) 311. — 36. HIRSCH FR, PRINDIVILLE SA, BYERS T, Proc Am Soc Clin Oncol, 21 (2002) 301. — 37. TOCKMAN MS, MULSHINE JL, PIANTADOSI S, EROZAN YS, GUPTA PK, RUCKDESCHEL JC, TAYLOR PR, ZHUKOV T, ZHOU WH, QIAO YL, YAO SX, Clin Cancer Res, 3 (1997) 2237. — 38. KINI SR (Ed) Color Atlas of Pulmonary Cytopathology, (SV, New York, 2002). — 39. SMOJVER-JEŽEK S, PEROŠ-GOLUBIČIĆ T, TEKAVEC-TRKANJEC J, MAŽURANIĆ I, ALILOVIĆ M, Cytopathol, 18 (2007) 3. — 40. TRAVIS WD, BRAMBILLA E, MULLER-HERMELINK HK, HARRIS CC (Eds) WHO classification of tumours. Pathology and genetics of tumours of the lung, pleura, thymus and heart (IARC Press, Lyon, 2004). — 41. GEISINGER KR, SILVERMAN JF, Gastrointestinal cytology. In: SILVERBERG SG, DELELLIS RA, FRABLE W (Eds) Principles and practice of surgical pathology and cytopathology (Churchill Livingstone Inc, New York, 1997). — 42. HAMILTON SR, AALTONEN LA (Eds) WHO classification of tumours. Pathology and genetics of tumours of the digestive system (IARC Press, Lyon, 2000). — 43. VOLMAR KE, VOLLMER RT, ROUDBORT MJ, CREAGER AJ, Cancer Cytopathol, 108 (2006) 231. — 44. CENTENO BA, Cancer Control, 13 (2006) 13. — 45. JHALA NC, JHALA DN, CHIENG DC, ELOUBEIDI MA, ELTOUM IA, Am J Clin Pathol, 120 (2003) 351. — 46. PITMAN MB, DESHPANDE V, Cytopathol, 18 (2007) 331. — 47. PODOLSKI P, DRINKOVIĆ I, STANEČ M, RIES S, KARDUM-SKELIN I, PETRANOVIĆ D, Medicina, 38 (2002) 73. — 48. KOCJAN G, Acta Med Croatica, 62 (2008) 391. — 49. KOCJAN G, Cytopathology, 2 (1991) 13. — 50. PEDIO G, LANDOLT U, DIRSCH OR, Acta Cytol, 34 (1990) 906. — 51. ZNIDARČIĆ Ž, ČREPINKO I, JEREN T, ROGLIĆ M, NAKIĆ M, MARKOV-GLAVAŠ D, KRALJIĆ I, KARDUM-SKELIN I, Lijec Vjes, 124 (2002) 360. — 52. KOCJAN G, BOURGAIN C, FASSINA A, HAGMAR B, HERBERT A, KAPILA KASUM, KARDUM-SKELIN I, KLOBOVES-PREVODNIK V, KRISHNAMURTHY S, KOUTSELINI H, MAJAK B, OLSZEWSKI W, ONAL B, POHAR-MARINŠEK Z, SHABALOVA I, SMITH J, TANI E, VIELH P, WIENER H, SCHENCK U, SCHMITT F, Cytopathology, 19 (2008) 271. — 53. SCHUMANN GB, SCHUMANN JL, MARCUSSEN N Cytodiagnostic urinalysis of renal and lower urinary tract disorders (Igaku-Shoin, New York, Tokyo, 1995). — 54. KOSS LG, MELAMED MR (Eds) Koss' diagnostic cytology (Lippincott Williams and Wilkins, Baltimore, 2006). — 55. RONE VR, Urogenital tract and prostate. In: RAMZY I (Ed) Clinical cytopathology and aspiration biopsy (McGraw-Hill Companies, Inc., Hong Kong, 2001). — 56. KAPUR U, VENKATARAMAN G, WOJCIK EM, Cancer Cytopathol, 114 (2008) 270.

Ž. Znidarčić

Buličeva 8, 10 000 Zagreb, Croatia
e-mail: zznidarc@inet.hr

KLINIČKA CITOLOGIJA I PRIMARNA ZDRAVSTVENA ZAŠTITA DJECE I ODRASLIH

SAŽETAK

Klinička je citologija medicinska dijagnostička struka, poznata poglavito kao Papa test u ginekologiji, ali se ona primjenjuje u gotovo svim medicinskim strukama. Njene su prednosti visoki stupanj točnosti, jednostavna tehnika, mala ili nikakva agresivnost i mali troškovi, ali se unatoč tome ne koristi dovoljno u praksi. U medicinskoj praksi, kao i u medicinskoj znanosti, a i u edukaciji, danas je na prvom mjestu profit, a ne stvarna dobrobit bolesnika. Liječnici u primarnoj zdravstvenoj zaštiti nemaju dovoljno prilike da upoznaju sve mogućnosti citološke dijagnostike, iako bi to bilo potrebno upravo zbog njene prednosti u smanjenju troškova i koristi za bolesnike. O toj temi održana je rasprava za okruglim stolom na 4. Hrvatskom kongresu kliničke citologije, održanom u Splitu od 11. do 14. listopada 2009. godine u organizaciji Hrvatskog društva za kliničku citologiju Hrvatskog liječničkog zbora, usmjerena na informiranje liječnika u primarnoj zdravstvenoj zaštiti djece i odraslih o mogućnostima citološke dijagnostike. Bilo je riječi o indikacijama za citodijagnostiku u zaraznim bolestima (T. Jeren i A. Vince), hematologiji (I. Kardum-Skelin), pulmologiji (S. Smojver-Ježek), bolestima štitnjače (A. Knežević-Obad) i dojke (I. Kardum-Skelin), te u gastroenterologiji i urologiji (G. Kaić), kao i o tehničkim postupcima te o interpretaciji citoloških nalaza. Voditeljica rasprave (Ž. Znidarčić) održala je uvodno izlaganje o kliničkoj citologiji i njejoj ulozi u primarnoj zdravstvenoj skrbi. U zaključku je naglašena potreba bolje komunikacije između liječnika primarne zdravstvene skrbi i citologa. U članku su prikazani tekstovi ove rasprave.