

Myeloid Sarcoma Involving the Breast

Biljana Jelić-Puškaric¹, Slobodanka Ostojić-Kolonić^{2,4}, Ana Planinc-Peraica^{2,4},
Dragica Obad-Kovačević³, Ika Kardum-Skelin^{1,4} and Branimir Jakšić^{2,4}

¹ Department of Medicine, Laboratory for Cytology and Hematology, »Mercur« University Hospital, Zagreb, Croatia

² Department of Medicine, »Mercur« University Hospital, Zagreb, Croatia

³ Department of Diagnostic and Interventional Radiology, »Mercur« University Hospital, Zagreb, Croatia

⁴ Zagreb University, School of Medicine, Zagreb, Croatia

ABSTRACT

Myeloid sarcoma is a tumor mass with extramedullary growth pattern, composed of myeloblasts or immature myeloid cells. The development of myeloid sarcoma may precede or concur with acute or chronic myeloid leukemia (AML or CML) or other myeloproliferative diseases or myelodysplastic syndromes (MDS). Isolated myeloid sarcoma of the breast is very rare. A case is presented of a 25-year-old, previously healthy woman that presented to our department for a palpable node, 5x2 cm in size, in the upper medial quadrant of her left breast. Fine needle aspiration (FNA) produced a sample consisting of medium sized blasts. Additional work-up revealed anemia, thrombocytopenia and leukocytosis, along with atypical blasts detected in peripheral blood and bone marrow smear. Based on the morphology, cytochemical characteristics and immature cell immunophenotype, it was considered a case of acute myeloid leukemia without maturation. In spite of intensive chemotherapy, the patient died within a year of diagnosis. In cases of isolated breast myeloid sarcoma, the diagnosis can be missed if the possibility of myeloid sarcoma is not remembered on differential diagnosis of a breast neoplasm.

Key words: myeloid sarcoma of the breast, acute myeloid leukemia

Introduction

Myeloid sarcoma is an extramedullary tumor mass composed of myeloblasts or immature myeloid cells¹. These tumors are known by a variety of synonyms in literature, including chloroma, granulocytic sarcoma, monocytic sarcoma, myeloblastoma and extramedullary myeloid tumor². Myeloid sarcoma was first described by A. Burns in 1811³, but the term chloroma was first used by King in 1853 due to the presence of myeloperoxidase which gives these tumors the green color⁴. The development of myeloid sarcoma may precede or concur with acute or chronic myeloid leukemia (AML or CML) or with other types of myeloproliferative diseases or myelodysplastic syndromes (MDS)^{1,5}. A myeloid sarcoma can be the first manifestation of relapse in remission in a previously treated patient with AML¹. The most common sites of myeloid sarcoma include bone (skull, paranasal sinuses, sternum, ribs, vertebrae and pelvis), lymph nodes, skin and soft tissue^{1,2,5–10}. According to the litera-

ture, breast tissue is an unusual site of myeloid sarcoma⁵.

Case Report

A 25-year-old female patient presented with a painless, left breast mass discovered on self-examination. She did not give a history of associated local symptoms such as nipple discharge or retraction. She was otherwise in good health. She had no other symptoms, had negative past medical and family history. On clinical examination, the lump was in the upper medial quadrant of her left breast, 5x2 cm in size. Ultrasound scan of the breast showed a hypoechoic area with well defined margin in the upper medial quadrant of the left breast. Fine needle aspiration (FNA) was then performed which showed a large number of medium sized blasts of dispersed, gentle

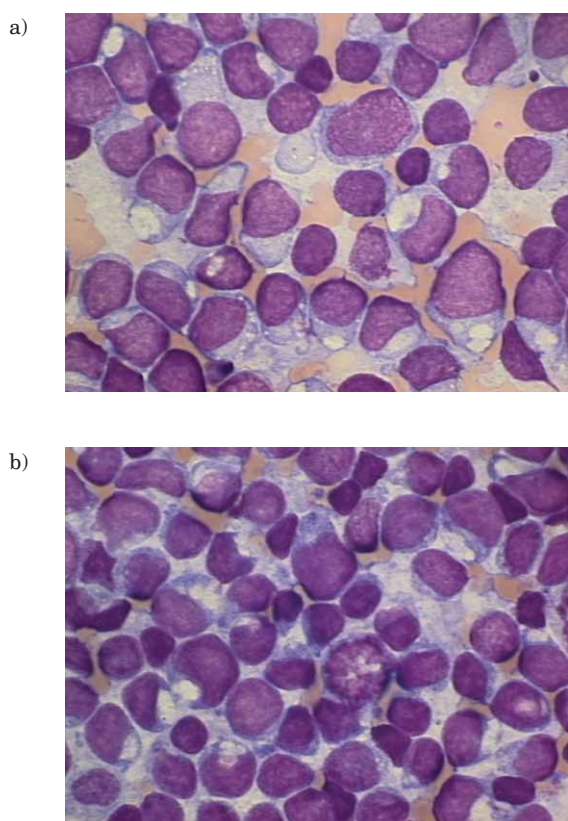


Fig. 1. Immature tumor cells in breast FNA (May-Grünwald-Giemsa, x1000).

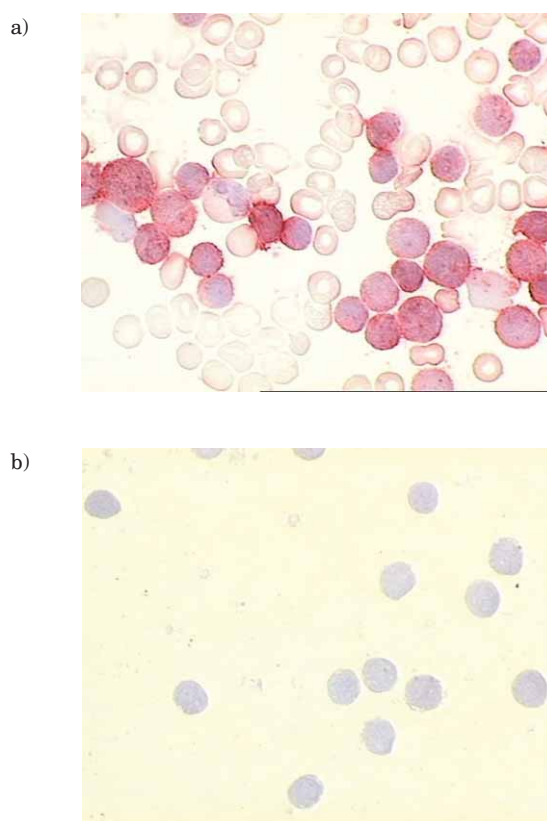


Fig. 2. a) Myeloperoxidase positive tumor cells in breast FNA (immunocytochemistry, LSAB x1000), b) CD10 negative tumor cells in breast FNA (immunocytochemistry, LSAB x1000).

chromatin structure and basophil cytoplasm showing negative cytochemical reaction to PAS, nonspecific esterase and myeloperoxidase (MPO); however, immunocytochemistry yielded positive reaction to MPO and negative reaction to lymphocytic markers CD20, CD3 and CD10 (Figures 1 and 2). FNA was reported as a myeloid sarcoma. Additional work-up confirmed this diagnosis.

Laboratory findings were anemia (red blood cell count $3.8 \times 10^{12}/L$, hemoglobin 106 g/L), thrombocytopenia (platelet count $53 \times 10^9/L$) and leukocytosis (white blood cell count $11 \times 10^9/L$). Bone marrow aspirate yielded a hypercellular sample of bone marrow with 97% of atypical blasts of the same cytochemical and immunocytochemical characteristics as the breast aspirate sample (Figure 3). Atypical blasts were also detected in peripheral blood smear (76%). On flow cytometry, the phenotype of the breast and bone marrow aspirate samples showed a very high percentage expression of the immature myeloid cell markers CD34, CD33 and HLA DR. Cytogenetic analysis of the breast and bone marrow aspirate samples indicated numerous alterations (81,XX,-X,-X,-7,-8,-8,-9, add(17p)x2,-18,-18[15]/46,xx[3]). Based on the morphology, cytochemical characteristics and immature cell immunophenotype, it was considered a case of AML without maturation. Bone marrow biopsy was also performed and confirmed the diagnosis of acute leukemia. The patient was treated with chemotherapy for AML. Remission

was shortly achieved, and then the patient experienced two relapses in the bone marrow and breast 6 and 12 months later. She died within 1 year of the diagnosis.

Discussion and Conclusion

Myeloid sarcoma is an unusual variant of myeloid malignancy, presenting as an extramedullary tumor consisting of immature granulocytic cells^{1,2,5-10}. The most common type of myeloid sarcoma is granulocytic sarcoma composed of myeloblasts, neutrophils and neutrophil precursors¹. According to the World Health Organization classification, the tumors are classified into three types based on the degree of maturation: blastic type (composed primarily of myeloblasts), immature type (composed of myeloblasts and promyelocytes) and differentiated type (composed of promyelocytes and more mature neutrophils)¹.

Monoblastic sarcoma is a less common type of myeloid sarcoma, which is usually composed of monoblasts and can precede or concur with acute monoblastic leukemia¹. In cases of transformation of chronic myeloproliferative disorders, myeloid sarcoma can be associated with trilineage hematopoiesis or erythroid precursors or megakaryocytes¹. Myeloid sarcoma usually develops concurrently or following the diagnosis of AML^{1,5}. It varies rarely

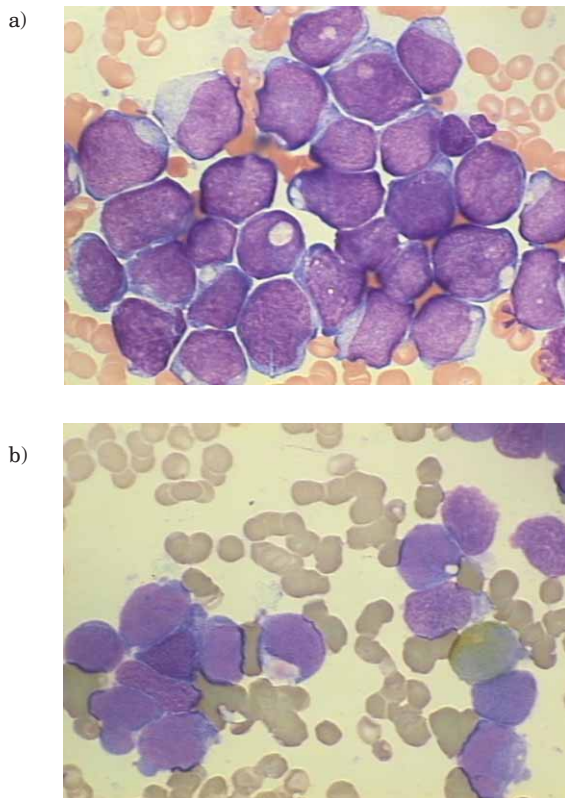


Fig. 3. a) Tumor cells in bone marrow aspirate (May-Grünwald-Giemsa, x1000), b) myeloperoxidase negative tumor cells in bone marrow aspirate (cytochemistry, x1000).

precedes leukemia, presenting as an isolated extramedullary tumor mass without blood or bone marrow involvement^{8,9}. About 95% of patients with isolated myeloid sarcoma develop AML within 1–48 months⁹. The most common sites of myeloid sarcoma are bone, lymph nodes, skin and soft tissue^{1,2,5–10}. Breast tissue is an unusual site of myeloid sarcoma⁵. Myeloid sarcoma of the breast develops synchronously or following the diagnosis of AML, and only 6% develop primarily in the breast without bone marrow involvement⁸. In our patient, myeloid sarcoma of the breast was the first manifestation of the disease. However, additional examinations revealed immature cells multiplied in the bone marrow and peripheral blood, leading to the diagnosis of AML. The majority of patients with myeloid sarcoma of the breast present with unilat-

eral breast mass, rarely with bilateral mass⁶. Although patients are usually female, breast myeloid sarcoma has also been reported in male patients, presenting with gynecomastia². The patients usually had no local symptoms such as nipple discharge or retraction⁶. Our patient was also female, presented with unilateral breast mass and had no local symptoms.

According to the literature, the age of patients at presentation ranges from 16 to 72⁶. Due to the rarity of myeloid sarcoma of the breast, the diagnosis can be missed, especially in cases of isolated breast tumor mass without blood and bone marrow involvement, if the possibility of myeloid sarcoma is not remembered on differential diagnosis of a breast neoplasm⁸. Imaging (mammography, ultrasonography and magnetic resonance) produces varied appearances and makes it difficult to differentiate myeloid sarcoma from other disorders like breast carcinoma or lymphoma⁶. The differential diagnosis includes a different type of hematopoietic (diffuse large B-cell lymphoma, anaplastic large-cell lymphoma, lymphoblastic lymphoma and Burkitt lymphoma) and non-hematopoietic malignancies (breast carcinoma, melanoma and sarcoma)^{2,6–9,11}. The differential diagnosis should also include non-neoplastic conditions like inflammation and extramedullary hematopoiesis⁵. Myeloid sarcoma with a large number of mature myeloid cells and histiocytes could be misdiagnosed with an acute inflammatory process⁵. Small round cell tumors (neuroblastoma, rhabdomyosarcoma, Ewing's/PNET, and medulloblastoma) should also be considered, particularly in children¹. Immunophenotyping by immunocytochemistry and flow cytometry for expression of myelomonocytic antigens are essential to make a correct diagnosis^{1,7}. An immunocytochemical panel which includes MPO, CD20, CD43 and CD68 can diagnose about 96% of myeloid sarcoma cases⁷. In our case, immunocytochemistry yielded positive reaction to myeloperoxidase and negative reaction to lymphocytic markers CD20, CD3 and CD10, while flow cytometry showed a very high percentage expression of the immature myeloid cell markers CD34, CD33 and HLA DR. An early and accurate diagnosis of breast myeloid sarcoma can save patients from unnecessary surgery. Appropriate chemotherapy may lead to complete remission or prolong patient survival. Differential diagnosis of breast tumor masses should include myeloid sarcoma of the breast to avoid inappropriate treatment of this tumor and improve patient prognosis^{6,7,9}.

REFERENCES

1. JAFFE ES, HARRIS NL, STEIN H, VARDIMAN JW, Pathology and Genetics of Tumours of Haematopoietic and Lymphoid Tissues (IARC-Press, Lyon, 2001). — 2. D'COSTA GF, HASTAK MS, PATIL YV, Indian J Med Sci, 61 (2007) 152. — 3. BURNS A, Head and Neck (Royce, London, 1811). — 4. KING A, Month J Med, 17 (1853) 97. — 5. NGU IWY, SINCLAIR EC, GREENAWAY S, GREENBERG ML, Diagn Cytopathol, 24 (2001) 53. — 6. THACHIL J, RICHARDS RM, COPELAND G, Ann R Coll Surg Engl, 89 (2007) 7. — 7. CUI Y, ZHOU JL, WU JH, ZHANG JZ, Chin Med J, 121 (2008) 1854. — 8. AZIM HA, GIGLI F, PRUNERI G, MARTNELLI G, TRAVAINI LL, PETRALIA G, PECCATORI FA, J Clin Oncol, 26 (2008) 4041. — 9. DUTTA ROY S, STAFFORD JS, SCALLY J, SELVACHANDRAN SN, Breast, 13 (2004) 242. — 10. SHEA B, REDDY V, ABBITT P, BENDA R, DOUGLAS V, WINGARD J, Breast, 10 (2004) 48. — 11. KAIĆ G, ŠTOOS-VEIĆ T, TRUTIN OSTOVIĆ K, VOJNOVIĆ J, VIDOVIĆ LJ, LAMBAŠA S, HARIŠ V, AJDUKOVIĆ R, STANEC S, BUDI S, Coll Antropol, 34 (2010) 193.

B. Jelić Puškarić

Laboratory for Cytology and Hematology, Department of Medicine, »Merkur« University Hospital, Zajčeva 19, 10000 Zagreb, Croatia

e-mail: biljana.jelic.puskaric@zg.t-com.hr

MIJELOIDNI SARKOM DOJKE

S A Ž E T A K

Mijeloidni sarkom je ekstramedularna tumorska masa građena od mijeloblasta ili nezrelih mijeloičnih stanica. Može predhoditi ili se javiti istovremeno s akutnom ili kroničnom mijeloičnom leukemijom ili drugim tipovima mijeloproliferativnih bolesti ili mijelodisplastičnih sindroma. Izolirani mijeloidni sarkom dojke javlja se vrlo rijetko. Prikazujemo slučaj dvadesetpetogodišnje, do tada zdrave žene koja se javlja na kliniku radi palpabilnog čvora, veličine 5x2 cm u području gornjeg medijalnog kvadranta lijeve dojke. Citološkom punkcijom čvora tankom iglom dobije se uzorak srednje velikih blasta. U laboratorijskim nalazima nađe se anemija, trombocitopenija i leukocitoza, uz prisutne atipične blaste u razmazu periferne krvi i punktatu koštane srži. Obzirom na morfologiju, citokemijska obilježja i imunofenotip nezrelih stanica zaključeno je da se radi o akutnoj mijeloičnoj leukemiji bez sazrijevanja. Unatoč intenzivnoj kemoterapiji pacijentica umire unutar godinu dana od postavljenja dijagnoze. U slučaju izoliranog mijeloidnog sarkoma dojke može se previdjeti točna dijagnoza ako se u diferencijalnoj dijagnozi tumora dojke ne razmišlja o mijeloidnom sarkomu.