

Polyomavirus Associated Nephropathy after Kidney and Pancreas Transplantation: Case Report

Sonja Gracin¹, Ivana Kovačević Vojtušek¹, Željko Vidas², Mladen Knotek^{1,5}, Ika Kardum Skelin^{3,5} and Danica Ljubanović^{4,5}

¹ Department of Nephrology, »Mercur« University Hospital, Zagreb, Croatia

² Department of Urology, »Mercur« University Hospital, Zagreb, Croatia

³ Cytology Laboratory, »Mercur« University Hospital, Zagreb, Croatia

⁴ Department of Pathology, Dubrava University Hospital, Zagreb, Croatia

⁵ Zagreb University, School of Medicine, Zagreb, Croatia

ABSTRACT

Polyomavirus virus associated nephropathy (PVAN) is an important cause of graft failure in the renal transplant population. The prevalence of PVAN has increased from 1% to 10% in the past decade, leading to loss of transplanted organ in 30% to 80% of cases. In the absence of specific antiviral drugs, early detection of disease and modification/reduction of immunosuppressive regimen is currently the cornerstone of therapy. In the setting of multiorgan transplantation, like simultaneous pancreas and kidney transplantation (SPKT), diagnosis and therapy of PVAN can be even more challenging problem. We report a first described case of PVAN in patient after SPKT in Croatia. Patient is a 32 years old Caucasian male with type 1 diabetes mellitus and end stage renal failure, diagnosed for PVAN 6 month after SPKT. Patient was treated with reduced immunosuppressive regimen. At 32 month follow up, patient has preserved kidney and pancreas function with estimated glomerular filtration (eGFR) rate of 91 mL/min and no signs of PVAN on his 2 year protocol kidney biopsy.

Key words: polyomavirus, pancreas and kidney transplantation, immunosuppressive minimization therapy

Introduction

Polyomavirus-associated nephropathy (PVAN) is caused by BK virus (BKV) and has emerged in the last decade as one of major causes of allograft failure in renal transplant recipients. Polyomavirus disease is defined as histopathological or ultrastructural evidence of polyomavirus induced cytopathic damage and organ involvement¹. The prevalence of PVAN has increased and now ranges between 1% and 10%. This infection carries a poor prognosis with reported renal allograft loss from 10% to >80%^{1,2}. The majority of PVAN cases occur within the first year posttransplantation, but approximately a quarter of cases are diagnosed later¹.

Intense immunosuppression is perceived as a major risk factor for PVAN. The majority of patients reported to date received combinations containing tacrolimus and mycophenolate mophetil (MMF)³. Brennan DC et al. demonstrated, in prospective study, an increased risk of

tacrolimus-MMF-corticosteroid combination for BKV replication and PVAN⁴.

In two major single center reports published on SPKT patients, a relatively high incidence (6.2–7.5%) of PVAN was noted. These reports have suggested that patients with PVAN following SPKT may represent a difficult subgroup of patients to manage compared with renal transplant only recipients⁵.

Diagnosis of PVAN is based on the based on invasive and non-invasive tests. Of noninvasive tests used are: 1) cytology-detection of decoy cells in the urine which has a high negative predictive value, but low positive predictive value (PPV); 2) quantification of viral DNA by real time polymerase chain reaction (PCR) in urine and plasma. Plasma BK viral load of over 10⁴ copies/mL is a sensi-

tive and specific marker for PVAN with a positive predictive value between 50–60%^{6,7,14}. »Gold standard« in diagnosing PVAN is renal biopsy together with immunohistochemical analysis which utilizes monoclonal antibodies toward viral proteins⁶. The mainstay of therapy is prompt immunosuppressive dose reduction. It is not clear whether the reduction or elimination of antimetabolites is more effective than reduction of calcineurin inhibitor. No antiviral drug with proven efficacy against the BKV has been licensed, but number of drugs have been explored in small series of cases like: cidofovir, leflunomide and derivatives, fluoroquinolones, intravenous immunoglobulin⁷.

Case Report

We present a 32 year old Caucasian male with type 1 diabetes mellitus since he was eight years old, with proliferative retinopathy and diabetic nephropathy which progressed to renal failure four years prior to transplantation. Since than patient was on intermittent haemodialysis therapy. Patient underwent his first simultaneous kidney and pancreas transplantation (SPKT) in November 2006. He received induction therapy with daclizumab, tacrolimus, mycophenolat mofetil and steroids and had immediate recovery of kidney and pancreas function.

His serum creatinine on discharge was 157 μmol/L with estimated glomerular filtration rate (eGFR) of 63 mL/min. In the second month after SPKT his serum creatinine was 104 μmol/L and eGFR was 101 mL/min. Four month after SPKT he had an episode of sepsis caused by *Pseudomonas aeruginosa*. At that point his kidney function declined for about 30% which has afterwards only partially recovered. Sixth. month after SPKT his serum creatinine has increased to 137 μmol/L with eGFR of 81 mL/min (Figure 1). Protocol urine cytology screening at that point was positive for decoy cells. Kidney allograft biopsy was performed at that time. Kidney biopsy revealed dense tubulointerstitial infiltrate with mononuclear cells associated with edema and tubulitis

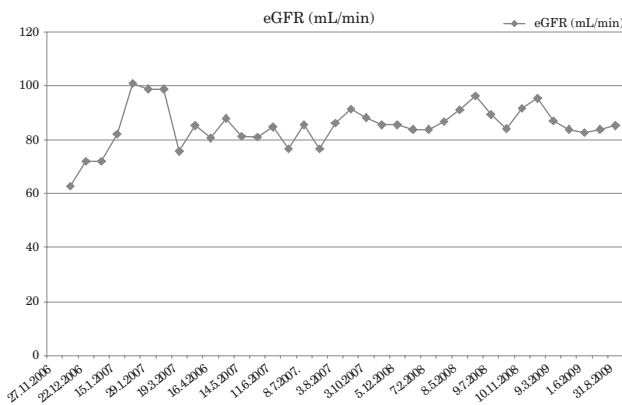


Fig. 1. Glomerular filtration rate (GFR) curve during 32 months follow up. At 32 month follow up patient has GFR of 91.3 mL/min. GFR was estimated by Cockcroft Gault formula.

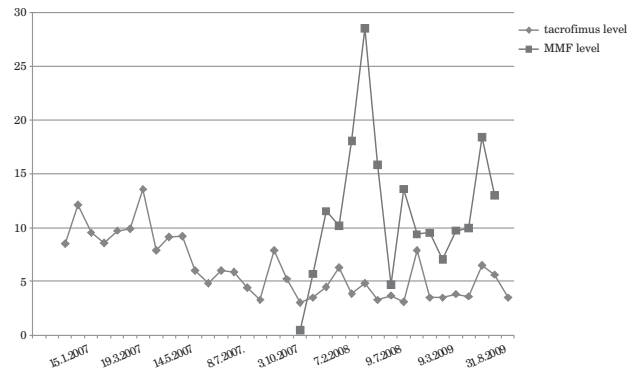


Fig. 2. Serum concentrations of immunosuppressive drugs; tacrolimus (blue line) and mycophenolate mofetil (MMF) (red line) during 32 month follow up. Since December 2007, serum concentrations of mycophenolate mofetil have been measured routinely in our center.

(Figure 3). BKV inclusions were proven by immunohistochemical analysis (Figure 4).

Therefore, we decided to minimize his immunosuppression therapy. We have reduced doses of both calcineurin inhibitor and mycophenolat mofetil (MMF) and tapered steroids. Target levels of tacrolimus after PVAN was diagnosed were 3–6 ng/mL, MMF dose was reduced for 50% to a daily dose of 1000 mg/day and steroids were tapered from 30 mg initially to 5 mg daily at 6 month after SPKT. During whole period of follow up patient remained on minimized triple immunosuppressive therapy (Figure 2).

His kidney function was stable with mean eGFR of 80 mL/min during follow up. At 1-year protocol kidney biopsy, initial chronic changes were present with no signs of rejection nor PVAN. Interstitial fibrosis and tubular atrophy with dense mononuclear infiltrate was present in about 15% of biopsy material of 15 glomeruli. Scor of chronic changes was ci1, ct1, cg0, mm0, cv0, ah1 regarding to Banff classification⁸. Electron microscopy and immunohistochemical analysis were negative for BKV.

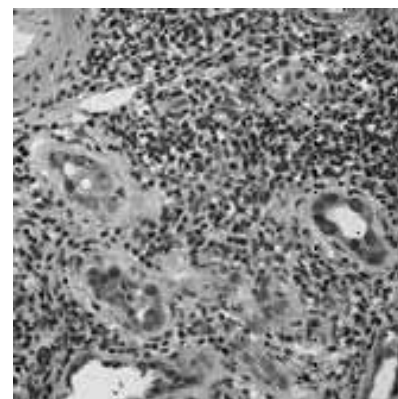


Fig. 3. Histology finding of PVAN in kidney allograftof by light microscopy (hemalaun eosin staining). It shows diffuse mononuclear cell infiltration,heavy tubulitis (>10 lymphocytes on 10 tubular epithelial cells). Many tubular epithelial cells express nuclear vacuolisation and viral inclusions.

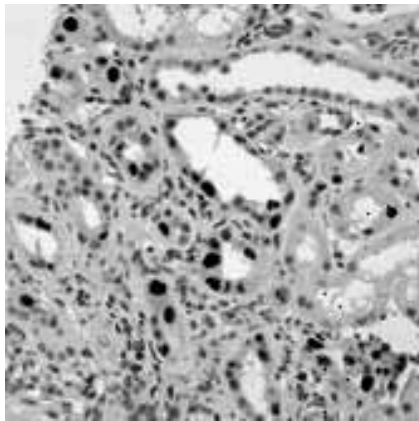


Fig. 4. Positive immunohistochemistry staining for BKV (brown coloured nuclei). BKV- BK virus.

His renal function declined for 10 mL/min 2.5 years after SPKT (95.5 mL/min to 84 mL/min). Kidney biopsy was done and revealed borderline acute cellular rejection and mild to moderate chronic changes (Banff '97). Score of acute changes was: i1, t2, g0, v0, ptc0, C4d0 and score of chronic changes was: ci1, ct1, cg0, mm0, cv0, ah1⁸. Immunohistochemical analysis was negative to BKV. Patient received a course of steroid antirejection therapy. On his last visit, his creatinine level is 120 μ mol/L and eGFR is 91 mL/min. Endocrine and exocrine pancreas function were normal. Negativization of decoy cells in urine has never been achieved. Quantification PCR test for BKV in plasma was not available in Croatia until September 2009 so unfortunately we were not able to follow up viraemia in this patient.

Discussion and Conclusion

Polyomavirus associated nephropathy has emerged as an important cause of allograft loss and renal dysfunction in renal transplant recipients^{1,2}. Use of tacrolimus compared to cyclosporine, or MMF compared to azathioprine, in maintenance immunosuppression has been implicated as an important determinant of BK viraemia, viremia and nephropathy⁴. Prevalence of PVAN in different centers ranges from 1% to 10%^{1,2}.

We have presented first case of PVAN after SPKT in Croatia. Both allografts have been successfully preserved

during 32 month of follow up by minimization of maintenance immunosuppressive therapy only. Goal levels of tacrolimus during follow up were 3–6 ng/mL, MMF dose was reduced by 50% (1000 mg daily) and steroid tapered to 5 mg per day. Prevalence of PVAN in our center is 1.7% or overall 3 patients. We have been able to successfully preserve kidney allografts in 2 patients. One kidney allograft has been lost due to multiple rejection episodes, uncontrollable PVAN, one episode of humoral rejection and surgical complications related to ureteral stenosis. BK virus surveillance protocol in our center consists of: cytology screening test for decoy cells in urine at 1, 3, 6, 12 months, protocol kidney biopsy at zero, 3 month, 6 month and 1 year time with immunohistochemical analysis for BKV when indicated. Since quantification PCR test for BKV in plasma has become available in Croatia at September 2009, it will be used monthly for the first 6 month after transplantation, every second month up to 1 year, than yearly.

Among 3 patients with PVAN in our center, this patient underwent treatment with minimization of immunosuppression therapy, only. Because patient has had stable renal function during the follow up and no signs of PVAN on 1 year protocol biopsy we have decided to continue MMF without adding antiviral agent. Patient had one biopsy proven acute cellular rejection episode 2.5 years after SPKT with no signs of PVAN. Looking back on this case in 2006, we believe we should have performed control renal biopsy earlier after PVAN was diagnosed rather than wait until one year protocol biopsy, especially in the setting of not being able to monitor BK viraemia at that time.

There are different treatment approaches and one is unlikely to be satisfactory until safe and effective antiviral drugs are discovered. Different approaches to treatment of BK nephropathy have been reported. Some centers use serial monitoring of viral load in urine and blood and preemptively withdraw antimetabolites upon detecting viraemia⁴, other use standard immunosuppression reduction⁹ or antiviral treatment¹³. Antiviral agents used for treatment of BK nephropathy include cidofovir, leflunomide, quinolone antibiotics and intravenous immunoglobulin^{1,11,13}. Prospective randomized studies with standardized treatment protocols are urgently required.

REFERENCES

- HIRSCH HH, BRENNAN DC, DRACHENBERG CB, GINEVRI F, GORDON J, LIMAYE AP, MIHATSCH MJ, NICKELEIT V, RAMOS E, RANDHAWA P, SHAPIRO R, STEIGER J, SUTHANTHIRAN M, TROFE J, *Transplantation*, 79 (2005) 1277. — 2. BOUDREAULT AA, COURTE-MANCHE C, LATULIPPE E, COTE E, HOUE I, DESCHENES L, *J Clin Virol*, 45 (2009) 318. — 3. HIRSCH HH, STEIGER J, *Lancet Infect Dis*, 3 (2003) 611. — 4. BRENNAN DC, AGHA I, BOHL DL, SCHNITZLER MA, HARDINGER KL, LOCKWOOD M, TORRENCE S, SCHUESLER R, ROBY T, GAUDREAULT-KEENER M, STORCH GA, *Am J Transplant*, 5 (2005) 582. — 5. GUPTA G, SHAPIRO R, THAI N, RANDHAWA SP, VATS A, *Transplantation*, 82 (2006) 382. — 6. SESSA A, ESPOSITO A, BERGALLO GM, COSTA C, ROSSANO R, LETTIERI E, CA-PUANO M, *Transplant Proc*, 40 (2008) 2055. — 7. HILTON R, TONG CYW, *J Antimicrob Chemother*, 62 (2008) 855. — 8. SOLEZ K, COLVIN RB, RACUSEN LC, HAAS M, SIS B, MENGEL M, HALLORAN PF, BALDWIN W, BANFI G, COLLINS AB, COSIO F, DAVID DS, DRACHENBERG C, EINECKE G, FOGO AB, GIBSON IW, ISKANDAR SS, KRAUS E, LERUT E, MANNON RB, MIHATSCH M, NANKIVELL BJ, NICKELEIT V, PAPADIMITRIOU JC, RANDHAWA P, REGELE H, RENAUDIN K, ROBERTS I, SERON D, SMITH RN, VALENTE M. *Am J Transplant*, 4 (2008) 753. — 9. BRESSOLLETTE-BODIN C, COSTEBUREL M, HOURMANT M, SEBILLE V, ANDRE-GARNIER E, IMBERT-MARCILLE BM, *Am J Transplant*, 5 (2005) 1926. — 10. RANDHAWA P, RAMOS E, *Transplant Rev*, 21 (2007) 77. — 11. LEUNG ANS-

KAR YH, CHAN M, TANG SYDNEY CW, LIANG R, KWONG YL, J Virol Methods, 103 (2002) 51. — 12. GUASCH A, Results of phase 2, randomized, open label, multicenter study to assess the efficacy and safety of FK778 compared with standard care (SC) in renal transplant recipients with untreated BK nephropathy. (American Transplant Congress, San Francisco, CA, 2007). — 13. KOVAČEVIĆ-VOJTUŠEK I, GRACIN S,

KNOTEK M, LJUBANOVIĆ D, KARDUM-SKELIN I, SABLJAR-MATOVINOVIĆ M, Coll Antropol, 34 (2010) 1–255. — 14. VIDAS Z, MIŠIĆ M, PAČIĆ A, JURENEC F, KNOTEK M, KARDUM-SKELIN I, Coll Antropol, 34 (2010) 153.

S. Gracin

*Department of Neurology, »Mercur« University Hospital, Zajčeva 19, 10 000 Zagreb, Croatia
e-mail: sonja.gracin@gmail.com*

POLIOMAVIRUSOM UZROKOVANA NEFROPATIJA NAKON SIMULTANE TRANSPLANTACIJE BUBREGA I GUŠTERAČE – PRIKAZ SLUČAJA

S A Ž E T A K

Poliomavirusom uzrokovana nefropatija (PVAN) važan je uzrok disfunkcije i gubitka grafta bubrega nakon transplantacije. Prevalencija PVAN-a se povećala od 1% do 10% u posljednjih 10 godina i uzrokom je gubitka grafta bubrega u 30% do 80% slučajeva. Rana otkrivanje bolesti i modificiranje imunosupresivne terapije predstavljaju temelj liječenja. Specifična antiviralna terapija ne postoji. Dijagnostika i liječenje PVAN u bolesnika nakon multiorganske transplantacije, kao što je simultana transplantacija bubrega i gušterače (SPKT), predstavlja još veći izazov. Ovdje predstavljamo prvi opisani slučaj PVAN-a u bolesnika nakon SPKT u Hrvatskoj. Bolesnik je bio bijelac u dobi od 32 godine, koji boluje od tipa 1 šećerne bolesti i terminalne kronične bubrežne insuficijencije i koji je liječen simultanom transplantacijom bubrega i gušterače. PVAN je dijagnosticirana 6 mjeseci nakon SPKT. Liječen je smanjenjem doze trojne imunosupresivne terapije (takrolimus, mikofenolat mofetil i steroidi). Bolesnik ima očuvanu funkciju oba grafta nakon 32 mjeseca praćenja. Procijenjena glomerularna filtracija i znosi 91 mL/min bez znakova PVAN-a na protokol biopsiji bubrega nakon 2 godine.