



Morphological variations of the limbic-lobar border cortex on the inner side of human brain hemisphere

GORAN SPASOJEVIĆ¹,
ZLATAN ŠTOJANOVIĆ¹,
DUŠAN ŠUŠČEVIĆ¹,
SLOBODAN MALOBABIĆ²,
SAŠA VUJNOVIĆ³

¹ Department for Anatomy
Faculty of Medicine Banja Luka
Save Mrkalja 14
78000 Banja Luka
RS, Bosnia and Herzegovina

² Institute of Anatomy
Faculty of Medicine Belgrade
Dr Subotića 4/II
11000 Belgrade, Serbia

³ Department for Radiology
Clinical Centre Banja Luka
12 Beba bb
78000 Banja Luka
RS, Bosnia and Herzegovina

Correspondence:

Goran Spasojević
Department for Anatomy
Faculty of Medicine Banja Luka
Save Mrkalja 14
78000 Banja Luka
RS, Bosnia and Herzegovina

Key words: limbic-lobar border, brain asymmetry, sulcus cinguli/paracinguli, sulcus subparietalis, transitional gyri.

Abbreviations:

- **SCG:** sulcus cinguli,
- **SPC:** sulcus paracinguli,
- **SSP:** sulcus subparietalis,
- **GTS:** gyri transitivi superficiales.

Received February 20, 2009.

Abstract

Background and Purpose: Medial side of brain hemispheres is divided into two cortical regions: the inner region – limbic, and the outer region – lobar one. As the limbic region is responsible for vegetative and sexual functions, memory and cognition, the outer region – lobar cortex of medial brain side is the seat of associative, sensorimotor and sensorial regions. By studying the morphology and morphometry of brain medial side sulci: sulcus cinguli (SCG), sulcus subparietalis (SSP) and presence of gyri transitivi superficiales (GTS), this work aims to research variability of the limbic-lobar border area, as well as the presence of right/left brain asymmetry – the phenomenon of function lateralization.

Material and Methods: Morphological examination was performed on 42 brains (84 hemispheres) taken from persons of both sexes and different age at death (26 males and 16 women, 20–65 years old), who had no pathological changes on the brain. The brains were fixated in 10% formalin during 4 weeks, after which the brain membranes were removed. After morphological classification we measured the length of SCG i SSP by digital morphometry with AutoCAD software. We also determined the frequency of transitional gyri: gyrus frontolimbicus in anterior, gyrus lobulolimbicus in medial, and gyrus precuneolimbicus and gyrus cuneolimbicus in posterior part of the cortex.

Results: The length of sulcus cinguli on the left was 146.38mm, on the right 145.93mm ($p > 0.05$). Summing the lengths of sulcus cinguli and sulcus paracinguli (where the latter was found), showed statistically significant difference on left hemispheres (left: 196.66mm, right: 168.35mm, $p < 0.01$). The results of length measurements for sulcus subparietalis, on the left side: 78.33mm, on the right: 72.55mm, did not show statistical significance ($p > 0.05$). The frequency of transitional gyri were: gyrus frontolimbicus (one transitional gyrus 32.2%, two transitional gyri 5.9%), gyrus lobulolimbicus (16.7%), gyrus precuneolimbicus (anterior 61.9%, medius 8.3%, posterior 85.7%) and gyrus cuneolimbicus (2.4 %).

Conclusion: Cumulative length of sulcus cinguli and sulcus paracinguli is statistically higher on left hemispheres, what implicates the Left/Right brain asymmetry and presence of lateralized functions on medial limbic-associative cortical border.

INTRODUCTION

Brain cortex (cortex cerebri) of the medial side of telencephalon hemispheres is divided into two cortical regions: the inner – limbic and the outer – lobar region. The following sulci divide the outer region from the inner limbic part of the medial and lower side of hemispheres:

sulcus cinguli, sulcus subparietalis, sulcus collateralis and sulcus rhinalis. The cortex of limbic region is responsible for vegetative and sexual functions, memory and cognition, while the outer – lobar cortex of the medial side of hemispheres contains associative, sensorimotor and sensorial areas (prefrontal associative cortex, primary somato-motor area, supplemental motor area, primary somato-sensitive area, visual cortex – area striata etc.). Sulcus cinguli (SCG) is the largest sulcus on the inner side of brain hemispheres: it starts under rostrum corpori callosi, goes parallel with corpus callosum until the area above splenium corpori callosi, where it bends towards the upper edge of hemispheres and ends behind the ending part of sulcus centralis. There are two basic parts on sulcus cinguli that can be differentiated: the front part – pars subfrontalis, and the end part – pars (ramus) marginalis. SCG has dorsal branches (towards lobar region) and ventral branches (towards limbic region). SCG can be clearly seen as early as at eighteenth week of gestation (1). SCG shows different morphological variations like continuous, segmented or doubled sulcus (2–6).

Sulcus subparietalis (SSP) is situated on the border of precuneus and gyrus cinguli. This sulcus has different morphological forms and can be anastomosed with sulcus cinguli. It is developing in 26th week of gestation (1). Morphological characteristics of both SCG and SSP, like segmentation and variations of sulci anastomoses create transitional gyri that connect gyri of lobar and limbic regions (gyri transitivi superficiales).

By studying the morphology and morphometry of brain medial side sulci: sulcus cinguli (SCG), sulcus subparietalis (SSP) and presence of gyri transitivi superficiales (GTS), this work aims to research variability of the limbic-lobar border area, as well as the presence of right/left brain asymmetry – the phenomenon of function lateralization.

MATERIAL AND METHODS

Morphological examination was performed on 42 brains (84 hemispheres) taken from persons of both sexes

and different age at death (26 males and 16 women, 20–65 years old), who had no pathological changes on the brain. The brains were fixated in 10% formalin during 4 weeks, after which the brain membranes were removed. Hemispheres were separated by medio-sagittal cut through fissura longitudinalis cerebri and were photographed with Olympus digital camera with resolution 8Mpx. The photographing was performed from a standard distance of 50cm, at a right angle with the surface of medio-sagittal brain cut.

After morphological classification of SCG and SSP we measured the length of both by digital morphometry with AutoCAD software (Picture 1). We also classified peripheral branches, and determined the anastomoses of SCG and SSP with adjacent sulci. Significance of SCG and SSP length differences depending on the hemisphere side (right/left asymmetry) was determined by Student T-test of dependant samples. The research also covered the frequency of transitional gyri: gyrus fronto-

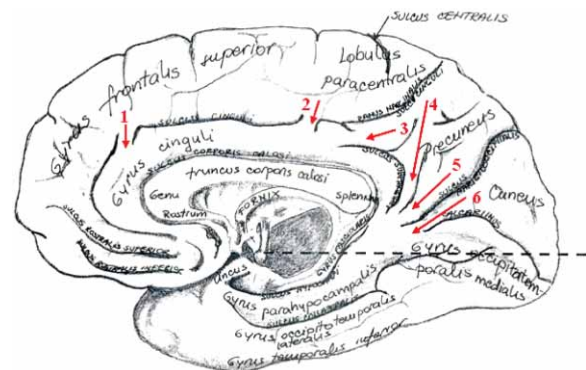


Diagram 1. Medial side (facies medialis) of human brain hemispheres. Brain sulci, gyri and transitional gyri. (1 – gyrus frontolimbicus, 2 – gyrus lobulolimbicus, 3 – gyrus precuneolimbicus anterior; 4 – gyrus precuneolimbicus medius, 5 – gyrus precuneolimbicus posterior; 6 – gyrus cuneolimbicus)

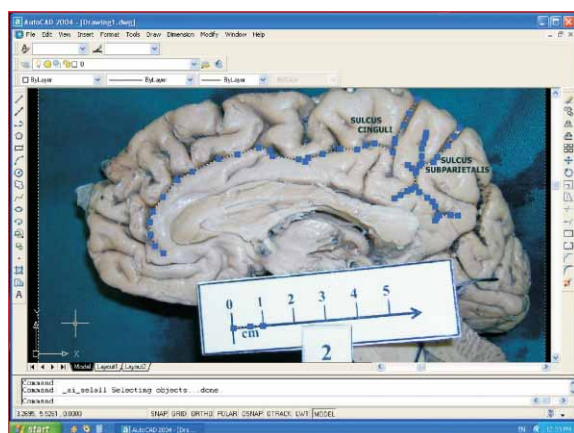


Figure 1. AutoCAD digital morphometry of sulcus cinguli and sulcus subparietalis (explanation in work methodology)

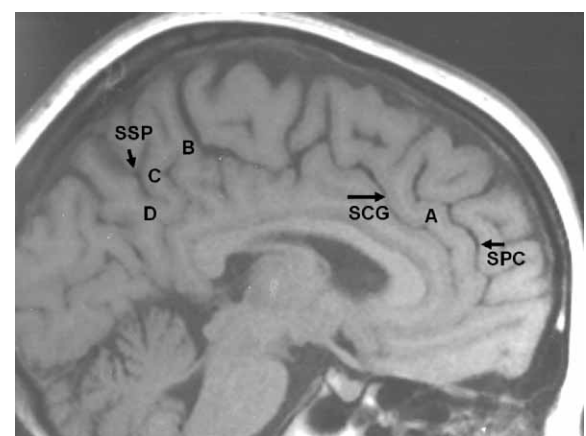


Figure 2. Brain NMR: brain sulci, gyri and transitional gyri, medial side (facies medialis) of human brain hemispheres (SCG – sulcus cinguli, SPC – sulcus paracinguli, SSP – sulcus subparietalis, A – gyrus frontolimbicus, B – gyrus precuneolimbicus anterior; C – gyrus precuneolimbicus medius, D – gyrus precuneolimbicus posterior)

limbicus in frontal, gyrus lobulolimbicus in medial, gyrus precuneolimbicus and gyrus cuneolimbicus in posterior part of the cortex. (Diagram 1). The mentioned brain sulci and transitional gyri can be seen and examined *in vivo* by NMR (Picture 2).

RESULTS

I – Sulcus cinguli (SCG)

Morphologically, sulcus cinguli (SCG) is classified into the following types:

- type 1: sulcus cinguli continuous, without sulcus paracinguli (SPC) (Picture 1),
- type 2: sulcus cinguli segmented into two or more segments, without SPC (Picture 3),

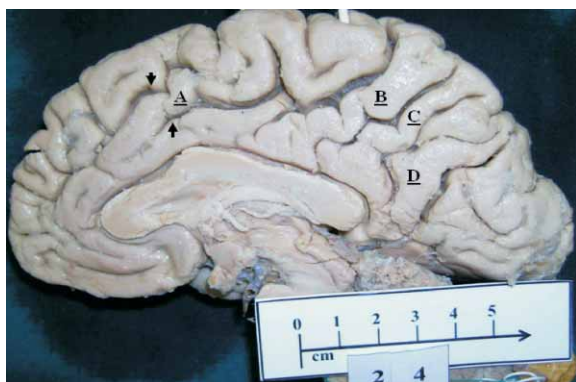


Figure 3. Sulcus cinguli segmented (type 2) – marked with arrows, and transitional gyri (A,B,C,D) (arrows – segmentation of sulcus cinguli; A – gyrus frontolimbicus; B – gyrus precuneolimbicus ant., C – gyrus precuneolimbicus med., D – gyrus precuneolimbicus post.)

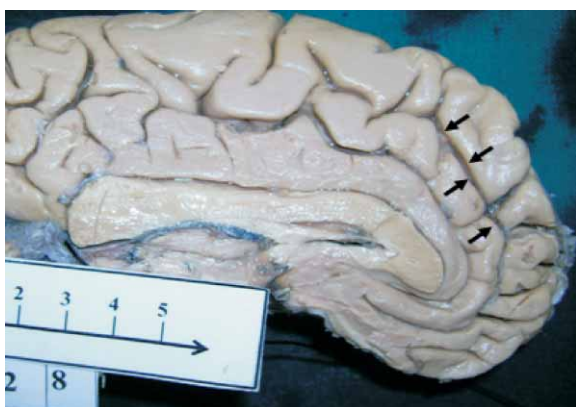


Figure 4. Sulcus cinguli with sulcus paracinguli (arrows) – type 3.

TABLE 1

Morphological types and anastomoses of sulcus cinguli.

SCG morphological type	No. Of samples	Frequency (%)
type 1	31	36.9
type 2	15	17.9
type 3	26	30.9
type 4	12	14.3
total	84	100
Anastomoses of SCG with:		
– sulcus rostralis superior	25	29.8
– sulcus subcallosus anterior	17	20.2
– sulcus subparietalis	30	35.7
SCG front part without anastomoses	32	38.1

- type 3: sulcus cinguli continuous or segmented, with the presence of SPC (Picture 4),
- type 4: unclassified type of SCG.

The frequency of morphological types and anastomoses of SCG with adjacent sulci are shown in the Table 1.

Peripheral branches of SCG are classified as follows (Table 2):

- rami frontales (towards gyrus frontalis superior),
- rami lobulares (towards lobulus paracentralis),
- rami cinguli (towards gyrus cinguli),
- ramus marginalis (edging branch of sulcus cinguli),
- ramus posterior (posterior branch of sulcus cinguli).

Measuring of sulcus cinguli length also included the length measurements of pars subfrontalis sulci cinguli, and ramus marginalis SCG (Table 3).

Results of morphological examination of sulcus cinguli depending on hemisphere side (right/left) are shown in Tables 4 and 5 and Graph 1.

The difference in sulcus cinguli length on right and left hemisphere is not statistically significant ($p > 0.05$).

TABLE 3

Results of sulcus cinguli length measurements (sample of 84 hemispheres).

SCG	N	X (mm)	SD (mm)	CV (%)	Max (mm)	Min (mm)
	84	146.16	13.48	9.22	181	105

TABLE 2

Side branches of sulcus cinguli.

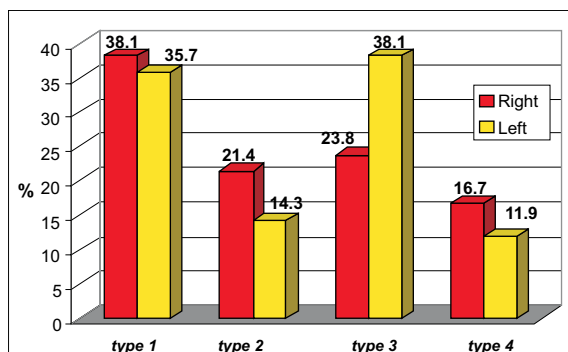
Branches /No./	rr. Frontales 2 – 8	rr. Lobulares <2	rr. Cinguli <5	r. Marginalis 1	r. Posterior <1
Frequency	100%	50%	84.5%	100%	94%

After summing the lengths of sulcus cinguli and sulcus paracinguli, the difference was highly statistically significant – length on left hemisphere $p < 0.01$ (Table 6).

TABLE 4

Morphological types and anastomoses of sulcus cinguli depending on hemisphere side, sample of 84 hemispheres (42 right + 42 left).

SCG morphological type	Right hemisphere	Left hemisphere
type 1	38.1	35.7
type 2	21.4	14.3
type 3	23.8	38.1
type 4	16.7	11.9
total	100%	100%
Anastomoses of SCG with:		
– sulcus rostralis superior	30.1%	28.6%
– sulcus subcallosus anterior	14.3%	26.1%
– sulcus subparietalis	42.8%	28.6%
SCG front part without anastomoses	45.2%	30.9%



Graph 1. Frequency of sulcus cinguli types depending on hemisphere side.

TABLE 5

Results of sulcus cinguli length measurements depending on the hemisphere side.

SCG	N	X (mm)	SD (mm)	CV (%)	Max (mm)	Min (mm)
Right	42	145.93	13.84	9.48	181	105
Left	42	146.38	13.27	9.06	179	123

TABLE 6

Results of sulcus cinguli length measurements including the length of sulcus paracinguli.

SCG	N	X (mm)	SD (mm)	CV (%)	Max (mm)	Min (mm)
Right	42	168.35	31.78	18.82	250	128
Left	42	196.66	32.48	16.31	265	137

II SULCUS SUBPARIETALIS (SSP)

Morphological types of sulcus subparietalis (SSP)

- type 1: sulcus subparietalis contains »H« connection from which the sulci diverge (Picture 5),
- type 2: sulcus subparietalis »Y«-shaped (Picture 6),
- unclassified type of SSP (Picture 1).

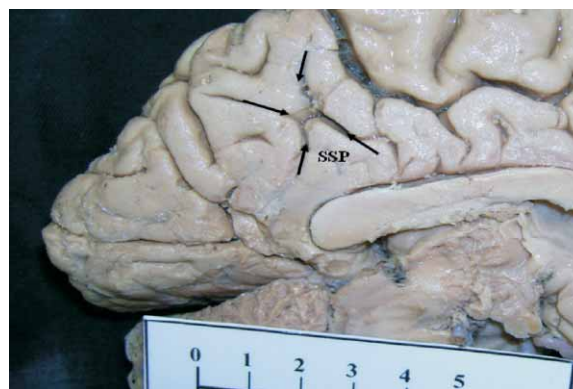


Figure 5. Sulcus subparietalis »H« (type 1).

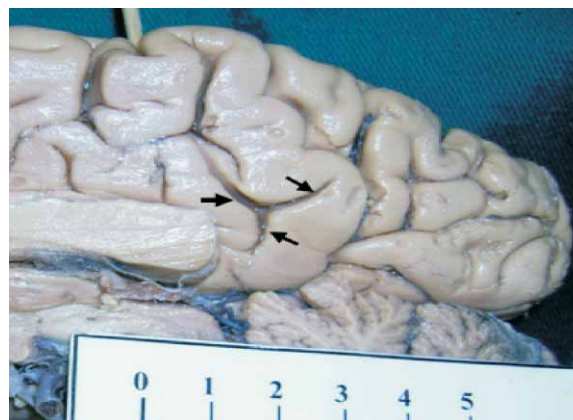
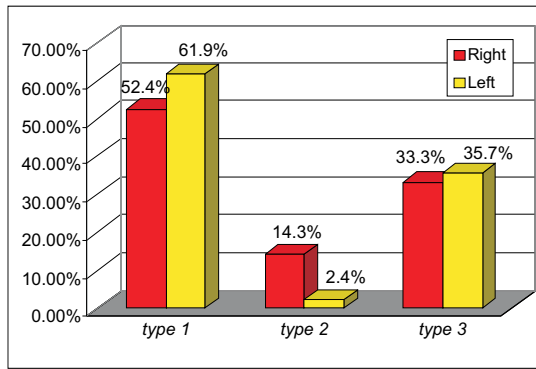


Figure 6. Sulcus subparietalis »Y« (type 2).

TABLE 7

Frequency of morphological types and anastomoses of sulcus subparietalis (sample of 84 hemispheres).

SSP Morphological type	No. Of samples	Frequency
type 1	48	57.1%
type 2	7	8.4%
unclassified	29	34.5%
total	84	100%
Anastomoses of SSP with		
– sulcus cinguli	30	35.7%
– sulcus parietooccipitalis	6	7.1%
– sulcus calcarinus anterior	2	2.4%
without anastomoses	50	59.5%



Graph 2. Frequency of types of sulcus subparietalis depending on the hemisphere side.

TABLE 8

Morphological types and anastomoses of sulcus subparietalis depending on the hemisphere side, sample of 84 hemispheres (42 right + 42 left).

SSP Morphological type	Right hemisphere	Left hemisphere
type 1	52.4%	61.9%
type 2	14.3%	2.4%
unclassified	33.3%	35.7%
total	100%	100%
Anastomoses of SSP with		
– sulcus cinguli	42.9%	28.6%
– sulcus parietooccipitalis	7.1%	7.1%
– sulcus calcarinus anterior	0%	4.8%
without anastomoses	57.8%	61.3%

TABLE 9

Results of measurement of sulcus subparietalis length (with the length of side branches).

SSP	N	X (mm)	SD (mm)	CV (%)	Max (mm)	Min (mm)
	84	75.44	15.31	20.29	109	42

TABLE 10

Results of measurements of sulcus subparietalis length depending on the hemisphere side.

SSP	N	X (mm)	SD (mm)	CV (%)	Max (mm)	Min (mm)
Right	42	72.55	13.83	19.06	105	50
Left	42	78.33	16.31	20.76	109	42

Branches of sulcus subparietalis can be divided into two groups:

- rami ventrales (towards gyrus cinguli)
- rami dorsales (towards precuneus).

Ventral and dorsal branches were present in all samples (100%). The number of ventral branches varies in interval 1–3, and number of dorsal ones 1–4.

The greater length of sulcus subparietalis on left hemispheres is not statistically significant ($p > 0.05$).

III The frequency of transitional gyri presence:

- gyrus frontolimbicus: one transitional gyrus 32.2%, two transitional gyri 5.9%;
- gyrus lobulolimbicus 16.7%;
- gyrus precuneolimbicus anterior 61.9%, medius 8.3%, posterior 85.7%;
- gyrus occipito s. cuneolimbicus 2.4% (Table 11).

TABLE 11

Frequency of transitional gyri (gyri transitivi superficiales – GTS) depending on hemisphere side, sample of 84 hemispheres (42 right + 42 left).

Name	Left	Right	Total
GFL (1 gyrus)	30.1%	33.3%	32.2%
GFL (2 gyri)	4.8%	7.1%	5.9%
GLL	9.5%	23.8%	16.7%
GPL anterior	71.4%	52.4%	61.9%
GPL posterior	76.2%	95.2%	85.7%
GPL medius	7.1%	9.5%	8.3%
GPL ant + post	50%	38.1%	44.05%
GPL ant + post + med	7.1%	9.5%	8.3%
GCL	/	4.8%	2.4%

(GFL – gyrus frontolimbicus, GLL – gyrus lobulolimbicus, GPL – gyrus precuneolimbicus, GCL – gyrus cuneolimbicus)

DISCUSSION

Sulcus cinguli (SCG) is the sulcus of the medial side of the brain hemispheres that divides gyrus frontalis superior and lobulus paracentralis from gyrus cinguli and precuneus. In total view this sulcus has the shape of an elongated letter »S«. Two basic parts can be distinguished on SCG: pars subfrontalis – parallel with the upper edge of hemispheres, and pars marginalis – posterior part that ends on the upper edge of lobulus paracentralis, behind the spot where sulcus centralis forms the upper hemisphere edge.

In our research it can be seen that the continuous sulcus cinguli without sulcus paracinguli (Type 1) is the most often morphological form found (36.9%). The same form was found by Retzius (2) in 41% of cases, by Miljaljica (3) in 46.15%, by Vogt *et al.* (4) in 40% of cases, which is consistent with our research. Sulcus cinguli divided into two or more segments without sulcus paracinguli (Type 2) was found in 17.9% cases. Paus *et al.* (5) found type 2 in 16.5%, Retzius (2) in 58% cases. Although the last result significantly disagrees with our

own research, the difference can be accounted for by the different classification of the mentioned sulcus. The results of Retzius (2) also include the presence of segmented SCG with sulcus paracinguli.

Continuous or segmented SCG with the presence of sulcus paracinguli (Type 3) is the second most often found type in our research (30.9%). The sulcus situated ventrally and dorsally of continuous or segmented SCG is called sulcus paracinguli. That name was first mentioned by Elliot Smith in 1907, citing from Paus *et al.* (5). Besides continuous and segmented sulcus cinguli, Ono *et al.* (6) introduce the notion of *parallel type sulcus cinguli*, which corresponds to sulcus paracinguli. Paus *et al.* (5) regard sulcus that is continuous and parallel to the SCG as sulcus paracinguli. In this classification we tried to include both those considerations. Ono *et al.* (6) state that in 24% of cases they found sulcus cinguli of parallel type. Paus *et al.* (5) found the presence of considerable sulcus paracinguli in 40.5% of cases, Vogt *et al.* (4) found doubled sulcus cinguli in 35% of cases (in 15% of cases doubled sulcus cinguli was continuous, and in 20% of cases it was segmented). We found unclassified form of SCG (Type 4) in 14.3% of cases, while Milaljica (3) found it in 11.5%. It is obvious that our results are consistent with the research of these authors.

Anterior part of sulcus cinguli may anastomose with sulcus subcallosus anterior (SSA) and sulcus rostralis superior (SRS). The anastomosis of SCG with SRS we found in 29.8% of cases, and with SSA in 20.2% of cases. Ono *et al.* (6) found anastomosis of SCG with SSA in 34% of cases, and with SRS in 16%, which partly disagrees with our data. Anterior part of SCG without anastomoses we found in 38.1% of cases, while Ono *et al.* (6) found it in 52%, which confirms our results.

In our research we also analyzed the branches of sulcus cinguli, and we did classify the tertiary branches according to their direction into: rami frontales, rami lobulares, ramus marginalis, ramus posterior et rami cinguli (Table 2).

Rami frontales extend ventrally and dorsally from SCG towards gyrus frontalis superior. The number of these branches varies from 2 to 8. These branches, in different number, were found in all the samples (100%). Stanczyk (7) found frontal branches in all of his samples, varying in number 1–7. Our results confirm his findings.

Rami lobulares extend dorsally from SCG towards lobulus paracentralis. These branches were found in 50% of samples, and their number varies from 1 to 2 branches. Stanczyk (7) divides lobular branches into anterior, medial and posterior, and finds anterior ones in 36% of cases, medial in 34%, and posterior in 13% of cases.

Ramus marginalis is always present ending branch of sulcus cinguli. It divides lobulus paracentralis from precuneus. Permanent presence of this branch is confirmed also by other authors: Retzius (2), Paus *et al.* (5), Stanczyk (7), Perović (8), Kostović (9).

Ramus posterior SCG is the last branch of sulcus cinguli that emerges from the spot where ramus mar-

ginalis leaves pars subfrontalis sulci cinguli, or from the anterior part of ramus marginalis. This branch is usually directed dorso-caudally and may end in the area of posterior gyrus cinguli or to anastomose with sulcus subparietalis. This branch was found in 94% of cases.

Rami cingulares SCG are vertical branches that are directed towards gyrus cinguli. We found these branches in 84.5% of cases, and their number varied from 1 to 5. Ono *et al.* (6) call those branches *lower branches of sulcus cinguli*, and recognize the branches originating from anterior and posterior part of SCG. The number of anterior branches varies from 1 to 2, and of posterior ones 1–5. Stanczyk (7) uses the name *separating branches of sulcus cinguli* and divides them according to the location in relation to corpus callosum into three groups: rami subgenuales, rami perigenuales and rami supratruncales (anterior et posterior), but does not state the number of branches.

AutoCAD measurement of sulcus cinguli length in our study included the length of pars subfrontalis and pars marginalis sulci cinguli. The average length of SCG was 146.1mm (105–181mm). Ono *et al.* (6) state the average length of 145mm, which is in concordance with our results. Although there have been found some morphological differences in frequency of certain types of SCG depending on hemisphere side, greater length of SCG on left hemispheres is not statistically significant (left: 146.38mm, right: 145.93mm, $p > 0.05$). Watkins KE *et al.* (10) state greater length of sulcus cinguli on the right side, which is in correlation with greater intra-sulci area of the anterior segment of right hemisphere SCG (Paus *et al.* (11)). By summing up the length of sulcus paracinguli, we concluded that the length of SCG on left hemispheres is highly significant (left: 196.66mm, right: 168.35mm, $p < 0.01$), which is consistent with studies Paus *et al.* (5), Yücel *et al.* (12). This difference implies the presence of lateralisation phenomenon and possible domination of left hemisphere in performing higher cortical functions of prefrontal associative cortex (*reasoning speech s. verbal thought*). Supportive to this is the fact that there is reduction of sulcus paracinguli of the left hemisphere in persons affected by or under the high risk of developing schizophrenia, in whom there is developed »picture talk« (*visual s. imaginative thought*) (13–18).

Sulcus subparietalis, as well as sulcus cinguli, belongs to the group of border sulci. It divides lobar precuneus from the posterior part of gyrus cinguli and shows variations in shape and anastomoses with adjacent sulci.

Among morphological types of sulcus subparietalis (SSP), one that contains »H« connection, from which emerge the branches of this sulcus, was the most often found type (57.1%). Ono *et al.* (6) in their classification of SSP forms found the presence of sulcus subparietalis shaped like letter »H« in 34% of cases. They also found (in 25% of cases) the presence of sulcus subparietalis shaped like deformed and elongated letter »H«. It is obvious that our results are in accordance with theirs. Morphological type 2, SSP shaped like letter »Y« was found in 8.4% of cases, presenting the rarest registered type of sulcus subparietalis.

Unclassified sulcus subparietalis (Type 3) showed different morphological characteristics that made it impossible to classify it, and it is the second most often found type (34.5%).

Sulcus subparietalis may be anastomosed with sulcus cinguli (35.7%), sulcus parietooccipitalis (7.1%), and sulcus calcarinus (2.4%). Anastomosis of sulcus subparietalis with sulcus cinguli is the most often found one. The presence of this anastomosis was described by Retzius in 1896 (2) in 34% of cases, which is in accordance with our results.

The branches of sulcus subparietalis, according to their direction, are divided into rami ventrales (oriented towards gyrus cinguli) and found in different number (1–3 branches), and rami dorsales (towards precuneus), whose number varied from 1 to 4 branches. Sulcus subparietalis branches were found in 100% of cases, but in different number. Dorsal branches of sulcus subparietalis are referred to as splenial grooves (*sulci spleniales*) by Vogt *et al.* (4), and parts of the precuneus cortex in between those branches as parasplenic lobules (lobuli paraspleniales).

AutoCAD morphometry of sulcus subparietalis included the length of all peripheral branches. The average length of SSP is 75.44mm (42–109mm), and difference in SSP length depending on the hemisphere side is not statistically significant (left: 78.33mm, right: 72.55mm, $p > 0.05$).

Morphological characteristics of examined sulci (segmentation, anastomoses) acquire the presence of transitional gyri of lobar-limbic cortex (gyri transitivi superficiales – GTS). Based on localisation and anastomoses with adjacent gyri, they are divided into frontal (anastomoses with gyrus frontalis superior), lobular (with lobulus paracentralis), precuneal and cuneal (Diagram 1, Picture 2). Stanczyk (7) states that fronto-limbic transitional gyri are found as 1–5 gyri, lobular 1–3, and parietal (which correspond to precuneal transitional gyri in our classification) also 1–3. The same author found transitional gyri on the right hemisphere in 70% of cases, and on the left in 68%. Stanczyk found fronto-limbic gyri on right hemispheres in 68% of cases, on left in 70%, and on both sides in 68%. Lobular gyri were found in 43% on the right, in 37% on the left, and in 37% on both hemispheres. The frequency of parietal (precuneolimbic) gyri on right hemispheres was 52%, on left 58%. In our study fronto-limbic and lobular transitional gyri were found in less number of cases, while the frequency of precuneolimbic transitional gyri was higher (Table 11).

CONCLUSION

The measured length of sulcus cinguli (pars subfrontalis + pars marginalis) was on the left: 146.38mm, and on the right: 145.93mm ($p > 0.05$). By summing the length of sulcus paracinguli with the length of SCG we

got statistically significant difference on left hemispheres (left: 196.66mm, right: 168.35mm, $p < 0.01$), which proves the right/left asymmetry of brain and the presence of lateralisation phenomenon on the border of limbic and frontal associative cortex of hemisphere medial side.

Morphological-morphometric examination of sulcus subparietalis length did not show the presence of right/left brain asymmetry (sulcus subparietalis left: 78.33mm, right: 72.55mm; $p > 0.05$).

REFERENCES

1. CHI JG, DOOLING EC, GILLES FH 1977 Gyral development of the human brain. *Ann Neurol* 1(1): 86–93
2. RETZIUS G 1896 Das Menschenhirn, vols 1 and 2. Norstedt Soner.
3. MILJALJICA D 1997 Morphology, asymmetry and sexual dimorphism of human gyrus cinguli. Proceedings of 39th Congress of Medicine and Dentistry Students, Novi Sad.
4. VOGT B A, NIMCHINSKY E A, VOGT L J, HOF P R 1995 Human cingulate cortex: surface features, flat maps, and cytoarchitecture. *J Comp Neurol* 359(3): 490–506
5. PAUS T, TOMAIUOLO F, OTAKY N *et al.* 1996 Mar-Apr Human cingulate and paracingulate sulci: pattern, variability, asymmetry, and probabilistic map *Cereb Cortex*. 6 (2): 207–14
6. MICHIO ONO, STEFAN KUBIK, CHAD D. ABERNATHEY 1990 Atlas of the cerebral sulci. Thieme Medical Publishers, New York.
7. STANCZYK J L 1983 Variations of the gyrus and sulcus cinguli in phylo- and ontogenesis. *Folia Morphol (Warsz)* 42(4): 243–69
8. PEROVIĆ D 1964 Anatomija čovjeka, knjiga II. Medicinska knjiga, Beograd–Zagreb.
9. KOSTOVIĆ I 1986 Anatomija centralnog nervnog sistema. Medicinar, Zagreb.
10. WATKINS K E, PAUS T, LERCH J P *et al.* 2001 Structural asymmetries in the human brain: a voxel-based statistical analysis of 142 MRI scans. *Cereb Cortex* 11(9): 868–77
11. PAUS T, OTAKY N, CARAMANOS Z *et al.* 1996 Dec In vivo morphometry of the intrasulcal gray matter in the human cingulate, paracingulate, and superior-rostral sulci: hemispheric asymmetries, gender differences and probability maps. *J Comp Neurol* 376(4): 664–73
12. YUCEL M, STUART G W, MARUFF P *et al.* 2001 Hemispheric and gender-related differences in the gross morphology of the anterior cingulate/paracingulate cortex in normal volunteers: an MRI morphometric study. *Cereb Cortex* 11(1): 17–25
13. FORNITO A, YUCEL M, WOOD S J *et al.* 2006 Morphology of the paracingulate sulcus and executive cognition in schizophrenia. *Schizophr Res* 88(1–3): 192–7
14. LE PROVOST J B, BARTRES-FAZ D, PAILLIERE-MARTINOT M L *et al.* 2003 Paracingulate sulcus morphology in men with early-onset schizophrenia. *Br J Psychiatry* 182: 228–32
15. YUCEL M, STUART G W, MARUFF P *et al.* 2002 Paracingulate morphologic differences in males with established schizophrenia: a magnetic resonance imaging morphometric study. *Biol Psychiatry* 52(1): 15–23
16. WOOD S J, YUCEL M, VELAKOULIS D *et al.* 2005 Hippocampal and anterior cingulate morphology in subjects at ultra-high-risk for psychosis: the role of family history of psychotic illness. *Schizophr Res* 75(2–3): 295–301
17. YUCEL M, WOOD S J, PHILLIPS L J *et al.* 2003 Morphology of the anterior cingulate cortex in young men at ultra-high risk of developing a psychotic illness. *Br J Psychiatry* 182: 518–24
18. TEMPLE GRANDIN 2006 Thinking in pictures, the expanded edition. Vintage Press.