

Bilateral Congenital Dislocation of the Knee with Ipsilateral Developmental Dysplasia of the Hip – Report of Three Patients

Sandor Roth¹, Branko Šestan², Barbara Gruber³, Darko Ledić⁴, Zdenko Ostojić⁵ and Ivan Rakovac²

¹ Institute of Children Orthopedics, University Hospital Center Rijeka, Rijeka, Croatia

² Department of Orthopedic Surgery Lovran, Lovran, Croatia

³ Department of Emergency Medicine, Osijek, Croatia

⁴ Department of Neurosurgery, University Hospital Center Rijeka, Rijeka, Croatia

⁵ Faculty of Medicine, University of Mostar, Mostar, Bosnia and Herzegovina

ABSTRACT

Congenital dislocation of the knee (CDK) is a very rare condition. Here we report our strategy and results in treatment of three children with CDK. All three patients were treated with conservative method, and only one had underwent a surgical procedure on one knee. Of the remaining, we recorded a good outcome with conservative treatment in three knees, while two had poorer outcome as a result of musculoskeletal anomalies. We also present here a unique case of a child born without cruciate ligaments and patellas on both sides. We performed the operative procedure by Z-plasty of the extensor apparatus on one left knee according to Niebauer and King on one child. The clinical result of this procedure was very good. Five years after the operation we decided to perform an MRI examination to assess the postoperative status of the operated knee, especially the position and the shape of left patella. We found the asymmetry and high position of the operated patella resulting in patella alta. Compared to the initial clinical presentation, we consider all patients to have good clinical presentation nowadays.

Key words: congenital dislocation, recurvatum, children, knee, hips

Introduction

Congenital dislocation of the knee (CDK) is a relatively rare condition described for the first time in 1822¹. The incidence was estimated to be ~1% of the incidence of congenital dislocation of the hip (CDH) by Jacobsen et al. Musculoskeletal anomalies such as CDH and clubfoot have been recorded in 40 to 100% of these patients. Etiology varies from mechanical theory like trauma of the mother, lack of amniotic fluid, lack of intra-uterine space, malposition of the fetus, or theory of breech position with hyperextension of the knees inside the uterus, to the theory of primary or secondary muscle imbalance^{5–9}. In general, the diagnosis is established just after birth by the typical position of knee recurvatum and is confirmed by radiography. Usually, conservative treatment is effective.

If knees do not respond to conservative measures such as manual manipulations and serial plasters, operative treatment is indicated^{10–20}. From 1991–2006 we had three children with congenital dislocation of both knees and severe ipsilateral dysplasia of the hips. Here we present and report our strategy and result in the treatment of six cases of CDK with severe ipsilateral CDH which were bilaterally present in three children: one was treated immediately after birth, and the second six days after birth, the third came to our Hospital at the age of three month. Our aim was to make our patients capable of normal walking; firstly, by using conservative treatment, and in the case that failed, we performed operative treatment.

Case Report

Case 1

A two-hour-old male infant was referred for bilaterally hyper-extended knees, breech delivery, prematurus at 2450 grams of birth weight. After clinical and ultrasound examination we confirmed the diagnosis of bilaterally congenitally dislocated knees (Figures 1a, b), with bilateral hip dysplasia classified as Graf IV²¹ (Figure 2), no other anomaly was observed, and family history was unremarkable. The knees were hyper-extended and dislocated, the right side -45° and the left -40° without the possibility of knee flexion. The conservative treatment of the knees has started immediately, with a passive stretching and serial plaster casts (Figure 1c). Long cast serial correction, which we changed every week throughout a ten-week period together with increasing of the angle of flexion and when we got good knee flexion of 90° , we continued with application of Pavlik harness to treat the hips and knees simultaneously. The response on conservative treatment was good, and after six months of treatment, the knees mobility was 95° of flexion from full ex-

tension with good hips development. Today, the patient, a two year-old boy, walks normally without braces, because both knees are stable, with mobility from full extension up to 100° of flexion.

Case 2

A ten-day-old female infant was referred to our hospital department after breech delivery, prematurus weighing 2200 grams. When in her fifth month of pregnancy, the mother was taking antibiotics due to streptococcal infection, and the »Prepar« for pregnancy protection, as well as Isoptyn because of arrhythmia. The clinical, ultrasound and radiology examination showed dislocation of both hips and of both knees. Both knees could not be flexed, i.e. they could be straightened by resistance, but they returned to their primary position immediately after released, in recurvatum to -50° in both knees. We ordered therapy for both knees with long serial cast immobilization, which were changed every week; increasing the flexion of the knees, paying attention to tightening of the skin and surrounding structures. After two months, the knees could be flexed up to 90° , so we put the Pavlik

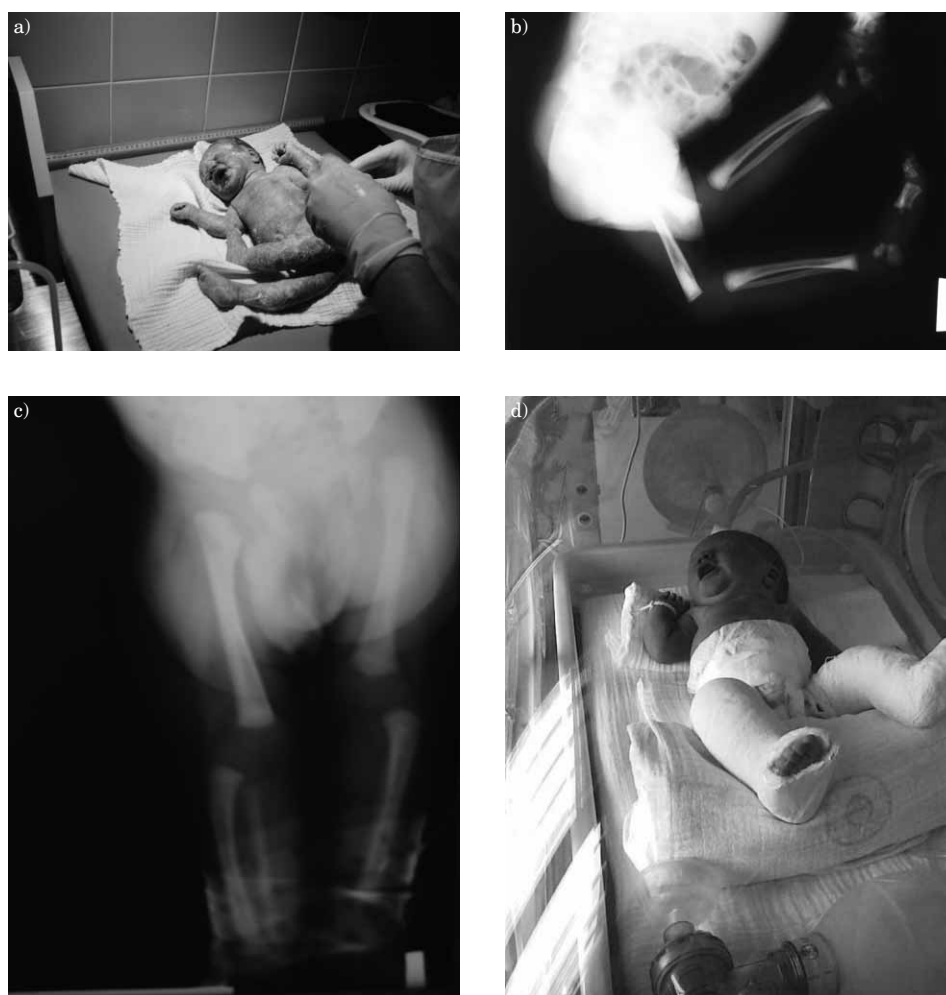

Fig. 1. Typical position of the congenital dislocation of the knee, radiograph and first therapy.

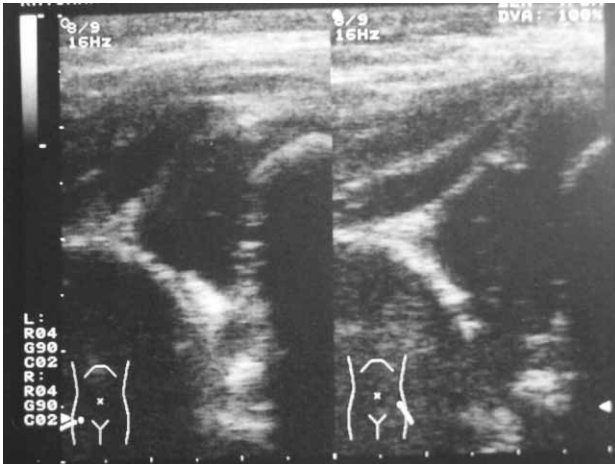


Fig. 2. Bilateral hip dysplasia or dislocation classified as Graf IV.

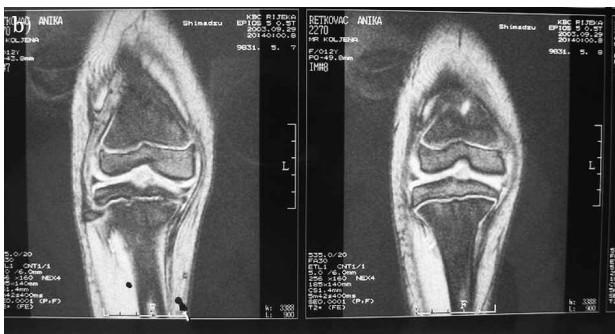
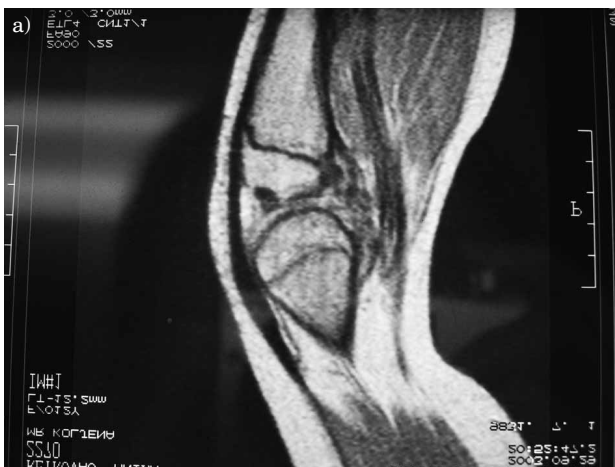
Fig. 3. MRI proofs the absence of cruciate ligaments and patella.

harness to continue the therapy for the knees and the hips. After that, we could begin with the therapy for the hips, which were able to be repositioned. But, the right knee, which was held by the harness, became unstable, subluxated. Therefore, we continued with the long cast immobilization with the flexion of 90° in the knee, for three more weeks. After the cast was taken off, the knees were stable and the right knee flexed up to 90° without

any phenomenon, and we continued the therapy with the Pavlik harness. At the age of eight months, we noticed the somatomotoric retardation, and we continued with the therapy with Pavlik harness up to one year of age. Since the hips were still dysplastic, we have put the Hilgenreiner's brace. The genetic analysis did not show chromosomal aberration. The child was raised to her feet at the second year of age, when the development of the hips were satisfactory, but since the knees remained unstable for weight-bearing, we ordered long knee braces which were connected with shoes. The knee mobility was 0–140° of flexion, but at the vertical weight-bearing without braces, lateral and ventral subluxation occurred on both knees, which were painful after a short walk. In the fifth year of age, the child underwent the eye surgery, but it had to be stopped unexpectedly, because she had serious extrasystole. In the twelfth year of age, in view of asymmetrically developed apophysis of the knees, and no patella, we ordered a MRI examination of both knees, which showed absence of cruciate ligaments on both side (Figure 3). Reconstructive surgical procedures were planned but the child's parents did not give permission for surgery because they were afraid of the effects of anesthesia. Today, at the age of 17, the girl walks by herself with two knee braces. Despite full mobility while standing, the knees are subluxated. The cause of it is the absence of cruciate ligaments or abnormal sloping of tibial articular surface (Figure 4). The right knee is in varus because of asymmetric apophyseal growth, and the child gets tired quickly and feels pain in both knees.

Case 3

A three month old male infant came for the first time to our Hospital with the recurvatum of both knees, and without the possibility of flexion, which made the child able to suck his both toes. Placenta previa was diagnosed in the 25th gestational week, so the child was delivered by C-section in 31st week of pregnancy because of bleeding. The newborn weighed 1800 grams. The mother was taking Ferritin tablets for anemia during the pregnancy. After clinical, ultrasound and radiographic examination a case of bilateral congenital dislocation of both knees with bilateral congenital hip dislocation was recognized (Figure 5a and b). There were not any other associated congenital anomalies and the laboratory results were within physiological limits, the chromosomal analysis was done and was normal as well. After vertical traction for three weeks, we managed to reposition the hips and we applied Lorenz cast immobilization to fixate repositioned hips. At the same time we tried to reduce the knees with the same cast. At the beginning we changed Lorenz cast (Figure 6) every two weeks increasing the flexion of the knees every time. After six months of conservative treatment with serial plaster casts, we got good hip development, reposition of the right knee and flexion up to 90°, but the left knee remained flexed to 65°, and still dislocated, which was the reason why we could not continue the therapy with Pavlik harness. Treatment was continued with serial long cast immobilization of solely left

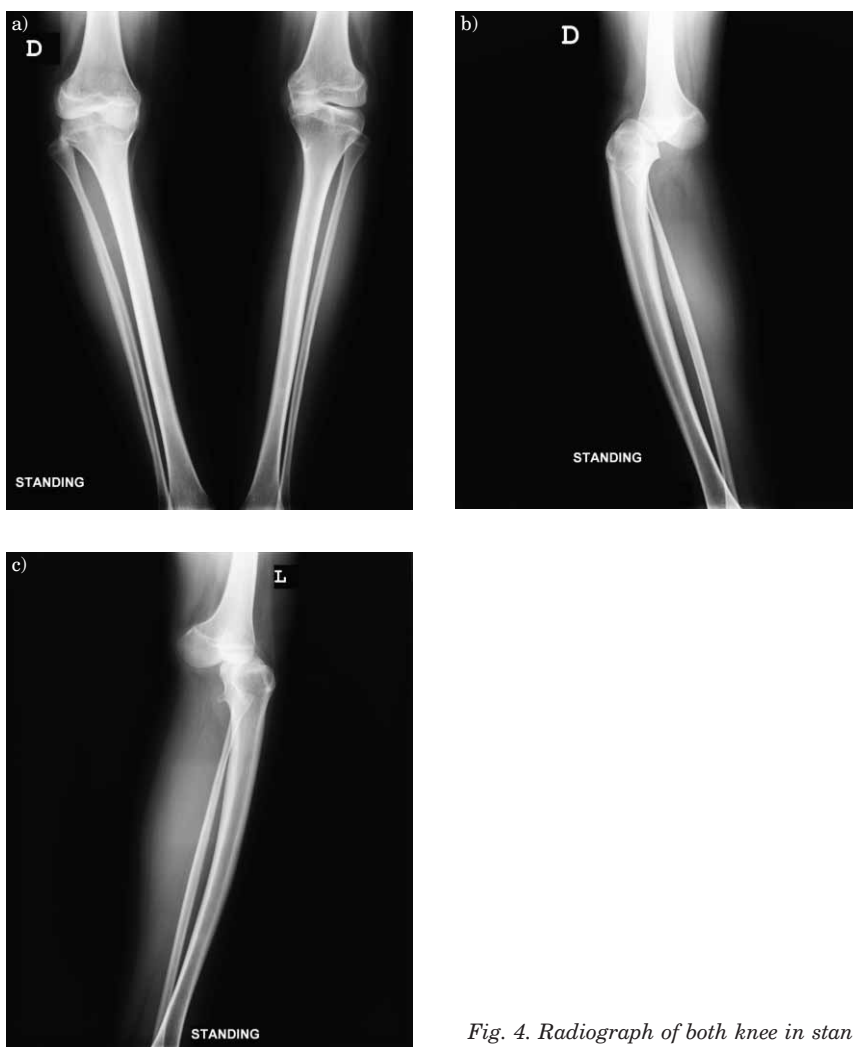

Fig. 4. Radiograph of both knee in standing AP and LL view.

knee for three more months, but the conservative treatment of the left knee failed. At patient's 12th month of life we decided to treat the left knee operatively by Z-plasty of the extensor apparatus, according to Niebauer and King (Figure 7).

The extensor mechanism – patella, quadriceps tendon, and patellar tendon, were splitted longitudinally and than lenghtened by Z-plasty. Abundant abnormal fibrous tissue underlying quadriceps tendon and from suprapatellar pouch was excised. Transversal capsulotomy and retinaculotomy was performed. Joint particles were repositioned and the patient had good cruciate ligaments which were sufficiently tightened, therefore we did not do any shortening of the cruciate ligaments. Lateral and medial meniscuses were good. After the operation, the child had cast immobilization for six weeks in 60° knee flexion, and then the brace another six weeks, but with the range of motion from 0 to 90°. Today, the patient walks normally without braces. He has correct mobility of both stable knees without flexion contracture, with flexion from full extension up to 95° of right ad 100° of the left knee (Figure 8).

Discussion

The authors agree that both early recognition and treatment are of the paramount importance in treating the CDK and CDH. The main pathologic condition in the CDK is the shortening of the extensor apparatus and tight anterior articular capsule^{4,7,9,10,17–20}. In CDK, as a result of the action of the ishiocrural muscles on the hip joint, the femoral head is pulled superolaterally, and subluxation occurs. According to Ooishi et al.¹⁰, the good hip position cannot be maintained as long as the knee is not sufficiently flexed, because the hamstrings are under continuous tension while the knee remains dislocated, and the femoral head is pulled superiorly and laterally^{4,10}. Taking these facts into consideration, we started to treat two patients CDK before CDH, but in one patient we started to treat both disorders simultaneously because he came too late and we were worried about his hips. We obtained good hip position in all cases although in Case 3 the left knee stayed dislocated.

The aim of the therapy of CDK was to obtain minimum 90° knee flexion, first of all, with conservative

treatment by stretching the quadriceps femoris tendon and anterior articular capsule^{4,15,19,20}. This should be started immediately after birth, because, the improvement of the delayed development of the anterior distal femoral epiphysis occurs, after early reposition and acquisition of a normal, reduced knee position¹⁰. In our Case 3 we recognized a delayed development of the proximal tibial epiphysis of the right knee. At the age of 5 the right proximal tibial surface stayed in slight posterior slope (Figure 9).

Cases refractory on conservative procedure, or those treated after the first 3–4 months of life may require surgical treatment^{3,5,6,11,19,20}. Indeed, with the same pathologic condition in two cases of CDK, we failed in 50% of cases, when the conservative treatment started after the first 3 months of life – Case 3. Our cases confirmed that the early treatment, in the first days after delivery, is the only warranty that the conservative treatment would succeed if there were no other associated congenital anomalies^{14,9,15,19,20}.

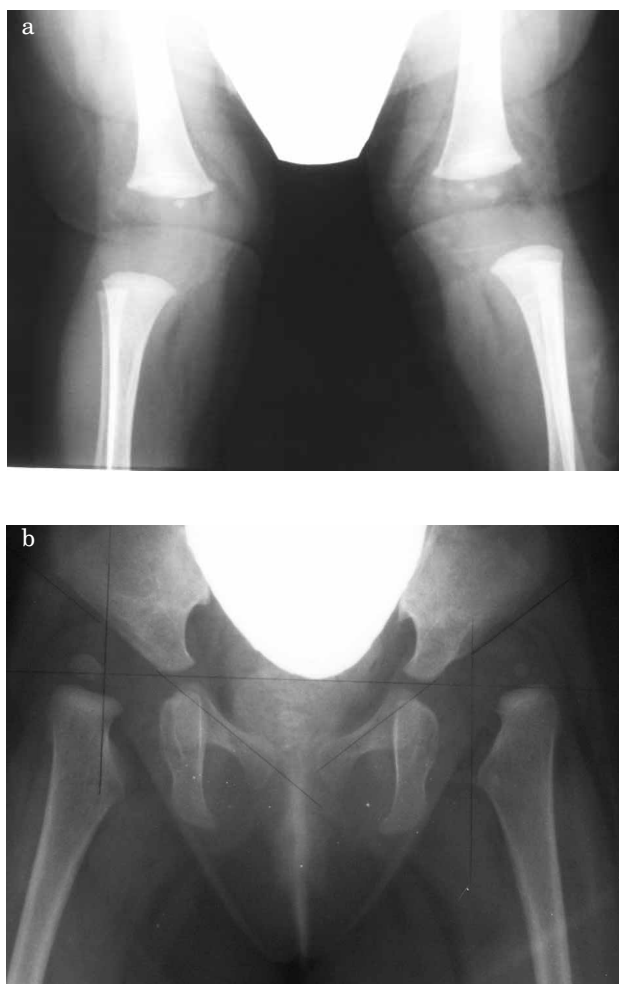


Fig. 5a and b. Bilaterally congenitally dislocated knees and bilaterally congenitally dislocated hips – radiograph of three-month-old boy.

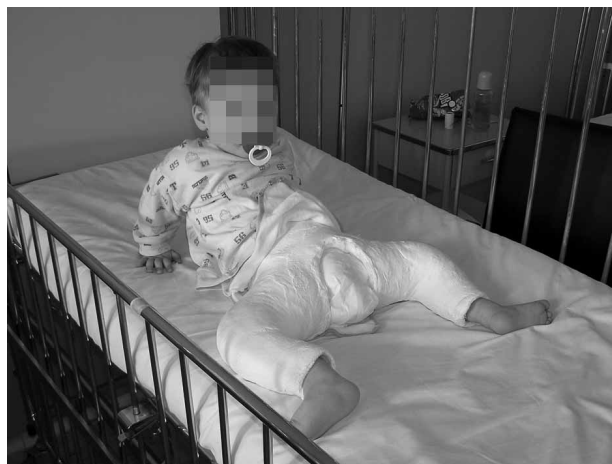

Fig. 6. After six-month therapy left knee was flexed but still dislocated – Lorentz cast

If there are other congenital anomalies of the knee present then even immediately started therapy will not give excellent results. In our Case 2 although the child has good knee mobility they are unstable and painful. Therefore we found the results of conservative treatment in this case to be poor according to classification of Ko JY et al.⁴.

We did not wait to see whether the knees would spontaneously reduce as Haga et al.¹⁴ recommended, because he came to us three months after delivery and we made a lot of effort to get just half of a result; one knee had to be operated. In this case we could not use Pavlick harness to treat simultaneous CDK and CDH because the hips also

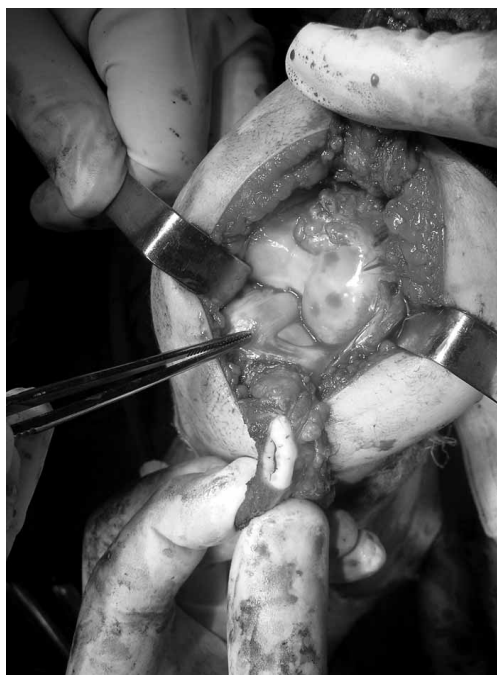

Fig. 7. The Z-plasty of the extensor apparatus of the left knee, according to Niebauer and King.

needed to be treated¹². In Case 3, the left knee was refractory to conservative treatment and the operative procedure was performed. Ferris and Aichroth⁷ suggested VY plasty for quadriceps lengthening, often assisted with proximal mobilization of the quadriceps muscle. To do this, the incision extends from the above of the greater trochanter of the femur to the anterior border of the tibia. Quadriceps need to be elongated to almost a double of its length if reduction is to be achieved with a useful range of knee flexion⁶. Bell et al.⁶ reported residual extensor contracture of the knee up to 30°. Lakshmanan et al., found the Z plasty to provide sufficient quadriceps lengthening and secured more repair than with the VY

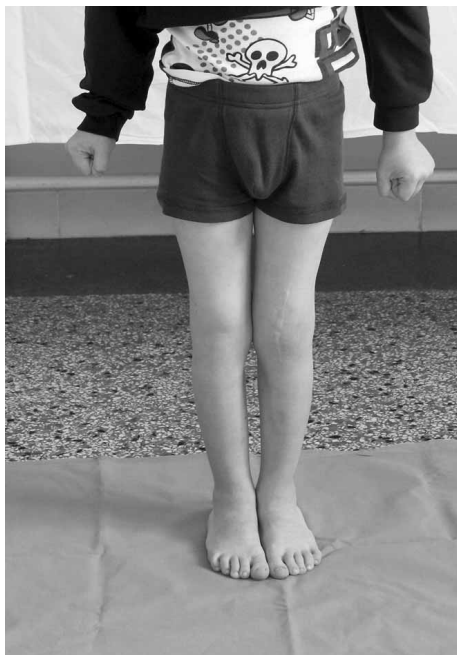
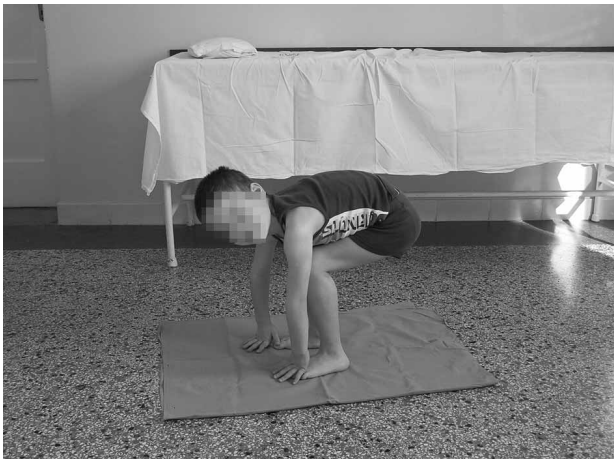
Fig. 8. The patient 5 years after operation.

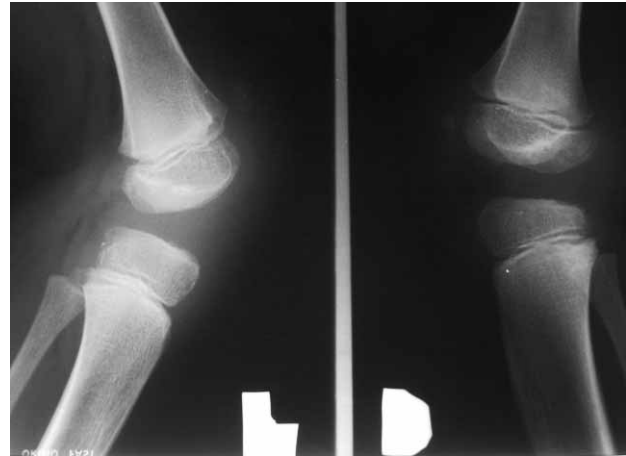


Fig. 9. Right tibial surface stayed in slight posterior slope on the right knee.

plasty in the treatment of CDK¹³. Because of less extensive operative approach and less operative trauma in comparison to VY plasty, we decided to perform the Z-plasty of the extensor apparatus, according to Niebauer and King⁵. For percutaneous surgery according to Roy and Crawford it was late and they also did not recommend this procedure in this child age¹⁸. The incision, extended about 10 cm in the midline of the knee, provided an excellent view of all structures of the knee, and of abnormal fibrous tissue, usually present beneath the contracted quadriceps. After the operation, six weeks of cast immobilization and physical therapy, the results were very good with the left knee, painless mobility up to 100° of flexion from full extension and the right knee 95° of flexion from full extension. We found our results very good in comparison to the literature, with technically demanding but less extensive operative procedure^{1–11,13–15}.

In conclusion, we think that the early recognition and treatment, in the first days after delivery, is the paramount strategy in treatment of CDK and CDH. The treatment should be planned simultaneously, hips and knees, taking care of individual patterns in complex congenital deformity, with emphasis on careful examination, continuous evaluation and evidence based flexibility in choosing the treatment methods. Because of less extensive operative approach in comparison to VY plasty with proximal mobilization of the quadriceps muscle, we are suggesting the Z-plasty of extensor apparatus, according to Niebauer and King, in operative treatment of CDK. Today, five years after operation, the left knee is painless, with good range of motion and functionally excellent extensor apparatus. The last radiograph and MRI of the left patella proved that the ossification centers are adapted to the new anatomical situation. If it develops out of the bottom part, then the *patella alta* would probably not appear and the stable, good mobile and painless knee would give an excellent radiology finding.

REFERENCES

1. SHATTOCK SG, Trans Pathol Soc London, 42 (1891) 280. — 2. JACOBSEN K, VOPALECKY F, Acta Orthop Scand, 56 (1985) 1. — 3. CURTIS BH, FISHER RL, J Bone Joint Surg Am, 51 (1969) 255. — 4. KO JY, SHIH CH, WENGER DR, J Pediatr Orthop, 19 (1999) 252. — 5. NIEBAUER JJ, KING DE, J Bone Joint Surg Am, 42 (1960) 207. — 6. BELL MJ, ATKINS RM, SHARRARD WJ, J Bone Joint Surg Br, 69 (1987) 403. — 7. FERRIS B, AICHROTH P, Clin Orthop, 216 (1987) 135. — 8. JOHNSON E, AUDELL R, OPPENHEIM WL, J Pediatr Orthop, 7 (1987) 194. — 9. MOHILOGULLARI M, OZEAN P, KIRAL A, Arh Orthop Trauma Surg, 126 (2006) 634. — 10. OOISHI T, SUGIOKA Y, MATSUMOTO S, FUJII T, Clin Orthop Relat Res, 287 (1993) 187. — 11. SÖYÜNCÜ Y, MIHÇI E, OZCANLI H, OZENCI M, AKYILDIZ F, AYDIN AT, Knee Surg Sports Traumatol Arthrosc, 14 (2006) 1171. — 12. NAKAMURA J, KAMEGAYA M, SAISU T, SOMEYA M, KOIZUMI W, MORIYA H, J Bone Joint Surg Br, 89 (2007) 230. — 13. LAKSHMANAN P, SHARMA A, HEMMADI S, FAIRCLOUGH JA, Eur J Orthop Surg Traumatol, 14 (2004) 249. — 14. HAGA N, NAKAMURA S, SAKAGUCHI R, YANAGISAKO Y, TANIGUCHI K, IWAYA T, J Pediatr Orthop, 17 (1997) 59. — 15. NOGI J, MACEWEN GD, J Pediatr Orthop, 2 (1982) 509. — 16. KATZ MP, GREGGONO BJS, SOPER KC, J Bone Joint Surg Br, 49 (1967) 112. — 17. LAURENCE M, J Bone Joint Surg Br, 49 (1967) 121. — 18. ROY DR, CRAWFORD AH, J Pediatr Orthop, 9 (1989) 717. — 19. FERNANDEZ-PALAZZI F, SILVA JR, Int Orthopaedics, 14 (1990) 17. — 20. BENZAHEL H, DELMONTE A, HELMSTEDT A, Journal of Pediatric Orthopedics, 9 (1989) 174. — 21. GRAF R, Arch Orthop Trauma Surg, 102 (1984) 248.

S. Roth

Institute of Children Orthopedics, University Hospital Center Rijeka, Fiorello la Guardia 14, 51000 Rijeka, Croatia
e-mail: rothmed@ri.htnet.hr

OBOSTRANA KONGENITALNA LUKSACIJA KOLJENA S ISTOSTRANIM RAZVOJNIM POREMEĆAJEM KUKA – PRIKAZ TRI SLUČAJA

SAŽETAK

Kongenitalna luksacija koljena (CDK) je relativno rijetko stanje. Ovdje mi prikazujemo našu strategiju i rezultate u liječenju šest slučajeva kongenitalne dislokacije koljena sa jakim istostranim razvojnim poremećajem kukova, koji su bilateralno prikazani u tri djeteta. Svi pacijenti su bili liječeni odmah pri primitku na odjel konzervativnom metodom, jedno koljeno je kasnije operirano. Tri koljena su imala dobre rezultate sa konzervativnim načinom liječenja, dva su ostala loša zbog toga što su imala muskuloskeletalnu anomaliju. Mi smo operirali ekstenzorni aparat na lijevom koljenu jednog djeteta Z plastikom prema Niebauer-Kingu. Iako smo imali vrlo dobre kliničke rezultate, pet godina nakon operacije odlučili smo učiniti magnetsku rezonancu poradi vrednovanja operiranog koljena, odnosno pozicije i oblika lijevog ivera. Našli smo asimetriju i visoku poziciju operiranog ivera u odnosu na drugu stranu. Patela alta se pojavila jer se razvila iz proksimalnog dijela razdjelnog ivera prilikom Z plastike. Prikazujemo jedinstveni slučaj djeteta rođenog bez križnih ligamenata i ivera koji se nisu razvili obostrano. Svi pacijenti su bili uspješno izliječeni.