

Isolated Splenic Metastasis from Colon Cancer – Case Report and Literature Review

Željko Bušić^{1,4}, Kristijan Čupurdija¹, Marijan Kolovrat¹, Vlatka Čavka², Mislav Čavka³,
Leonardo Patrlj¹, Dražen Servis¹ and Ante Kvesić⁴

¹ Department of Abdominal Surgery, University Hospital Dubrava, Zagreb, Croatia

² Department of Dermatology, University Hospital »Sestre milosrdnice«, Zagreb, Croatia

³ Department of Radiology, University Hospital Dubrava, Zagreb, Croatia

⁴ Clinic of Surgery, Faculty of Medicine, University of Mostar, Mostar, Bosnia and Herzegovina

ABSTRACT

Solitary splenic metastases are very rare and sporadic. There are several explanations for this low incidence of splenic metastasis including anatomical, histological and immunological features of the spleen. In this paper we present a case of 70-year-old man with no history of previous diseases who was first operated under the diagnosis of acute abdomen revealing perforated colon tumor of splenic flexure with no metastases at that time. Left hemicolectomy was performed followed by postoperative complications demanding a subtotal colectomy and ileostomy. Primary tumor was classified as Dukes (Astler-Coller)-C2, T4N1M0. Patient was referred to oncologist and received chemotherapy (5FU, Leucovorin). 5 months later continuity of the gut was performed by ileosygmooanastomosis. 2 years after first surgical procedure, a CT scan and abdominal ultrasound, followed by needle biopsy, showed isolated metastasis in spleen, so splenectomy was performed. Pathological findings revealed sharply bordered, partially necrotic tumor inside of spleen tissue, spreading to, but not reaching splenic hilum. Histology showed low to medium differentiated adenocarcinoma tissue with desmoplastic stromal reaction. There were no protrusions of tumor cells through spleen surface. In splenic hilum 4 tumor free lymph nodes were harvested. No additional chemotherapy was conducted. The latest follow up, a year after diagnosis of metastasis showed no signs of cancer disease. Review of the literature showed that long term survival and prognosis of isolated splenic colorectal metastasis after splenectomy are rather optimistic, although these are the cases of distant metastasis. Due to small number of cases reported in literature, definitive conclusions and/or guidelines for the treatment of isolated splenic metastasis cannot be given, but splenectomy and chemotherapy are preferable in the treatment, promising long term survival at least for metachronous metastasis.

Key words: colon cancer, metastasis, spleen

Introduction

The incidence of splenic metastasis, due to better medical imaging and long term follow up has been increasing¹. In most of the cases, they are part of multivisceral metastatic cancer². There have been several autopsy studies considering prevalence of splenic metastasis ranging from 2.3 to 7.1%³. Also, there have been several studies considering prevalence in living patients showing 1.3% of 1280 splenic tumors as metastatic⁴, 9.8% of 122 diagnostic splenectomies were positive for metastasis⁴ and 1% of 1743 splenectomies were positive for metastasis⁵.

Majority of the cases are part of multivisceral metastatic diseases and usually originate from breast, lung, ovarian, colorectal and gastric cancer and skin melanoma^{3,5}. Most of them are asymptomatic and diagnosed during regular follow up by ultrasound and CT scan, while PET scan is introduced as tool for revealing more asymptomatic cases¹. Solitary metastases are very rare and sporadic². Incidence of colon and rectum metastasis in autopsy study of Berge³ was 4.4 and 1.6% respectively, however no solitary metastases were reported. Pisanu et al.⁶ reported in their case report and review of the litera-

ture, published in November 2007, only 42 cases of well documented isolated splenic metastasis of colon and rectum origin. There are several explanations for this low incidence of splenic metastasis including anatomical, histological and immunological features of the spleen⁷.

Case Report

In 2005, a 70-year-old man with no history of previous diseases was referred to emergency department of our Clinic suffering from abdominal pain, fatigue and vomiting. During clinical examination distension and tenderness of abdomen were found and patient was immediately operated under the diagnosis of acute abdomen. Laparoscopic exploration was done at first and it revealed approximately 1 L of free intraperitoneal puss so conversion to open laparotomy was done. After peritoneal washing, a perforated tumor (approximately 10×5 cm) of splenic flexure was found, infiltrating surrounding fat tissue close to pancreas tail. No macroscopic metastases were found. Left hemicolectomy was performed with end to end hand sewed anastomosis. On 10th postoperative day patient developed signs of acute abdomen, so relaparotomy was done revealing anastomotic leakage. Since the rest of the colon was distended, a subtotal colectomy and ileostomy was performed. Two weeks after the second operation patient was discharged from hospital.

Pathological finding revealed ulcero-infiltrative circumferential tumor, whose dimension was 11.5×4.5 cm. Histology analyses showed a moderately differentiated adenocarcinoma with high mitotic and apoptotic pattern together with areas of necrosis. Tumor invaded visceral peritoneum and surrounding fat tissue. Five lymph nodes were harvested and two of them were positive for me-

tastasis. Resection margins of colon and mesocolon were free of tumor. Overall, primary tumor was classified as Dukes-C, Dukes (Astler-Coller)-C2, T4 N1 M0, stage IIIB, according to TNM system and histological grade – G2.

Following discharge from surgery department patient was referred to oncologist and received chemotherapy (5FU, Leucovorin). Four months after the initial examination, patient was admitted to our Clinic and continuity of the gut was performed by ileosigmoidostomy. The free edge of sigmoid colon was resected during surgery and histopathology did not revealed signs of colon cancer. The patient was regularly followed up, having no symptoms of the disease. A scheduled CT scan in May 2007 showed hypovascular lesion of the spleen, 7.9 cm in diameter (Figure 1). Other findings were normal except for gallbladder stone. CEA level was 5.05 µg/L (ref. <3.4 µg/L). Abdominal ultrasound examination also showed hypovascular lesion (Figure 2). In July 2007 an ultrasound guided needle biopsy was performed and cytology analyses revealed adenocarcinoma cells. Patient was again admitted to our Clinic and scheduled for surgery. Laparotomy was done and exploration revealed spleen with tumor mass inside with no protrusion through spleen tissue. There were no signs of other metastatic lesions. Splenectomy was performed. Pathology findings after splenectomy revealed an enlarged spleen (13×10×5 cm) (Figure 3a and 3b) with sharply bordered, partially necrotic tumor (8×7×3 cm) inside of spleen tissue, spreading to but not reaching splenic hilum (Figure 4). Histology examination showed low to medium differentiated adenocarcinoma tissue with desmoplastic stromal reaction. There were no protrusions of tumor cells through spleen surface. In splenic hilum four lymph nodes were harvested, all without carcinoma cells.

Early postoperative myocardial infarction developed and stenting of left anterior descending coronary artery was performed. A week later a cerebrovascular infarction developed with dysphasia and mild right hemiparesis.

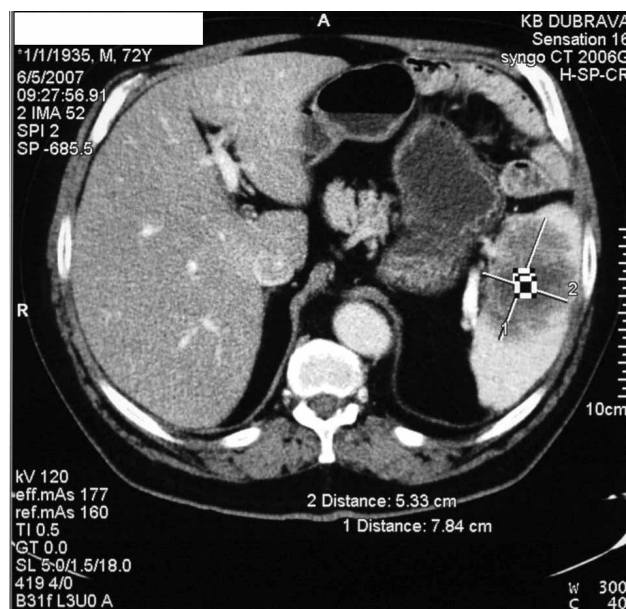


Fig 1. Abdominal CT scan showing hypovascular splenic lesion.

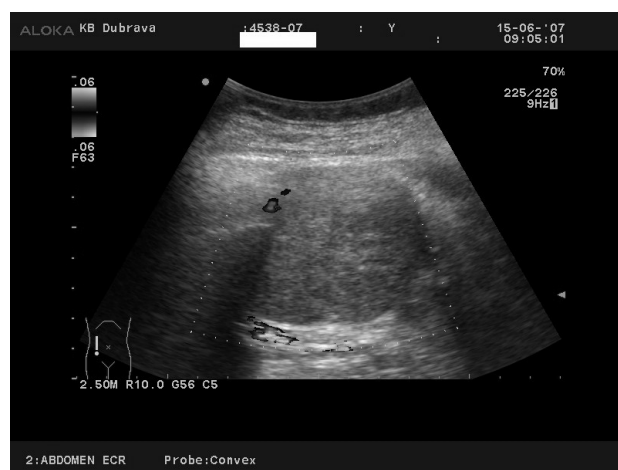

Fig. 2. Abdominal ultrasound showing hypovascular splenic lesion.

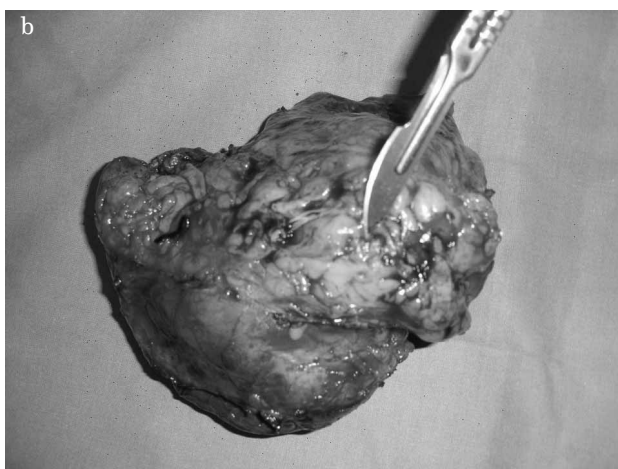
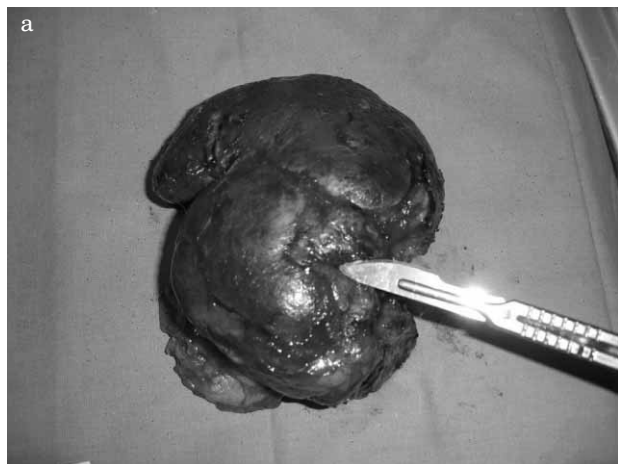


Fig 3. a) Spleen without visible tumor protrusion, b) Spleen (hilum) without visible tumor protrusion

There were no surgical complications. In August 2007 patient was discharged from hospital and referred to specialized institution for further rehabilitation. No additional chemotherapy was conducted. The latest follow up in May 2008 showed no signs of cancer disease.

Discussion

As mentioned before, splenic metastasis of various cancers are very rare and usually part of multivisceral dissemination and isolated metastases are sporadic. There are several theories to explain this rarity and two main are: first including mechanical/anatomical and histological factors preventing implantation of blood borne cancer cells. These factors include constant flow of blood through spleen and rhythmic contractions of splenic capsule and splenic sinusoidal architecture, sharp angle of splenic and celiac artery preventing clamps of tumor cells from passing through and lack of afferent lymphatic vessels limiting lymphogenic metastases^{7,8}. According to Indudhara⁹ neoplastic cells can reach splenic vein and parenchyma by retrograde diffusion through the inferior

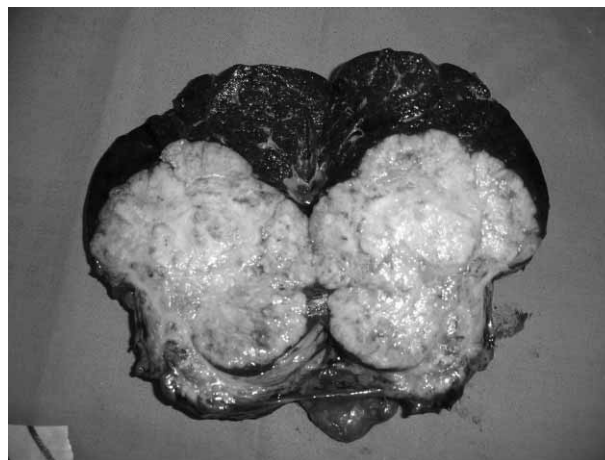


Fig. 4. Spleen crosssected through hilum.

mesenteric vein. The spleen parenchyma has no lymphatic vessels but they are present in capsular, subcapsular and trabecular regions⁸. Tumor cells might also reach the spleen through lymphatic system which explains the subcapsular localization of isolated splenic metastasis⁸. The second theory includes immunology factors and that is inhibitory effect of splenic microenvironment on the growth of cancer cells^{3,7} as the spleen is the second largest organ of lymphoreticular endothelial system, so immune surveillance appears to potentially inhibit tumor cell proliferation¹⁰. However, recent studies based on sensitive immunologic and molecular methods that can detect single cells showed that micrometastases can be detected at the time of tumor diagnosis^{11,12}. Considering this, it could be assumed that implantation of cancer cells can occur but further growth is inhibited by microenvironment, explaining high prevalence of splenic micrometastasis found at autopsy and low prevalence of clinically detectable metastases².

The prevalence of splenic metastasis, although very low, is increasing with the improvement of imaging techniques². About 20% of colorectal carcinomas are metastatic at their clinical presentation¹³. The usual sites of metastasis are liver, lung and axial skeleton^{14,15}. Microscopic splenic metastases were found in 7–34% of cancer patients³. In the same study, incidence of splenic colorectal micrometastasis was reported as 2% of 1019 colorectal tumors but all of these cases involved other organs as well³. In his article, Pisanu reported that up to his case review only 41 cases of isolated colorectal splenic metastasis have been reported⁶ and most of the cases were metachronous.

Majority of cases reported had a disease free survival period of 3–144 months after the diagnosis of primary tumor^{16–18}. Long term survival after splenectomy in patients with metachronous splenic metastasis was 0.5–7 years^{17–19}. So, prognosis of isolated splenic colorectal metastasis is rather optimistic, although these are the cases of distant metastasis¹⁹. For synchronous metastasis much

worse prognosis and shorter disease free survival has been reported¹⁸.

Although due to small number of cases reported in literature, definitive conclusions and/or guidelines for the

treatment of isolated splenic metastasis can not be given, splenectomy and chemotherapy are preferable in treatment, promising long term survival, at least for metachronous metastasis.

REFERENCES

1. METSER U, MILLER E, KESSLER A, LERMAN H, LIEVSHITZ G, OREN R, EVEN-SAPIR E, J Nucl Med, 46 (2005) 52. — 2. COMPERAT E, BARDIER-DUPAS A, CAMPARO P, CAPRON F, CHARLOTTE F, Arch Pathol Lab Med, 131 (2007) 965. — 3. BERGE T, Acta Pathol Microbiol Scand, 82 (1974) 499. — 4. KRAUS MD, FLEMING MD, VONDERHEIDE RH, Cancer, 91 (2001) 2001. — 5. LAM KY, TANG V, Arch Pathol Lab Med, 124 (2000) 526. — 6. PISANU A, RAVARINO A, NIEDDU R, UCCHEDDU A, World J Gastroenterol, 13 (2007) 5516. — 7. KIM JC, JEONG CS, KIM HC, YU CS, KANG GH, LEE MG, J Korean Med Sci, 15 (2000) 355. — 8. CAVALLARO A, MODUGNO P, SPECCHIA M, PONTENZA AE, LOSCHIAVO V, COLLI R, LAURIOLA L, BARONE C, J Exp Clin Cancer Res, 23 (2004) 143. — 9. INDUDHARA R, VOGT D, LEVIN HS, CHURCH J, South Med J, 90 (1997) 633. — 10. GABIZON A, SMALL M, TRAININ N, Int J Cancer, 18 (1976) 813. — 11. PANTEL K,

BRAKENHOFF RH, Nat Rev Cancer, 4 (2004) 448. — 12. GOODISON S, KAWAI K, HIHARA J, JIANG P, YANG M, URQUIDI V, HOFFMAN RM, TARIN D, Clin Cancer Res, 9 (2003) 3808. — 13. PEDERSEN IK, BURCHARTH F, ROIKJAER O, BADEN H, Dis Colon Rectum, 37 (1994) 1078. — 14. PLACE RJ, Am Surg, 67 (2001) 454. — 15. KLEIN B, STEIN M, KUTEN A, STEINER M, BARSHALOM D, ROBINSON E, GAL D, Cancer, 60 (1987) 100. — 16. GENNA M, LEOPARDI F, VALLONCINI E, MOLFETTA M, DE MANZONI G, CASTELLI A, Minerva Chir, 58 (2003) 811. — 17. WEATHERS BK, MODESTO VL, GORDON D, Dis Colon Rectum, 42 (1999) 1345. — 18. AVESANI EC, CIOFFI U, DE SIMONE M, BOTTI F, CARRARA A, FERRERO S, Am J Clin Oncol, 24 (2001) 311. — 19. OKUYAMA T, OYA M, ISHIKAWA H, Jpn J Clin Oncol, 31 (2001) 341.

Ž. Bušić

Department of Abdominal Surgery, University Hospital Dubrava, Av. Gojka Šuška 6, HR-10000, Zagreb, Croatia
e-mail: zbusic@kdb.hr

IZOLIRANA METASTAZA RAKA DEBELOG CRIJEVA U SLEZENI – PRIKAZ SLUČAJA I PREGLED LITERATURE

SAŽETAK

Izolirane metastaze u slezeni javljaju se vrlo rijetko i sporadično. Postoji nekoliko objašnjenja ove niske incidencije metastaza u slezeni, uključujući anatomske, histološke i imunološke osobine slezene. U ovom članku prezentirali smo slučaj 70-godišnjeg muškarca, koji ranije nije bolovao od težih bolesti, a koji je najprije operiran pod kliničkom slikom akutnog abdomena kada je otkriven perforirani tumor debelog crijeva u području lijenalne fleksure bez metastaza. Učinjena je lijeva hemikolektomija, a potom zbog poslijeoperacijskih komplikacija subtotalna kolektomija i isleostoma. Primarni tumor klasificiran kao Dukes (Astler-Coller)-C2, T4N1M0. Pacijent je upućen onkologu te je primio kemoterapiju (5FU, Leucovorin). Pet mjeseci kasnije kontinuitet probavnog sustava uspostavljen je ileosigmoanastomozom. Dvije godine nakon prve operacije CT i ultrazvuk trbuha te punkcijska biopsija otkrili su izoliranu metastazu u slezeni te je učinjena splenektomija. Patološka analiza pokazala je da se radi o oštro ograničenom, djelomično nekrotičnom tumoru unutar tkiva slezene koji se širi prema, ali ne dopire do hilusa slezene. Histološka analiza pokazala je nisko do srednje diferenciran adenokarcinom sa dezmodulacijskim reakcijom strome. Nije nađena protruzija stanica tumora kroz površinu slezene. Iz hilusa slezene izolirana su 4 limfna čvora bez znakova tumorskog rasta. Dodatna kemoterapija nije provedena. Na zadnjem kontrolnom pregledu, godinu dana nakon dijagnoze metastaze, kod pacijenta nije nađena karcinomska bolest. Pregled literature ukazuje da je dugoročno preživljavanje bolesnika sa izoliranim metastazama raka debelog crijeva u slezeni nakon splenektomije moguće te prognoza prilično optimistična, iako su to zapravo slučajevi udaljenih metastaza. Zbog malog broja slučajeva opisanih u literaturi, definitivni zaključci i/ili smjernice za liječenje izoliranih metastaza raka debelog crijeva u slezeni ne mogu se donijeti ali su splenektomija i kemoterapija preporučljivi načini liječenja obećavajući dugoročno preživljenje, barem kod metakronih metastaza.