

A Quantitative Evaluation of the Distal Displacement of the Gingival Zenith in the Maxillary Anterior Teeth

Maja Žagar, Dubravka Knezović Zlatarić and Vlado Carek

Department of Prosthodontics, School of Dental Medicine, University of Zagreb, Zagreb, Croatia

ABSTRACT

The aim of this study was to quantify the specific distal displacement of the gingival zenith in the maxillary anterior dentition. Bilateral measurements, taken with a digital caliper in maxillary stone casts were recorded in six maxillary anterior teeth to evaluate distal displacement of the gingival zenith in relation to the long axis of the crowns. The gingival zenith was distally displaced between 0.45 and 1.01 mm in 90%, 85% and 60% of the central incisors, lateral incisors and canines, respectively. Contralateral comparisons between the tooth groups revealed significantly larger distal displacement of the zenith in left canine ($p < 0.05$). Ipsilateral comparisons revealed that the lateral displacement of the zenith was significantly larger in central than in lateral incisors ($p < 0.05$). Similarly, the zenith of lateral incisors was displaced significantly more distal than that of canine teeth ($p < 0.05$). Comparisons of the frequency of coincidence of the position of the gingival zenith with the long axis of the tooth revealed that it was significantly greater in canines than in lateral and central incisors ($p < 0.05$). The frequency and magnitude of distal displacement is tooth-dependent and larger in central than in lateral incisors, which in turn, is larger than in canines. These data could be used as reference points during esthetic anterior oral rehabilitation, especially in case of porcelain laminate veneers.

Key words: gingival zenith, long axis, maxillary anterior teeth, distal displacement

Introduction

The appearance of gingival tissues plays an important role in the esthetics of the maxillary anterior teeth and the abnormalities in symmetry and contour can significantly affect the harmony of the natural or prosthetically restored dentition¹. Prior to the prosthodontic treatment the esthetic evaluation always starts with the smile analysis that involve the relationships among the teeth, the lip framework and the gingival contours^{2,3}. Gingival morphology, contour and visibility play important role in a beautiful smile and are among the first fundamental esthetic objectives during treatment planning⁴. They are therefore essential to consider prior to the final decision about the prosthodontic treatment.

In an investigation of gingival visibility, performed on 576 patients, Liebart et al revealed that 44% of the patients displayed gingiva during smile⁵. Deviations from the normal gingival appearance will result in an estheti-

cally undesirable gingival asymmetry and lead to visual stress and imbalance of both patient and dentist.

Numerous articles have addressed various aspects related to gingival contours of the maxillary anterior teeth^{6–9}. One of the significant clinical parameter of gingival morphology is the gingival zenith, the most apical aspect of the free gingival margin¹⁰. Different authors recommend the different position of the gingival zeniths in maxillary anterior teeth. Magne and Belser suggested that the gingival zenith is positioned distally to the long axis of all the maxillary anterior teeth⁴. Rufenacht proposed that the gingival zenith was distally displaced on the central incisors and canines only, whereas those of the lateral incisors were coincident with the long axis of the tooth^{11,12}. Goodlin described the gingival zeniths for central incisors at the distal third, laterals at the tooth long axis, and canines ranging from the anterior third to

the distal third of the long axis of the tooth¹³. Chu et al.¹⁰ and Mattos and Santana¹ reported the largest displacement of the gingival zenith in central incisors, minor displacement in lateral incisors and coincidence of the gingival zeniths with the long axis in canines.

This study aimed to quantify the specific distal displacement of the gingival zenith in the maxillary anterior dentition in young adults, measuring the gingival topography of the maxillary incisors and canines for the mesio-distal displacement of the gingival zenith in relation to the long axis of the natural crowns.

Methods

A total of 30 young adult patients (13 men and 17 women, mean age 26; range from 22 to 32 years old), who met the inclusion criteria¹⁴ (older than 20 years; free gingival margin of the facial aspect of the teeth in the maxillary sextant positioned apical to the cervical bulge; absence of gingival recession and bleeding on probing; probing depth <3 mm; and marginal tissue knife-edged in form, firm in consistency and coral pink in color) participated in this study.

Alginate impressions (Vival NF, Ivoclar Vivadent, Liechtenstein) of the maxillary arch were taken in stock trays and poured in type IV dental stone (GC Fujirock EP, GC Europe) according to the manufacturer's specifications. Reference lines were drawn and bilateral measurements, using digital caliper (CD-6", Mitutoyo, Tokyo, Japan), were taken in the respective stone casts in the canine, lateral incisor and central incisor teeth (Figure 1). The gingival zenith was determined at the most apical point of the gingival marginal scallop. A vertical line was drawn bisecting the midline of the maximum crown width. Using this landmark as the reference, the distance between vertical line and gingival zenith was defined as the discrepancy between the most apical point of the gingival margin and vertical line of the teeth. Prior to the measurement, two independent prosthodontists separately measured 10 patients. The measurement was repeated after a week interval. No significant difference was noted between the first and the second measurement ($p=0.62$; paired t-test, $\alpha=0.05$). The weighted kappa statistics showed satisfactory agreement between the independent prosthodontists ($\kappa=0.86$; confidence interval CI 0.74 to 0.93). Because the reliability of the measurements and the agreement were excellent, the measurement of the more consistent prosthodontists was considered for statistical analysis.

The measurement was then performed under direct light with a digital caliper with a resolution of 0.01 mm. Measurements were recorded to the nearest 1/100th mm. Duplicated measurements were performed for every tooth and averaged.

All the results are expressed as mean±SD. Inter measurement differences were analyzed with the paired-t test for continuous variables and χ^2 -test for percentages. An α value =0.05 was used to declare statistical significance.

Results

The gingival zenith was distally displaced between 0.26 and 1.01 mm in 90%, 85% and 60% of the central incisors, lateral incisors and canines, respectively (Figures 1 and 2). Mesial displacement of the gingival zenith in relation to the long axis of the crown was not observed in any tooth, regardless of the tooth group.

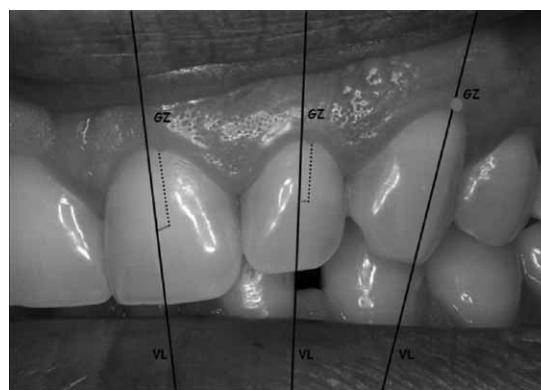


Fig. 1. Measurements of the distal displacement of the gingival zeniths in maxillary anterior teeth. GZ= gingival zenith, VL = vertical line bisecting the midline of the maximum crown width.

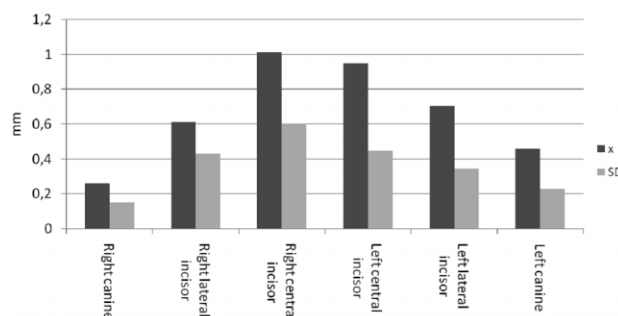


Fig. 2. Mean values (X) and standard deviations (SD) of the distal displacement of gingival zenith in maxillary anterior teeth.

Contralateral comparisons between the tooth groups revealed significantly larger distal displacement of the zenith in left canine ($p<0.05$) (Table 2). Ipsilateral comparisons revealed that the lateral displacement of the zenith was significantly larger in central than in lateral incisors ($p<0.05$) (Table 2). Similarly, the zenith of lateral incisors was displaced significantly more distal than that of canine teeth ($p<0.05$) (Table 2). Comparisons of the frequency of coincidence of the position of the gingival zenith with the long axis of the tooth revealed that it was significantly greater in canines than in lateral and central incisors (χ^2 -test; $p<0.05$) (Table 3).

Discussion

Elements involved in designing an esthetic smile have been profoundly discussed in the dental literature^{4,11,12},

TABLE 1
DISTAL DISPLACEMENT OF THE GINGIVAL ZENITH IN RELATION TO THE LONG AXIS OF THE TOOTH

Measurement	Right canine (RC)	Right lateral incisor (RLI)	Right central incisor (RCI)	Left central incisor (LCI)	Left lateral incisor (LLI)	Left canine
$\bar{X} \pm SD$ (mm)	0.26±0.15	0.61±0.43	1.01±0.60	0.95±0.44	0.70±0.34	0.45±0.23
Range-Min/Max (mm)	0.0/1.02		0.0/2.50	0.0/1.7	0.0/1.78	0.0/1.10
	RC vs. RLI *	RLI vs. RCI *	RCI vs. LCI		LCI vs. LLI *	LLI vs. LC *
		RC vs. RCI *		RLI vs. LLI		LCI vs. LC *
				RC vs. LC *		

*(p<0.05)

TABLE 3
PREVALENCE OF COINCIDENCE OF THE POSITION OF THE GINGIVAL ZENITH WITH THE LONG AXIS OF THE TOOTH

	Right canine	Left canine	Right lateral incisor	Left lateral incisor	Right central incisor	Left central incisor	Total (%)
Coincide (%)	48		30	19	15	10	11
\bar{X} (%)		39			17	10.5	
		*					
Diverge (%)	52		70	81	85	90	89
\bar{X} (%)		61			83	89.5	
		*					

*(p<0.05)

^{15,16}. Details, such as the gingival zenith position, the most apical point of the free gingival margin of the periodontium, can significantly influence the esthetic appearance of the smile¹⁰. However, numerous studies, though discussing various aspects related to the gingival contours of the maxillary anterior teeth, have presented different information of gingival zenith position. Some of them suggested the gingival zeniths of all the maxillary anterior teeth should be positioned distally from the long axis of the teeth⁴, some suggested the gingival zeniths should be distally displaced on the central incisors and canines only^{11,12}, and some suggested the gingival zeniths in central incisors should be positioned at the distal third, in laterals at the long axis and in canines from the anterior third to the distal third of the long axis of the tooth¹³.

Results of the present study, derived from quantitative measurements, revealed that the distal displacement of the zenith was not a universal finding in the anterior maxillary sextant as previously believed. Data demonstrated that the distal position of the zenith was very frequent in central incisors, frequent in lateral incisors and rare in canines (Table 1). These findings are in accor-

dance with the results of Chu et al.¹⁰ and Mattos and Santana¹.

In addition, lateral displacement of the zenith was greater in central incisors than lateral, which, in turn, was greater than in canines. Contralateral comparisons did not reveal significant differences between the tooth groups (except for the canines, p<0.05), thus demonstrating contralateral symmetry for the distal displacement of the gingival margin.

Considering the multidisciplinary diagnostic and therapeutic importance of the ideal positioning of the gingival zenith, further investigations on the subject are warranted.

Conclusions

The frequency and magnitude of distal displacement is tooth-dependent and larger in central than in lateral incisors, which in turn, is larger than in canines. These data could be used as reference points during esthetic periodontal and prosthetic anterior oral rehabilitation, especially in case of porcelain laminate veneers.

REFERENCES

1. MATTOS CML, SANTANA RB, J Periodontol, 79 (2008) 1880. — 2. GARBER DA, SALAMA MA, Periodontol 2000, 11 (1996) 18. — 3. CHAR-RUEL S, PEREZ C, FOTI B, CAMPS J, MONNET-CORTI V, J Periodontol, 79 (2008) 795. — 4. MAGNE P, BELSER U, Bonded porcelain restorations in the anterior dentition. A biomimetic approach (Quintessence, Carol Stream, 2002). — 5. LIEBART MF, FOUQUE-DERUELLE C, SANTINI A, Perio, 1 (2004) 17. — 6. KOKICH VG, SPEAR FM, Semin Orthod, 3 (1997) 3. — 7. MCGUIRE MK, Dent Clin North Am, 42 (1998) 411. — 8. AHMAD I, Pract Periodontics Aesthet Dent, 10 (1998) 813. — 9. REDDA MS, J Am Dent Assoc, 134 (2003) 295. — 10. CHU SJ, TAN JHP, STAPPERT CFJ, TARNOW DP, J Esthet Restor Dent, 21 (2009) 113. — 11. RUFENACHT CR, Fundamentals of esthetics (Quintessence, Berlin, 1990). — 12. RUFENACHT CR, Principles of esthetic integration (Quintessence, Chicago, 2000). — 13. GOODLIN R, Oral Health and Dental Practice, 93 (2003) 10. — 14. STERRETT JD, OLIVER T, ROBINSON F, FORTSON W, KNAAK B, RUSSEL CM, J Clin Periodontol, 26 (1999) 153. — 15. CHICHE GJ, PINAULT A, Esthetics of anterior fixed prosthetics (Quintessence, Chicago, 1994). — 16. FRADEANI M, Esthetic rehabilitation in fixed prosthodontics. Volume I – Esthetic analysis: a systematic approach to prosthetic treatment (Quintessence, Chicago, 2004).

M. Žagar

Department of Prosthodontics, School of Dental Medicine, University of Zagreb, Gundulićeva 5, 10000 Zagreb, Croatia
e-mail: mpavic@sfzg.hr

KVANTITATIVNA PROCJENA DISTALNOG ODSUPANJA GINGIVNIH ZENITA GORNJIH PREDNJIH ZUBI

SAŽETAK

Svrha je ovoga rada bila odrediti specifično distalno odstupanje gingivnih zenita gornjih prednjih zubi. Stoga je digitalnom pomičnom mjerkom na sadrenim modelima pacijenata izmjeren obostrani distalni otklon gingivnih zenita u odnosu na dužinsku os gornjih prednjih zubi. Gingivni su zeniti odstupali od dužinske osi zubi u iznosu od 0,45 do 1,01 mm, i to u 90% gornjih središnjih inciziva, u 85% gornjih lateralnih inciziva te u 60% gornjih kanina. Usporedba odstupanja po skupinama zubi pokazala je značajno veće odstupanje zenita na lijevim kaninima ($p < 0,05$). Istostrana usporedba otkrila je da su lateralna odstupanja zenita bila značajno veća kod središnjih u usporedbi s lateralnim incizivima ($p < 0,05$). Jednako su tako zeniti lateralnih inciziva bili značajno distalnije položeni od onih na kaninima ($p < 0,05$). Usporedbe učestalosti podudaranja položaja gingivnog zenita s dužinskom osi zuba pokazala je da je ono značajno češće kod kanina nego kod lateralnih i središnjih inciziva ($p < 0,05$). Učestalost i iznos distalnog odstupanja gingivnog zenita ovisi o zubi i najveće je kod središnjih inciziva, nešto manje kod lateralnih inciziva, a najmanje kod kanina. Dobivene podatke moguće je koristiti kao referentne točke tijekom estetskih zahvata na gornjim prednjim zubima, naročito pri izradi keramičkih ljusaka.