

The Value of Stereotactic Biopsy in Improving Survival and Quality of Life for Malignant Brain Glioma Patients

Goran Lakičević¹, Bruno Splavski² and Zdrinko Brekalo¹

¹ Department of Surgery, University Hospital Mostar, Mostar, Bosnia and Herzegovina

² Department of Neurosurgery, University Hospital Center Osijek, Osijek, Croatia

ABSTRACT

The purpose of the study was to investigate possible differences in the survival and outcome of malignant brain glioma patients when treated by two different methods of surgery. During a 3-year period, 32 glioma patients underwent surgery and oncological protocol afterwards. The patients were divided into two groups according to the surgical method applied. The case group comprised 11 patients in whom a stereotactic biopsy was performed, while the control group consisted of 21 patients who were operated on by radical surgery (craniotomy and maximal reduction of the tumor mass). All survived patients were clinically examined at follow-ups (one year and 2 years following the surgery). The monitored variables for both groups were the tumor pathohistology (the tumor type), the survival rate (time between surgery and follow-up), and the outcome assessed by The Extended Glasgow Outcome Scale. Data statistical analysis was done to compare various investigated variables in two different groups of patients. The majority of patients treated by a stereotactic biopsy survived for more than 2 years following the procedure. The great part of patients treated by radical surgery died or was severely disabled at follow-up examination. The survival and outcome for the patients in whom a stereotactic biopsy was performed were notably better comparing to the patients who were treated by radical surgery. Consequently, it appears that a stereotactic biopsy is surgical option for primary treatment of selected patients with malignant brain glioma when the survival and quality of life are concerned.

Key words: brain glioma, stereotactic biopsy, radical surgery, survival, outcome

Introduction

Gliomas are a heterogeneous group of neoplasms that comprise the majority of tumors originating in the central nervous system¹. A number of surgical options are available for patients suffering from different grade of malignant glioma. The principal objective of any management is to advance both the duration of life and quality of survival.

Typically, the standard treatment for these tumors is a surgery followed by radiation and chemotherapy. Surgery and/or tumor tissue biopsy are required for a definite pathohistological diagnosis, which will dictate succeeding therapy preferences. Maximal surgical tumor

resection, advocated by some authors, is a well known way to improve glioma prognosis¹. However, if for various reasons a glioma cannot be radically removed, the method of choice remains a stereotactic biopsy to verify tumor cell histology, which facilitates the proper treatment choice. Nevertheless, prognostic factors for the treatment of malignant brain glioma have yet to be definitely identified². Therefore, examining the impact of patient selection on the survival and outcome is rather important³.

The purpose of this study is to investigate whether there are any differences in the survival and outcome of

malignant brain glioma when treated by two different methods of surgery (radical open surgery vs. stereotactic biopsy).

Patients and Methods

During a 3-year period, 32 patients with different types of malignant brain gliomas underwent surgery at the Neurosurgery Unit of the Clinic for Surgery, University Hospital Mostar, Bosnia and Herzegovina, and were treated by oncological protocol afterwards (radiation and chemotherapy). The average age of the patients was 62.5±SD13.9 years.

The patients were divided into two groups according to the surgical method applied. The case group of 11 patients consisted of 9 (81.8%) males and 2 (18.2%) females with an average age of 61.2 years. They underwent a stereotactic biopsy as a method of primary surgical treatment. The patients in whom a craniotomy and maximal reduction of the tumor mass were performed comprised the control group of 21 patients (radical surgery group), consisting of 13 (61.9%) males and 8 (38.1%) females with an average age of 62.3 years.

All survived patients were clinically examined at follow-ups twice, one year and 2 years after the surgery. The observed variables for both groups of patients were the tumor pathohistology (the tumor type), the survival period (the time between surgery and follow-up), and the outcome (the quality of life) assessed by The Extended Glasgow Outcome Scale (GOSE)^{4,5}.

Data statistical analysis was carried out to compute the results and compare various investigated prognostic variables in two different groups of patients. χ^2 -test and Fisher’s Exact Test were used to analyze the difference in frequency variances between the case and the control group. The level of significance was set at $p < 0.05$. Commercially available software (SPSS for Windows, release

9.0.0, by SPSS Inc., Chicago, Illinois, USA) was utilized for data processing.

Results

Nine out of 11 (81.8%) patients in the case group (stereotactic biopsy) survived, while 2 patients died. The fatality rate for the case group was 18.2%. The tumor was located above the tentorium, in the frontal, parietal, and occipital cerebral lobe in 2 patients each (18.2%), in the temporal lobe in one patient (9.1%), in both the temporal and occipital lobes in 2 (18.2%), and in the mid-brain in 2 patients (18.2%; Table 1).

Regarding the tumor type (pathohistological tumor tissue diagnostics), glioblastoma multiforme was recorded in 5 (45.5%) patients of the case group, astrocytoma and ependymoma were recorded in 2 cases each (18.2%), while oligodendroglioma and mixed glioma were noticed in one patient each (9.1%; Table 2).

Six patients (54.5%) were additionally operated on by open surgery due to continued tumor growth following a stereotactic procedure. Two patients from the case group

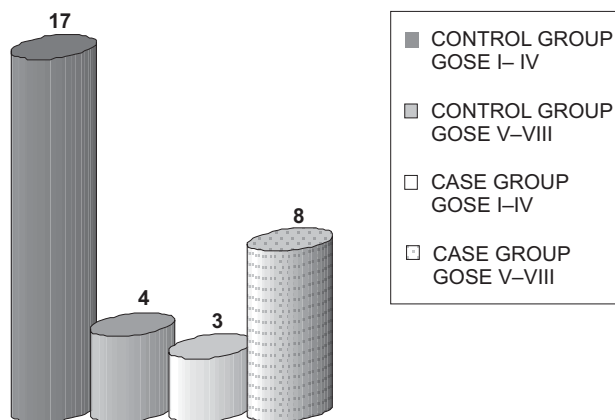


Fig. 1. Comparison of the outcome between the case and control group.

TABLE 1
DISTRIBUTION OF PATIENTS FROM BOTH GROUPS ACCORDING TO TUMOR LOCALIZATION

Tumor localization	No (%) of patients	
	Radical surgery	Stereotactic biopsy
Frontal lobe	3 (14.3)	2 (18.2)
Parietal lobe	3 (14.3)	2 (18.2)
Temporal lobe	5 (23.8)	1 (9.1)
Occipital lobe	2 (9.5)	2 (18.2)
Frontal and parietal lobes	4 (19.0)	0
Parietal and temporal lobes	2 (9.5)	0
Temporal and occipital lobes	1 (4.8)	2 (18.2)
Midbrain	1 (4.8)	2 (18.2)
Total	21 (100.0)	11 (100.0)

$\chi^2 = 7.324$; $df = 7$; $p = 0.396$

TABLE 2
DISTRIBUTION OF PATIENTS FROM BOTH GROUPS ACCORDING TO TUMOR PATHOLOGY

Tumor type	No (%) of patients	
	Radical surgery (craniotomy)	Stereotactic biopsy
Glioblastoma multiforme	10 (47.6)	5 (45.5)
Astrocytoma	2 (18.2)	2 (18.2)
Ependymoma	2 (18.2)	2 (18.2)
Oligodendroglioma	5 (23.8)	1 (9.1)
Mixed glioma	2 (18.2)	1 (9.1)
Total	21 (100.0)	11 (100.0)

$\chi^2 = 1.709$; $df = 4$; $p = 0.789$

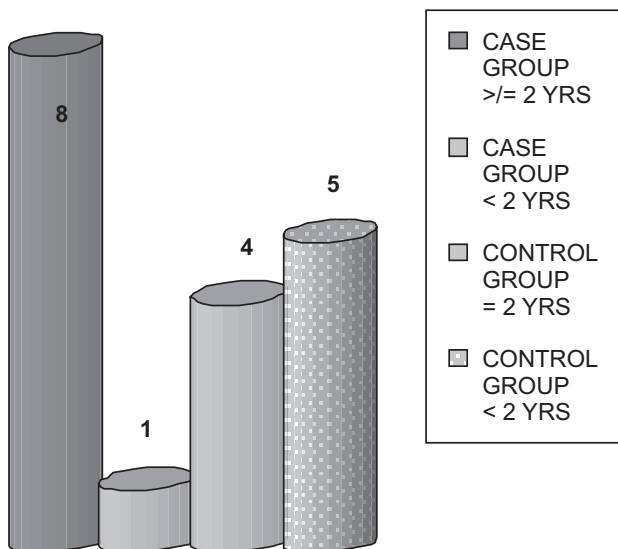


Fig. 2. Comparison of the survival between the case and control group.

died and one patient (11.1%) among the survived was GOSE I-IV (severely disabled), 5 patients (55.5%) were GOSE V-VII (mild to moderate disability), and 3 patients (33.3%) were GOSE VIII (full recovery). In 8 (88.9%) patients a satisfactory outcome was recorded (GOSE V-VIII) (Figures 1 and 3). In eight out of 9 patients (88.9%) from the case group, the survival for more than 2 years was recorded, while one patient (11.1%) survived less than 2 years (Figures 2 and 4).

In the control group (radical surgery), 9 out of 21 (42.9%) patients survived and 12 patients succumbed. The control group fatality rate was 57.1%. All tumors were located supratentorially, in the temporal cerebral lobe in 5 (23.8%) patients, in both the frontal and parietal lobes in 4 (19.1%), in the frontal and parietal lobes in

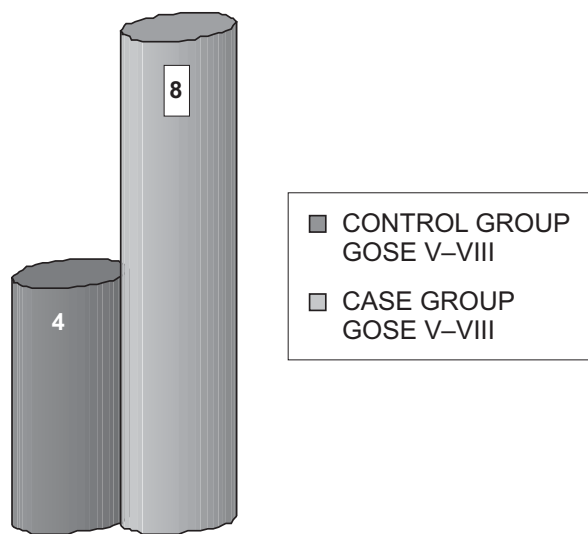


Fig. 3. Satisfactory outcome in the patients who survived surgery.

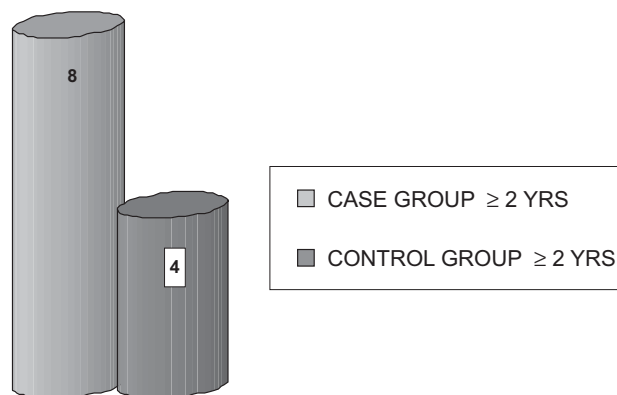


Fig. 4. 2-year survival in both groups of the patients.

3 (14.3%) patients each, in the occipital lobe in 2 (9.5%), in both the parietal and temporal in 2 (9.5%), and in both the temporal and occipital lobes, and in the midbrain in 1 case each (4.8%; Table 1).

A glioblastoma multiforme was recorded by pathohistological tumor tissue diagnostics in 10 (47.6%) patients of the control group, oligodendroglioma in 5 (23.8%), and astrocytoma, ependymoma and mixed glioma in 2 patients each (9.5%; Table 2). Five patients (23.8%) from the control group were re-operated on due to continued tumor growth.

In the control group 12 patients died and 5 (55.6%) among the survived patients were GOSE I-IV at the follow-ups. Three patients (33.3%) were GOSE V-VII, and one (11.1%) was GOSE VIII. A satisfactory outcome was recorded in 4 (44.4%) patients (GOSE V-VIII) (Figures 1 and 3). The survival for more than 2 years was recorded in 4 out of 9 (44.4%) patients, while 5 (55.5%) patients survived less than 2 years after surgery (Figures 2 and 4).

There were no statistically significant differences in variables between the case and control group regarding the tumor localization ($\chi^2=7.324$; $df=7$; $p=0.396$) and the tumor type (pathohistology) ($\chi^2=1.709$; $df=4$; $p=0.789$), indicating that the investigated samples were homogeneous and that the groups were properly selected (Tables 1, 2). However, when the tumor pathohistology was correlated for the entire sample of all 32 patients, a statisti-

TABLE 3
DISTRIBUTION OF ALL PATIENTS ACCORDING TO TUMOR PATHOHISTOLOGY

Tumor type	No (%) of patients
Glioblastoma multiforme	15 (46.9)
Astrocytoma	4 (12.5)
Ependymoma	4 (12.5)
Oligodendroglioma	6 (18.8)
Mixed glioma	3 (9.4)
Total	32 (100.0)

$\chi^2=15.188$; $df=4$; $p=0.004$

TABLE 4
DiSTRIBUTION OF SURVIVED PATIENTS WITH UNFAVORABLE
OUTCOME (GOSE I-IV)

GOSE I-IV	No (%) of patients	
	Radical surgery (craniotomy)	Stereotactic biopsy
Yes	5 (55.6)	1 (11.1)
No	4 (44.4)	8 (88.9)
Total	9 (100)	9 (100)

$\chi^2=4.000$; $df=1$; $p=0.046$ Fisher’s Exact Test

cally highly significant difference between the number of high-grade glioma patients and the number of those with other tumor types was observed ($\chi^2=15.188$; $df=4$; $p=0.004$), demonstrating that glioblastoma multiforme was by far the most frequent tumor type that was found in 15 out of 32 (46.9%) patients in our series (Table 3).

When the outcome assessed by The Extended Glasgow Coma Scale of the case group was compared to that of the control group, a statistically significant difference between the groups was observed for a bad outcome (GOSE I-IV) in favor of the survived patients from the case group ($\chi^2=4.000$; $df=1$; $p=0.046$ Fisher’s Exact Test) (Table 4). However, no statistical difference between the groups was observed for a satisfactory outcome (GOSE V-VIII) ($\chi^2=0.900$; $df=1$; $p=0.343$ Fisher’s Exact Test).

When the survival rate of the case group was compared to that of the control group, a statistically significant difference between the groups was observed for a 2-year survival period in favor of the patients from the case group ($\chi^2=4.000$; $df=1$; $p=0.046$ Fisher’s Exact Test; Table 5).

Discussion

The glioma treatment options and survival odds are associated with the tumor type, size and location, as well as the patient’s age. The goal of glioma surgery is to remove as much of the tumor as possible, while minimizing damage to healthy tissue. However, uncertainty still exists about the adequate treatment of adult patients with

TABLE 5
DISTRIBUTION OF SURVIVED PATIENTS ACCORDING TO
LENGTH OF SURVIVAL

Survival period	No (%) of patients	
	Radical surgery (craniotomy)	Stereotactic biopsy
<2 yrs	5 (55.6)	1 (11.1)
≥2 yrs	4 (44.4)	8 (88.9)
Total	9 (100)	9 (100)

$\chi^2=4.000$; $df=1$; $p=0.046$ Fisher’s Exact Test

unresectable, primary, biopsy-proven high-grade glioma⁶. The majority of the patients from both groups in our series were middle aged men in whom the tumor was located supratentorially, mostly at the frontal, parietal and temporal cerebral lobes (Table 1). Pathohistologically, high-grade glioma (glioblastoma multiforme) was the most frequent tumor type found (Tables 2 and 3).

Since an appropriate tumor treatment depends upon precise morphological diagnosis⁷, we have preferred a stereotactic biopsy as a primary surgical option for selected malignant brain glioma patients. In view of this, computed tomography-guided stereotactic brain tumor biopsy proved to be an effective, feasible, reliable and relatively safe method associated with a low likelihood of postbiopsy hemorrhage, which can even be performed as an outpatient day-surgery procedure⁸⁻¹¹. While some authors have stressed that the method may be inaccurate in ensuring a correct pathohistological diagnosis¹², we support the standpoint that a stereotactic biopsy can usually provide accurate tumor material which is sufficient enough for further clinical management guiding subsequent therapy^{7,13-15}. Therefore, it should be employed to direct glioma therapy where complete excision is not possible or when diagnostic questions arise¹⁶. Usually, the rationale cited for performing a stereotactic biopsy was the tumor localization, preferably in eloquent or near-eloquent brain areas¹², and the most frequently established histopathological diagnosis was a glioblastoma multiforme¹⁴.

This background characterizes the crucial idea of this study, the main hypothesis of which is that a stereotactic biopsy represents less radical surgery, having some advantages over open surgery when the outcome and survival for selected brain glioma patients are concerned.

In view of this, a statistically significant difference between the case and control group of our patients was observed for a bad outcome (GOSE I-IV) in favor of the patients who were treated by a stereotactic biopsy ($p<0.05$) (Tables 3 and 4, Figures 1 and 2).

Prognostic glioma factors that predict overall survival rate include young age, pilocytic histology, gross total resection, and small preoperative tumor volumes^{17,18}. At the same time, gross total tumor resection was associated with significantly improved survival rate compared to tumor biopsy only¹⁹. On the contrary, some studies evaluating low-grade glioma suggest that no survival benefit was related to the initial tumor resection when compared to biopsy²⁰. Considering this, a statistically significant difference between the case and control group was observed for a 2-year survival period in favor of the patients who were treated by a stereotactic biopsy in our series ($p<0.05$) (Tables 3 and 4, Figures 3 and 4).

Conclusion

The majority of patients (88.9%) in whom a stereotactic biopsy was performed survived for a two-year period and recovered well (GOSE V-VIII). Most of those treated by radical surgery succumbed (57.1%) or were severely disabled (55.6%) at follow-ups (GOSE I-IV). The

survival rate was by far higher and the outcome was considerably better in the patients from a stereotactic biopsy group compared to those from radical surgery group. Considering the results of this study, it appears that a stereotactic biopsy is well justified as a surgical method of choice for the primary malignant brain glioma treatment concerning the survival and the quality of life of se-

lected patients. Eventually, it is necessary to remind of a particular limitation of this study that occurs from its retrospective character and relatively small number of patients. Therefore, supplementary prospective investigations are required to support these findings.

REFERENCES

- BURTON EC, PRADOS MD, *Curr Treat Options Oncol*, 1 (2000) 459. — 2. STUPP R, JANZER RC, HEGI ME, VILLEMURE JG, MIRIMANOFF RO, *Semin Oncol*, 30 (2003) 23. — 3. KIRBY S, BROTHERS M, IRISH W, FLORELL R, MACDONALD D, SCHOLD C, CAIRNCROSS G, *J Natl Cancer Inst*, 20 (1995) 1884. — 4. TEASDALE GM, PETTIGREW LE, WILSON JT, MURRAY G, JENNETT B, *J Neurotrauma*, 15 (1998) 587. — 5. WILSON JT, PETTIGREW LE, TEASDALE GM, *J Neurotrauma*, 15 (1998) 573. — 6. NIEDER C, GROSU AL, ASTNER S, MOLLS M, *Anticancer Res*, 25 (2005) 4605. — 7. FEIDEN W, STEUDE U, BISE K, GÜNDISCH O, *Neurosurg Rev*, 14 (1991) 51. — 8. BHARDWAJ RD, BERNSTEIN M, *Neurosurgery*, 51 (2002) 358. — 9. FIELD M, WITHAM TF, FLICKINGER JC, KONDZIOLKA D, LUNSFORD LD, *J Neurosurg*, 94 (2001) 545. — 10. HALL WA, *Cancer*, 82 (1998) 1749. — 11. KIM JE, KIM DG, PAEK SH, JUNG HW, *Acta Neurochir (Wien)*, 145 (2003) 547. — 12. JACKSON RJ, FULLER GN, ABI-SAID D, LANG FF, GOKASLAN ZL, SHI WM, WILDRICK DM, SAWAYA R, *Neuro Oncol*, 3 (2001) 193. — 13. CHANDRASOMA PT, SMITH MM, APUZZO ML, *Neurosurgery*, 24 (1989) 160. — 14. FERREIRA MP, FERREIRA NP, PEREIRA FILHO ADE A, PEREIRA FILHO GDE A, FRANCISCATTO AC, *Surg Neurol*, 65 (2006) 27. — 15. MCGIRT MJ, VILLAVICENCIO AT, BULSARA KR, FRIEDMAN AH, *Surg Neurol*, 59 (2003) 277. — 16. PLUNKETT R, ALLISON RR, GRAND W, *Neurosurg Rev*, 2 (1999) 117. — 17. BUCKNER JC, O'FALLON JR, DINAPOLI RP, SCHOMBERG PJ, FARR G, SCHAEFER P, GIANNINI C, SCHEITHAUER BW, BALLMAN KV, *J Neurooncol*, 84 (2007) 279. — 18. STIEBER VW, *Curr Treat Options Oncol*, 2 (2001) 495. — 19. BUCKNER JC, *Semin Oncol*, 30 (2003) 10. — 20. LOTE K, EGELAND T, HAGER B, STENWIG B, SKULLERUD K, BERG-JOHNSEN J, STORM-MATHISEN I, HIRSCHBERG H, *J Clin Oncol*, 15 (1997) 3129.

B. Splavski

*Department of Neurosurgery, University Hospital Center Osijek, Huttlerova 4, 31000 Osijek, Croatia
e-mail: splavuno@hotmail.com*

VRIJEDNOST STEREOTAKSIJSKE BIOPSIJE U POBOLJŠANJU STOPE PREŽIVLJAVANJA I KVALITETE ŽIVOTA BOLESNIKA S MALIGNIM GLIOMIMA MOZGA

SAŽETAK

Cilj ovoga rada bio je istražiti moguće razlike u stopi preživljavanja i uspješnosti liječenja bolesnika s malignim gliomima mozga liječenih dvama različitim kirurškim metodama. Tijekom trogodišnjega razdoblja, 32 su bolesnika s gliomima mozga kirurški liječena, nakon čega je proveden onkološki terapijski protokol. Bolesnici su bili podijeljeni u dvije skupine, ovisno o primijenjenoj metodi kirurškoga liječenja. Oglednu skupinu činilo je 11 bolesnika u kojih je učinjena stereotaksijska biopsija, a kontrolnu skupinu sačinjavao je 21 radikalno operirani bolesnik (kraniotomija i maksimalna redukcija tumorskoga tkiva). Svi su preživjeli bolesnici klinički ispitivani na kontrolnim pregledima (u razdoblju od godinu dana i 2 godine nakon kirurškoga liječenja). Promatrane varijable u obje skupine bile su tumorska patohistologija (tip tumora), stopa preživljavanja (vrijeme između operacije i kontrolnoga pregleda), te uspješnost liječenja prosuđena pomoću proširene glazgovske ljestvice uspješnosti liječenja (The Extended Glasgow Outcome Scale). Statistička analiza podataka provedena je radi usporedbe različitih istraživanih varijabli iz obje skupine bolesnika. Većina bolesnika u kojih je učinjena stereotaksijska biopsija preživjela je zahvat duže od 2 godine, dok je većina radikalno operiranih bolesnika umrla ili je bila teško onesposobljena na kontrolnom pregledu. Stopa preživljavanja i uspješnost liječenja u bolesnika operiranih metodom stereotaksijske biopsije bili su znatno bolji u usporedbi s onima u radikalno operiranih bolesnika. Sukladno tomu, čini se kako je stereotaksijska biopsija kirurška metoda izbora primarnoga liječenja selekcioniranih bolesnika s malignim gliomima mozga kada je u pitanju preživljavanje i kvaliteta života ovakvih bolesnika.