

# Symptomatic Sacral Perineurial (Tarlov) Cysts

Tomislav Sajko, Damir Kovač, Nenad Kudelić and Lana Kovač

Department of Neurosurgery, University Hospital »Sestre milosrdnice«, Zagreb, Croatia

## ABSTRACT

*Sacral perineurial (Tarlov) cysts are rare lesions. Over a seven year period 4000 patients underwent surgery for lumbar disk herniation. In three patients neurological symptoms were caused by large sacral perineurial cysts. Methods of choice for diagnosis of Tarlov cysts are lumbosacral magnetic resonance imaging and computerized tomography myelography. The majority of Tarlov cysts are asymptomatic. In case of large ( $\geq 1.5$  cm) and symptomatic perineurial cyst, as in three patients reported in this article, microsurgical treatment was successful. Although rare, perineurial (Tarlov) cysts must be taken into consideration when approaching to patient with low back and radicular pain. Authors review the medical literature, pathological and pathophysiological features and treatment options of sacral perineurial cysts.*

**Key words:** symptomatic sacral perineurial cysts, Tarlov cysts

## Introduction

Sacral perineurial cysts were first described by Tarlov in 1938<sup>1</sup>. Tarlov cysts arise at the junction of the dorsal ganglion and the posterior nerve root and develop between the endoneurium and perineurium<sup>2</sup>. According to Nabors' classification perineurial cysts are classified as Type II menigeal cysts<sup>3</sup>. The prevalence of sacral perineurial cysts has been estimated to be 1.5 to 4.6%<sup>4,5</sup>. Perineurial cysts typically involve sacral nerve roots and are usually discovered incidentally during computed tomography (CT) or magnetic resonance imaging (MRI) for other condition. Majority of perineurial cysts are asymptomatic, but approximately 1% may become large and cause symptoms by local compression of surrounding neural structures<sup>4</sup>. Over a seven and a half year period we came across three patients with large, symptomatic sacral perineurial cysts that were operated on. Clinical picture, pathological and pathophysiological characteristics, MRI findings and treatment options are presented.

## Patients and Methods

Over a seven and a half year period (January 2000–November 2007) there were 4000 patients with lumbar disc herniation operated at the Department of Neurosurgery, University Hospital »Sestre milosrdnice« in Zagreb, Croatia. There were only three patients with large sacral perineurial cysts presenting with low back and radicular pain. All three patients were women, aging between 48–68 years. The detailed characteristics of the patients'

clinical presentation are summarized in Table 1. In all three cases, CT and MRI scans revealed a cystic lesion in the region of S1-S3. On MRI scans the lesion was low signal on T1-weighted images and high signal on T2-weighted images. Also, there was characteristically scalloping of the sacral vertebral body (Figure 1).

## Surgical procedure

After introduction of the general anaesthesia, the skin incision, usually from L5 to S3 was made. Sacral lamina were exposed and S1S2 laminectomy was performed. The operating microscope was introduced. The cyst wall was fenestrated and CSF like fluid was evacuated. Cyst resection followed with caution taken to prevent damage of the sacral nerve roots. The cyst wall was removed as close as possible to the normal structures. Upon resection of the cyst wall thorough inspection of the dural sac and sacral roots was performed. After the haemostasis the cyst cavity was covered with fibrin glue. The wound was closed in a watertight fashion.

## Pathohistological examination

Resected specimens were formalin fixed and paraffin embedded. Light microscopy demonstrated that the cyst wall was composed of dense connective tissue with sparse cellularity Figure 2. In the patient No. 2, in a part of the cyst wall a remaining of the degenerated axon was found and it was S-100 immunoreactive.

**TABLE 1**  
PATIENT CHARACTERISTICS AND CLINICAL PRESENTATION

Patient No.	Age (yr)/sex	Length of history	Clinical presentation
1	68/F	6 months	Low back pain, root radical pain, sensory disturbances, leg motor strength 4/5
2	59/F	2 weeks	Low back pain, bladder dysfunction
3	48/F	5 years	Low back pain, root radical pain, sensory disturbance, claudication, leg motor strength 3/5



Fig. 1. T1 weighted sagittal MR scan of lumbosacral spine. White arrow indicated a Tarlov cyst with characteristically scalloping of the sacral vertebral body.

### Surgical outcome

All three patients experienced substantial resolution of the preoperative symptoms. Patients No. 1 and 3 had resolution of leg numbness and motor weakness. Patient No. 2 had a transient worsening of the bladder dysfunction that resolved within one month. There was no CSF leak. On follow-up all patients had mild low back pain.

### Discussion

According to Nabors et al. spinal meningeal cysts are classified as three types: Type I-extradural cysts without spinal nerve fibers; Type II-extradural meningeal cysts with spinal nerve root fibers and Type III-intradural meningeal cysts<sup>3</sup>.

The term »sacral perineurial cysts« is often misused as referring to the other cystic lesion in the sacral region<sup>6,7</sup>. Although CT and MRI are useful in determining the diagnosis of a spinal cystic lesion, the definite diagnosis of a sacral perineurial cyst should be a histopathological diagnosis, in order to avoid the term misuse.

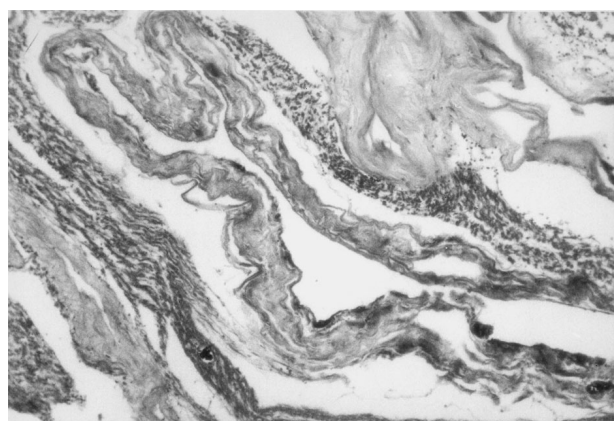


Fig. 2. Microscopic picture demonstrates that the cyst wall is composed of dense connective tissue with sparse cellularity.

Several hypothesis exist regarding the cause of Tarlov cysts, including inflammation within the nerve root, developmental or congenital origin and trauma<sup>4,8,9</sup>. One of our patients reported a low back trauma several years prior to the clinical presentation.

Of the various mechanisms proposed to explain the cyst size progression, the »ball-valve« mechanism is the most accepted one. According to this theory the CSF enters the cyst with systolic pulsation but is unable to exit through the same portal during diastole<sup>5,10</sup>. Intraoperative we did not observe quick refill of the cyst. There is a possibility that cases in the literature describing quickly refilling of the cyst upon fenestration have been confused with the term »meningeal diverticulum« because the latter can communicate freely with the spinal subarachnoid space<sup>2</sup>.

Vast majority of sacral perineurial cyst remain asymptomatic. Cyst enlargement, by pressuring the periost or joint capsule, may cause local back pain. Radicular pain results from cyst compressing the nerve root, and in the case of ventral root compression motor weakness occurs. All our patients reported exacerbation of symptoms upon coughing, lifting and standing which can be explained by »ball-valve« mechanism.

Conservative treatment of the sacral perineurial cysts should be the first choice. The surgical treatment is recommended in cases when MRI scans reveal a large ( $\geq 1.5$  cm) cyst associated with neurological symptoms and no response to conservative therapy.

The reported treatment options for sacral perineurial cysts include partial cyst removal and cyst wall imbrication, partial cyst removal and neck ligation with or without nerve root resection, microsurgical cyst removal and cyst wall imbrication together with defect repairing with muscle, Gelfoam or fibrin glue, CT-guided percuta-

neous aspiration with or without fibrin glue replacement, cyst subarachnoid shunt placement and lumbar peritoneal shunt<sup>11–13</sup>.

Based on the data from the literature and from our limited experience we consider the microsurgical operation to be the safest surgical method.

## REFERENCES

1. TARLOV IM, *AMA Arch Neurol Psychiatry*, 40 (1938) 1067. — 2. GUO D, SHU K, CHEN R, KE C, ZHU Y, LEI T, *Neurosurgery*, 60 (2007) 1059. — 3. NABORS MW, PAIT TG, BYRD EB, KARIM NO, DAVIS DO, KOBRINE AI, ROZZOLI HV, *J Neurosurg*, 68 (1988) 366. — 4. LANG-DOWN AJ, GRUNDY JR, BIRCH NC, *J Spinal Disord Tech*, 18 (2005) 29. — 5. PAULSEN RD, CALL GA, MURTAGH FR, *AJNR Am J Neuroradiol*, 15 (1994) 293. — 6. CASPAR W, PAPAVERO L, NABHAN A, LOEW C, AHLHELM F, *Surg Neurol*, 59 (2003) 101. — 7. NISHIURA I, KOYAMA T, HANDA J, *Surg Neurol*, 23 (1985) 265. — 8. ACOSTA FL JR, QUI-
- NONES-HINOJOSA A, SCHMIDT MH, WEINSTEIN PR, *Neurosurg Focus*, 15 (2003) E15. — 9. VOYADZIS JM, BHARGAVA P, HENDERSON FC, *J Neurosurg*, 95 (2001) 25. — 10. ARUNKUMAR MJ, SELVAPANDIAN S, CHANDY MJ, *Neurol India*, 47 (1999) 61. — 11. BARTELS RH, VAN OVERBEEKE JJ, *Neurosurgery*, 40 (1997) 861. — 12. MORIO Y, NANJO Y, NAGASHIMA H, MINAMIZAKI T, TESHIMA R, *Spine*, 26 (2001) 451. — 13. PATEL MR, LOUIE W, RACHLIN J, *AJR Am J Roentgenol*, 168 (1997) 367.

*T. Sajko*

*Department of Neurosurgery, University Hospital »Sestre milosrdnice«, Vinogradska 29, 10000 Zagreb, Croatia  
e-mail: t\_sajko@net.hr*

## SIMPTOMATSKE PERINEURIJALNE CISTE SAKRUMA

### SAŽETAK

Simptomatske perineurijalne (Tarlov-e) ciste sakruma su vrlo rijetke. Kroz razdolje od sedam i pol godina, operirano je 4000 bolesnika s hernijacijom diska lumbalnog segmenta kralježnice. U samo tri bolesnice neurološki simptomi su bili uzrokovani većom perineurijalnom cistom sakruma. Metode izbora u dijagnosticiranju Tarlov-ih cista su kompjuterizirana mijelografska tomografija i magnetna rezonancija. Većina Tarlov-ih cista je asimptomatska. U slučaju postojanja veće ( $\geq 1,5$  cm) i simptomatske perineurijalne ciste sakruma, mikrokirurško liječenje je uspješno. Premda rijetke, perineurijalne ciste sakruma se moraju uzeti u obzir u diferencijalnoj dijagnozi bolesnika s križoboljom. Autori iznose pregled medicinske literature, patološke i patofiziološke karakteristike i metode liječenja perineurijalnih cista sakruma.