

# Lymphomatoid Granulomatosis in a 23-year-old Man – Cytological and Histological Typing and Rapid Response to Steroid and Cyclophosphamide Combination Therapy

Neven Rakušić<sup>1</sup>, Diana Krmpotić<sup>1</sup>, Ana Hećimović<sup>1</sup>, Zagorka Boras<sup>1</sup>, Božica Vrabec-Branica<sup>1</sup>, Sonja Džebro<sup>2</sup>, Nevena Rakušić<sup>3</sup>, Tomislav Rešković<sup>4</sup> and Nika Rakušić<sup>4</sup>

<sup>1</sup> University Hospital for Lung Diseases »Jordanovac«, Zagreb, Croatia

<sup>2</sup> Department of Patology, University Hospital »Merkur«, Zagreb, Croatia

<sup>3</sup> University of Zagreb, School of Medicine, Zagreb, Croatia

<sup>4</sup> University of Rijeka, School of Medicine, Rijeka, Croatia

## ABSTRACT

*Lymphomatoid granulomatosis (LG) is currently called as extranodal angiocentric and angiodestructive immunoproliferative disorder with various degrees of histological differentiation and disease severity. Histological grading and clinical manifestations are due to number of atypical large EBV+ B-lymphatic cells. We report the case of a 23-year-old man clinically presented with fever, sweating, and physical intolerance, and bilateral pulmonary infiltrates of nodular type and destructive changes on the chest X-ray, previously treated with antituberculous for 1.5 month. As the disease showed progression, diagnostic procedures extended to transbronchial lung biopsy and percutaneous fine needle aspiration with cytological and histological analysis of collected specimens, all being not conclusive enough. LG was confirmed by open lung biopsy, followed by induction of corticosteroids and cyclophosphamide therapy. Very good clinical, functional and radiomorphologic improvement was achieved in a few weeks, and remission of disease maintained in long term follow-up.*

**Key words:** lymphomatoid granulomatosis, pulmonary nodular infiltrates, open lung biopsy, EBV+ B-lymphatic cells

## Introduction

Lymphomatoid granulomatosis (LG) is a rare EBV-driven lymphoproliferative disorder, which may progress to diffuse large B-cell lymphoma (DLBCL)<sup>1</sup>. LG predominantly affects the lungs, but also other extrathoracic sites such as brain, kidneys, liver and skin. Diagnosis is difficult and based on histological examination of samples usually achieved by surgical procedures<sup>2,3</sup>. Therapy is based on high-dose steroids associated with cyclophosphamide, and recently used targeted agent rituximab, which specifically targets the CD 20 antigen on the surface of B-cells<sup>4,5</sup>.

## Case Report

A 23-year-old man previously being healthy referred to local hospital because of haemoptysis, cough and fever.

He noticed intolerance of physical activity and excessive sweating for last 3 months. On admission to hospital, chest X-ray showed multiple nodal and destructive infiltrations bilaterally, predominantly in the left lung. Laboratory findings revealed sedimentation rate of 17, normal peripheral blood smear, and negative bacteriologic tests for non-specific bacteria and *M. tuberculosis*. Four regimen antituberculous therapy was empirically introduced for 1.5 month. In that period, patient's clinical status deteriorated with radiologic progression of bilateral lung infiltrates. For further diagnostic procedures the patient was admitted to our Clinic. On appearance, he was moderately dyspnoeic, pale, sweated, febrile to 37.6 °C, and in a depressive mood. Neurological examination was normal. Lung auscultation revealed normal breathing sounds with scattered rales bilaterally. Laboratory

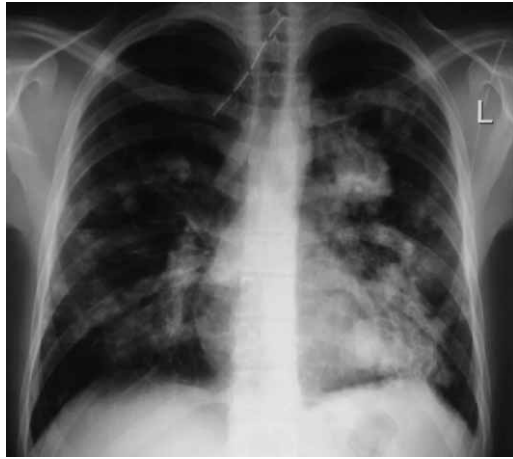

Fig. 1. A chest radiograph before treatment showing bilateral multiple nodular infiltrates.

findings showed elevated sedimentation rate (21), lymphopenia (0.7 g/L), hypogammaglobulinaemia (4.09 g/L), elevated liver enzymes (AST 58 U/L, ALT 83 U/L and GGT 112 U/L), and elevated C-reactive protein (CRP 43 mg/L), whereas the other routine laboratory tests were all within the normal values. Angiotensin converting enzyme (ACE), p and c ANCA, autoantibody screen and test for HIV were negative or normal. Tuberculin test was negative. Functional testing of respiratory tract showed restrictive pattern on spirometry (FEV1 65.5%,

FVC 55%) and decreased diffusing CO capacity of 57%. Bacteriological samples were negative for common causes, and *M. tuberculosis* negative in direct smears. Chest X-ray and chest computed tomography (CT) showed multiple nodal and destructive, confluent infiltrates of both lungs (Figures 1 and 2). Fiberbronchoscopy showed hyperaemic bronchial mucosa with normal intraluminal secretion. Bronchoalveolar lavage (BAL) showed a hypercellularity with 95% macrophages and 5% lymphocytes, and the CD4/CD8 ratio of 1.1. Brushing for cytological examination was done, followed by transbronchial lung biopsy of 5 specimens. Cytological findings of biopsy specimens were non-specific: lymphoid cells, pneumocytes, phagocytes and a few epitheloid cells. Histology of the same specimens showed lung parenchyma with lymphoid cells infiltrations (CD3+ and CD 20+), several intact vessels, and a few lymphoid infiltrations in the small vessel's walls. Percutaneous fine needle aspiration of pulmonary lesions by diascopic X-ray guidance has been done, and cytological smear showed lymphoid cells, few epitheloid cells and few large cells with basophilic cytoplasm and big nuclei (Figure 3). As cytological and histological findings were inconclusive, the open lung biopsy of the left lower lobe was performed under mini-thoracotomy. In the two biopsy specimens of lung parenchyma (4×2×0.7 cm and 3×1×0.2 cm in size) nodular infiltrates (up to 0.4 cm in diameter) consisted of polymorphic lymphoid cells and large cells with big nucleoli and mitotic activity (proliferation index 20%) were found (Figure 4). Immunohistochemical study showed that small lymphocytes were positive for CD3+, CD43+ and CD 5+, and large lymphatic cells were positive for CD20+, CD30+ and Epstein-Barr virus (EBV) + cells 5–7/ HPF-1 (Figures 5, 6, and 7). Vessels of greater calibre were intact, but small vessels contained subendothelial foci of lymphocytic infiltration (Figure 8). There were found no granulomatous formations. The diagnosis of lymphomatoid granulomatosis was established.

Immediate treatment followed with combination of corticosteroids in high doses (methylprednisolon 0.8 mg/kg of body weight) with cyclophosphamide 100 mg/day.

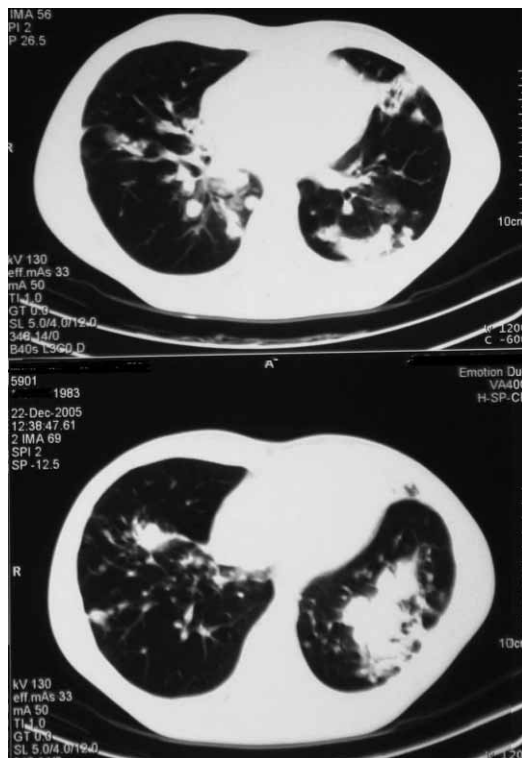


Fig. 2. Sequential CT scans of thorax before treatment. Multiple nodular confluent infiltrates, some excavated.

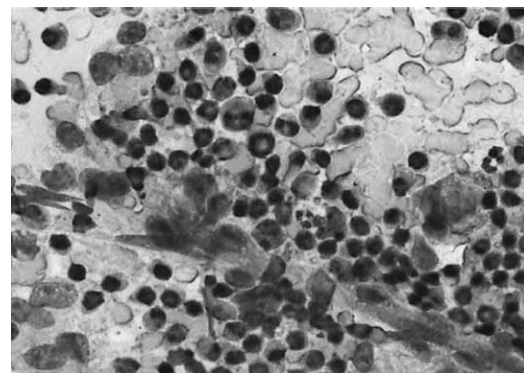


Fig. 3. Fragment of endothelial cells and polymorphic infiltrate containing small lymphocytes, histiocytes and one large atypical mononuclear cell beside (May-Grünwald-Giemsa stain, x400).

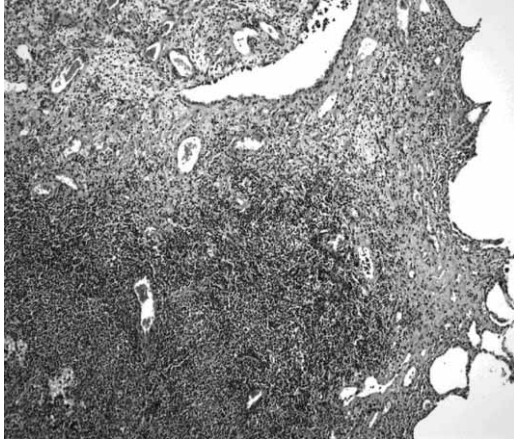


Fig. 4. Pulmonary tissue – nodular lymphocytic infiltration (H&E, x400).

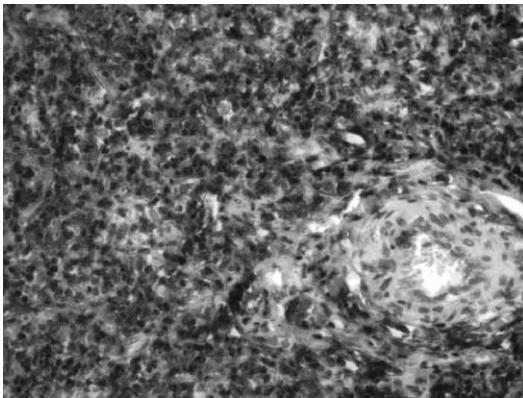


Fig. 5. Immunohistochemical staining of CD3+ numerous small lymphocytes (x400).

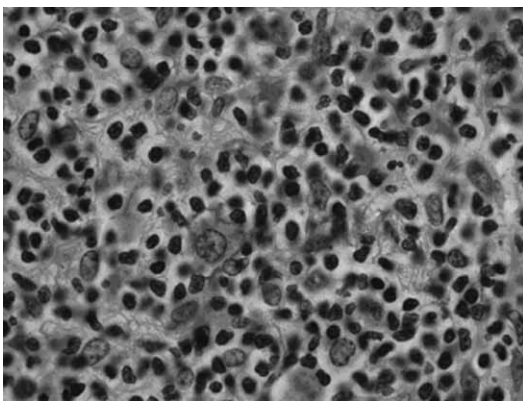


Fig. 6. Immunohistochemical staining of CD20+ large lymphatic cells (x400).

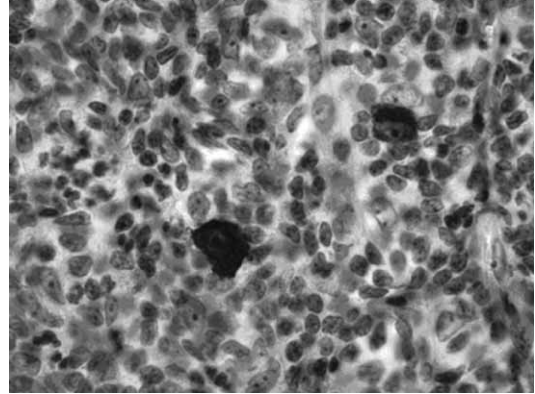


Fig. 7. Immunohistochemical staining of EBV+ B-lymphatic cells (x400).

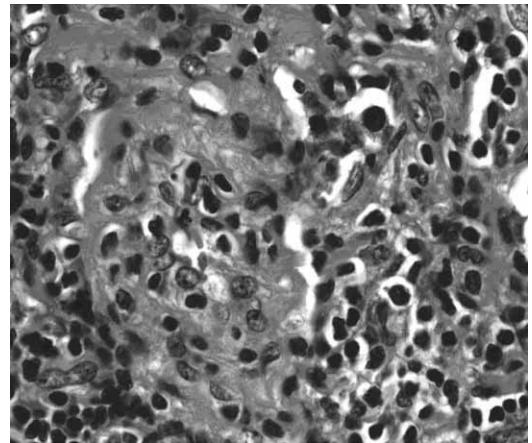


Fig. 8. Vasculitis with subendothelial foci of lymphocytic infiltration (H&E, x400).

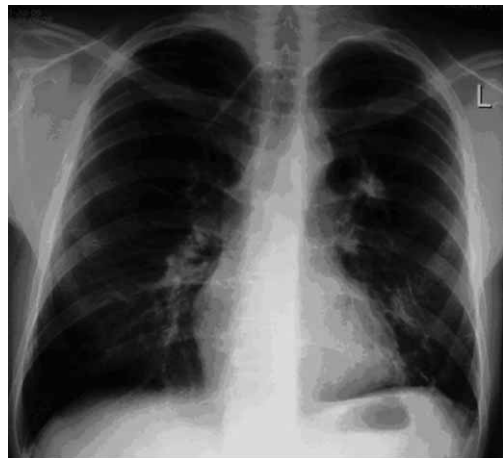

Fig. 9. Control chest X-ray after three weeks of treatment. Total regression of bilateral infiltrates are observed.

After three weeks of this treatment scheme, rapid and huge morphological regression of lung infiltrates was found on chest X-ray (Figure 9), as well as clinical improvement. The patient was discharged from the hospital, and continued taking at home cyclophosphamide in the same dose for period of 1.5 years, and metilprednisolone was maintained after gradually lowering dose to 8

mg/day, and discontinued after 9 months. After three-year follow-up, the patient has remained in the remission, clinically without any symptoms, and with normal lung function tests and laboratory findings, as well as normal chest X-ray.



## Discussion

LG was initially thought to be an inflammatory granulomatous disease, since its clinicomorphological presentation is somewhat similar to other granulomatoses, particularly Wegener's disease<sup>6,7</sup>. Currently, LG is defined as an extranodal angiocentric and angiodestructive immunoproliferative disorder with various degrees of histological differentiation and severity of clinical manifestations. LG usually occurs at age of 30–50 years, with a marked male predominance<sup>7,8</sup>. Patients are presented with systemic and respiratory symptoms, consisting of fever, weight loss, malaise, cough, dyspnoea, haemoptysis and chest pain. Disease is multisystemic involving many organs such as brain, skin, liver and kidneys, lung is the most frequent site. Radiological imaging by chest X-ray and CT of thorax are characterized with multiple smooth nodal infiltrates (occasionally with destructive pattern) of the lung. Macroscopically, LG forms multiple and often confluent nodules of variable size, which are yellow or grey on the cut surface with areas of necrosis. Histologically, pulmonary nodules are composed of an angiocentric, polymorphous and atypical lymphoid infiltrate with moderate to extensive necrosis involving arterioles and veins. Vessels show mural infiltrates of small lymphocytes and atypical large cells with vesicular nuclei. Subendothelial and adventitial zones are infiltrated by lymphoid cells, and cause erosion and obliteration of the vessel wall and lumen. Occasionally, granulomatous formations are seen. Central necrosis in the pulmonary nodules may be due to cytokines induced by IL-12, which is secreted by EBV infected B-cells<sup>7,9</sup>. Immunohistochemistry shows T-cell infiltrate (predominantly CD4+ T-lymphocytes) with scattered atypical B-cells. The 5-year survival is 30–40%, although spontaneous resolution and complete remission occur occasionally<sup>3</sup>. The main

prognostic factors are the following: age, extension of lesions and histological grading, which is subdivided into three grades according to the quantity and degree of cellular atypia and presence or absence of necrosis. Mitotic figures and necrosis may be extensive, and proliferation index within the B-cell population correlates with the histological grade<sup>2</sup>. In addition, histological grade is shown to be related to number of EBV+ cells<sup>10</sup>. Our case is grade II LG comprising in the lesion the EBV+ cells 5–7/HPF–1 and proliferation index of 20%. The quantification of number of EBV+ B-cells and proliferation index is particularly useful in distinguishing grade II LG from grade III LG<sup>3,7</sup>, suggesting that only grade III LG might proliferate to B-cell lymphoma. Our patient might have a good prognostic outcome regarding age, histological grade, proliferation index, and very good response and remission of the disease after introduction and maintenance of first line therapy with steroids and cyclophosphamide. Administration of rituximab as a second line treatment should be considered in the case of reoccurrence of disease activity in the follow-up of our patient<sup>4,5</sup>.

## Conclusion

Clinical presentation and radiologic imaging of our patient, laboratory findings, as well as cytological and histological examination of specimens achieved by bronchoscopy, all were not of enough diagnostic value. Open lung biopsy with more representative specimens of lung tissue showed nodular infiltrations with EBV+ cells, proliferation index of 20%, and diagnosis of LG grade II was established. Therapy with steroids and cyclophosphamide achieved good and fast control with disease remission.

## REFERENCES

1. WHO Classification of Tumours of Haematopoietic and Lymphoid Tissues 4th (International Agency for Research on Cancer, Lyon, 2008).
2. PISANI RJ, DEREMEE RA, Mayo Clin Proc, 65 (1990) 151.
3. JAFFE ES, WILSON WH, Cancer Surv, 30 (1997) 233.
4. JAFFE S, JARDIN F, DOMINIQUE S, DUET E, HUBSCHER P, GENOVOIS A, CORNE F, BOTA S, NOUVET G, THIBERVILLE L, Eur Respir J, 27 (2006) 644.
5. SMITH MR, Oncogene, 20 (2003) 7359.
6. LIEBOW AA, CARRINGTON CR, FRIEDMAN PJ, Human Pathol, 3 (1972) 457.
7. WILSON WH, KINGMA DW, RAFFELD M, WITTES RE, JAFFE ES, Blood, 87 (1996) 4531.
8. MCCLOSKEY M, CATHERWOOD M, MC-MANUS D, TODD G, CUTHBERT R, RILEY M, Thorax, 59 (2004) 818.
9. GUNEE DG, PERKINS SL, TRAVIS WD, HOLDEN JA, TRIPP SR, KOSS MN, Am J Surg Pathol, 22 (1998) 1093.
10. TANIER P, THIVOLET-BEJUI F, VITERY D, ISAAC S, LOIRE R, CORDIER JF, BERGER F, Eur Respir J, 12 (1998) 102.

N. Rakušić

University Hospital for Lung Diseases »Jordanovac« 104, Zagreb, Croatia  
e-mail: neven.rakusic@zg.t-com.hr

**LIMFOMATOIDNA GRANULOMATOZA U 23-GODIŠNJEG MLADIĆA – CITOLOŠKA  
I HISTOLOŠKA SLIKA I BRZI ODGOVOR NA KOMBINIRANU TERAPIJU KORTIKOSTROIDIMA  
I CIKLOFOSFAMIDOM**

**S A Ž E T A K**

Limfomatoidna granulomatoza (LG) danas se definira kao ekstranodalni angiocentrični i angiodestruktivni limfoproliferativni poremećaj s različitim spektrom histološkog stupnja diferenciranosti i kliničke agresije. Histološki *grading* i klinički tijek ovise o broju atipičnih velikih EBV+ B limfatičnih stanica. Prikazan je slučaj 23-godišnjeg mladića s izraženim simptomima povišene temperature, pojačanog znojenja, intolerancije napora i dispneje, te s radiološki verifikiranim nodularnim i destruktivnim infiltratima pluća obostrano, inicijalno tretiranim antituberkuloticima u trajanju od 1,5 mjesec. Zbog progresivne dinamike bolesti dijagnostika je proširena na bronhološko uzimanje materijala transbronhalnom biopsijom pluća i perkutanu transtorakalnu punkciju lezija pluća s citološkom i histološkom obradom dobivenog materijala, što nije bilo dovoljno za egzaktnu dijagnozu. LG je dokazana u uzorcima dobivenim otvorenim biopsijom pluća, nakon čega je provedena terapija kortikosteroidima i ciklofosfamidom. U nekoliko tjedana postignuto je vrlo dobro kliničko, laboratorijsko, funkcijsko i radiomorfološko poboljšanje, a remisija bolesti održana je u dužem periodu praćenja.