

Expression of Ki-67, P53 and Progesterone Receptors in Uterine Smooth Muscle Tumors. Diagnostic Value

Davor Petrović¹, Damir Babić^{1,3}, Jadranka Ilić Forko^{1,3} and Ivana Martinac²

¹ Department of Gynecological and Prenatal Pathology, University Hospital Center Zagreb, Zagreb, Croatia

² Children's Hospital Zagreb, Zagreb, Croatia

³ University of Zagreb, School of Medicine, Zagreb, Croatia

ABSTRACT

Aim was to investigate expression of Ki-67, P53 and progesterone receptors (PR) in leiomyomas (LM), smooth muscle tumors of uncertain malignant potential (STUMP) and leiomyosarcomas (LMS) and to establish possible usefulness of these three parameters in distinguishing between LM and STUMP, and STUMP and LMS. Retrospective study of 51 uterine smooth muscle neoplasm (16 LM, 18 STUMP, 17 LMS) technically acceptable for analyses from years 2002–2007 from Department of Gynecological and Prenatal Pathology, University Hospital Center Zagreb, Croatia. Immunohistochemical analysis of Ki-67, P53 and PR expression was performed. Every nuclei stained brown, regardless of shade intensity, was considered positive. The interpretation of immunohistochemical staining was expressed as number of positive cells in 100 cell count in most active area of the slide. Non-parametric analysis of variance Kruskal-Wallis test was performed. Ki-67 expression was negative in all LM and higher than 5% in 12/18 STUMP and 10/17 LMS. Significant differences were observed between LM and STUMP expression for Ki-67 ($p=0.000$), and LM and LMS expression for Ki-67 ($p=0.000$). There was no expression of P53 in LM, expression of P53 was found in 7/17 LMS and 5/18 STUMP. Expression of P53 was significant between LM and LMS ($p=0.002$), and between LM and STUMP ($p=0.006$). Expression of PR was found in 16/16 LM and 18/18 STUMP, 10/17 LMS did not show PR expression. Expression of PR was significant between LM and LMS ($p=0.018$) and STUMP and LMS ($p=0.004$). The findings of our study in concordance with other study results are helpful information establishing more diagnostic criteria and parameters for diagnosis in doubtful cases between three entities. Immunoassaying for Ki-67, P53 and PR are such parameters. The panel of their expression in specific case eases diagnosis.

Key words: Ki-67, P53, PR, leiomyoma, STUMP, leiomyosarcoma

Introduction

Smooth muscle uterine neoplasms are most common female genital tract neoplasms. Usually they are classified as: leiomyomas (LM), smooth muscle tumors of uncertain malignant potential (STUMP) and leiomyosarcomas (LMS)^{1–4}. Principal consideration factors for this classification are: mitotic index, nuclear atypia, presence and extent of coagulation necrosis and other morphological features such as age and tumor size^{1–6}. LM of the uterus is the most frequent smooth muscle neoplasms occurring in almost 40% of women over 35 years of age⁴. Their clinical outcome is excellent. STUMP are characterized by lower mitotic index and/or less nuclear atypia

and/or absent or minimal presence of coagulative necrosis and more favorable clinical outcome than LMS^{1,7–8}. Incidence of STUMP in literature available to authors is usually described as rare without exact figures^{1–4}. LMS are rare, making about 1.3% of all uterine malignant neoplasms and 16% of malignant mesenchymal neoplasms are LMS. Approximately 1 out of 800 smooth muscle tumors is LMS¹. Clinical course and outcome are usually rapid and unfavorable. Local recurrence and metastasis risk is high, with overall 5-year survival from 12 to 25%¹. Varieties of prognostic factors were studied in LMS with unanimous agreement on clinical significance only for

extent of tumor at the moment of diagnosis^{1,9–14}. Antigen Ki-67 is a nuclear protein expressed in all active phases of the cell cycle except G0¹⁵. It is regarded as an indicator of cell proliferative activity and biological aggressivity¹⁶. High expression of Ki-67 was found in LMS versus LM^{7,17–19}, but studies comparing LM, STUMP and LMS are rare^{7,18,20–21}. Nuclear protein P53 is present in many normal human cells in non-detectable amounts²². P53 gene mutations are frequent in human neoplasm development and mutant P53 is accumulated in high quantities^{19,22}. LMS show higher P53 expression than other smooth muscle uterine neoplasms^{7,20–21,23}. Monoclonal mouse anti-human progesterone receptor is intended for use in semi-quantitative detection of progesterone receptor (PR) by light microscope. Reactivity of normal myometrium is characterized with high staining intensity⁴. Expression of PR is higher in LM and STUMP than in LMS^{7,20–21,24–25}. In the available literature, uniform morphological features such as mitotic count, type of mitoses, presence and extension of coagulation necrosis, tumor size, tumor border, tumor growth pattern are all relevant for establishing diagnoses of various smooth muscle uterine neoplasms^{1–6}. Still, variations in interpretation and subjective identifications of some of these features (mitotic figures, type of necrosis) have resulted in introduction of new diagnostic methods and criteria in diagnostics of these neoplasms. Immunohistochemical methods for expression analysis of various factors have been investigated^{1–28}. Discrepancies between approaches to evaluation of results of the particular method continually gives rise to new researches and consensus reaching. Different methods and procedures²⁶ were applied and used in effort to solve the mentioned dilemma. We were focused on diagnostic methods, adequate for use in routine practice, results of which would provide additional information to facilitate correct diagnosis achievement process. The aim of the present study was to investigate expression of Ki-67, P53 and progesterone receptor (PR) in LM, STUMP and LMS and to establish possible usefulness of these three parameters combined with other morphological features in distinguishing between LM and STUMP, and STUMP and LMS. We used method of exact and easily applicable morphometric analysis (precise number of positive cells in the total number of cells, presented as a percentage of positive cells).

Materials and Methods

At the Department of Gynecological and Prenatal Pathology of the University Hospital Center Zagreb, 3661 cases of smooth muscle neoplasms were diagnosed during the 2002–2007 period: 25(0.68%) STUMP, 43 (1.17%) LMS, and 3593 (98.15%) LM. For the purposes of this retrospective study we used neoplasms that met all the criteria (neoplasms were surgically removed in their entirety by hysterectomy, the amount of tissue embedded in paraffin blocks was satisfactory, materials from patients who underwent surgery in other hospitals were excluded); there were 18/25 STUMP, 17/43 LMS. The equal

number of LM was chosen by random sampling. This retrospective study includes 16 cases of LM, 18 cases of STUMP and 17 cases of LMS. All technically acceptable cases are from 2002 to 2007 from Department of Gynecological and Prenatal Pathology, University Hospital Center Zagreb, Croatia. Diagnosis of LM, STUMP and LMS was based on previously published criteria^{1–4}. All tissue specimens were obtained from surgically removed tumors. Tissue was fixed in formalin and cut to thickness of 5 µm from paraffin-embedded blocks. All haematoxylin eosin slides and all immunohistochemical slides for each case were reviewed by three experienced pathologist.

Immunohistochemistry

Paraffin-embedded tumor sections were deparaffinized and stained in automated platform DakoCytomation using monoclonal mouse anti-human Ki-67 antigen (Dako, Glostrup, Denmark), monoclonal mouse anti-human P53 protein (Dako, Glostrup, Denmark), and monoclonal mouse anti-human progesterone receptor (PR) clone: PgR 636 (Dako, Glostrup, Denmark). Criteria for positivism and negativism of cell nuclei were based on data, suggestions and photographs published in recent notebook of immunohistochemistry²⁹. Every nucleus stained brown, regardless of shade intensity, was considered positive. The interpretation of immunohistochemical staining was expressed as number of positive cells in 100 cell count in most active area of the slide. PC Image analysis software ISSA 3.1 VAMS Zagreb, Croatia was used. Results were divided in three categories: negative, 1–10% positive cells and more than 11% positive cells.

Statistical analysis

The SPSS 11.5 for Windows (SPSS inc., Chicago IL, USA) was used. Analyses of frequencies and non-parametric analysis of variance Kruskal-Wallis test were performed. ($p < 0.05$ was considered statistically significant).

Results

Ki-67 expression

Expression of Ki-67 was negative in 16/16 LM, 4/18 STUMP and 4/17 LMS. 1–5% of cells were positive in 8/18 STUMP and 3/17 LMS. Expression was positive in more than 15% of cells of 9/17 LMS. Mean expression of Ki-67 in LM is 0, 9.3% in STUMP and 14.4% in LMS. Statistically significant differences in Ki-67 expression was found between LM and STUMP ($p = 0.000$, Tables 1 and 2) and between LM and LMS ($p = 0.000$, Tables 1 and 2, Figure 1).

P53 expression

Expression of P53 was negative in 16/16 LM, 11/18 STUMP and 9/17 LMS. Expression of P53 in 1–10% of cells showed 5/17 STUMP and 2/17 LMS. Expression in >20% of cells showed 5/17 LMS. Median expression of P53 in LM is 0, 4.1% in STUMP and 17.5% in LMS. A sig-

TABLE 1
NUMBER OF LM, STUMP AND LMS POSITIVE FOR KI-67 AND P53 CONSIDERING POSITIVE CELLS COUNT

% Expression	Ki-67			p 53			PR		
	LM N	STUMP N	LMS N	LM N	STUMP N	LMS N	LM N	STUMP N	LMS N
0	16	4	4	16	11	9	0	0	10
1-10	0	8	4	0	5	2	0	0	0
≥11	0	6	9	0	2	6	16	18	7
Total	16	18	17	16	18	17	16	18	17

*Abbreviations: LM – leiomyoma, STUMP – smooth muscle tumor of uncertain malignant potential, LMS – leiomyosarcoma
† N – number of cases

nificant difference in expression of P53 was seen between LM and LMS (p=0.002, Table 1 and 2), as well as between LM and STUMP (p=0.006, Table 1 and 2, Figure 1).

PR expression

Expression of PR≥11% was positive in 16/16 LM, 18/18 STUMP, and 7/17 LMS. 10/17 LMS showed no PR expression, while 16/18 STUMP showed expression in ≥51% cells. Median expression of PR in LM was 68.3%, in STUMP 72.2% and in LMS 28.6%. A significant difference in expression of PR was seen between LM and LMS (p=0.018, Table 1 and 2), and STUMP and LMS (p=0.004, Tables 1 and 2, Figure 1)

TABLE 2
EXPRESSION OF KI-67, P53 AND PR IN LM, STUMP AND LMS

Tumor	Ki-67	p53	PR
LM	0†	0†	64.1±14.9 (27-90)†
STUMP	9.3±13.5 (0-40)†	4.1±8.3 (0-30)†	72.2±20.1 (11-98)†
LMS	14.4±13.3 (0-42)†	17.5±26.9 (0-80)†	28.6±40 (0-100)†

*Abbreviations: LM – leiomyoma, STUMP – smooth muscle tumor of uncertain malignant potential, LMS – leiomyosarcoma
† means±SE (range)

Discussion and Conclusion

The results in our study showed significant difference in Ki-67 expression between LM and STUMP as well as between LM and LMS. Expression of P53 was differed significantly between LM and LMS, and between STUMP and LM. There was a significant difference in PR expres-

sion between LM and LMS, as well as between STUMP and LMS. In spite of relatively clearly defined criteria¹⁻⁵, differential pathological diagnosis between LM, especially atypical LM with bizarre looking nuclei, and STUMP. And STUMP versus LMS can be difficult, particularly assessment of malignant potential and clinical outcome.

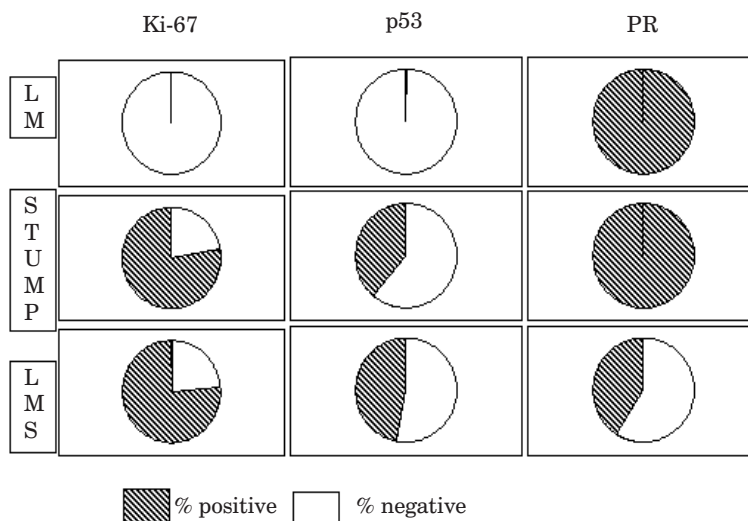


Fig. 1. Expression of Ki-67, p53 and PR in LM, STUMP and LMS; PR – progesterone receptors LM – leiomyoma, STUMP – smooth muscle tumor of uncertain malignant potential, LMS – leiomyosarcoma.

The criteria for establishing diagnosis of LM, STUMP and LMS has been constantly changing over the years from the initial and essential significance of the number of mitoses, nuclear atypia to the current significance of the presence of coagulation necrosis. Notorious problem of mitotic figure recognition in neoplasms full of clumped and degenerately changed nuclei and cells⁷ is recognized. No convention of the applied criteria proved to be completely safe and clear in establishing diagnosis. The published literature investigated presence and expression of the proliferative factors and hormone receptors in the cells of the smooth muscle neoplasms. Those papers stated the results for restricted number of cases, which motivated us to contribute to the research of the expression of the proliferative factors P53, Ki-67, and PR by investigating our own material. Additional factors and their parameters are needed and welcomed in effort to distinguish these two entities. We are aware that the restricted number of cases and relative difficulties in comparing the obtained results to the existing findings, due to the different evaluation criteria for the expression of the P53, Ki-67 and PR, may result in defective interpretation. We have chosen to measure expression of Ki-67, P53 and PR as a number of positive cells/100 cells count because it is acceptable and affordable in every day's practice. Achieved number is an absolute number but can also represent a percentage of positive cells. Unified measure of expression represents a path toward the most representative result of immunohistochemistry analysis with a potential of facilitating the process of diagnosing various types of smooth muscle neoplasms. Every nuclei stained brown, regardless of shade intensity, was considered positive. The interpretation of immunohistochemical staining was expressed as number of positive cells in 100 cells count in most active area of the slide. We compared our data with previously presented studies. None of them investigate immunoreactivity for P53, Ki-67 and PR in all three groups of uterine smooth muscle neoplasms, which make comparison of results somewhat difficult. Zhai et collaborates¹⁸ found less than 5% reactivity for P53 in all LM and O'Neill et al.²³ found reactivity for P53 in 1/10 LM. In our study all LM did not

show reactivity for P53. There are no results of P53 reactivity, to the best of author's knowledge, in STUMP so we could not compare our results. Zhai et collaborates¹⁸ found reactivity for P53 in half of their LMS (7/14), we found P53 reactivity in third (6/17) of our LMS. Zhai et collaborates¹⁸ based their results of Ki-67 reactivity on the number of positive cells per 10 high power fields (HPF) of microscope and their results can not be compared with others. Amada et al.¹⁹ didn't found reactivity of Ki-67 in LM, Mayerhofer et al.²⁷ found reactivity of Ki-67 in one tenth (2/25) of LM and O'Neil et al.²³ found Ki-67 reactivity in two fifths (4/10) of LM. We didn't found Ki-67 reactivity in our LM. Mayerhofer et al.²⁷ didn't found Ki-67 reactivity (0/22) in STUMP and O'Neill et al.²³ found Reactivity for Ki-67 in half (2/4) of STUMP. We found reactivity for Ki-67 in three fifths (14/18) of STUMP. Amada et al.¹⁹ found $\geq 3.6\%$ reactivity for Ki-67 in nine tenths (21/24) of LMS and $\geq 15\%$ reactivity for Ki-67 in three fifths (14/24) of LMS, Mayerhofer et al.²⁷ found reactivity for Ki-67 in half (10/20) of LMS and O'Neil et al.²³ found reactivity for Ki-67 in four fifths (20/22) of LMS. Three fourths (13/17) of our LMS show reactivity for Ki-67. Bodner et al.²⁸ found reactivity for PR in two fifths (9/21) of LMS and Leitao et al.²⁴ found reactivity of PR in one third (9/25) of LMS. In our study two fifths (7/11) of LMS show PR reactivity. Akhan et al.²¹ found in their study of 24 LMS that PR expression over 10% has positive effects on patient's survival. The findings of our study are in concordance with other studies results and are helpful information establishing more diagnostic criteria for diagnosis in doubtful cases between three entities. Major diagnostic features, as number of mitoses per 10 HPF, nuclear atypia, presence and extent of coagulation necrosis, tumor borders, tumor size, clinical stage¹⁻⁵, could be insufficient for accurate diagnosis because of tissue condition (clumped or degenerate nuclei) or amount of tumor tissue and relation to surrounding myometrium (laparoscopic methods used) so additional relevant parameters are needed. Immunostaining for Ki-67, P53 and PR are such parameters. The panel of their expression in specific case eases diagnosis.

REFERENCES

- ZALONDEX CJ, HENDRICKSEN CJ, Mesenchymal tumors of the uterus. In: KURMAN RJ (Ed) Blaustein's pathology of the female genital tract (Spinger Verlag, New York, 2002). — 2. VOLLENHOVEN BJ, LAWRENCE AS, HEALY DL, Br J Obstet Gynecol, 97 (1990) 285. — 3. BELL SW, KEMPSON RL, HENDRICKSON MR, Am J Surg Pathol, 18 (1994) 252. — 4. ROBBOY SJ, BENTLEY RC, BUTNOR K, ANDERSON MC, Environ health Perspect, 108 (2000) 779. — 5. CLEMENT PB, Int J Gynecol Pathol, 19 (2000) 39. — 6. RAMMEH-ROMMANI S, MOKNI M, STITA W, TRABELSI A, HAMISSA S, SRIHA B, TAHAR-YACOUBI M, KORBI S, J Gynecol Obstet Biol Reprod, 34 (2005) 568. — 7. MITTAL K, DEMOPOULOS RI, Hum Pathol, 32 (2001) 984. — 8. PETERS WA, HOWARD DR, ANDERSEN WA, FIGGE DC, Obstet Gynecol, 83 (1994) 1015. — 9. SCHWARTZ Z, DGANI R, LANCET M, KESSLER I, Gynecol Oncol, 20 (1985) 354. — 10. EVANS HL, CHAWLA SP, SIMPSON C, FINN KP, Cancer, 62 (1988) 2239. — 11. NORDAL RR, KRISTENSEN GB, KAERN J, STENWIG AE, PETTERSEN EO, TROPE CG, Acta Oncol, 34 (1995) 794. — 12. HSIEH CH, LIN H, HUANG CC, HUANG EY, CHANG SY, CHANGCHIEN CC, Acta Obstet Gynecol Scand, 82 (2003) 74. — 13. BODNER K, BODNER-ADLER B, KIMBERGER O, CZERWENKA K, LEODOLTER S, MAYERHOFER K, J Reprod Med, 48 (2003) 95. — 14. MAYERHOFER K, OBERMAUR A, WINBICHLER PG, PETRU E, KAIDER A, HEFLER L, CZERWENKA K, LEODOLTER S, KAINZ C, Gynecol Oncol, 74 (1999) 196. — 15. CATTORRETTI G, BECKER MHG, KEY G, DUCHROW M, SCHLUTER C, GALLE J, GERDES J, J Pathol, 168 (1992) 357. — 16. LAYFIELD LJ, LIU K, DODGE R, BARSKY SH, Arch Pathol Lab Med, 124 (2000) 221. — 17. CHOU CY, HUANG SC, TSAI YC, HSU KF, HUANG KE, Gynecol Oncol, 65 (1997) 225. — 18. ZHAI YL, KOBAYASHI Y, MORI A, ORII A, NIKAIIDO T, KONISHI, FUJII S, Int J Gynecol Pathol, 18 (1999) 20. — 19. AMADA S, NAKANO H, TSUNEYOSHI M, Int J Gynecol Pathol, 14 (1995) 134. — 20. GÖKSLAN H, TÜRKERİ L, KAVAK ZN, EREN F, SISMANOĞLU A, ILVAN S, DURMUSOĞLU F, Gynecol Obstet Invest, 59 (2005) 36. — 21. AKHAN SE, YAVUZ E, TECER A, IYIBOZKURT CA, TUZLALI S, BENGİSU E, BENGİSU E, BERKMAN S, Gynecol Oncol, 99 (2005) 36. — 22. VOJ-

TEŠEK B, BARTEK J, MIDGLEY CA, LANE DP, *J Immunol Methods*, 151 (1992) 237. — 23. O'NEILL CJ, MCBRIDE HA, CONNOLLY LE, MCCLUGGAGE WG, *Histopathology*, 50 (2007) 851. — 24. LEITAO MM, SOSLOW RA, NONAKA D, OLSHEN AB, AGHAJANIAN C, SABBATINI P, DUPONT J, HENSLEY M, SONODA Y, BARAKAT RR, ANDERSON S, *Cancer*, 101 (2004) 1455. — 25. BODNER K, BODNER-ADLER B, KIMBERGER O, CZERWENKA, MAYERHOFER K, *Fertile Steril*, 81 (2004) 1061. — 26. NOLA M, BABIĆ D, ILIĆ J, MARUŠIĆ M, UZAREVIĆ

B, PETROVEČKI M, SABIONCELLO A, KOVAC D, JUKIĆ S, *Cancer*, 78 (1996) 2543. — 27. MAYERHOFER K, LOZANOV P, BODNER K, BODNER-ADLER B, KIMBERGER O, CZERWENKA K, *Acta Obstet Gynecol Scand*, 83 (2004) 1085. — 28. BODNER K, BODNER-ADLER B, KIMBERGER O, CZERWENKA K, LEODOLTER S, MAYERHOFER K, *Anticancer Res*, 23 (2003) 729. — 29. DABS DJ, *Diagnostic Immunohistochemistry* (Churcill Livingstone Elsevier, Philadelphia, 2006).

D. Petrović

*Department of Gynecological and Prenatal Pathology, University Hospital Center Zagreb, Petrova 13, Zagreb, Croatia
e-mail: dvrptruc@yahoo.com*

EKSPRESIJA KI-67, P53 I PROGESTERONSKIH RECEPTORA U GLATKOMOŠIĆNIM TUMORIMA MATERNICE. DIJAGNOSTIČKA VRIJEDNOST

SAŽETAK

Cilj rad je istražiti ekspresiju Ki-67, p53 i progesteronskih receptora (PR) u leiomiomima (LM), glatkomišićnim tumorima nepoznata zloćudnog potencijala (STUMP) i leiomiosarkomima (LMS), te utvrditi moguću korisnost ta tri promatrana parametra u olakšavanju razlikovanja LM, STUMP i LMS. Učinjena je retrospektivna studija 51 glatkomišićnog tumora (16 LM, 18 STUMP, 17 LMS), tehnički pogodnih za analizu, dijagnosticiranih u Zavodu za ginekološku i perinatalnu patologiju Kliničkog bolničkog centra Zagreb u razdoblju 2002.–2007. godine. Izvršena je imunohistokemijska analiza ekspresije Ki-67, p53 i PR. Statistička analiza učinjena je primjenom ne-parametrijskih metoda analize varijance Kruskal-Walis-ovim testom. U svim LM nije nađena ekspresija Ki-67, ekspresija Ki-67 viša od 5% nađena je u 12/18 STUMP i 10/17 LMS. Značajna je razlika u ekspresiji Ki-67 između LM i STUMP ($p=0,000$) te između LM i LMS ($p=0,000$). Nije nađena ekspresija p53 u LM. Ekspresija p53 nađena je u 7/17 LMS i 5/18 STUMP. Značajna je razlika u ekspresiji p53 između LM i LMS ($p=0,002$) te između LM i STUMP ($p=0,006$). Ekspresija PR nađena je u 16/16 LM i 18/18 STUMP, dok 10/17 LMS nije pokazalo nikakvu ekspresiju PR. Značajna je razlika u ekspresiji PR između LM i LMS ($p=0,018$) te između STUMP i LMS ($p=0,004$). Nalazi naše studije u suglasju s rezultatima drugih studija su korisna novost u utvrđivanju novih dijagnostičkih kriterija i parametara za olakšavanje postavljanja dijagnoze u nejasnim slučajevima ova tri entiteta. Imunohistokemijsko utvrđivanje ekspresije Ki-67, p53 i PR, te panel rezultata njihove ekspresije olakšava dijagnozu u pojedinim nejasnim slučajevima.