

PARENCHYMAL POST-IRRADIATION ANGIOSARCOMA: A CASE REPORT

Željko Soldić¹, Daniela Salopek¹, Marijana Jazvić¹, Jasna Radić¹, Jasmina Marić-Brozić¹, Davor Tomas²,
Petar Kirac³, Ante Bolanča¹ and Zvonko Kusić¹

¹University Department of Oncology and Nuclear Medicine, ²Ljudevit Jurak University Department of Pathology,
³University Department of Surgery, Sestre milosrdnice University Hospital, Zagreb, Croatia

SUMMARY – Secondary angiosarcoma is an aggressive tumor that can develop in breast cancer patients treated with conserving therapy and radiotherapy. The symptoms can be misleading, whereas mammography and fine-needle aspiration (FNA) are typically negative in early stage of the disease. A high grade of clinical suspicion is very important for early diagnosis. A case of angiosarcoma involving breast parenchyma in a patient treated with quadrantectomy and radiotherapy for T1cN1Mx breast carcinoma is presented.

Key words: *Neoplasms – radiation induced; Sarcoma – etiology; Breast neoplasms – radiotherapy; Radiotherapy – adverse effects*

Introduction

Angiosarcoma is a malignant tumor with morphological properties of endothelial cells¹. Mammary angiosarcoma can be of primary (*de novo*) type in breast parenchyma, secondary type in the skin and underlying soft tissue after radical mastectomy followed by chronic lymphedema known as Stewart Treves syndrome, secondary in the skin after radical mastectomy and radiotherapy, or secondary in the skin or/and breast parenchyma following conservation treatment and radiotherapy¹. Primary angiosarcoma of the breast is a rare tumor, accounting for 0.05% of all primary malignancies of the breast², its incidence being constant through the years¹. Post-radiotherapy angiosarcoma can manifest in the chest wall after mastectomy and radiotherapy when the neoplastic endothelial proliferation is confined to the skin¹, or

after conservation treatment followed by radiotherapy when in most cases it only involves the skin, with very rare exclusive involvement of the breast parenchyma¹. The overall risk of sarcoma in populations exposed to radiation has been estimated to be up to 0.8%³. A Finnish study evaluating the risk of angiosarcoma after radiotherapy among patients with cancer of the breast, cervix uteri, corpus uteri, lung, ovary, prostate, rectum and lymphoma estimated an increased risk of angiosarcoma following breast and gynecologic cancer in every treatment group (radiotherapy with or without chemotherapy or no radio- or chemotherapy), except after chemotherapy alone⁴. Based on reports from The Netherlands Cancer Registry, the incidence of secondary angiosarcoma has been reported to range from 0.05% to 0.16%⁵. According to Taghian *et al.*, the cumulative incidence of angiosarcoma after radiation therapy for breast cancer ranges from 0.2% 10 years after treatment to 0.43% 20 years after treatment and 0.78% 30 years after treatment⁶. Schünemann *et al.* estimated the rate of edema after radical mastectomy alone to be 27.7%, after radical mastectomy with radiotherapy 44.7%, after modified radical mastectomy alone 29.3%, after modified radical mastectomy with

Correspondence to: Daniela Salopek, MD, University Department of Oncology and Nuclear Medicine, Sestre milosrdnice University Hospital, Vinogradska c. 29, HR-10000 Zagreb, Croatia

E-mail: dsalopek@gmail.com

Received November 10, 2008, accepted in revised form August 28, 2009

radiotherapy 29.3%, after breast conserving surgery alone 6.9%, and after breast conserving surgery with radiotherapy 10.4%.⁷ It is known that angiosarcoma develops in 0.07%-0.45% of patients with chronic lymphedema.⁸ In addition, a case of angiosarcoma associated with chronic lymphedema of the lower extremity after hysterectomy and radiotherapy for carcinoma of the uterine cervix has been described.⁹ The incidence of radiation induced sarcoma of the head and neck is 0.3%.¹⁰ The problem of angiosarcoma needs full attention because of the ineffectiveness of radiotherapy and chemotherapy. Recently, genetic predisposition has been assumed to play a role in the development of post-radiation angiosarcoma.¹¹

We report on a case of parenchymal angiosarcoma after quadrantectomy and radiotherapy for T1cN1 breast carcinoma. It was the first case of post-radiotherapy angiosarcoma at our department.

Case Report

A 70-year-old woman underwent quadrantectomy and axillary lymph node dissection for invasive ductal carcinoma of the right breast in 2004. The tumor was multifocal, measuring 1 cm and 0.8 cm, located in the upper lateral quadrant of the breast and with positive estrogen and progesterone receptors. Two of twelve lymph nodes were positive for tumor cells. The patient was treated with 6 cycles of chemotherapy with 5-flourouracil, epirubicin and cyclophosphamide. Af-

terwards, she received 25 tangent field radiotherapy sessions to the breast in a total dose of 45 Gy with a local "boost" of 10 Gy divided into four sessions. Hormone therapy was started with tamoxifen, which was replaced with exemestane after two years. She was doing well and was seen periodically in the following years.

In April 2008, she began to complain of persisting pain, redness of the skin and edema of the right breast. Mammography and magnetic resonance showed cutaneous and subcutaneous edema with no sign of recurrent tumor. Ultrasonography revealed a hypoechogenic area in the upper lateral quadrant of the right breast, so fine needle aspiration (FNA) biopsy was performed. Stained smears from the FNA sample showed larger clusters of fat cells, degenerative granulocytes, hystiocytes and erythrocytes. The patient was diagnosed with mastitis and treated with penicillin. Two months later, repeat ultrasonography showed a new hypoechogenic area in the medial quadrant of the right breast, with FNA biopsy suspect of tumor cells. The patient underwent right total mastectomy and lymph node dissection, which revealed a 3.5-cm angiosarcoma (Fig. 1) composed of spindle-shaped cells forming clusters and stripes pervaded with erythrocytes and areas of recent bleeding (Fig. 2). The mitotic rate was 20/10 HFP. The nuclei were hyperchromatic and anisokaryotic. Immunoperoxidase staining was strongly positive for vimentin (Fig. 3) and CD34 (Fig. 4), and negative for cytokeratin

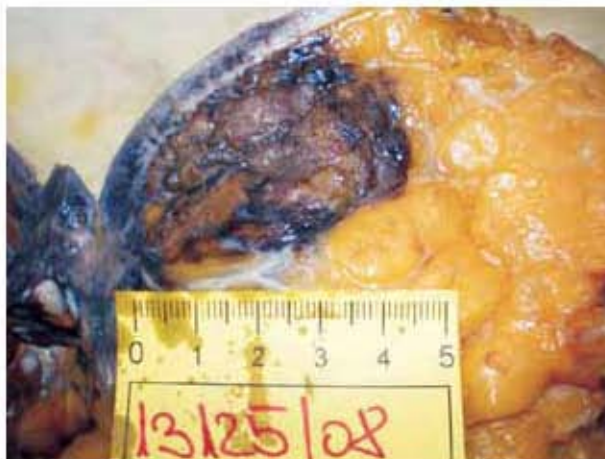

Fig. 1. Surgical specimen of the angiosarcoma: brown solid tumor mass involving the right breast parenchyma and measuring 3.5 cm.

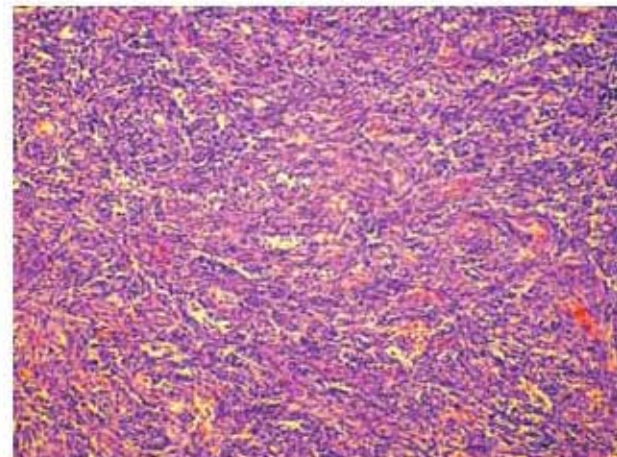


Fig. 2. Histopathologic evaluation shows spindle-shaped cells forming clusters and stripes (hematoxylin-eosin stain, original magnification X200)

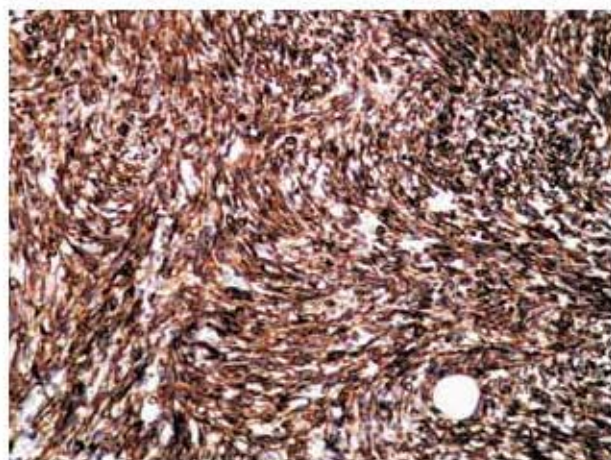


Fig. 3. Vimentin immunocytochemical expression in the cytoplasm of spindle-shaped cells (original magnification X200).

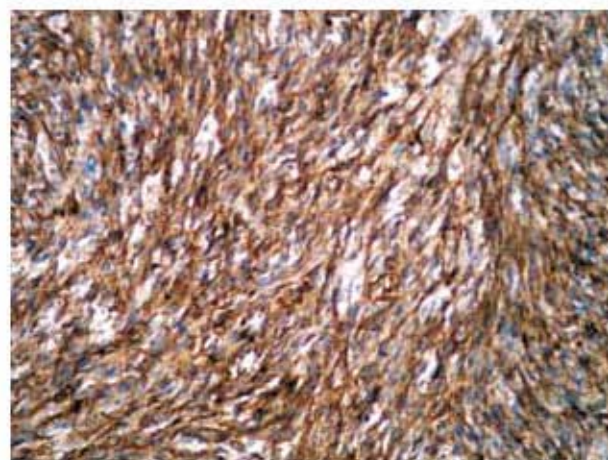


Fig. 4. CD34 immunocytochemical expression in the cytoplasm of spindle-shaped cells (original magnification X200).

and SMA. The tumor infiltrated the nipple but not the breast skin. The resection margins and axillary lymph nodes were free from tumor tissue. There was no need for further surgical treatment. Radiotherapy and chemotherapy are not part of therapeutic algorithm because of their ineffectiveness¹. The patient has since been doing well and under observation.

Discussion

Secondary angiosarcomas are rare tumors that can develop in breast tissue after radiotherapy. They usually develop 3-12 years after primary radiotherapy, with the median interval between radiotherapy and angiosarcoma of approximately 6 years¹². Angiosarcomas behave aggressively, spread hematogenously with a recurrence rate of about 70% and 35% of 2-year disease-free survival¹³. The first reported case of angiosarcoma arising within the skin overlying an irradiated breast was published in 1981¹⁴. Stewart-Treves iatrogenic angiosarcoma, i.e. Stewart-Treves syndrome, is attributed to chronic lymphedema¹. Recently, a new form of cutaneous post-radiation angiosarcoma of the breast (CPRASB) related to breast-conserving therapy has been recognized, which differs from Stewart-Treves syndrome by a shorter latency period and absence of chronic lymphedema¹⁵. Namely, surgical therapy for breast carcinoma has developed and improved over years, so a shift has been made from radical mastectomy and modified radical

mastectomy towards breast conservation. Controlled studies have shown that breast-conserving therapy is as safe and effective as mastectomy for stage I and II patients¹⁶, i.e. that breast-conserving therapy and mastectomy have an identical survival rate¹⁷. Studies have also shown that breast-conserving surgery has many benefits, from better body image through psychosocial well-being to overall quality of life¹⁸. As the quality of life in cancer patients has been attracting an ever increasing amount of interest, an even wider use of breast-conserving therapy should be expected in the years to come. What needs to be considered is that even patients treated for preinvasive or minimally invasive carcinomas are at a risk of developing angiosarcoma as a deadly complication.

Another problem lies in the fact that secondary angiosarcomas are often clinically subtle with a delay in the diagnosis¹⁹. Their clinical onset is often deceiving, and because it includes skin thickening or discoloration, it can be taken by mistake for radiation changes, for example post-radiation morphea, inflammation, trauma or malignant melanoma, especially amelanotic or other types with minimal pigmentation²⁰. Together with the rarity of their occurrence, angiosarcomas are unlikely to be considered at that point of initial presentation. Even if suspected, inappropriate choice of diagnostic method often results in disease oversight. As reported by Gherardi *et al.*, mammography and FNA biopsy as the most frequently used diagnostic methods in these patients are

typically negative in early disease and are not diagnostic for angiosarcoma. Results of punch biopsy can also be misleading²¹. Only biopsy, incisional or excisional biopsy, ensures satisfactory and accurate sampling and should be considered the gold standard for the diagnosis.

In conclusion, the diagnosis of post-irradiation angiosarcoma requires correlation of clinical findings, knowledge of prior breast surgery and radiotherapy, and immunocytochemical findings. It is very important to remember that even patients treated for preinvasive or minimally invasive carcinomas are at a risk of developing angiosarcoma. A high index of clinical suspicion is needed as it can be crucial for timely action.

References

1. TAVASSOLI F, DEVILEE P. WHO classification of tumors. Pathology & genetics. Tumors of the breast and female genital organs. Lyon: IARC Press, 2003: 94-6.
2. NASCIMENTO AF, RAUT CP, FLETCHER CD. Primary angiosarcoma of the breast: clinicopathologic analysis of 49 cases, suggesting that grade is not prognostic. *Am J Surg Pathol* 2008 Sep 19 [Epub ahead of print].
3. PIERCE SM, RECHT A, LINGOS TI, *et al.* Long-term radiation complications following conservative surgery (CS) and radiation therapy (RT) in patients with early stage breast cancer. *Int J Radiat Oncol Biol Phys* 1992;23:915-23.
4. VIRTANEN A, PUKKALA E, AUVINEN A. Angiosarcoma after radiotherapy: a cohort study of 332163 Finnish cancer patients. *Br J Cancer* 2007;97:115-7.
5. STROBBE LJ, PETERSE JL, Van TINTEREN H, WIJNMAALEN A, RUTGERS EJTH. Angiosarcoma of the breast after conservation therapy for invasive cancer, the incidence and outcome. *Breast Cancer Res Treat* 1998;47:101-9.
6. TAGHIAN A, De VATHIAIRE F, TERRIER P, LE M, AUQUIER A, MOURIESSE H, GRIMAUND E, SARRAZIN D, TUBIANA M. Long-term risk of sarcoma following radiation treatment of breast cancer. *Int J Radiat Oncol Biol Phys* 1991;21:361-77.
7. SCHÜNEMANN H, WILLICH N. Secondary lymphedema of the arm following primary therapy of breast carcinoma. *Zentralbl Chir* 1992;117:220-5.
8. WOODWARD AH, IVINS JC, SOULE EH. Lymphangiosarcoma arising in chronic lymphedematous extremities. *Cancer* 1972;30:562-72.
9. NAKAZONO T, KUDO S, MATSUO Y, MATSUBAYASHI R, EHARA S, NARISAWA H, YONEMITSU N. Angiosarcoma associated with chronic lymphedema (Stewart-Treves syndrome) of the leg: MR imaging. *Skeletal Radiol* 2000;29:413-6.
10. MARK RJ, BAILET JW, POEN J, TRAN LM, CALCATERRA TC, ABEMAYOR E, FU YS, PARKER RG. Postirradiation sarcoma of the head and neck. *Cancer* 1993;72:887-93.
11. DeBREE, Van COEVORDEN F, PETERSE JL, RUSSELL NS, RUTGERS EJ. Bilateral angiosarcoma of the breast after conservative treatment of bilateral invasive carcinoma: genetic predisposition? *Eur J Surg Oncol* 2002;28:392-5.
12. RAO J, DEKOVEN JG, BEATTY JD, JONES G. Cutaneous angiosarcoma as delayed complication of radiation therapy for carcinoma of the breast. *J Am Acad Dermatol* 2003;49:532-8.
13. TAHIR M, HENDRY P, BAIRD L, QURESHI NA, RITCHIE D, WHITFORD P. Radiation induced angiosarcoma a sequela of radiotherapy for breast cancer following conservative surgery. *Int Semin Surg Oncol* 2006;3:26.
14. MADDOX JC, EVANS HL. Angiosarcoma of skin and soft tissue: a study of forty-four cases. *Cancer* 1981;48:1907-21.
15. BILLINGS S, McKENNEY JK, FOLPE AL, HARDACRE MC, WEISS SW. Cutaneous angiosarcoma following breast-conserving surgery and radiation: an analysis of 27 cases. *Am J Surg Pathol* 2004;28:781-8.
16. VERONESI U, SALVADORI B, LUINI A, *et al.* Conservative treatment of early breast cancer. Long-term results of 1232 cases treated with quadrantectomy, axillary dissection and radiotherapy. *Ann Surg* 1990;211:250-9.
17. VERONESI U, CASCINELLI N, MARIANI L, *et al.* Twenty-year follow-up of a randomized study comparing breast-conserving surgery with radical mastectomy for early breast cancer. *N Engl J Med* 2002;347:1227-32.
18. VOLKERA A, STEGMAIER C, ZIEGLER H, BRENNER H. Quality of life over 5 years in women with breast cancer after breast-conserving therapy *versus* mastectomy: a population based study. *J Cancer Res Clin Oncol* 2008 May 27 [Epub ahead of print].
19. MOORE A, HENDON A, HESTER M, SAMAYOA L. Secondary angiosarcoma of the breast: can imaging findings aid in the diagnosis. *Breast J* 2008;14:293-8.
20. CAFIERO F, GIPPONI M, PERESSINI A, *et al.* Radiation-associated angiosarcoma: diagnostic and therapeutic implications – two case reports and a review of the literature. *Cancer* 1996;77:2496-502.
21. GHERARDI G, ROSSI S, PERRONE S, SCANNI A. Angiosarcoma after breast-conserving therapy. Fine-needle aspiration biopsy, immunocytochemistry and clinicopathologic correlates. *Cancer (Cancer Cytopathol)* 2005;105:145-51.

Sažetak

PARENHIMNI ANGIOSARKOM POSLIJE ZRAČENJA: PRIKAZ SLUČAJA

Ž. Soldić, D. Salopek, M. Jazvić, J. Radić, J. Marić-Brozić, D. Tomas, P. Kirac, A. Bolanča i Z. Kusić

Sekundarni angiosarkom je agresivni tumor koji se može razviti kod bolesnica s rakom dojke liječenih terapijom očuvanja i radioterapijom. Simptomi mogu dovesti u zabunu, dok su mamografija i citološka punkcija redovito negativne u ranom stadiju bolesti. Za ranu dijagnozu vrlo je važna visoka klinička sumnja na ovu bolest. Prikazuje se slučaj angiosarkoma koji je zahvatio parenhim dojke u bolesnice liječene kvadrantektomijom i radioterapijom zbog raka dojke T1cN1Mx.

Ključne riječi: *Novotvorine – izazvane zračenjem; Sarkom – etiologija; Novotvorine dojke – radioterapija; Radioterapija – štetni učinci*