

Luiz Guedes de Carvalho Neto<sup>1</sup>, Wellington Torres de Andrade<sup>2</sup>, Alessandro Leite Cavalcanti<sup>3</sup>, Dmitry Jose de Santana Sarmiento<sup>4</sup>, Ana Flávia Granville-Garcia<sup>3</sup>

## Deformacijska plagiocefalija: prikaz slučaja

### Deformational Plagiocephaly: A Case Report

<sup>1</sup> Odjel za oralnu i maksiofacijalnu kirurgiju Stomatološkog fakulteta Državnoga sveučilišta Paraíba, Campina Grande, Brazil  
DDS, MSc, Research Fellow, Department of Oral and Maxillofacial Surgery, School of Dentistry, State University of Paraíba, Campina Grande, PB, Brazil

<sup>2</sup> Neurokirurški odjel bolnice Antonio Targino, Campina Grande, Brazil  
Division of Neurological Surgery, Hospital Antonio Targino, Campina Grande, PB, Brazil

<sup>3</sup> Odjel za dječju stomatologiju Stomatološkog fakulteta Državnoga sveučilišta Paraíba, Campina Grande, Brazil  
DDS, MSc, PhD, Professor, Department of Pediatric Dentistry, School of Dentistry, State University of Paraíba, Campina Grande, PB, Brazil

<sup>4</sup> Student Stomatološkog fakulteta Državnoga sveučilišta Paraíba, Campina Grande, Brazil  
Undergraduate student, School of Dentistry, State University of Paraíba, Campina Grande, PB, Brazil

#### Sažetak

Plagiocefalija je izraz kojim se obično opisuju kongenitalne asimetrije čela. Frontalnu plagiocefaliju ima oko pet posto pacijenata, uglavnom muške djece s predominacijom desnostranih jednostranih slučajeva. Dijagnoza se obično postavlja odmah nakon rođenja ili u prvom mjesecu života. U ovom prikazu opisujemo devetomjesečno dijete s deformacijskom plagiocefalijom te facijalnom asimetrijom s lijeve strane. Preporučena terapija uključivala je kraniostenozu i ljevostranu orbitalnu osteotomiju. Facijalnu asimetriju znatno je poboljšalo stvaranje novih zona koštanoga rasta.

**Zaprimljen:** 16. kolovoza 2009.

**Prihvaćen:** 16. veljače 2010.

#### Adresa za dopisivanje

Prof. Dr. Alessandro Leite Cavalcanti  
Avenida Manoel Moraes, 471/802  
- Manaíra  
58038-230 João Pessoa, PB, Brasil  
Phone: +55 83 3315-3326  
dralessandro@ibest.com.br

#### Ključne riječi

dijete; kraniotomija; plagiocefalija

#### Uvod

Plagiocefalija potječe od grčkih riječi: *plagio* (koso, zavijeno ili krivo) i *kephale* (glava), a opisuje asimetriju kraniuma (1). Deformacijska plagiocefalija (DP) višeslojni je deformitet kraniuma koji se kod djece javlja prenatalno ili postnatalno (2) te je čest problem u svakodnevnoj praksi (3).

Kod postavljanja dijagnoze i određivanja terapije plagiocefalija bi se trebala inicijalno svrstati u anteriornu ili posteriornu. Dodatno se može ubrojiti među sinostotske i non-sinostotske plagiocefalije (4). Posteriorna sinostotska plagiocefalija posljedica je vrlo rijetke lambdoidne kraniostenoze, a non-posteriorna vanjskih sila i dosta je česta.

Za non-posteriornu sinostotsku plagiocefaliju upotrebljavala su se različita imena - posteriorna plagiocefalija, zatim posturalna, okcipitalna i deformacijska plagiocefalija (1).

Budući da gotovo sva novorođenčad spava na leđima, veći na ima određeni stupanj zaravnavanja stražnjeg dijela glave. To stanje može biti i mnogo gore ako dijete spava samo na jednoj strani. Rezultat je katkada deformacijska plagiocefalija, poznata i kao sindrom spljoštene glave. Prevalencija DP-a kod djece mlađe od 6 mjeseci jest oko 10 posto za okcipitalnu plagiocefaliju i oko 5 posto za frontalnu (5). Uglavnom se javlja kod muške djece (6, 7) i dominantni su desnostrani slučajevi (8).

#### Introduction

The term plagiocephaly, derived from the Greek words *plagio* (oblique, twisted or slant) and *kephale* (head), describes an asymmetric cranium (1). Deformational plagiocephaly (DP) is a multi-planar deformity of the cranium that occurs either pre- or post-natally in infants (2) and is a common problem in daily practice (3).

For diagnosis and treatment, plagiocephaly should initially be categorized as either anterior or posterior. Subsequently, it can be classified as synostotic or nonsynostotic plagiocephaly (4). Posterior synostotic plagiocephaly results from lambdoid craniosynostosis, which is very rare, whereas posterior nonsynostotic plagiocephaly results from external forces and is quite prevalent today. Various names have been assigned to posterior nonsynostotic plagiocephaly, including posterior plagiocephaly, postural plagiocephaly, occipital plagiocephaly, and deformational plagiocephaly (1).

Since the majority of children sleep on their backs, most of them have some flattening of the back of their heads. This condition can be much worse on one side if a child preferentially sleeps with that side down. Deformational plagiocephaly, also known as flattened head syndrome, results from preferentially lying on one side of the head. The prevalence

DP se tijekom standardnoga pedijatrijskog pregleda može dijagnosticirati brzo i jednostavno ako se oblik djetetove glave promatra odozgo (9). Djecu bi trebalo promotriti srijeda, straga i iz verteks-položaja. Za početak dijete se okrenuto naprijed položi na krilo roditelja, a liječnik ocjenjuje asimetriju prednjeg dijela glave. Tako se može kritički procijeniti naginjanje i zakretanje glave, zatim čelo, orbite, srednji dio lica i mandibule (1).

Strategija terapije počinje prevencijom. Stručnjaci koji pružaju primarnu zdravstvenu zaštitu novorođenčadi moraju podučiti roditelje kako mogu smanjiti opasnost od nastanka deformacijske plagiocefalije. Ona djeca kod kojih konzervativna terapija nema uspjeha - a imaju blage inicijalne do opsežne deformitete te još i anteriorne kraniofacijalne deformitete - kandidati su za eksternu kranioplastiku (1). Kako bi se deformiteti ispravili, mogu se izabrati različite kirurške terapije. To su operacije od trakaste kraniookdomije do okcipitalne transpozicije ili formalne kraniofacijalne rekonstrukcije (9).

U ovom radu opisan je slučaj DP-a kod djeteta s lijevostranom facijalnom asimetrijom. Naveden je i postupak terapije.

### Prikaz slučaja

Pacijent je devetomjesečno dijete koje je došlo na Maksofacijalni odjel bolnice Antonio Targino (HAT) u gradu Campini Grande u Brazilu. Majka je kao glavni razlog dolaska na konzultaciju navela prirodenu, sve izraženiju, asimetriju lijeve strane lica. Dijete u anamnezi nije imalo teških poremećaja i bilo je za svoju dob na primjerenom neuropsihomotornom stupnju razvoja. U obitelji nije bilo sličnih slučajeva.

Na kliničkom pregledu uočena je lijevostrana asimetrija i hipoplazija u srednjoj trećini lica te okularna i nostralna asimetrija, (Slika 1.).

Dijagnoza DP-a je potvrđena kliničkim pregledom i radiografski (Slika 2.). Pacijent je premješten na Neurokirurški odjel, a preporučena terapija uključivala je kraniostenozu i lijevostranu osteotomiju.

Pod općom anestezijom i orotrahealnom intubacijom bila je obavljena bikoronalna incizija, a bilateralni suprapariostealni flap podignut sve do lateralnog zida orbite. Nakon toga je bila poduzeta osteotomija frontoparietalne, frontonazalne i fronto-zigomatične suture na lijevoj strani kako bi se stvorile nove zone rasta. Koštani graft je bio postavljen na lijevi gornji orbitalni zid kako se smanjio deformitet nastao zbog plagiocefalije. Kada su stvorene buduće zone rasta, bila je repositionirana i fiksirana frontalna kost, perios je reponiran, a bikoronarni flap vraćen. Nakon toga je rana bila zašivena.

U postoperativnom razdoblju nije bilo komplikacija i dijete se oporavilo bez ikakvih neuroloških problema. Nakon 90 dana vidjelo se znatno poboljšanje facijalne asimetrije (Slika 3.). Pacijent je pod stalnom kontrolom neurologa i napredak se kontrolira periodično.

of DP below the age of 6 months is around 10% for occipital plagiocephaly and around 5% for frontal plagiocephaly (5). A male predilection has been reported (6,7), with predominance of right-sided unilateral cases (8).

DP can be diagnosed quickly and easily if the child's head shape is observed from above as part of the standard well-baby examinations (9). The infant should be observed from anterior, posterior and vertex positions. Initially, the infant is placed in the parental lap facing forward, and the examiner evaluates the anterior craniofacial skeleton for symmetry. In this view, head tilt and twist, as well as the forehead, orbits, midface, and mandible, are critically assessed (1).

Treatment strategies begin with prevention. Primary care providers for newborns are instrumental in educating new parents about methods of reducing the risk of deformational plagiocephaly. Those infants who fail conservative management, present with initial moderate to severe deformities or have concomitant anterior craniofacial deformities are candidates for external cranioplasty (1). Several types of surgical procedures can be used to correct the deformity. These operations range from a strip craniectomy to occipital transposition or formal craniofacial reconstruction (9).

This paper presents a case of DP in an infant who presented left-sided facial asymmetry. The treatment approach is described.

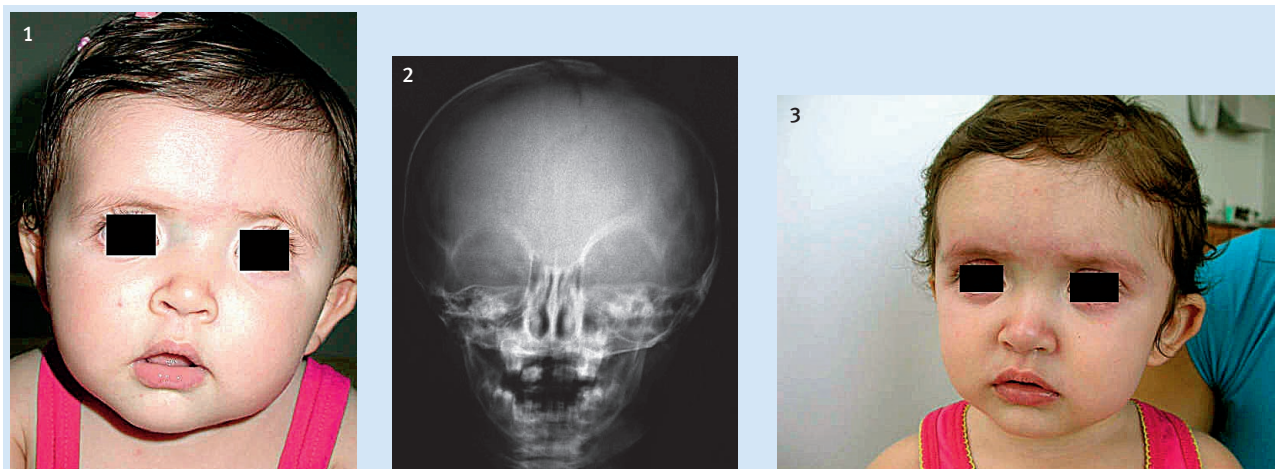
### Case Report

A 9-month-old female patient was brought to the Oral and Maxillofacial Surgery Service of the Hospital Antonio Targino (HAT), in the city of Campina Grande, PB, Brazil. The mother reported that the main reason for the consultation was the inborn asymmetry of the left side of the face, which was worsening with time. The child had no history of severe morbidity and presented an adequate neuropsychomotor development. There were no similar cases in the family.

At physical examination, it was observed the presence of left-sided asymmetry and hypoplasia in the middle third of the face as well as ocular and nostril asymmetry. (Figure 1) and the diagnosis of DP was confirmed radiographically (Figure 2). The patient was referred to the Neurosurgery Service and the proposed treatment plan included craniostenosis and left orbital osteotomy.

Under general anesthesia with orotracheal intubation, a bicoronal incision was done followed by bilateral suprapariosteal flap elevation up to the orbital lateral wall. Next, osteotomy of the frontoparietal, frontonasal and frontal-zygomatic sutures on the left side was done to create new zones of bone growth. A bone graft was placed juxtaposed to the left superior orbital wall to reduce the deformity caused by the plagiocephaly. Once the future bone growth zones were recreated, the frontal bone was repositioned and fixed, the periosteum was reattached and the bicoronal flap was returned to its position and the wound was sutured.

The immediate postoperative period was uneventful and the child recovered well from surgery without signs of neurological problems. After 90 days, a significant improvement of the facial asymmetry was observed (Figure 3). The patient is under continuous neurological follow up and case progression has been monitored periodically.



Slika 1. Frontalni pogled upućuje na hemi-facijalnu asimetriju

Figure 1 Frontal view showing the presence of left hemi-facial asymmetry.

Slika 2. AP-radiogram glave - vidljiva je povećana orbita i nedostatak fronto-zigomatične suture

Figure 2 Anteroposterior skull radiograph. Presence of enlarged orbit and absence of frontal-zygomatic suture.

Slika 3. Frontalni pogled 90 dana nakon operacije pokazuje znatno poboljšanje facijalne asimetrije

Figure 3 Frontal view at 90 days postoperatively, showing a significant improvement of the facial asymmetry.

## Rasprava

Pozicijska plagiocefalija (ponekad zvana i deformacijska ili ne-sinostolička) stanje je koje karakteriziraju promjene u obliku i simetriji glave. U većini slučajeva roditelji ili rodbina prvi kod djece uoče kraniofacijalnu asimetriju.

Premda djeca s lambdoidnom kraniosinostozom i DP-om imaju okcipitalno izravnavanje, razlikuje se vrijeme prvog prepoznavanja. Lambdoidna kraniosinostozna prepoznaje se kod čeda odmah nakon rođenja te se može postnatalno nastaviti s rastom djeteta. No, za postavljanje dijagnoze vrlo je važno točno promatranje tijekom obvezatnih redovitih pregleda. Dijete bi se trebalo promatrati s prednje i stražnje strane i iz verteks-položaja (1). Ako je dijagnoza upitna, liječnik može predložiti i kompjutorsku tomografiju s koštanim prozorima (9).

Vrste terapije za deformacijsku plagiocefaliju sljedeće su: neinterventni konzervativni pristup, pozicioniranje glave, terapija kacigom, kirurški zahvat, ili bilo koja kombinacija od navedenih načina liječenja (10). U prikazanom slučaju, terapija je uključivala kraniosinostozu i ljevostranu orbitalnu osteotomiju, jer ta kirurška metoda omogućuje stvaranje novih zona koštanoga rasta.

Perzistentna okcipitalna asimetrija može nastati zbog preuranog srašćavanja sutura, točnije lambdoidne suture (kraniosinostozna), sindroma kraniofacijalne sinostoze, metaboličkih poremećaja, frakture lubanje s utiskivanjem, povećanog intrakranijalnog volumena (hidrocefalus) i smanjenoga intrakranijalnog volumena (mikrocefalus) (11).

Još i danas ima nesuglasica u vezi s pitanjem ima li DP potencijalne fizičke posljedice. Neki autori upozoravaju da dugotrajne kraniofacijalne promjene mogu utjecati na funkciju čeljusti i okluzalne odnose, te na vizualne i neurološke poremećaje (1). U prikazanom slučaju pacijent nije imao takve posljedice.

Pedijatri imaju jedinstvenu mogućnost - oni mogu smanjiti broj pacijenata ranim pregledima, određivanjem rizič-

## Discussion

Positional plagiocephaly (sometimes referred to as deformational plagiocephaly or non-synostotic plagiocephaly) is a condition characterized by changes in skull shape and symmetry. In most cases, parents or family members are the first to notice the presence of craniofacial asymmetry in the children.

Although infants with lambdoid craniosynostosis and DP both have occipital flattening, the time of first recognition tends to differ. Infants with lambdoid craniosynostosis have recognized asymmetry at birth, which may progress as the child grows postnatally. Accurate observation during well-baby examinations is therefore the key to the diagnosis. The infant should be observed from anterior, posterior and vertex positions (1). When, however, the diagnosis is questionable, a computed tomography scan with bone windows can be used (9).

The treatment modalities for deformational plagiocephaly include: nonintervention, head positioning, helmet therapy, surgery, or any combination of these (10). In the present case, craniostenosis and left orbital osteotomy were the treatment of choice because these surgical procedures allow the creation of new bone growth zones. Persistent occipital asymmetry may be caused by premature fusion of skull sutures, particularly the lambdoid suture (craniosynostosis), craniofacial synostosis syndromes, metabolic bone disorders, depressed skull fractures, excessive intracranial volume (hydrocephalus) and diminished intracranial volume (microcephalus) (11).

Currently, controversy remains on the question of whether DP has any potential physiologic sequelae. Some authors have warned about long-lasting craniofacial changes affecting jaw function and occlusal relationships, visual disturbances and neurological disorders (1). In the present case, the patient did not present any of these sequelae.

Pediatricians have a unique opportunity to reduce the number of affected patients by early screening, by identifying patients at risk, and by educating parents about the im-

nih pacijenata i obavještanjem roditelja o tome koliko je važno okretati novorođenčad te im pod nadzorom omogućiti i spavanje na trbuhu (9).

Prevenција DP-a zahtijeva ranu intervenciju, jer se tako zapravo izbjegava trajna deformacija i fizičke posljedice poput tzv. "glave čudnog izgleda". Zato se edukacija roditelja i njegovatelja treba usredotočiti na dva područja - prvo je rano postavljanje dijagnoze što čini terapiju učinkovitijom zbog plastičnosti kosti glave novorođenčadi, a drugo je sama terapija (11).

Dijete koje sa šest mjeseci stalno spava u istom položaju i razvila mu se deformacija glave, u velikoj je opasnosti jer se asimetrija ne može "sama ispraviti" nego će se pogoršavati, što može završiti trajnim kraniofacijalnim deformacijama (1).

### Zaključak

Pozicijska plagiocefalija je deformacija glave obično kod djece do jedne godine. Postavljanje dijagnoze pretežno je kliničko, ali je i radiološko ispitivanje važno za potvrđivanje deformiteta i kao pomoć u kirurškom planiranju. Terapija ovisi o težini slučaja, a uključuje različita rješenja - od savjetovanja roditelja do kirurške indikacije.

portance of rotating infants and providing supervised tummy time (9).

Prevention of permanent DP requires early intervention. Early intervention actually avoids permanent deformity with the resultant psychosocial consequences of the "funny looking head." Therefore, the education of parents and caregivers should be focused on two areas. The first is early diagnosis, which makes early intervention more effective due to the plastic nature of the neonatal cranium. The second is the intervention itself (11).

The infant who at 6 months of life remains in a persistent sleep position and has developed craniofacial asymmetry is at significant risk for not "self-correcting" and for experiencing progressive asymmetry that may result in permanent craniofacial deformities (1).

### Conclusion

Positional plagiocephaly is a cranial deformity commonly found in children under one year of age. The diagnosis is predominantly clinical, but the radiographic examination is important to confirm the deformity and aid the surgical planning. The treatment is directly related to case severity, involving a number of issues that range from parental education to surgical indication.

#### Abstract

Plagiocephaly is a term commonly used to describe congenital forehead asymmetry. Frontal plagiocephaly has been shown to occur in approximately 5% of patients, mostly males, with predominance of right-sided unilateral cases. The diagnosis is usually done at birth or within the first month of life. This paper reports a case of a 9-month old infant female with deformational plagiocephaly who presented left-sided facial asymmetry. The proposed treatment plan included craniostenosis and left orbital osteotomy. The creation of new bone growth zones produced a significant improvement of facial asymmetry.

Received: August 16, 2009

Accepted: February 16, 2010

#### Address for correspondence

Prof. Dr. Alessandro Leite Cavalcanti  
Avenida Manoel Moraes, 471/802  
- Manaíra  
58038-230 João Pessoa, PB, Brasil  
Phone: +55 83 3315-3326  
dralessandro@ibest.com.br

#### Key words

Plagiocephaly, Nonsynostotic; Infant; Craniotomy

### References

1. Losee JE, Mason AC. Deformational plagiocephaly: diagnosis, prevention, and treatment. *Clin Plast Surg.* 2005 Jan;32(1):53-64.
2. Plank LH, Giavedoni B, Lombardo JR, Geil MD, Reisner A. Comparison of infant head shape changes in deformational plagiocephaly following treatment with a cranial remolding orthosis using a noninvasive laser shape digitizer. *J Craniofac Surg.* 2006 Nov;17(6):1084-91.
3. van Vlimmeren LA, Takken T, van Adrichem LN, van der Graaf Y, Helders PJ, Engelbert RH. Plagiocephalometry: a non-invasive method to quantify asymmetry of the skull; a reliability study. *Eur J Pediatr.* 2006 Mar;165(3):149-57.
4. Hansen M, Mulliken JB. Frontal plagiocephaly. Diagnosis and treatment. *Clin Plast Surg.* 1994 Oct;21(4):543-53.
5. Boere-Boonekamp MM, van der Linden-Kuiper LT LT. Positional preference: prevalence in infants and follow-up after two years. *Pediatrics.* 2001 Feb;107(2):339-43.
6. Mulliken JB, Vander Woude DL, Hansen M, LaBrie RA, Scott RM. Analysis of posterior plagiocephaly: deformational versus synostotic. *Plast Reconstr Surg.* 1999 Feb;103(2):371-80.
7. McKinney CM, Cunningham ML, Holt VL, Leroux B, Starr JR. Characteristics of 2733 cases diagnosed with deformational plagiocephaly and changes in risk factors over time. *Cleft Palate Craniofac J.* 2008 Mar;45(2):208-16.
8. Pople IK, Sanford RA, Muhlbauer MS. Clinical presentation and management of 100 infants with occipital plagiocephaly. *Pediatr Neurosurg.* 1996 Jul;25(1):1-6.
9. Littlefield TR, Reiff JL, Reikate HL. Diagnosis and management of deformational plagiocephaly. *BNI Quarterly* 2001;17(4):18-25.
10. Teichgraber JF, Ault JK, Baumgartner J, Waller A, Messersmith M, Gateño J, et al. Deformational posterior plagiocephaly: diagnosis and treatment. *Cleft Palate Craniofac J.* 2002 Nov;39(6):582-6.
11. Morrison CS, Chariker M. Positional plagiocephaly: pathogenesis, diagnosis, and management. *J Ky Med Assoc.* 2006 Apr;104(4):136-40.