

Ana Kotarac Knežević¹, Goran Knežević², Berislav Perić², Jakša Grgurević²

Marsupijalizacija u liječenju čeljusnih cista

Marsupialization in the Treatment of Jaw Cysts

¹ Zavod za oralnu kirurgiju Stomatološkog fakultet Sveučilišta u Zagrebu
Department of Oral Surgery, School of Dental Medicine, University of Zagreb² Klinički zavod za oralnu kirurgiju Kliničke bolnice Dubrava u Zagrebu
Clinical Department of Oral Surgery, University Hospital Dubrava

Sažetak

U radu je postavljeno pitanje vrijednosti marsupijalizacije kao metode liječenja čeljusnih cista i cističnih odontogenih tumora. Postupak je obavljen retrospektivnom raščlambom uzoraka od 71 pacijenta obrađenog u dvanestogodišnjemu razoblju u Kliničkom zavodu za oralnu kirurgiju i u Klinici za kirurgiju čeljusti i lica Kliničke bolnice Dubrava u Zagrebu. Među uzorcima je bila 61 odontogena cista (85,92 %) – od kojih 14 (19,72 %) odontogenih keratocista i sedam (9,86 %) njihovih recidiva. Radikalarnih i folikularnih odontogenih cista bilo je ukupno 39 (54,93 %), zatim slijedi šest traumatskih koštanih šupljina – "cista" (8,45 %), jedan odontogeni tumor (1,41 %), jedan gigantocelularni centralni granulom (1,41 %), jedan recidiv gigantocelularnog granuloma (1,41 %) i jedan centralni kavernozi hemangiomi (1,41 %). Tvorbe su bile liječene svim poznatim kirurškim postupcima, a marsupijalizaciji je bilo podvrgnuto deset pacijenata – tri (9,68 %) s cistama promjera od 3 do 6 centimetara te šest (22,22 %) s cistama većima od šest centimetara. Riječ je bila o odontogenim keratocistama ili njihovim recidivima te o po jednom slučaju radikalne i folikularne ciste čeljusti. Rezultati su pokazali da se marsupijalizacijom vidljivo smanjuje koštana šupljina u svim tako liječenim slučajevima te da ju je moguće primijeniti kao konačan kirurški postupak kojim se mogu potpuno izliječiti odontogene keratociste ili druge odontogene ciste čeljusti. No, kako su rezultati preliminarni, postupak ipak treba primjenjivati racionalno.

Zaprimljen: 28 kolovoza 2009

Prihvaćen: 8. veljače 2010.

Adresa za dopisivanje

Ana Kotarac Knežević
Sveučilište u Zagrebu
Stomatološki fakultet
Zavod za oralnu kirurgiju,
Gundulićeva 5, 10 000 Zagreb
Tel: +385 (0)1 4802 111
Fax: +385 (0)1 4802 159
kotarac@sfzg.hr

Ključne riječi

marsupijelizacija, ciste, čeljusne

Uvod

Odontogene patološke promjene, a posebice čeljusne ciste, stvaraju u čeljustima koštane šupljine različitih veličina. Kirurško liječenje takvih promjena ovisi o veličini i lokalizaciji. U literaturi i u oralnokirurškoj praksi prevladavala su stajališta da sve male čeljusne ciste, tj. one do promjera najviše tri centimetra - bez obzira na lokalizaciju - treba liječiti metodom Partsch II ili izljuštenjem cistične čahure, a koštani defekt prepustiti cijeljenju organizacijom krvnoga ugruška (1,2). Velike čeljusne ciste u donjoj čeljusti liječene su marsupijalizacijom ili metodom Partsch I, jer bi se organizacija krvnoga ugruška - u slučaju da su liječene metodom Partsch II - komplicirala infekcijom krvnoga ugruška, raspadom rane i sekundarnim cijeljenjem. Spajanjem cistične šupljine s usnom šupljinom u postupku marsupijalizacije očekivalo se da će se tvorba smanjiti zbog toga što čahura više nije bila stimulirana cističnom tekućinom. To je pretpostavljalo i novo stvaranje kosti na mjestu cističnog defekta. Sličan se postupak ponekad primjenjivao i u liječenju velikih ameloblastoma čeljusti. Na taj se način željelo izbjeći veće poslijeoperativne defekte, ponekad i mutilaciju čeljusti te sačuvati sve prije zahvata vitalne zube u neposrednoj blizini tvorbe. Za pacijenta je zahvat bio ugodniji, ali je poslijeoperacijski tijek nešto neugodniji, jer traži više kliničkih i radioloških

Introduction

Odontogenic pathological lesions, particularly jaw cysts, create bone cavities in the jaws of various size. Surgical treatment of such lesions depends on their size and localisation. In the literature and oral surgical practice the opinion has been that all small jaw cysts, i.e. those up to a diameter of 3 cm, regardless of their localisation, should be treated by the Partsch II method or by scaling of the cystic shell, and that the bone defect should be left to healing by organisation of a blood clot (1,2). Large jaw cysts in the mandible are treated by the method of marsupialization or Partsch I method, because organisation of a blood clot, in the case that larger cysts are treated by the Partsch II method, would be complicated by infection of the blood clot, decomposition of the wound and secondary healing. By joining the cystic cavity with the oral cavity by the method of marsupialization it was anticipated that the formation would become smaller, due to the fact that there was no longer stimulation of the capsule by cystic fluid. This presumed the new formation of bone at the site of the cystic defect. A similar method was occasionally also used in the treatment of large ameloblastomas of the jaw. The reason for using this method was to avoid a larger post-operative defect, occasional mutilation of the jaw and to preserve the vitality of all the teeth in the immediate vicinity of

kontrola, brušenje i prilagodbu opturatora, a komunikacija s usnom šupljinom - unatoč opturatoru - dovodi do zadržavanja hrane u šupljini, pa ju je potrebno redovito čistiti, jer uzrokuje neugodan zadah iz usta. U gornjoj čeljusti su metode liječenja za velike rinološke ciste bile i ostale uobičajene. Riječ je o spajanju koštane šupljine zaostale nakon izljuštenja ciste sa susjednim šupljinama - s maksilarnim sinusom ili maksilarnim sinusom i nosom.

Tijekom godina razvili su se i drugi načini liječenja velikih cista donje čeljusti. Danas postoje dvofazni načini liječenja, zatim kombinacije metode Partsch II s uporabom autoloških, heteroloških ili aloplastičnih koštanih nadomjestaka ili s dekortikacijom ili resekcijom jedne čeljusne stijenke ili s primjenom trajne poslijeoperativne sukcije sa svrhom da se pacijentovo liječenje završi nakon prvoga kirurškog zahvata i da mu se što prije omogući uključiti se u svakodnevni život (3,4,5). Tako je danas metoda Partsch II, na početku namijenjena isključivo liječenju malih cista, osim u iznimnim slučajevima, postala - uz spomenute modifikacije - univerzalan način liječenja svih čeljusnih cista (6,7).

Svrha istraživanja

Svrha istraživanja bila je objektivizirati vrijednost marsupijalizacije u liječenju čeljusnih cista i cističnih odontogenih tumora kao jedine metode liječenja te usporediti rezultate s rezultatima liječenja iste vrste patoloških promjena tretiranih isključivo metodom Partsch II ili njezinim inačicama. Postupak je posebice bio planiran za liječenje patoloških promjena čeljusti sklonih recidivima, a u skladu s novim klasifikacijama prema kojima su svrstane među tumorske tvorbe lokalno invazivnih karakteristika. To se odnosilo na odontogene keratociste (OKC) koje se od 2003. godine nazivaju keratocističnim odontogenim tumorima (KCOT) (8.).

Ispitanici i postupak

Postupak je bio proveden na kliničkom uzorku od 71 pacijenta, a liječeni su u Klinici za kirurgiju čeljusti i lica i u Kliničkome zavodu za oralnu kirurgiju Kliničke bolnice Dubrava u Zagrebu zbog patoloških promjena koje su u čeljustima stvorile velike koštane šupljine.

Primjenjivale su se sve u uvodu spomenute metode kirurškoga liječenja, a izbor je ovisio o prosudbi operatera o najboljem rješenju te o pacijentovu pristanku na predloženi postupak.

Svi su se podaci o pacijentima unosili u već pripremljeni upitni listić koji je sadržavao opće podatke o pacijentu, vrsti i lokalizaciji promjene, trajanju bolesti, veličini koštane šupljine u centimetrima, radiološki nalaz i provedeni postupak, radiološke značajke cijeljenja koštanog defekta do potpunog izliječenja te podatke o patohistološkoj dijagnozi od-

the formation, which prior to the operation had been vital. For the patient the operation was more acceptable, although the postoperative course was unpleasant as it requires several clinical and radiographic check-ups, grinding and adaptation of the obturator, and communication with the oral cavity, in spite of the obturator, leads to the retention of food in the cavity, which has to be regularly cleaned as it causes an unpleasant odour from the mouth (halitosis).

For large cysts in the maxilla rhinological methods have always been the usual methods of treatment, i.e. joining of the bone cavities remaining after scaling the cyst with adjacent cavities, maxillary sinus or maxillary sinus and nose.

Over time other methods of treatment for large mandibular cysts have been developed. Two-stage methods of treatment have been developed, a combination of the Partsch II method with the use of autologous, heterologous or alloplastic bone replacements, or with decortication or resection of one wall of the jaw or with application of permanent postoperative suction, with the aim of finalizing the patient's treatment after the initial surgical operation and in order to enable his return to everyday life as quickly as possible (3,4,5). Thus today the Partsch II method, which was intended exclusively for the treatment of small cysts, has become, except in rare cases, with the above modification, the universal method for treatment of all jaw cysts (6,7).

Aim of the Investigation

The aim of the investigation was to analyze the value of marsupialization in the treatment of jaw cysts and cystic odontogenic tumours as the only method of treatment and to compare the results achieved with the results of treatment of the same type of pathological lesions treated by the Partsch II method as an exclusive method or with its variations. The procedure was specially planned for the treatment of pathological lesions of the jaws which have a tendency to recur and which in accordance with the new classifications are classified among tumour formations of local invasive characteristics, which includes odontogenic keratocysts (OKC) which since 2003 have been known as keratocystic odontogenic tumours (KCOT) (8).

Subjects and Methods

The method was performed on a clinical sample of 71 patients, treated in the Clinic of Maxillofacial Surgery and the Clinical Department of Oral Surgery of the University Hospital Dubrava for pathological lesions which had created large bone cavities in the jaws.

All the aforementioned methods of surgical treatment mentioned in the Introduction were applied, and the choice of surgical method depended on the judgement of the operator regarding the best surgical solution and on the patient's agreement to the suggested operation.

All data on the patients were entered into a specially prepared questionnaire containing general data on the patient, type and localization of the lesion, duration of the disease, size of the bone cavity in centimeters, radiographic finding and operation performed, and on the radiographic signs of

govarajuće promjene. Dokumentaciju su, osim podataka iz upitnog listića, činile i rendgenske snimke čeljusti prije provedenoga kirurškog zahvata i poslije njega, te nakon četiri, šest, osam ili više mjeseci, sve do radioloških znakova potpune obnove kosti.

Rezultati

U uzorku od 71 pacijenta bilo je 48 muškaraca (67,61%) i 23 žene (32,39%). Raspon godina bio je od 1 do 69, a prosječna dob iznosila je 39,79 godina. Odnos pojavnosti patoloških promjena u donjoj čeljusti prema onima u gornjoj bio je 56 : 15 ili 3,71 : 1.

Među patološkim promjenama čeljusti bila je 61 odontogena cista (85,92%), od čega je odontogenih keratocista bilo 14 (19,72%), a njihovih recidiva sedam (9,86%). Radikularnih i folikularnih odontogenih cista ukupno je bilo 39 (54,93%) i jedan recidiv odontogene ciste. Kako je ovo istraživanje obavljeno u sklopu projekta koji se bavio postupcima liječenja velikih koštanih šupljina čeljusti različitih etiologija, u uzorku je također nađeno šest traumatskih koštanih šupljina (8,45%), jedan odontogeni tumor (1,41%), jedan gigantocelularni centralni granulom (1,41%), jedan recidiv gigantocelularnog granuloma (1,41%) i jedan centralni cavernozni hemangiom (1,41%).

U većini slučajeva u liječenju je bila primijenjena metoda Partsch II, i to kod 33 (46,48%) pacijenta. Kao samostalna, ili uz potporu intraoralne poslijeoperativne sukcije, primijenjena je bila u 17 slučajeva, a u 16 slučajeva se kombinirala s punjenjem koštanog defekta granulatom trikalcijeva fosfata, a uz potporu dekortikacije čeljusti - često uz intraoralnu sukciju u 25 slučajeva (Tablica 1.).

Metoda Partsch II, kao isključivi način liječenja, bila je primijenjena u slučajevima patoloških promjena čeljusti promjera do 3 centimetra, a kombinacije s intraoralnom poslijeoperativnom sukcijom s dekortikacijom čeljusti ili bez nje, primijenjene su bile pretežito kod većih patoloških promjena čeljusti, dakle, onih promjera od tri do šest centimetara ili većih od šest centimetara.

O marsupijalizaciji se odlučivalo na temelju radiološkog nalaza i karakteristika rendgenograma koji su upućivali na tu mogućnost (KCOT/OKC-a), ali i na osnovi veličine i loka-

healing of the bone defect up to complete healing, and also data on the histopathological diagnosis of the relevant lesions. Apart from data in the questionnaire, documentation included X-rays of the jaws prior to and after the surgical operation and after 4, 6, 8 or more months up to radiographic signs of complete bone regeneration.

Results

The sample of 71 patients included 48 males (67.61%) and 23 females (32.39%). Age ranged from one to 69 years, and the average age was 39.79 years. The relation between the occurrence of pathological lesions in the mandible and those in the maxilla amounted to 56:15, or 3.71:1.

Among the pathological lesions of the jaws were 61 odontogenic cysts (85.92%), of which 14 (19.72%) were odontogenic keratocysts, and 7 (9.86%) recurrences of odontogenic keratocysts. Radicular and follicular odontogenic cysts amounted to 39 (54.93%) and one recurrence of an odontogenic cyst. As the investigation was carried out within the framework of a project on the methods of treating large bone cavities of the jaws of different aetiology, 6 traumatic bone cavities (8.45%), one odontogenic tumour (1.4%), one gigantocellular central granuloma (1.4%), one recurrence of a gigantocellular granuloma (1.41%) and one central cavernous hemangioma (1.41%) were also found in the sample.

In the majority of cases Partsch II method was applied in the treatment of 33 (46.48%) cases. The method was carried out independently or with the support of intraoral postoperative suction in 17 cases, in 16 cases it was combined with filling of the bone defect by granulate tricalcium phosphate, and with the support of decortication of the jaws, frequently with the application of intraoral suction in 25 cases (Table 1).

As an exclusive method of treatment Partsch II method was applied in cases of pathological lesions of the jaws up to 3 cm in diameter. A combination of Partsch II method with intraoral postoperative suction with or without decortication of the jaws was applied mainly in cases of large pathological lesions of the jaws, i.e. those 3-6 cm diameters or larger than 6 centimeters.

Marsupialization was decided on the basis of the radiographic finding and characteristic X-ray which indicated the

Tablica 1. Raspodjela uzoraka prema veličini patološke promjene i vrsti provedenog kirurškog zahvata
Table 1 Distribution of the sample according to the size of the pathological lesion and type of surgical intervention performed

	<3cm		3-6cm		>6cm		UKUPNO • TOTAL	
	N	%	N	%	N	%	N	%
PARTSCH II + SUKCIJA ILI + ALOPLASTIČNA IMPLANTACIJA • PARTSCH II + SUCTION OR + ALLOPLASTIC IMPLANTATION	13	100.00	16	51.61	4	14.81	33	46.48
PARTSCH II + DEKORTIKACIJA + SUKCIJA • PARTSCH II + DECORTICATION + SUCTION	0	0	11	35.48	14	51.85	25	35.21
MARSUPIJALIZACIJA • MARSUPIALIZATION	0	0	3	9.68	6	22.22	9	12.68
CALDWELL- LUC ILI DRUGA RINOLOŠKA METODA • CALDWELL- LUC OR OTHER RHINOLOGICAL METHOD	0	0	0	0	3	11.11	3	4.23
PARTSCH II + ANTROTOMIA • PARTSCH II + ANTHROTOMIA	0	0	1	3.22	0	0	1	1.41
UKUPNO • TOTAL	13	100.00	31	100.00	27	100.00	71	100.00

lizacije promjene. Uglavnom je to bilo pitanje preglednosti operacijskog područja i mogućnosti da se prvi zahvat možda ne bi mogao izvesti dovoljno pregledno i pomno te namjera da se što manjim zahvatom sačuva vitalnost zuba i izbjegnu eventualni recidivi. Metoda je bila odabrana za devet pacijenata, što u ovom prikazu iznosi 12,68% , a u šest slučajeva patološka je promjena bila veća od 6 centimetara. U uzorku je bilo sedam slučajeva KCOT/OKC-a, od kojih jedan recidiv nakon 40 godina i po jedna radikularna i folikularna cista. One su uzrokovale veće defekte čeljusti, a zubi su pritom bili vitalni, pa je u oba slučaja bila obavljena marsupijalizacija kako bi se sačuvala vitalnost zuba i spriječio opsežniji zahvat.

Caldwell-Lucova ili druge rinološke metode bile su primijenjene kod četiri (5,63%) pacijenta.

S obzirom na korišteni kirurški zahvat ($\chi^2=6,313$; $df=8$; $p=0,612$), Chi-kvadrat test nije pokazao statistički znatne razlike u rezultatima cijeljenja.

possibility of KCOT/OKC, and also on the basis of the size and localization of the lesion. In the majority of cases the main concern was the clearness of the area of the operation and the possibility that the first operation may be impossible to perform sufficiently precisely and carefully and also the desire to retain the vitality of the teeth and avoid the possibility of recurrence by using the smallest operation possible. The method was applied in 9 patients, which in this case amounted to 12.68% of patients, of which the pathological lesion was larger than 6 cm in 6 cases. There were 7 cases in the sample of KCOT/OKC of which there was one recurrence after 40 years and one case each of a radicular and follicular cyst, which had created large jaw defects. The teeth were vital, and thus marsupialization was performed in both cases in order to preserve the vitality of the teeth and prevent the need for a more extensive operation. Caldwell Luc or other rhinological methods were applied in 4 (5.63%) of the patients.

Tablica 2. Raspodjela uzoraka prema vrsti provedenog kirurškog zahvata i rezultatima cijeljenja koštanih defekata.
Table 2 Distribution of the sample according to the type of surgical operation performed and the results of healing of the bone defects.

	Obnova kosti za 4 -6 mjeseci • Regeneration of bone in 4 -6 months		Obnova kosti za 8 – 10 mjeseci • Regeneration of bone in 8 - 10 Months		Obnova kosti za 12 i više mjeseci • Regeneration of bone in 12 and more months		Ukupno • Total	
	N	%	N	%	N	%	N	%
Partsč II kao samostalna metoda ili u kombinaciji s jednom ili objema inačicama – sukcijom ili dekortikacijom • Partsč II as an independent method or in combination with one or both variations - suction or decortication	4	21.05	16	64.00	22	81.48	42	59.15
Marsupijalizacija • Marsupialization	1	5.26	2	8.00	6	22.22	9	12.68
Partsč II + aloplastična implantacija • Partsč II + alloplastic implantation	11	57.89	5	20.00	0	0	16	22.54
Caldwell - Lucova ili druga rinološka metoda • Caldwell - Luc or other rhinological method	3	15.79	1	4.00	0	0	4	5.63
Ukupno • Total	19	100.00	25	100.00	27	100.00	71	100.00

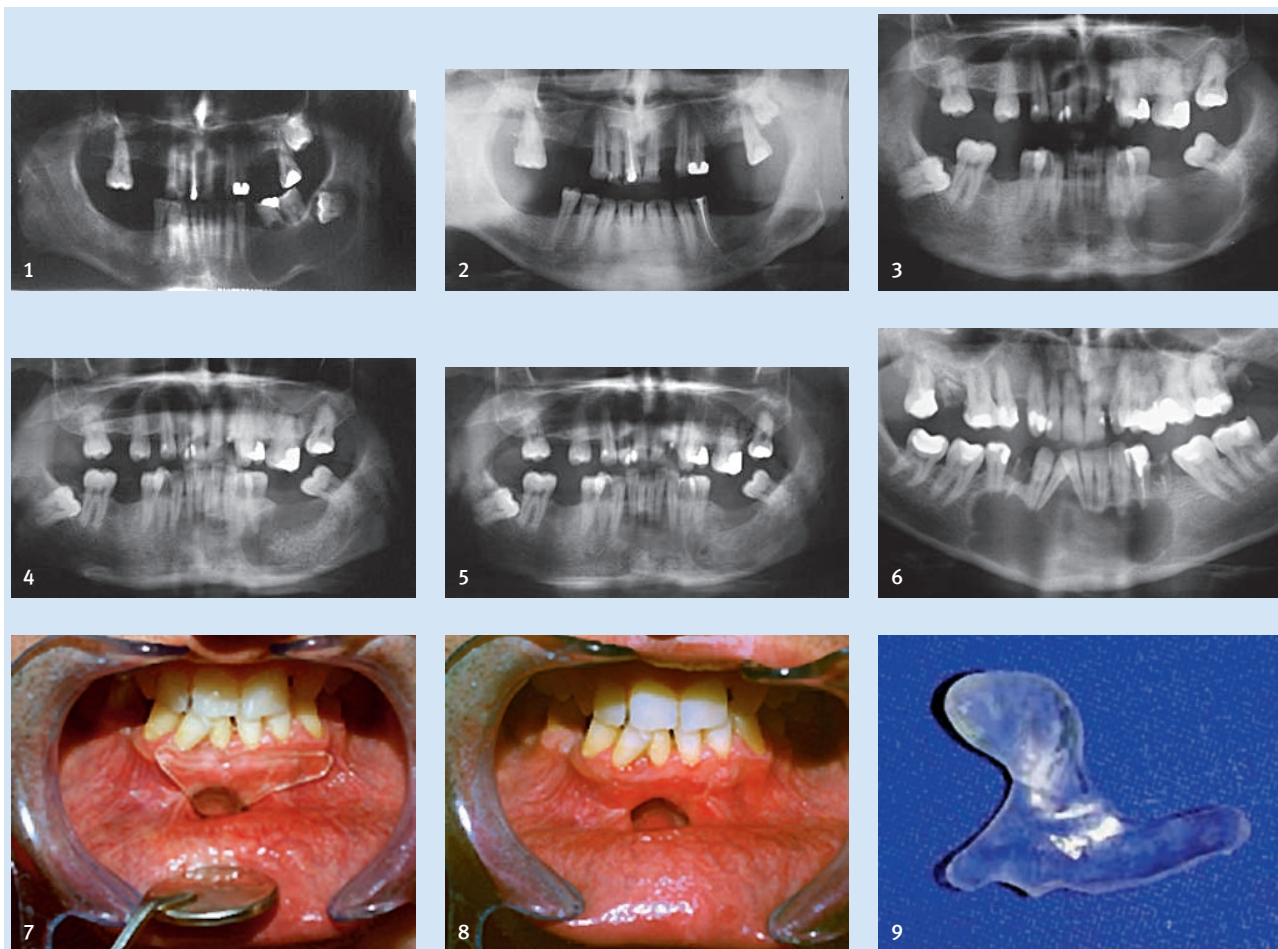
Iako nisu postojale statistički veće razlike u cijeljenju koštanih defekata nakon različitih kirurških zahvata, na Tablici 2. moguće je raščlaniti i usporediti podatke o dinamici cijeljenja koštanih defekata čeljusti u odnosu prema obavljenim zahvatima.

Metoda Partsč II odabrana je u slučajevima patoloških promjena čeljusti promjera do tri centimetra, a kombinacije s intraoralnom poslijeoperacijskom sukcijom s dekortikacijom čeljusti ili bez nje obavljene su pretežito u slučajevima većih patoloških promjena u čeljusti, dakle, onih promjera od tri do šest centimetara ili većih od šest centimetara (Slike 1. i 2.). Ukupan broj slučajeva liječenih metodom Partsč II s kombinacijama ili bez njih u opisanim je inačicama iznosio 42 (59,15%). Među patološkim promjenama liječenima tim metodom prevladavale su odontogene upalne i razvojne folikularne ciste, jedan recidiv odontogene ciste, ostale prije spomenute patološke promjene u čeljusti, ali i sedam slučajeva KCOT/OKC-a i pet recidiva KCOT/OKC-a koji su prije već bili liječeni istom metodom. U slučajevima da je njihova veličina bila manja, zahvati su bili ponovljeni prema metodi Partsč II.

Chi-square test did not show statistically significant differences in the results of healing with regard to the surgical method used ($\chi^2=6.313$; $df=8$; $p=0.612$).

Regardless of the fact that there were no statistically significant differences in healing of the bone defects after different surgical methods in Table 2 it is possible to analyse and compare data on the dynamics of healing the bone defects in the jaws with regard to the methods used.

As an exclusive method of treatment Partsč II method was applied in cases of pathological lesions of the jaws up to 3 cm in diameter, and a combination of Partsč II method with intraoral postoperative suction with or without decortication of the jaws was applied mainly in cases of larger pathological lesions of the jaws, i.e. those of 3-6 cm in diameter or those larger than 6 centimetres (Figs. 1 and 2). The total number of cases treated by the Partsč II method with or without combination with the described variations amounted to 42 (59.15%). Among the pathological lesions treated by these methods odontogenic inflammatory and developmental follicular cysts were prominent, one recurrence of



Slika 1. Nalaz folikularne ciste donje čeljusti prije zahvata - primjenjena je metoda Partsch II s trajnom poslijeoperativnom sukcijom
Figure 1 Finding of a follicular cyst of the mandible prior to the operation. Partsch II method with permanent postoperative suction was applied.

Slika 2. Rendgenski nalaz 12 mjeseci nakon zahvata pokazuje obnavljanje kosti
Figure 2 X-ray finding 12 months after the operation showing bone regeneration.

Slika 3. Primjer pacijenta s rezidualnom cistom donje čeljusti liječenom metodom Partsch II i punjenjem šupljine granulatom trikalcijeva fosfata - nalaz prije zahvata

Figure 3 Example of a patient with residual cyst of the mandible treated by the Partsch II method and filling of the cavity with granulate tricalcium phosphate. Finding prior to the operation.

Slika 4. Nalaz neposredno nakon zahvata vidljiv je kontrast granulata

Figure 4 Finding immediately after the operation. Visible contrast of granulates.

Slika 5. Nalaz sedam mjeseci nakon zahvata pokazuje obnovljenu koštanu gradnju čeljusti

Figure 5 Finding 7 months after the operation showing regenerated bone structure of the jaws.

Slika 6. KCOT/OKC u predjelu simfize donje čeljusti - svi su zubi vitalni osim 34,35, i 44 (punjeni su)

Figure 6 KCOT/OKC in the region of the mandibular symphysis. All teeth apart from 34,35 and 44 (filled) are vital.

Slike 7. i 8. Pacijent sa slike 6 nakon marsupijalizacije, s opturatorom i bez njega

Figures 7 & 8 Patient from Figure 6 after marsupialization, with and without obturator.

Slika 9. Opturator izvan pacijentovih usta

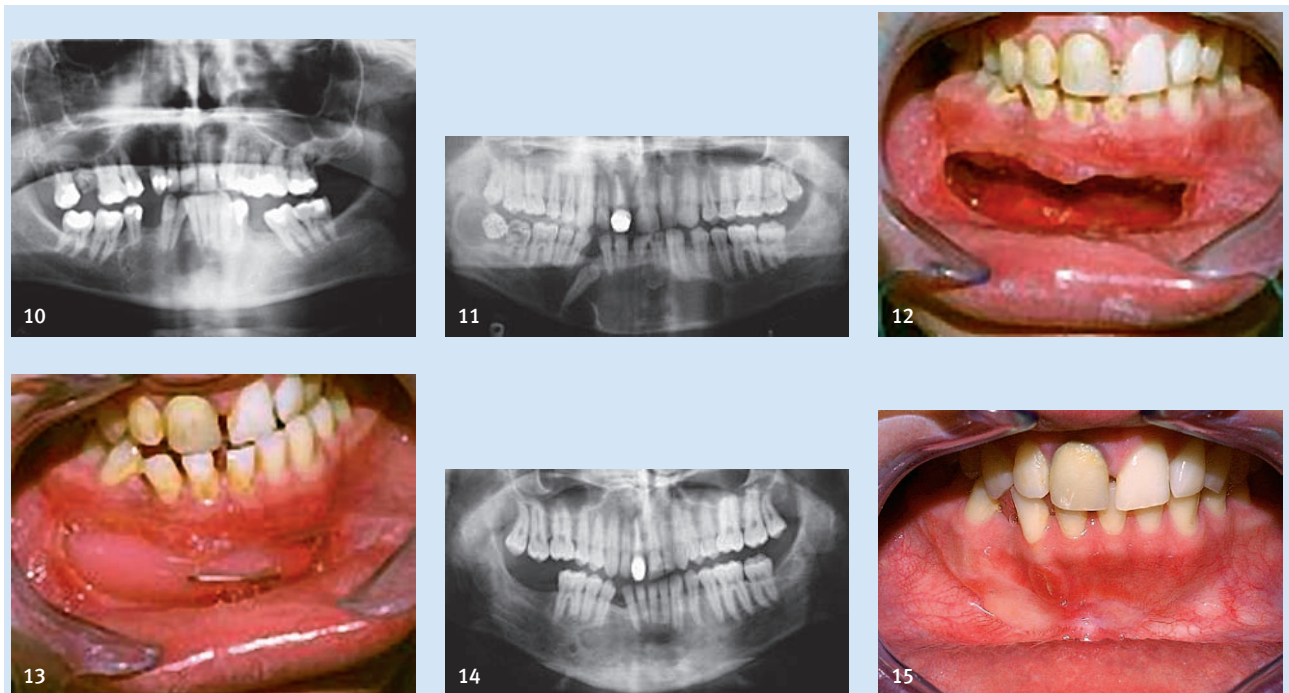
Figure 9 Obturator out of the patients mouth

Upotreba trikalcijeva fosfata u liječenju velikih koštanih šupljina čeljusti pokazala je da njihovo cijeljenje dinamički teče znatno brže (četiri do šest mjeseci) negoli ako se liječenje provodilo metodom Partsch II i trajnom poslijeoperativnom sukcijom (osam do dvanaest mjeseci), što potvrđuju i recentni radovi o toj temi (9, 10) (Slike 3.4. i 5.) .

Metoda marsupijalizacije primijenjena je bila kod devet pacijenata, liječenje je najčešće trajalo između 10 i 12 mjeseci i nije zabilježen ni jedan slučaj recidiva. Svrha primjene marsupijalizacije nije bila dobiti bržu obnovu koštanog defekta, nego spriječiti veću "žrtvu" kosti i zuba te moguće recidive, pa zbog toga - bez obzira na činjenicu da se to ne može

an odontogenic cyst, other previously mentioned pathological lesions of the jaws, and also 7 cases of KCOT/OKC and 5 cases of recurrence of KCOT/OKC which had previously been treated by the same method. In cases where their size was smaller operations according to Partsch II method were performed or repeated.

The use of tricalcium phosphate in the treatment of large bone cavities showed that healing of the cavity occurred much faster (4 to 6 months) than in cases where treatment was carried out by the Partsch II method and permanent postoperative suction (8 to 12 months), which confirms recent studies on this topic (9,10) (Figs. 3,4 & 5).



Slika 10. Rendgenski nalaz nakon godinu dana pokazuje regresiju koštanoga defekta, osim na mjestu nošenja opturatora

Figure 10 X-ray finding after one year showing regeneration of the bone defect apart from the place of the obturator.

Slika 11. Rendgenski nalaz velike folikularne ciste u predjelu simfize i druge folikularne ciste u desnom angulusu donje čeljusti

Figure 11 X-ray finding of a large follicular cyst in the region of the symphysis and other follicular cysts in the right angle of the mandible.

Slike 12. i 13. Klinički izgled pacijenta sa slike 10 nakon marsupijalizacije folikularne odontogene ciste u predjelu simfize, bez opturatora i s opturatorom

Figures 12 & 13 Clinical appearance of the patient from Figure 10 after marsupialization of the follicular odontogenic cyst in the region of the symphysis, with and without obturator.

Slike 14. i 15. Radiološki i klinički nalaz godinu dana nakon marsupijalizacije pokazuje potuno zacjeljivanje kosti - prosvjetljenje ispod sjekutića odgovara vezivnome zacjeljivanju kosti.

Figures 14 & 15 Radiographic and clinical finding one year after marsupialization showing complete healing of the bone. Translucency beneath the incisor indicates connective healing of the bone.

statistički potvrditi - postupak ima preliminarnu vrijednost u skladu s navodima iz literature (Slike 6 – 14.) .

Rasprava

Marsupijalizaciji je bilo podvrgnuto devet pacijenata - sedam je imalo odontogene keratociste ili njihove recidive, a dva ostale odontogene ciste. Vrijeme praćenja liječenih slučajeva iznosilo je od tri do pet godina nakon kirurškoga zahvata.

Nakon što je nekoliko autora dokazalo da se marsupijalizacijom KCOT/OKC-a znatno smanjio broj recidiva i nakon što su se pojavile informacije da je marsupijalizaciju (KCOT/OKC) moguće smatrati jedinim i konačnim postupkom liječenja (11,12,13,14), to je potaknulo pitanja treba li tu metodu češće primjenjivati u svakodnevnoj praksi. No, tri do pet godina nakon prvih mišljenja u korist marsupijalizacije kao konačnog postupka u liječenju (KCOT/OKC-a), u literaturi se mogu naći stajališta nekih navedenih autora koji su

The method of marsupialization was applied in 9 patients. Treatment most frequently lasted between 10 and 12 months and not one case of recurrence was recorded. The object of using the marsupialization method was not to achieve faster regeneration of the bone defect but to prevent greater sacrifice of bone and teeth and to prevent possible recurrence. Thus, regardless of the fact that this cannot be statistically confirmed, the method has preliminary value, which agrees with reports in the literature (Fig. 6 - 14).

Discussion

Marsupialization was performed in 9 patients of which 7 had odontogenic keratocysts or their recurrences, and the remaining 2 other odontogenic cysts. The treated cases were monitored for a period of 3 to 5 years after the surgical operation.

After several authors had demonstrated that marsupialization of KCOT/OKC resulted in a significant reduction in the number of recurrences, and after the appearance of information that marsupialization (KCOT/OKC) can possibly be considered the only and definitive method of treatment (11,12,13,14), the question was raised of the possibility of wider application of the method in everyday practice.

However 3-5 years after the first opinions, which favoured marsupialization as the definitive method of treat-

ublažili ili djelomice povukli svoje tvrdnje o marsupijalizaciji kao konačnome postupku u liječenju KCOT/OKC-a (15).

Svi registrirani slučajevi KCOT/OKC-a donje čeljusti iz prikazanog uzorka pokazali su da je metoda vrlo korisna i da je moguće konačno izlječenje samo tim postupkom, što potvrđuju autori koji govore o marsupijalizaciji kao o konačnome postupku koji vodi do izlječenja (14) (Slike 6 – 15.). Činjenica da su - od ukupnog broja slučajeva kod kojih je bila primijenjena metoda Partsch II - bila tri recidiva nakon liječenja recidiva ili nakon prvoga kirurškog zahvata u liječenju KCOT/OKC-a, ponovno ističe lokalno invazivne karakteristike te tvorbe i kao rješenje nameće radikalniji kirurški zahvat ili metodu marsupijalizacije.

Djelotvornost metode dokazuje činjenica da se nakon marsupijalizacije svih liječenih pacijenata, među kojima je bilo šest prvi put liječenih te jedan recidiv KCOT/OKC-a, nije pojavio ni jedan slučaj recidiva. Kako je vrijeme praćenja kliničkog uzorka razmjerno kratko, ali i na temelju novijih spoznaja o toj problematici, bilo bi pretenciozno marsupijalizaciju smatrati konačnim postupkom u liječenju velikih slučajeva KCOT/OKC-a. Dokazanu uspješnost u prikazanom uzorku treba shvatiti kao preliminarno izvješće i treba je potvrditi ili opovrgnuti nakon barem pet godina praćenja radioloških nalaza liječenih pacijenata.

Koliko je sigurno marsupijalizacijom liječiti KCOT/OKC pitanje je koje - bez obzira na preliminarnu pozitivne rezultate - treba uzeti s rezervom zbog poznatih činjenica o mogućnosti razvoja karcinoma iz epitela cistične čahure odontogenih cista, ali i iz odontogenih tumora među koje se danas ubraja KCOT/OKC. O tome i kod nas i u svijetu postoje podaci koje treba imati na umu pri izboru metode (16– 20).

Zaključak

Marsupijalizacija u liječenju KCOT/OKC-a i drugih odontogenih cista omogućuje regresiju koštanih šupljina, a prema dobivenim rezultatima i potpuno izlječenje jer šupljine posve nestaju. Postupak traje od osam do dvanaest mjeseci i nisu zabilježeni recidivi. Metoda se, bez obzira na duljinu postupka, predlaže u liječenju i prevenciji recidiva lokalnoinvazivnih cističnih promjena čeljusti odontogene etiologije kao što je KCOT/OKC-e, koji se danas - poput ameloblastoma - svrstava među odontogene tumore. No, kako su rezultati preliminarni, postupak ipak treba primjenjivati racionalno.

ment (KCOT/OKC), data appeared in the literature by some of the cited authors who modified or partially revoked their claim that marsupialization is the definitive method of treatment (KCOT/OKC) (15).

All registered cases of KCOT/OKC of the mandible in the sample presented demonstrated that the method is very useful and that definitive cure is only possible with this method, confirms the claim of authors who regard marsupialization as the definitive method which leads to cure (14) (Figs. 6-15).

The fact that of the total number of cases in which Partsch II method was applied there were three recurrences after treatment of recurrence or after the first surgical operation in the treatment of KCOT/OKC, again emphasises the local invasive characteristics of these formations and suggests the need for radical surgical operation or marsupialization method.

The fact that after marsupialization of all the cases treated, among which there were 6 treated for the first time and one case of KCOT/OKC recurrence, no case of recurrence occurred, shows the efficacy of the method.

As the duration of monitoring the clinical sample is relatively short, and on the basis of more recent knowledge of the problem, it would be pretentious to consider marsupialization the definitive method of treatment of large cases (KCOT/OKC). The success of the method in the presented sample should be considered as a preliminary report and should be confirmed or refuted after at least 5 years of monitoring the radiographic findings of treated patients.

The safety of marsupialization treatment of KCOT/OKC, regardless of the preliminary positive results, should be considered with reserve because of the well known possibility of carcinoma developing from the epithelium of the cystic capsules of odontogenic cysts, and also from odontogenic tumours, which today includes KCOT/OKC. Therefore, before choosing the method to be used relevant data should be considered (15-20).

Conclusion

Marsupialization in the treatment of KCOT/OKC and other odontogenic cysts enables regression of bone cavities, and according to the results obtained, complete cure as the cavities completely disappear. The procedure lasts from 8 to 12 months and no case of recurrence has been observed. Regardless of the duration of the procedure the method is proposed for the treatment and prevention of recurrences of local invasive cystic lesions of the jaws of odontogenic aetiology, such as KCOT/OKC, which today, like ameloblastoma, are classified as odontogenic tumours. However as the results are preliminary the procedure should be applied rationally.

Abstract

The investigation raises the question of the value of marsupialization as a method for treatment of jaw cysts and cystic odontogenic tumours. The study comprises a retrospective analysis of a sample of 71 patients treated during a twelve-year period in the Clinical Department of Oral Surgery and the Clinic of Maxillofacial Surgery of the University Hospital Dubrava. The sample consisted of 61 odontogenic cysts (85.92%), among which 14 (19.72%) were odontogenic keratocysts and 7 (9.86%) recurrences of odontogenic keratocysts. There were 39 (54.93%) radicular and follicular odontogenic cysts, 6 traumatic bone cavities "cysts" (8.45%), one odontogenic tumour (1.4%), one giant-cell central granuloma (1.41%), one recurrence of a giant-cell granuloma (1.41%) and one central cavernous hemangioma (1.41%). The formations were treated by all known surgical procedures, and marsupialization was undertaken in 9 patients of which 3 (9.68%) with cysts 3-6 cm in diameter and 6 (22.22%) with cysts larger than 6 cm. They were odontogenic keratocysts or their recurrences and one case each of a radicular and follicular jaw cyst. The results showed that marsupialization visibly reduced the bone cavity in all cases treated by this method and indicated that it could be applied as the final surgical procedure in which a complete cure is possible of odontogenic keratocysts or other odontogenic cysts of the jaws. However as the results are preliminary the procedure should be applied rationally.

Received: August 28, 2009
Accepted: February 8, 2010

Address for correspondence

Ana Kotarac Knežević
University of Zagreb
School of Dental Medicine
Department of Oral Surgery
Gundulićeva 5, Zagreb
Tel: + 385 1 4802 111
Fax: + 385 1 3802 159
kotarac@sfzg.hr

Key words

Marsupialization; Jaw Cysts; Odontogenic Tumors

References

- Miše I. Oralna kirurgija. Zagreb: JUMENA; 1983.
- Knežević G. Oralna kirurgija II dio. Zagreb: Školska knjiga; 2003.
- Grgurević J, Knežević G. Alternative u liječenju velikih cista donje čeljusti. Zbornik kratkih sažetaka 9. kongresa Udruženja stomatologa Jugoslavije, Ljubljana; 1988. p. 65.
- Grgurević J. Biphase treatment of large mandibular cysts - case presentation. *Acta Stomatol Croat.* 2004;38(4):272-3.
- Knežević G. Surgical procedures in the treatment of large osseous cavities of the jaws. *Acta Stomatol Croat.* 2004;38(4):271.
- Knežević G, Jokić D, Kotarac-Knežević A. Surgical-orthodontic treatment of development odontogenic cysts of the jaw. *Acta Stomatol Croat.* 2005;39(1):113-23.
- Brosch F. Die Cysten des Kiefer-Gesichtsbereiches. In: Häupl K, Meyer W, Schuhardt K, editors. *Zahn-Mund und Kieferheilkunde.* München Berlin: Urban und Schwarzenberg; 1957.
- Reichart PA, Philipsen HP. Odontogenic tumors and allied lesions. London: Quintessence Publishing Co.Ltd.; 2004.
- Knežević G, Rinčić M, Knežević D. Radiological evaluation of the healing of bone defects filled with tricalcium phosphate (Bioresorb) after cystectomy of the mandible. *Acta Stomatol Croat.* 2007;41(1):66-73.
- Rinčić M. The application of the pure ceramic of tricalcium phosphate -Bioresorb- in treatment of large bone defects of jaws [master's thesis]. Zagreb: School of Dental Medicine; 2008.
- Nakamura N, Mitsuyasu T, Mitsuyasu Y, Taketomi T, Higuchi Y, Ohishi M. Marsupialization for odontogenic keratocysts: long-term follow-up analysis of the effects and changes in growth characteristics. *Oral Surg Oral Med Oral Pathol Oral Radiol Endod.* 2002 Nov;94(5):543-53.
- Marker P, Brøndum N, Clausen PP, Bastian HL. Treatment of large odontogenic keratocysts by decompression and later cystectomy: a long-term follow-up and a histologic study of 23 cases. *Oral Surg Oral Med Oral Pathol Oral Radiol Endod.* 1996 Aug;82(2):122-31.
- Brøndum N, Jensen VJ. Recurrence of keratocysts and decompression treatment. A long-term follow-up of forty-four cases. *Oral Surg Oral Med Oral Pathol.* 1991 Sep;72(3):265-9.
- Pogrel MA, Jordan RC. Marsupialization as a definitive treatment for the odontogenic keratocyst. *J Oral Maxillofac Surg.* 2004 Jun;62(6):651-5.
- Pogrel MA. Decompression and marsupialization as definitive treatment for keratocysts--a partial retraction. *J Oral Maxillofac Surg.* 2007 Feb;65(2):362-3.
- Kobler P. Development of carcinoma in the radicular cyst of the maxilla. *Acta Stomatol Croat.* 1979;13:68-72.
- Macan D, Kobler P, Virag M, Bunarević A. Razvoj karcinoma iz epitelne ovojnice ciste čeljusti. Zbornik kratkih sažetaka 9. kongresa Udruženja stomatologa Jugoslavije, Ljubljana; 1988. p. 63.
- Uglešić V, Knežević P, Manojlović S. Planocellular Carcinoma in a Mandibular Cyst. *Acta Stomatol Croat.* 2001;35(4):501-6.
- Chaisuparat R, Coletti D, Kolokythas A, Ord RA, Nikitakis NG. Primary intraosseous odontogenic carcinoma arising in an odontogenic cyst or de novo: a clinicopathologic study of six new cases. *Oral Surg Oral Med Oral Pathol Oral Radiol Endod.* 2006 Feb;101(2):194-200.
- Holsinger FC, Owens JM, Raymond AK, Myers JN. Central mucoepidermoid carcinoma of the mandible: tumorigenesis within a keratocyst. *Arch Otolaryngol Head Neck Surg.* 2002 Jun;128(6):718-20.