

## Cosmetic dentistry in ancient times – a short review

• Vukovic A (1), Bajzman A (2), Zukic S (2), Secic S (3) •

1 - Department of Dental Pathology and Endodontics, Faculty of Dental Medicine Sarajevo, Bosnia and Herzegovina

2 - Department of Dental Morphology and Anthropology, Faculty of Dental Medicine Sarajevo, Bosnia and Herzegovina

3 - Department of Oral Surgery, Faculty of Dental Medicine Sarajevo, Bosnia and Herzegovina

### Address for correspondence:

Amra Vuković

Faculty of Dental Medicine

Department of Dental Pathology and Endodontics

Bolnička 4a

71000 Sarajevo

Bosnia and Herzegovina

E- mail: [avukovic@sf.unsa.ba](mailto:avukovic@sf.unsa.ba)

**Bull Int Assoc Paleodont. 2009; 3 (2):9-13.**

### Abstract

Paleodontological research has proven that some form of cosmetic dentistry existed in ancient times. Intentional dental mutilation, dental decoration and modifications on anterior teeth have been widespread occurrences in many cultures. The fact that there are various names for these phenomena indicates different interpretations of data gained from research into this type of intervention into human dentition. Although archaeological specimens of modified teeth are usually isolated and damaged, they broaden our knowledge of ancient nations and human behaviour in the past. This paper describes examples of such intervention from Southeast Asia, Africa, pre-Columbian America and Europe, as well as Phoenician and Etruscan dental art. It is interesting that different civilisations with no mutual contact and very distinct cultures have developed such similar customs. This could be considered evidence that the sense of and need for beauty lies deep within human nature.

**Keywords:** Tooth Modification; Intentional Dental Mutilation; Prehistoric Dentistry; Cosmetic Dentistry

Throughout the history of humanity, healthy teeth have represented a symbol of youth, health, beauty and strength, but they also have held other meaning. Some forms of cosmetic dentistry have been practised for thousands of years. Dental mutilation and dental decoration of anterior teeth have been documented in many cultures in the past. These were performed because for ritual-religious purposes,

aesthetic reasons, or because they represented symbol of prestige, a sign of belonging to a specific social group (1). Similar rituals have been preserved until the present. One example of this is spiritual tooth drilling (Mapandes) among Hindu youths from Bali tribes. It is a rite of passage, in this case entrance into adulthood through the symbolic act of destroying the Six soul enemies such as anger, pride, greed, etc.

Although archaeological samples of modified teeth are usually isolated and damaged, they broaden our knowledge of ancient nations and human behaviour in the past. Various forms of dental mutilation and decorations have been found in some of the earliest civilisations in China, India, Southeast Asia, Africa and North America, although best documented specimens of these activities come from pre-Columbian America.

The earliest known evidence of drilling human teeth dates from 7500–9000 years ago. Eleven drilled permanent molar crowns, from nine adults, were found in the Neolithic town of Mehrgarh in Pakistan. The holes vary in depth between 0.5 and 3.5 mm, with diameters ranging from 1.3 to 3.2 mm. Research into such findings has even allowed from the reconstruction of possible primitive tools for enamel drilling (2). The posterior location of the drilled holes caused controversy: was this performed for therapeutic or aesthetic reasons? We may never learn whether they were trying to relieve pain caused by these teeth, to make them more beautiful or to release evil spirits.

Mayan dental mutilation consisted of surface grooves, occlusal notches and/or incrustations of jade, turquoise or pyrite inlays. This practice dates from 500-900 A.D. (3,4,5). Mexican anthropologist Romero established a classification system for the great variety of mutilations. In 1965, Romero described seven basic types of intentional dental alterations, based on a collection of 1212 teeth at the Instituto Nacional de antropologia e Historia in Mexico City. The basic types are named from A to G with 5 or more subtypes, for a total of 59 different variants. This classification is based on alteration of crown contours, surface decorations, or both. Romero's tooth mutilation types from the 1970's became a reference to researchers worldwide (Figure 1). The most frequently mutilated teeth are maxillary central and lateral incisors and canines. This fact along with findings of dental modification, especially inlays, in skeletons of young individuals could be argued for decorative pattern. Whatever the reasons were for such procedures they continue to be explored (6).

There is evidence that the Mayas had practiced the implantation of shell pieces instead of missing teeth. During excavating burial sites in Honduras in 1931, archaeologists found a fragment of mandible dating from about 600 A.D. This mandible had three tooth shaped pieces of shell placed into the sockets of three missing lower incisor teeth. It is the earliest endosseous alloplastic implants discovered yet (7).

The specimen of upper incisors from Halin (Burma) provides evidence of dental decoration in Southeast Asia. According to Chinese references the "gold teeth" from Halin may date back to 7th century A.D. or later. The specimens of teeth were decorated by the insertion of several golden inlays into small perforations cut into the enamel of the upper incisors. This elegant form of cosmetic dentistry demonstrated that decorated teeth were considered objects of beauty (8).

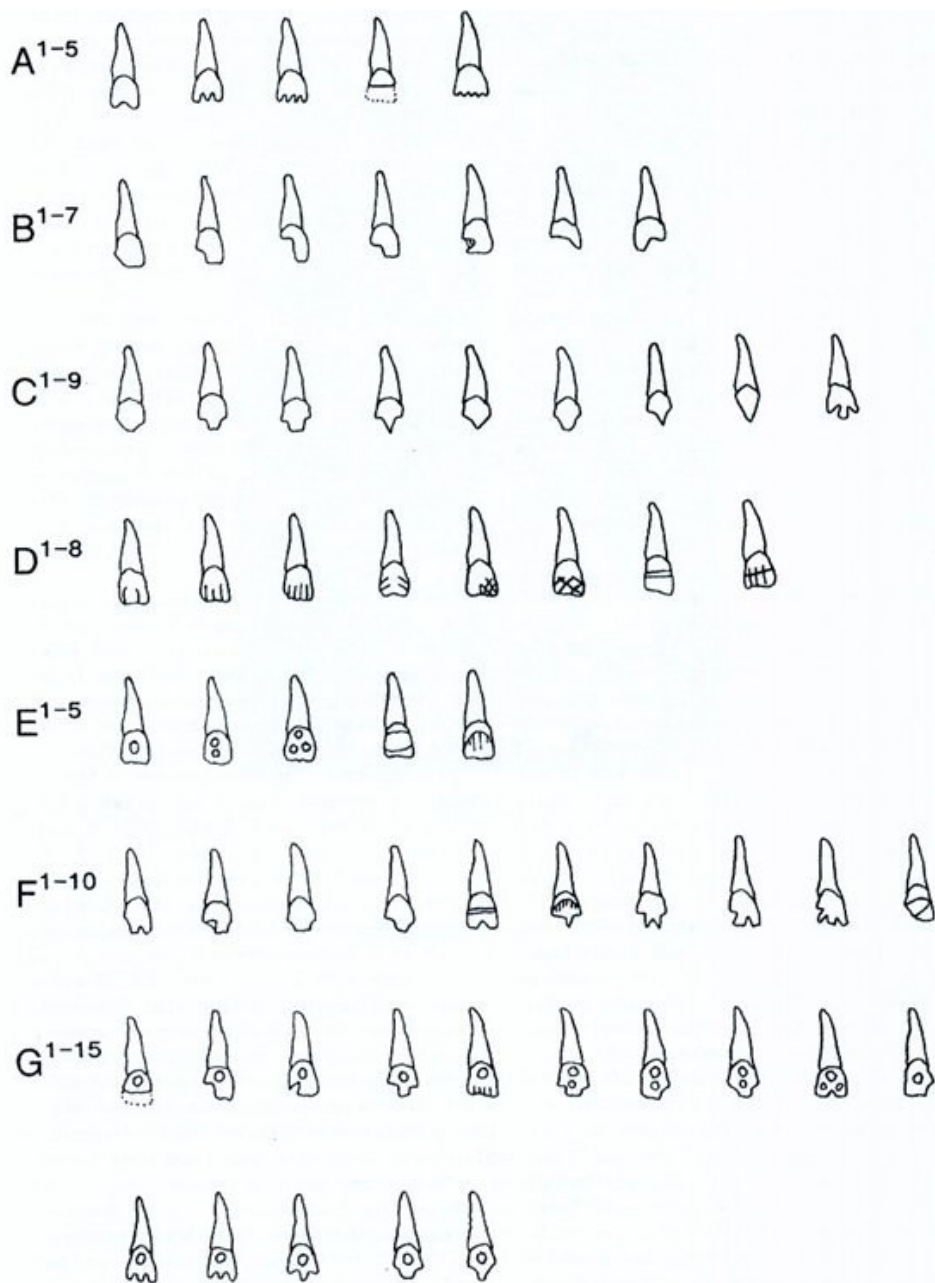


Figure 1 Classification system for the variety of dental mutilations given by Romero. Redrawn from Kelley MA, Larsen CS.-editors *Advances in Dental Anthropology*, NewYork Willey-Liss, Inc 1991.

There are also specimens of dental mutilation from North America. The Sky Arieae (Colorado) specimen originates from a period ranging from 880-1170 A.D. It represents a perforated and drilled lower right canine. This is the first example of tooth modification from the American Southwest. The second specimen, originates from Tennessee, and dates from 900 – 1250 A.D. It represents a

mutilated upper central incisor with a transverse mesiodistal groove in the cervical part of the labial surface, and a single notch on the incisal edge. For the first specimen, it is not possible to determine the motivation for drilling but the second example clearly suggests that individuals of higher status displayed such mutilation, considering the position of the grave in which the specimen was found (9,10).

Numerous studies have described tooth modification in Africans living in the past (11,12,13). Tooth modification has been practised in Northwest and Western Central Africa in prehistoric times. Archaeological findings have established that this practice existed at least from the third millennium B.C. The two most common methods of mutilation were filing or chipping the incisal edge of the incisors. A third, seemingly less common method, ablation, has also been detected, although it may have been more frequent in other areas in Africa (14). The form of modification depends upon the localisation and ethnicity of the individual bearing the modification (15,16).

Only one example of dental modification has been documented in Europe. Horizontal grooves have been described on the labial surfaces of anterior teeth of roughly 25 young men. Skeletal remains have been found at several burial sites in Sweden and Denmark dated to the Viking Age, from 800-1050 A.D. (17).

Two retentive appliances belonging to Phoenician dental art have been discovered, both from tombs near Sidon. The best known specimen of Phoenician dental art is the mandibular retentive appliance which dates from between the fifth and fourth centuries B.C. It consists of four natural lower teeth acting as anchors for two carved ivory teeth held between them, which were bound with golden wire (7,18).

It is known that the Etruscans were the first to fabricate true dental appliances. Etruscan dental art displayed great creativity and allows us to observe the high standard of Etruscan dentistry in the 7th and 6th centuries B.C. It is the art of applying artificial substitutes for lost teeth. The usual practice was to fit gold bands over the remaining natural teeth. Bands were constructed to carry the artificial teeth. The missing teeth were replaced with ox teeth, reshaped ivory or human teeth. This type of bridge was not to be fabricated again until the 19th century (19).

All of the above could be described using a phrase borrowed from Scott and Turner: "Writing history with teeth" (20). We would add "Learning history through teeth". Paleodontological research has proven that various pathological conditions of the teeth and jaws were present among our ancestors. Also, research has shown that cosmetic dentistry existed in ancient times. This signifies that old civilisations were considered teeth as one of the principal ornaments of the face. It is interesting that those distinct civilisations developed such similar customs even without any mutual contact and despite their vast differences. This could be considered evidence that the sense of and need for beauty resides deep within human nature.

## References

1. Herrmann NP, Benedix DC, Scott AM, Haskins VA. A Brief Comment on Functional Use of Intentionally Filed Teeth: Cueva de las Arañas Tooth Paper. [cited 2009 Oct 23];[about 3 p.]. Available from: <http://130.18.228.15/Aranas/aranpap.htm>

2. Coppa A, Bondioli L, Cucina A, Frayer D, Jarrige J, Jarrige C, Quivron G, Rossi M, Vidale M, Macchiarelli R. Early Neolithic Tradition of Dentistry. *Nature* 2006; 440 755-756.
3. Alt K., Pichler S. *Artificial Modifications of Human Teeth Dental Anthropology Fundamentals, Limits and Prospects*. New York: SpringerWien, 1998.
4. Klötzer WT, Bollinger K. Mutilation of the teeth in precolumbian America *Dtsch Zahnarztl Z* 1974; 29(6):515-8.
5. Tiesler V. Head Shaping and Dental Decoration Among the Ancient Maya: Archeological and Cultural Aspects. *Proceedings of the 64th Meeting of the Society of American Archaeology*; 1999 Mar 24-28; Chicago, Illinois; 1999. p. 1-6.
6. Kelley MA, Larsen CS.-editors *Advances in Dental Anthropology*, NewYork Willey-Liss, Inc 1991.
7. Malvin E *Ring Dentistry an Illustrated History*. New York Abrams Harry N Inc1993.
8. Hudson B. Dental Wealth, *Archaeology*. 2003; 56(4):10.
9. White TD, DeGusta D, Richards GD, Baker SG., Prehistoric dentistry in the American southwest : A drilled canine from Sky Aerie, Colorado. *American journal of physical anthropology* 1997; 103(3): 409-414.
10. Autry AO. An example of intentional late prehistoric dental mutilation from Middle Tennessee. *Research notes [serial on the internet]*. 1991. Aug [cited 2009 Nov05];7: [about 3p] Available from: <http://mcclungmuseum.utk.edu/research/renotes/rn-07txt.htm>
11. Morris AG. Dental mutilation in Southern African history and prehistory with reference to the "Cap Flat Smile" *J.Humanities*1998; 53:179-183.
12. Gould AR, Farman AG, Corbit D. Mutilations of the dentition in Africa: a review with personal observations. *Quintessence Int Dent Dig* 1984;15(1): 89-94.
13. Reichart PA, Creutz U, Scheifele C. Dental mutilations and associated alveolar bone pathology in African skulls of the anthropological skull collection, Charité, Berlin. *Journal of Oral Pathology & Medicine* 2008;37(1) 50-55.
14. Handler JS. Determining African Birth from Skeletal Remains: A Note on Tooth Mutilation. *Historical Archaeology* 1994; 28(3) 113-19.
15. Finucane BC, Manning K, Touré M. Prehistoric dental modification in West Africa - early evidence from Karkarichinkat Nord, Mali. *International Journal of Osteoarcheology* 2008; 18 (6): 632-640.
16. Haour A, Pearson JA. An instance of dental modification on a human skeleton from Niger, West Africa. *Oxford J. Archaeol.* 2005; 24: 427-433.
17. Arcini C. The Vikings bare their filed teeth. *American Journal Of Physical Anthropology* 2005;128(4): 727-733.
18. Clawson D. Phoenician Dental Art. *The American Press [serial on the internet]*. 1934 [cited 2009 nov 9]; (1) [about 5 p.] Available from: <http://phoenicia.org/dentstry.html>
19. Becker MJ. Etruscan Gold Dental Appliances: Origins and Functions as Indicated by an Example from Orvieto, Italy, in the Danish National Museum. *Dental Anthropology Newsletter* 1994; 8(3) 2-8.
20. Scott GR, Turner CG. Dental anthropology. *Annual Review of Anthropology* 1988;17:99-126.