

Ivan Vrsalović¹, Anja Baraba², Ivica Anić², Ivar Espelid³, Anne B Tveit⁴, Ivana Miletić²

Odluke stomatologa Splitsko-dalmatinske županije o restaurativnom tretmanu aproksimalnih i okluzalnih karijesnih lezija: ogleđna studija

Restorative Treatment Decisions of Dentists in Split and Dalmatia County on Approximal and Occlusal Caries: a Pilot Study

¹ Privatna stomatološka ordinacija u Splitu, Hrvatska
Private practice in Split, Croatia

² Zavod za endodonciju i restaurativnu stomatologiju, Stomatološki fakultet Sveučilišta u Zagrebu, Hrvatska
Department of Endodontics and Restorative Dentistry, School of Dental Medicine, University of Zagreb, Croatia

³ Zavod za pedodonciju Stomatološkog fakulteta Sveučilišta u Oslu, Norveška
Department of Pedodontics, Faculty of Dentistry, University of Oslo, Norway

⁴ Zavod za karijesologiju Stomatološkog fakulteta Sveučilišta u Oslu, Norveška
Department of Cariology, Faculty of Dentistry, University of Oslo

Sažetak

Svrha istraživanja: Zadatak ovog eksperimentalnog istraživanja bio je odrediti dubinu aproksimalnih i okluzalnih karijesnih lezija kod kojih se stomatolozi na području Splitsko-dalmatinske županije odlučuju za restaurativni tretman te vrste preparacija i materijale koje za to odabiru. **Materijali i metoda:** Upitnik koji su sastavili Espelid i suradnici (2001.) preveden je s engleskoga jezika na hrvatski i podijeljen slučajno odabranom uzorku (n=100) stomatologa u Splitsko-dalmatinskoj županiji. Ispunilo ga je njih 28. Na slikama u upitniku bili su prikazani različiti klinički i radiološki stadiji aproksimalnih, okluzalnih i upitnih karijesnih lezija. **Rezultati:** Većina stomatologa odlučila se za restaurativni tretman aproksimalnih karijesnih lezija koje su dosegnule caklinsko-dentinsko spojište (39%) ili vanjsku trećinu dentina (39%). Za aproksimalnu karijesnu leziju 61 posto stomatologa odabrao je tunelsku preparaciju. Otvaranje okluzalne karijesne lezije u dentinu bio je izbor njih 75 posto. Većina (46%) odgovorila je da zub A ima karijesnu leziju u caklini, a 39 posto smatralo je da zub B nema karijesnu leziju. **Zaključak:** Stomatolozi Splitsko-dalmatinske županije odlučuju se za restaurativni tretman u trenutku kada karijesna lezija dosegne caklinsko-dentinsko spojište ili vanjsku trećinu dentina, ali su potrebna daljnja istraživanja na većem broju ispitanika.

Zaprimljen: 22. ožujak 2009.

Prihvaćen: 22. svibanj 2009.

Adresa za dopisivanje

Ivana Miletić
Zavod za endodonciju i restaurativnu stomatologiju
Stomatološki fakultet Sveučilišta u Zagrebu
Gundulićeva 5, 10 000 Zagreb
Tel: + 1 4802 128
Fax: + 1 4802 159
miletic@sfgz.hr

Ključne riječi

Zubni karijes; dentin; upitnik; zdravstvena skrb, istraživanje

Uvod

U većini razvijenih zemalja karijesa je sve manje (1-3), pa tako i u Hrvatskoj (4). Kako bi se ustanovilo mijenjaju li se stajališta o potrebnom stomatološkom tretmanu u skladu sa smanjenom incidencijom i prevalencijom karijesa te s novim smjericama u terapiji te bolesti, važni su podaci o trenutku kada se stomatolozi odlučuju za restaurativni tretman karijesnih lezija, tehnikama preparacije i materijalima kojima se koriste u svakodnevnoj praksi. Ispunjavanje upitnika o pristupu u restaurativnom tretmanu jedan je od načina ispitivanja stomatologa o njihovim odlukama u liječenju karijesnih lezija.

Istraživanja s ispunjavanjem upitnika u Norveškoj, Švedskoj, Danskoj, Zapadnoj Australiji, Škotskoj i Francuskoj, jasno su pokazala velike razlike u odlukama stomatologa kada je riječ o restaurativnom tretmanu karijesnih lezija, (5-15).

Malo je podataka o odlukama naših stomatologa i promjenama u njihovu pristupu terapiji karijesa s obzirom na moderna načela minimalno invazivnog pristupa. Svrha ovog eksperimentalnog istraživanja bila je odrediti dubinu aproksimalnih i okluzalnih karijesnih lezija kod koje se stomatolozi na području Splitsko-dalmatinske županije odlučuju za restaurativni tretman te vrste preparacija i materijale koje odabiru, što je uvod u istraživanje koje bi obuhvatilo veći broj ispitanika. Cilj je bio ispitati i sposobnost stomatologa da dijagnosticiraju okluzalnu karijesnu leziju.

Materijali i metode

Upitnik (Slika 1.) koji su sastavili Espelid *i suradnici* (15) preveden je s engleskoga jezika na hrvatski i podijeljen slučajnom uzorku (n=100) od ukupnog broja (n=853) stomatologa u Splitsko-dalmatinskoj županiji. Odgovaralo se anonimno i odgovori su bili skupljeni od 38 stomatologa, ali samo 28 ih je uključeno u istraživanje. Deset upitnika bilo je odbačeno zbog jednog ili više neodgovorenih pitanja. Upitnik je također poslužio da bi se otkrilo kada se stomatolozi odlučuju za restaurativni tretman aproksimalnih, okluzalnih i upitnih karijesnih lezija te koje su najčešće vrste preparacija i restaurativnih materijala. Slike u upitniku (Slika 1.) prikazivale su različite radiološke stadije aproksimalnog karijesa, kliničke stadije okluzalnog karijesa (stadiji od 1 do 5) i kombinaciju radiološkog i kliničkog nalaza upitnih karijesnih lezija za zube A i B. Osim pitanja o općim podacima, upitnik je sadržavao četiri

Introduction

Caries occurrence has decreased in most developed countries (1-3) and the same trend is observed in Croatia (4). Information about restorative treatment thresholds, preparation techniques and restorative materials dentists use in their practice are necessary to determine whether dental treatment philosophies are altering in response to decline in incidence and prevalence of caries, innovations in treatment practices and new guidelines regarding caries management. One approach which has been used to determine the treatment strategies among dentists consists of asking dentists to complete a questionnaire in which they are asked to identify their restorative treatment decisions.

The wide range of disparities among dentists were clearly demonstrated in studies investigating restorative treatment criteria on caries in everyday dental practice using questionnaires in Norway, Sweden, Denmark, Western Australia, Scotland and France (5-15).

Little is known about preferences of Croatian dentists and modifications in their approach in treatment due to new principles of minimally invasive dentistry. The aim of this pilot study was to identify treatment thresholds, restorative methods and materials for approximal and occlusal caries lesions used by Croatian dentists in Split and Dalmatia County, as an introduction to a more extensive study. The capacity of practitioners to detect an occlusal lesion was also assessed.

Materials and Methods

The questionnaire of Espelid *et al.* (15) was translated from English to Croatian. The final version of questionnaire (Figure 1) was distributed to a random sample (n=100) of all dentists in Split and Dalmatia County (n=853). The questionnaire was anonymous. Responses were collected from 38 dentists but only 28 questionnaires were included in the study. Ten questionnaires were discarded because of one or more unanswered questions. The questionnaire assessed dentists' treatment thresholds for hypothetical approximal, occlusal and questionable caries, as well as most favoured types of restorative techniques and materials. Figures in the questionnaire (Figure 1), included as an addition to questions, illustrated different radiographic stages of approximal caries, clinical appearance of different stages of occlusal caries (grades 1-5) and combination of radiographic and clinical findings for ques-

UPITNIK: Odluka o restaurativnom tretmanu aproksimalnih i okluzalnih karijesnih lezija**QUESTIONNAIRE: Restorative treatment decisions on aproximal and occlusal caries.**

Godina rođenja • Year of birth: 19.....

Spol • Sex: 1 Muški • Male 2 Ženski • Female

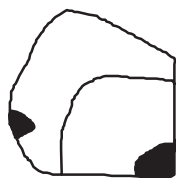Godina diplomiranja • Date of graduation:

Radi u • Type of activity:

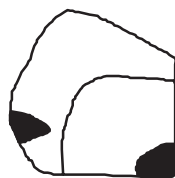- 1 Domu zdravlja • Public Dental Health Services
 2 Privatnoj praksi u ugovoru s HZZO-om • Private practice in contract with Croatian Institute for Health Insurance
 3 Privatnoj praksi • Private practice
 4 Specijalist • Specialist
 Navesti • Specify:

I a) Slika 1. prikazuje shematski različite radiološke stadije napredovanja aproksimalnog karijesa. Pacijentica ima nisku aktivnost karijesa i dobru oralnu higijenu. Kod koje dubine lezije biste počeli s izradom kaviteta?

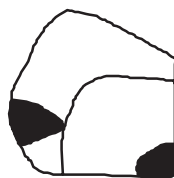1 a) Figure 1 illustrates different radiographic stages of caries progression. Which lesion(s) do you think require(s) immediate restorative treatment? That is, the lesion(s) for which you would not postpone restorative treatment under any circumstances even if the patient has low caries activity and good oral hygiene.



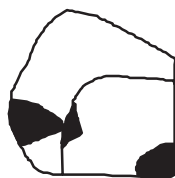Karijes dosegnuo vanjsku polovicu cakline • Outer half of enamel
1



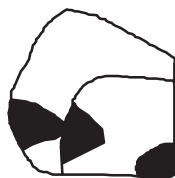Karijes dosegnuo unutrašnju polovicu cakline • Inner half of enamel
2



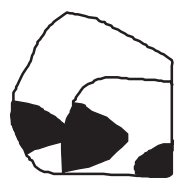
Karijes dosegnuo caklinsko-dentinsku granicu • Enamel-dentin border
3



Karijes dosegnuo vanjsku 1/3 dentina • Outer 1/3 of dentin
4



Karijes dosegnuo vanjsku polovicu dentina • Outer half of dentin
5



Karijes dosegnuo unutrašnju polovicu dentina • Inner half of dentin
6

I b) Aproksimalna lezija smještena je na distalnoj plohi drugog gornjeg premolara. Pacijentica ima 20 godina, posjećuje stomatologa jedanput na godinu, ima dobru oralnu higijenu i koristi se svaki dan fluoridiranom zubnom pastom. Kojoj vrsti kaviteta dajete prednost u odnosu prema prethodnom odgovoru?

1 b) Which type of preparation would you prefer for the smallest of the lesions you decided to drill and fill? Imagine that the approximal lesion is situated distally on the second premolar in the upper jaw. The patient who is 20 years of age sees his dentist once a year and has adequate hygiene and uses fluoride toothpaste.

(Odaberite jedan odgovor • Tick only one item)

Vrsta preparacije • Type of preparation	Kvačica • Tick
Klasična preparacija II. razreda (Black) • Traditional class II preparation	1 <input type="checkbox"/>
Tunelska preparacija • Tunnel-preparation	2 <input type="checkbox"/>
Preparacija u obliku tanjurića • Saucer shaped preparation	3 <input type="checkbox"/>

I c) Kojim materijalom biste se koristili za ispun gore navedenog aproksimalnog kaviteta?

1 c) What restorative material would you choose for the smallest approximal lesion that you would restore?

(Odaberite jedan odgovor • Tick only one item)

Restaurativni materijal • Material	Kvačica • Tick
Amalgam	1 <input type="checkbox"/>
Kompozit • Composite resin	2 <input type="checkbox"/>
Konvencionalni SIC* • Conventional GIC*	3 <input type="checkbox"/>
Smolom modificirani SIC* • Resin modified GIC*	4 <input type="checkbox"/>
Kombinacija SIC* i kompozita • Combination of GIC* and composite resin	5 <input type="checkbox"/>
Ostalo (opiši) Other (describe)	6 <input type="checkbox"/>

*SIC: staklenoionomerni cement • *GIC: glass ionomer cement

II a) Slika 2. (vidi prilog) prikazuje različite kliničke slike okluzalnog karijesa drugog donjeg molara. Pacijentica ima 20 godina, nisku aktivnost karijesa i dobru oralnu higijenu. Kod koje dubine lezije biste počeli s izradom kaviteta?

II a) Figure II illustrates different clinical appearances of occlusal caries in a lower second molar. Which lesion(s) do you think require(s) immediate restorative (operative) treatment? That is, the lesion(s) for which you would not postpone restorative treatment under any circumstances. Reckon that the patient is 20 years old, has low caries activity and good oral hygiene.

II 1	II 2		II 3	II 5
Bijela/smeđa diskoloracija u caklini, bez kavitacije. Nema znakova karijesa na rtg-u. • White/brownish discoloration in the enamel, no cavitation. No radiographic signs of caries.	Mali gubitak zubnog tkiva, pukotina u caklini ili diskoloracija fisura sa sivom/opaknom caklinom i/ili karijes ograničen na caklinu. Nema znakova karijesa na rtg-u. • Minor loss of tooth substance with a break in the enamel surface or discolored surface or discolored fissures with grey/opaque enamel and/or caries confined to the enamel. No radiographic signs of caries.	Umjeren gubitak zubnog tkiva i/ili karijes u vanjskoj 1/3 dentina koji je vidljiv na rtg-u. • Moderate loss of tooth substance and/or caries in the outer 1/3 of the dentin according to the radiograph.	Znatan gubitak zubnog tkiva i/ili karijes u srednjoj 1/3 dentina koji je vidljiv na rtg-u. • Considerable loss of tooth substance and/or caries in the middle 1/3 of the dentin according to the radiograph.	Znatan gubitak zubnog tkiva i/ili karijes u unutrašnjoj 1/3 dentina koji je vidljiv na rtg-u. • Considerable loss of tooth substance and/or caries in the inner 1/3 of the dentin according to the radiograph.
1 <input type="checkbox"/>	2 <input type="checkbox"/>	3 <input type="checkbox"/>	4 <input type="checkbox"/>	5 <input type="checkbox"/>

II b) Okluzalna lezija smještena je na donjem drugom molaru. Pacijentica ima 20 godina, posjećuje stomatologa jedanput na godinu, održava dobru oralnu higijenu i koristi se fluoridiranom zubnom pastom. Kojoj vrsti kaviteta dajete prednost u odnosu prema prethodnom odgovoru?

II b) Which type of preparation would you prefer for the smallest of the lesions you decided to drill and fill? Imagine that the occlusal lesion is situated in the second molar in the lower jaw. The patient is 20 years of age and sees his dentist once a year, has adequate hygiene and uses fluoride toothpaste.

(Odaberite jedan odgovor • Tick only one item)

Tehnika preparacije • Preparation technique	Kvačica • Tick
Uklanjanje samo karijesom promijenjenog tkiva • Removal of carious tissue only	1 <input type="checkbox"/>
Otvaranje cijelog fisurnog sustava • Open the whole fissure system	2 <input type="checkbox"/>
Ostalo (opiši) Other (describe)	3 <input type="checkbox"/>

II c) Kojim materijalima biste se koristili za ispun gore navedenog okluzalnog kaviteta?

II c) What restorative material would you choose for the smallest occlusal lesion that you would restore?

(Odaberite jedan odgovor • Tick only one item)

Restaurativni materijal • Material	Kvačica • Tick
Amalgam	1 <input type="checkbox"/>
Kompozit • Composite resin	2 <input type="checkbox"/>
Konvencionalni SIC* • Conventional GIC*	3 <input type="checkbox"/>
Smolom modificirani SIC* • Resin modified GIC*	4 <input type="checkbox"/>
Kombinacija SIC* i kompozita • Combination of GIC* and composite resin	5 <input type="checkbox"/>
Ostalo (opiši) Other (describe)	6 <input type="checkbox"/>

*SIC: staklenoionomerni cement • *GIC: glass ionomer cement

III a) Ima li, prema kliničkoj slici i radiološkom nalazu, zub A (vidi prilog) okluzalno karijes?

III a) Do you think that, from its clinical and radiographic appearance, tooth A has occlusal (enamel or dentin) caries?

(Odaberite jedan odgovor • Tick only one item)

Dijagnoza • Diagnostic	Kvačica • Tick
Nema karijesne lezije • No lesion	1 <input type="checkbox"/>
Karijes ograničen na caklinu • Caries confined to the enamel	2 <input type="checkbox"/>
Karijes prodro u dentin • Caries extend to the dentin	3 <input type="checkbox"/>
Nisam siguran/a • Uncertain	4 <input type="checkbox"/>

III b) Pacijentica ima 20 godina. Prvi put je došla u vašu ordinaciju i prošle su dvije godine od njezina posljednjeg pregleda kod stomatologa. Svaki se dan koristi fluoridiranom zubnom pastom i ima dobru oralnu higijenu. Ako se odlučite za terapiju lezije na zubu A, koji zahvat biste odabrali?

III b) How would you treat this occlusal surface? The patient is 20 years of age. You have not seen the patient before, and 2 years have elapsed since the last examination. The patient uses fluoride toothpaste on a daily basis and dietary and oral hygiene habits are considered satisfactory.

(Odaberite jedan odgovor • Tick only one item)

Tretman • Treatment	Kvačica • Tick
Bez tretmana • No treatment	1 <input type="checkbox"/>
Fluoridacija • Fluoride treatment	2 <input type="checkbox"/>
Pečaćenje fisura • Fissure sealing	3 <input type="checkbox"/>
Preparacija i restauracija isključivo karijesnog tkiva • Prepare and restore carious part only	4 <input type="checkbox"/>
Preparacija i restauracija isključivo karijesnog tkiva + pečaćenje fisura • Prepare and restore carious part + fissure sealing	5 <input type="checkbox"/>
Preparacija i restauracija cijelog fisurnog sustava • Prepare and restore whole fissure	6 <input type="checkbox"/>

III c) Ako ste izabrali izradu kaviteta za zub A, koji materijal biste odabrali za ispun? Primjer se odnosi na donji drugi molar.

III c) If you would restore the tooth, what material would you use? The example refers to a second molar.

(Odaberite jedan odgovor • Tick only one item)

Restaurativni materijal • Material	Kvačica • Tick
Amalgam	1 <input type="checkbox"/>
Kompozit • Composite resin	2 <input type="checkbox"/>
Konvencionalni SIC* • Conventional GIC*	3 <input type="checkbox"/>
Smolom modificirani SIC* • Resin modified GIC*	4 <input type="checkbox"/>
Kombinacija SIC* i kompozita • Combination of GIC* and composite resin	5 <input type="checkbox"/>
Ostalo (opiši) Other (describe)	6 <input type="checkbox"/>

*SIC: staklenoionomerni cement • *GIC: glass ionomer cement

IV a) Ima li, prema kliničkoj slici i radiološkom nalazu, zub B (vidi prilog) okluzalno karijes?

IV a) Do you think that, from its clinical and radiographic appearance, tooth B has occlusal (enamel or dentin) caries?

(Odaberite jedan odgovor • Tick only one item)

Dijagnoza • Diagnostic	Kvačica • Tick
Nema karijesne lezije • No lesion	1 <input type="checkbox"/>
Karijes ograničen na caklinu • Caries confined to the enamel	2 <input type="checkbox"/>
Karijes prodro u dentin • Caries extending to the dentin	3 <input type="checkbox"/>
Nisam siguran/a • Uncertain	4 <input type="checkbox"/>

IV b) Pacijentica ima 20 godina. Prvi put dolazi u vašu ordinaciju i prošle su dvije godine od njezina posljednjeg pregleda kod stomatologa. Svaki se dan koristi fluoridiranom zubnom pastom i ima dobru oralnu higijenu. Ako se odlučite za terapiju lezije na zubu B, koji zahvat biste odabrali?

IV b) How would you treat this occlusal surface? The patient is 20 years of age. You have not seen the patient before, and 2 years have elapsed since the last examination. The patient uses fluoride toothpaste on a daily basis and dietary and oral hygiene habits are considered satisfactory.

(Odaberite jedan odgovor • Tick only one item)

Tretman • Treatment	Kvačica • Tick
Bez tretmana • No treatment	1 <input type="checkbox"/>
Fluoridacija • Fluoride treatment	2 <input type="checkbox"/>
Pečaćenje fisura • Fissure sealing	3 <input type="checkbox"/>
Preparacija i restauracija isključivo karijesnog tkiva • Prepare and restore carious part only	4 <input type="checkbox"/>
Preparacija i restauracija isključivo karijesnog tkiva + pečaćenje fisura • Prepare and restore carious part + fissure sealing	5 <input type="checkbox"/>
Preparacija i restauracija cijelog fisurnog sustava • Prepare and restore whole fissure	6 <input type="checkbox"/>

IV c) Ako ste izabrali izradu kaviteta za zub B, koji materijal biste odabrali za ispun? Primjer se odnosi na donji drugi molar.
IV c) If you would restore the tooth, what material would you use? The example refers to a second molar.

(Odaberite jedan odgovor • Tick only one item)

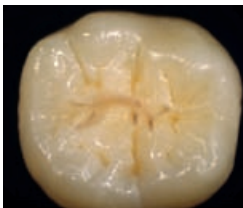Restaurativni materijal • Material	Kvačica • Tick
Amalgam	1 <input type="checkbox"/>
Kompozit • Composite resin	2 <input type="checkbox"/>
Konvencionalni SIC* • Conventional GIC*	3 <input type="checkbox"/>
Smolom modificirani SIC* • Resin modified GIC*	4 <input type="checkbox"/>
Kombinacija SIC* i kompozita • Combination of GIC* and composite resin	5 <input type="checkbox"/>
Ostalo (opiši) Other (describe)	6 <input type="checkbox"/>

*SIC: staklenoionomerni cement • *GIC: glass ionomer cement

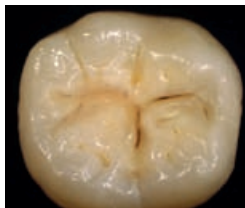Dodatak • Annexes

Pitanje II. • Question II

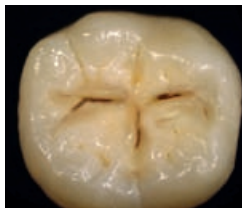II₁



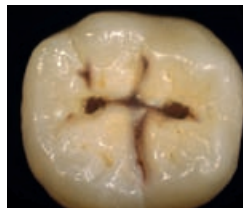II₂



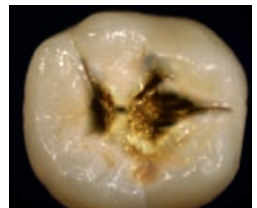
II₃



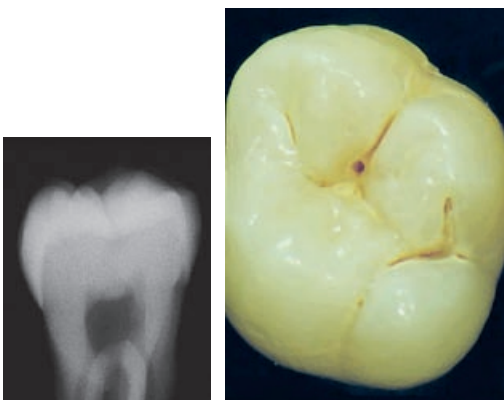II₄



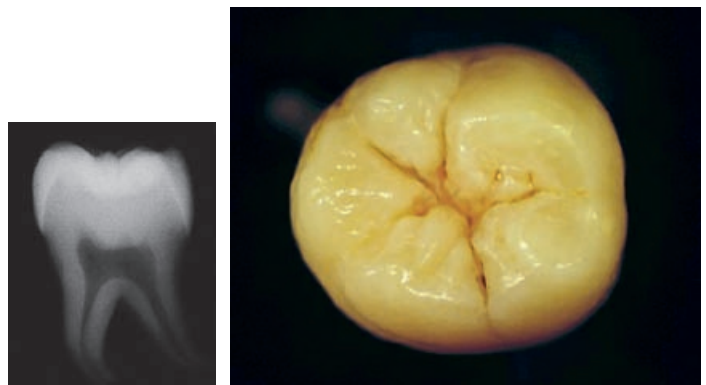II₅



Zub « A » (Pitanje III.) • Tooth « III » (Question III)



Zub « B » (Pitanje IV.) • Tooth « IV » (Question IV)



Slika 1. Upitnik
Figure 1 Questionnaire

skupine pitanja (I., II., III. i IV. - Slika 1.) s nekoliko ponuđenih odgovora za svako pitanje. Stomatolozi su trebali odgovoriti u kojem se stadiju aproksimalne (I.) i okluzalne (II.) karijesne lezije odlučuju za restaurativni tretman te postaviti dijagnozu okluzalnog karijesa na zubima A (III.) i B (IV.). Ponuđeni odgovori za tehnike preparacije bili su tradicionalna preparacija II. razreda, tunelska preparacija i preparacija u obliku tanjurića za aproksimalnu karijesnu leziju te uklanjanje samo karijesnog tkiva ili otvaranje cijeloga fisurnog sustava za okluzalni karijes. Za upitne karijesne lezije bili su ponuđeni odgovori: bez tretmana, fluoridacija, pečačenje fisura, uklanjanje samo karijesnog tkiva, kombinacija pečačenja fisura i uklanjanja karijesnog tkiva te otvaranje cijelog fisurnog sustava. Kao restaurativni materijali za sve četiri skupine pitanja bili su ponuđeni: amalgam, kompozit, konvencionalni stakleno ionomerni cement (SIC), smolom modificirani SIC, kompozit u kombinaciji sa SIC-om i drugo. Sva pitanja odnosila su se na hipotetskog 20-godišnjeg pacijenta koji redovito jedanput na godinu posjećuje stomatologa, s dobrom oralnom higijenom i niskom aktivnošću karijesa.

Rezultati

U ukupnom broju stomatologa koji su ispunili upitnik (28) bilo je 17 žena i 11 muškaraca. S obzirom na dob, 18 je bilo mlađih od 45 godina, a 10 starijih.

Aproksimalni karijes

Većina stomatologa odlučila se za restaurativni tretman aproksimalnih karijesnih lezija ako su dosegnule caklinsko-dentinsko spojište (39%) ili vanjsku trećinu dentina (39%), a 22 posto odlučilo je otvoriti leziju ograničenu na caklinu.

Za aproksimalnu karijesnu leziju 61 posto stomatologa odabralo je tunelsku preparaciju, a tradicionalnu preparaciju II. razreda izabralo je njih 21 posto. Preparaciju u obliku tanjurića napravilo bi 18 posto stomatologa. Kompozit kao materijal za izradu ispuna izabralo je njih 82 posto, 14 posto odabralo je kombinaciju SIC-a i kompozita, a 4 posto konvencionalni SIC. Nitko nije smatrao da za restauraciju aproksimalne karijesne lezije treba izabrati amalgam.

Okluzalni karijes

Većina stomatologa (75%) odlučila se za restaurativni tretman karijesnih lezija u dentinu (stadij 3 do

tionable occlusal caries for teeth A and B. Beside some general data which were required preliminary for dentists to fill out, the questionnaire consisted of four groups (I, II, III and IV) of questions (Figure 1) with multiple choice answers in which the dentists had to decide at which stage of approximal (I) and occlusal (II) carious lesion progress a restorative treatment was considered appropriate and to diagnose if occlusal caries was present in teeth A (III) and B (IV). Restorative techniques choice had to be made between traditional class II, tunnel and saucer shaped preparations for approximal lesions and between removing carious tissue only or opening the whole fissure system for occlusal lesions. For questionable caries in teeth A and B, dentists were offered the following treatments: no treatment, application of fluorides, fissure sealing, removing carious tissue only, combination of fissure sealing and operative treatment or opening the whole fissure system. Answers offered for restorative materials for all four groups of questions were: amalgam, composite resin, conventional glass ionomer cement (GIC), resin modified GIC, composite resin plus GIC and other. All questions referred to a hypothetical 20-year-old patient, with good oral hygiene, low caries activity and who visited a dentist annually.

Results

From the total number of respondents (28), there were 17 female and 11 male dentists; 18 dentists were younger and 10 were older than 45 years.

Approximal caries

The majority of dentists would prepare a cavity when a lesion reached the dentin-enamel junction (39%) or would not restore the lesion until it penetrated the dentin (39%), while 22% would restore a lesion still confined to enamel.

The preferred cavity design was the tunnel preparation technique chosen by 61% of dentists while the traditional class II preparation and the saucer-shaped preparation were chosen by 21% and 18% of the respondents, respectively. The preferred restorative material was composite resin for 82% of dentists, 14% suggested combination of GIC and composite resin and only 4% chose conventional GIC. No dentists would use amalgam for cavity restoration.

Occlusal caries

The majority of dentists (75%) stated that they would intervene restoratively for carious lesions in

5), a 25 posto otvorilo bi karijesnu leziju ograničenu na caklinu (stadij 2). Većina (79%) uklonila bi samo karijesno tkivo, a ne bi otvarala cijeli fisurni sustav. Najviše stomatologa (82%) izabralo je kompozit kao restaurativni materijal, 14 posto kombinaciju SIC-a i kompozita, a 4 posto odabralo bi druge restaurativne materijale koji nisu bili ponuđeni kao odgovori u upitniku. Ni kod okluzalnog karijesa nitko od stomatologa nije se odlučio za amalgam.

Upitna karijesna lezija

Većina stomatologa (47%) procijenila je da zub A ima karijesnu leziju ograničenu na caklinu (Slika 2.). Od ukupnog broja stomatologa koji su sudjelovali u istraživanju, 61 posto bi uklonio samo karijesom promijenjeno tkivo, a 14 posto bi obavilo i pečaćenje fisura. Otvaranje cijelog fisurnog sustava, pečaćenje fisura ili bez tretmana izabralo je 7 posto stomatologa, a za fluoridaciju odlučilo se njih 4 posto. Većina se odlučila za kompozit kao restaurativni materijal (83%), 13 posto stomatologa upotrijebilo bi smolom modificirani SIC, a 4 posto kombinaciju SIC-a i kompozita.

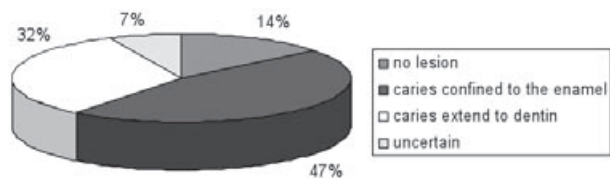
Zub B je većina (39%) proglasila “zdravim”, a isti postotak stomatologa (39%) dijagnosticirao je na istom zubu karijes ograničen na caklinu (Slika 3.). Od ponuđenih odgovora 25 posto stomatologa odlučilo se za pečaćenje fisura, a 25 posto samo za uklanjanje karijesnog tkiva (Slika 4.). Kompozitni materijal bio je izbor 57 posto stomatologa, 29 posto je izabralo smolom modificirani SIC, 7 posto konvencionalni SIC i 7 posto kombinaciju SIC-a i kompozita.

dentin (grade 3-5), 25% would prepare and restore caries lesions confined to enamel (grade 2). The majority (79%) of dentists would remove only the affected areas without preparing the whole fissure system. Composite resin was the most chosen restorative material (82%) and only 14% of dentists chose combination of GIC and composite resin while 4% would use other restorative materials than those offered in the questionnaire. Again, no one would use amalgam for restoration of the occlusal lesion.

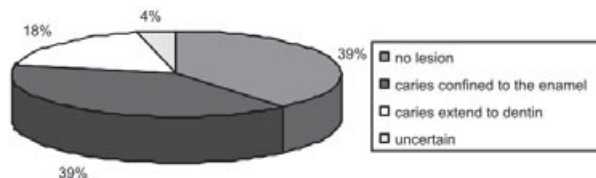
Questionable occlusal lesion

The majority (47%) of the dentists judged tooth as having a carious lesion confined to the enamel (Figure 2). Of all the dentists included in this study, 61% would prepare the carious part only, 14% would prepare the lesion and seal the fissure system. Treatment choices like opening the whole fissure system, sealing the fissure system and no treatment were chosen by 7% of dentists each while 4% of dentists would use only fluoridation for tooth A. The restorative material of choice was composite resin (83%), 13% of dentists would use resin modified GIC and 4% would use combination of GIC and composite resin.

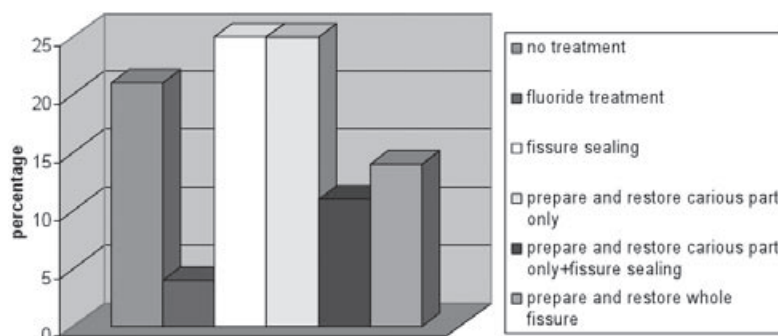
Tooth B was judged “sound” by 39% of the respondents, while the same percentage (39%) of dentists diagnosed caries confined to enamel (Figure 3). From the offered treatment options, 25% of all dentists would seal the fissure system and 25% of them would remove the caries without fissure sealing (Figure 4). Composite material was a choice for 57% of dentists, 29% chose resin modified GIC, 7%



Slika 2. Dijagnoza stomatologa za zub A
Figure 2 Dentists' diagnosis for tooth A



Slika 3. Dijagnoza stomatologa za zub B
Figure 3 Dentists' diagnosis for tooth B



Slika 4. Tretman koji su stomatolozi odabrali za zub B
Figure 4 Dentists' treatment suggestions for tooth B

Rasprava

U ovom se radu o rezultatima može raspravljati isključivo u sklopu ograničenja ovog eksperimentalnog istraživanja s obzirom na broj ispitanika, i zaključci se ne mogu odnositi na cijelu populaciju stomatologa Splitsko-dalmatinske županije. Izravne usporedbe sa sličnim istraživanjima u drugim zemljama – neka su bila provedena prije 10 ili više od 10 godina (5-12, 15) - nisu moguće, jer su se možda u tom razdoblju promijenila stajališta stomatologa o restaurativnom tretmanu.

Većina stomatologa Splitsko-dalmatinske županije ne bi otvarala karijesnu leziju do trenutka dok ne dosegne caklinsko-dentinsko spojište ili ne zahvati dentin. Tunelska preparacija bila je izbor za restauraciju aproksimalne karijesne lezije. Moguće objašnjenje za tu metodu jest činjenica da se tom tehnikom uklanja manje tvrdih zubnih tkiva u odnosu prema klasičnoj preparaciji II. razreda. No, tunelska se preparacija povezuje s nepotpunim uklanjanjem karijesa, povećanim rizikom od frakture marginalnog grebena ili lošom aproksimalnom adaptacijom ispuna (16). Ta se tehnika preparacije može primjenjivati samo kod pacijenata s niskom aktivnošću karijesa, poput onoga opisanoga u našem istraživanju. Može se rabiti i kod inicijalnih karijesnih lezija koje ne prelaze vanjsku trećinu dentina (17). Broj stomatologa koji se odlučio za klasičnu preparaciju II. razreda bio je veći od broja stomatologa koji su se odlučili za preparaciju u obliku tanjurića, iako taj način štedi zdrav dentin i zato je bolji izbor od klasične preparacije (18).

Glavna strategija stomatologa kod okluzalnog karijesa u ovom je istraživanju bila odgoditi restaurativni tretman dok karijes ne zahvati vanjsku trećinu dentina. U terapiji okluzalnog karijesa većina se odlučila ukloniti samo karijesom promijenjeno tkivo, a ne otvoriti cijeli fisurni sustav.

Zubi A i B prikazani su na slikama kao kombinacija radiološkog i kliničkog nalaza koja stomatologima daje najveću točnost i sigurnost u postavljanju dijagnoze (19). Za zub A bila je postavljena dijagnoza karijesa ograničenog na caklinu, a za zub B da nema karijesa. Većina stomatologa odlučila se za uklanjanje samo karijesom zahvaćenog tkiva za zub A i za pečaćenje fisura za zub B. Pečaćenje fisura siguran je i učinkovit način prevencije karijesa i zaustavljanja početnih karijesnih lezija (20). Postavljanje pečata obično je određeno vremenom nicanja

conventional GIC and 7% chose combination of GIC and composite resin.

Discussion

In Split and Dalmatia County, the response rate of dentists who were given the questionnaire was rather low and all the results can be discussed only within the limits of this pilot study. Direct comparison with other countries where the studies on restorative thresholds were conducted almost or over a decade ago (5-12, 15) is not possible because of a strong possibility of a shift in dentists' restorative decisions over longer period of time and because the sample of dentists who answered the questionnaire was too small to make conclusions for the entire population of dentists in Split and Dalmatia County.

The majority of respondents in Split and Dalmatia County would not restore the cavity for an approximal lesion until it reached dentin-enamel junction or penetrated dentin. A tunnel preparation for restoration of the approximal lesion was the choice of the dentists. Possible explanation for choice of tunnel technique in restoration of approximal lesion may be the fact that this technique is used as a more conservative alternative to the conventional class II preparation. However, tunnel preparation is regarded to be associated with incomplete caries removal, an increased risk of marginal ridge fracture or poor adaptation of the restoration proximally (16). This preparation technique is adequate only for patients with low caries activity, as the one described in this study, and for initial caries lesions that do not extend over outer third of dentin (17). The number of dentists who preferred the traditional class II preparation was higher than those preferring a saucer-shaped preparation, although the saucer-shaped preparation spares sound dentin and is preferable to traditional class II preparation (18). The leading strategy among the dentists in this study concerning occlusal caries was postponing operative treatment until the caries lesion penetrated the outer third of dentin. Concerning the preparation technique, the majority of dentists in this study would remove the carious part of the fissure only.

The teeth A and B were presented on figures as a combination of radiographic and clinical appearance which gives the best accuracy for practitioners in diagnosing occlusal caries (19). Tooth A and tooth B were judged having the caries confined to the enamel and free of caries, respectively, by the majority of dentists. Regarding the treatment alter-

zuba, ali u određenim slučajevima može se obaviti dugo nakon nicanja, a obzirom na cjelokupni rizik od nastanka karijesa kod pacijenta (21). Pečatni ispuni najprikladniji su za male okluzalne karijesne lezije. Za taj su postupak potrebne radiološke snimke (22) koje su i bile ponuđene u istraživanju.

Većina stomatologa odabrala je kompozit kao restaurativni materijal za aproksimalne i okluzalne karijesne lezije. Danas se u praksi, zbog novih materijala i potrebe za estetikom, mijenjaju zahtjevi pacijenata i stajališta stomatologa o odabiru restaurativnih materijala te se odabir kompozita mogao očekivati.

Unatoč nekim ohrabrujućim rezultatima, četvrtina stomatologa u Splitsko-dalmatinskoj županiji, sudionika našeg istraživanja, obavila bi restaurativni tretman inicijalnih aproksimalnih i okluzalnih karijesnih lezija koje se još mogu remineralizirati, posebice ako se ima na umu hipotetski pacijent opisan u upitniku (mlad, s niskim rizikom od nastanka karijesa, dobra oralna higijena, redoviti posjeti stomatologu).

Zaključak

Unatoč ograničenjima ovoga eksperimentalnog istraživanja, može se zaključiti da stomatolozi Splitsko-dalmatinske županije počinju s restaurativnim tretmanom u trenutku kada karijesna lezija dosegne caklinsko-dentinsko spojište ili zahvati vanjsku trećinu dentina. Osim toga biraju i preparacije koje štede strukturu zuba i estetske materijale za ispunje kod aproksimalnih i okluzalnih karijesnih lezija, što pokazuje da čuvaju zubno tkivo i misle na estetiku. Potrebna su daljnja istraživanja na većem uzorku kako bi se mogli prihvatiti zaključci o odlukama o restaurativnom tretmanu stomatologa Splitsko-dalmatinske županije.

Zahvala

Istraživanje je dobilo financijsku potporu u sklopu projekta "Eksperimentalna i klinička endodontologija", broj 065-0650444-0418, koji je odobrilo Ministarstvo znanosti, obrazovanja i športa Republike Hrvatske.

native, the majority of dentists in this study chose again preparation and restoration of carious tissue only for tooth A, and fissure sealing for tooth B. Sealants are safe and effective in preventing caries and arresting incipient decay (20) and although placement of sealants is usually determined by the time of the tooth eruption, in some cases sealants are placed long after tooth eruption, according to patients' overall caries risk (21). The sealant restoration is most appropriate for a small occlusal caries lesion, when the prepared cavity is discrete. In this case, radiographs are a pre-requisite (22), as were given in this study.

Overall, composite resin was chosen most often as a restorative material for approximal and occlusal caries lesion and this finding is not surprising. Modern dentistry emphasizes the importance of aesthetics in restorative treatment so selection of restorative materials and these demands influence both the patient and the dentists in their treatment planning.

Despite some encouraging results, still 1/4 of the dentists in Split and Dalmatia County, who answered the questionnaire, would restore incipient approximal and occlusal caries, which can probably be remineralized, especially when keeping in mind the theoretical patients' characteristics described in the questionnaire, like young age, low caries risk, good oral hygiene and regular attendance to dental office.

Conclusion

Within the limits of this pilot study, it can be concluded the dentists in Split and Dalmatia County who answered the questionnaire start the restorative treatment when carious lesions reached the dentin-enamel junction or penetrated dentin. Tooth substance-saving preparation techniques and tooth coloured materials are the choice for restoration of the approximal and occlusal lesions indicating the need for conservation of tooth structure and the demand for aesthetic dentistry. Further studies are necessary, including larger number of dentists, to conclude about the restorative decisions of dentists in Split and Dalmatia County.

Acknowledgements

This study was performed and financed within the research project „Experimental and Clinical Endodontology“ No. 065-0650444-0418 approved by the Ministry of Science, Education and Sports of the Republic of Croatia.

Abstract

Objective of work: The aim of this pilot study was to identify treatment thresholds, restorative methods and materials for approximal and occlusal caries lesions used by dentists in Split and Dalmatia County. **Materials and Methods:** The questionnaire of Espelid *et al.* (2001) was translated from English to Croatian and distributed to a random sample (n=100) of dentists in Split and Dalmatia County. Responses were collected from 28 dentists. Figures, included as an addition to questions, illustrated different clinical and radiographic stages of approximal, occlusal and questionable carious lesions. **Results:** The majority of dentists would perform restorative treatment for an approximal carious lesion which reached dentin-enamel junction (39%) or would not restore the lesion until it penetrated dentin (39%). The preferred cavity design was the tunnel preparation technique chosen by 61% of dentists. The majority of dentists (75%) stated that they would intervene restoratively for occlusal carious lesions in dentin. The majority (46%) of the dentists judged tooth A like having a carious lesion confined to the enamel while tooth B was judged "sound" by 39% of the respondents. **Conclusions:** Dentists in this pilot study tend to restore carious lesions at the moment the lesions reached dentin-enamel junction or just penetrated dentin, but further studies are necessary to conclude about the restorative decisions of dentists in Split and Dalmatia County.

Received: March 22, 2009

Accepted: May 25, 2009

Address for correspondence

Ivana Miletić
Department of Endodontics and
Restorative Dentistry,
School of Dental Medicine, University of
Zagreb, Croatia
Gundulićeva 5, 10 000 Zagreb
Tel: + 385 1 4802 128
Fax: + 385 1 4802 159
miletic@sfdz.hr

Key words

Dental caries; Dentin; Questionnaires,
Health care surveys

References

- Poulsen S, Malling Pedersen M. Dental caries in Danish children: 1988-2001. *Eur J Paediatr Dent.* 2002;3(4):195-8.
- Beltrán-Aguilar ED, Barker LK, Canto MT, Dye BA, Gooch BF, Griffin SO, et al. Surveillance for dental caries, dental sealants, tooth retention, edentulism, and enamel fluorosis--United States, 1988-1994 and 1999-2002. *MMWR Surveill Summ.* 2005;54(3):1-43.
- Hugoson A, Koch G, Göthberg C, Helkimo AN, Lundin SA, Norderyd O, et al. Oral health of individuals aged 3-80 years in Jönköping, Sweden during 30 years (1973-2003). II. Review of clinical and radiographic findings. *Swed Dent J.* 2005;29(4):139-55.
- Rajić Z, Radionov D, Rajić-Mestrovic S. Trends in dental caries in 12-year old children in Croatia. *Coll Antropol.* 2000;24 Suppl 1:21-4.
- Espelid I, Tveit A, Haugejorden O, Riordan PJ. Variation in radiographic interpretation and restorative treatment decisions on approximal caries among dentists in Norway. *Community Dent Oral Epidemiol.* 1985;13(1):26-9.
- Mileman PA, Espelid I. Decisions on restorative treatment and recall intervals based on bitewing radiographs. A comparison between national surveys of Dutch and Norwegian practitioners. *Community Dent Health.* 1988;5(3):273-84.
- Nuttall NM, Pitts NB. Restorative treatment thresholds reported to be used by dentists in Scotland. *Br Dent J.* 1990;169(5):119-26.
- Riordan PJ, Espelid I, Tveit AB. Radiographic interpretation and treatment decisions among dental therapists and dentists in Western Australia. *Community Dent Oral Epidemiol.* 1991;19(5):268-71.
- Mejäre I, Sundberg H, Espelid I, Tveit B. Caries assessment and restorative treatment thresholds reported by Swedish dentists. *Acta Odontol Scand.* 1999;57(3):149-54.
- Sundberg H, Mejäre I, Espelid I, Tveit AB. Swedish dentists' decisions on preparation techniques and restorative materials. *Acta Odontol Scand.* 2000;58(3):135-41.
- Tveit AB, Espelid I, Skodje F. Restorative treatment decisions on approximal caries in Norway. *Int Dent J.* 1999;49(3):165-72.
- Espelid I, Tveit AB. A comparison of radiographic occlusal and approximal caries diagnoses made by 240 dentists. *Acta Odontol Scand.* 2001;59(5):285-9.
- Doméjean-Orliaguet S, Tubert-Jeannin S, Riordan PJ, Espelid I, Tveit AB. French dentists' restorative treatment decisions. *Oral Health Prev Dent.* 2004;2(2):125-31.
- Tubert-Jeannin S, Doméjean-Orliaguet S, Riordan PJ, Espelid I, Tveit AB. Restorative treatment strategies reported by French university teachers. *J Dent Educ.* 2004;68(10):1096-103.
- Espelid I, Tveit AB, Mejäre I, Sundberg H, Hallonsten AL. Restorative treatment decisions on occlusal caries in Scandinavia. *Acta Odontol Scand.* 2001;59(1):21-7.
- Wiegand A, Attin T. Treatment of proximal caries lesions by tunnel restorations. *Dent Mater.* 2007;23(12):1461-7.
- Strand GV, Nordbø H, Tveit AB, Espelid I, Wikstrand K, Eide GE. A 3-year clinical study of tunnel restorations. *Eur J Oral Sci.* 1996;104(4 Pt 1):384-9.
- Nordbø H, Leirskar J, von der Fehr FR. Saucer-shaped cavity preparations for posterior approximal resin composite restorations: observations up to 10 years. *Quintessence Int.* 1998;29(1):5-11.
- Nytun RB, Raadal M, Espelid I. Diagnosis of dentin involvement in occlusal caries based on visual and radiographic examination of the teeth. *Scand J Dent Res.* 1992;100(3):144-8.
- Weintraub JA. Pit and fissure sealants in high-caries-risk individuals. *J Dent Educ.* 2001;65(10):1084-90.
- Richardson PS, McIntyre IG. Susceptibility of tooth surfaces to carious attack in young adults. *Community Dent Health.* 1996;13(3):163-8.
- Hassall DC, Mellor AC. The sealant restoration: indications, success and clinical technique. *Br Dent J.* 2001;191(7):358-62.